

# Acral pseudolymphomatous angiokeratoma of children respond to a combination of local UVA phototherapy and intralesional corticosteroids

Wasrin Natpracha MD,

Suthep Jirasuthat MD,

Ploysyne Rattanakaemakorn MD.

## ABSTRACT:

NATPRACHA W, JIRASUTHAT S, RATTANAKAEMAKORN P. ACRAL PSEUDOLYMPHOMATOUS ANGIOKERATOMA OF CHILDREN RESPOND TO A COMBINATION OF LOCAL UVA PHOTOTHERAPY AND INTRALESIONAL CORTICOSTEROIDS. THAI J DERMATOL 2019; 35: 149-155.

*DIVISION OF DERMATOLOGY, DEPARTMENT OF MEDICINE, FACULTY OF MEDICINE, RAMATHIBODI HOSPITAL, MAHIDOL UNIVERSITY, BANGKOK, THAILAND.*

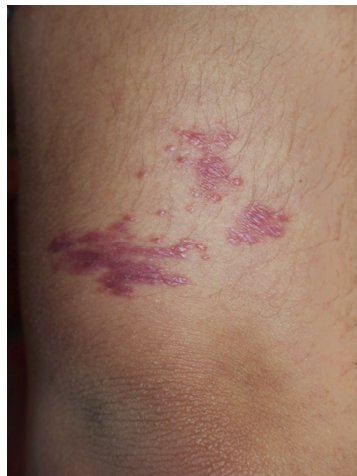
Acral pseudolymphomatous angiokeratoma of children or APACHE is a rare, benign cutaneous disease with unknown etiology, characterized by multiple, asymptomatic erythematous to violaceous papules and nodules, usually located unilaterally on the acral distribution, mostly affecting children. We reported a 12 year-old girl presented with 4 years history of multiple confluent non-blanchable erythematous papules and plaques on posterior aspect of right arm previously diagnosed as chronic eczema, followed by solitary mycosis fungoides after skin biopsy. The lesion did not respond to the one course of local NB-UVB. Repeat skin biopsy, immunohistochemistry, and also T-cell receptor gene rearrangement study were sent and the results were compatible with APACHE. Local UVA phototherapy combined with intralesional corticosteroid injection were treated with a good outcome after therapy.

**Key words:** Acral pseudolymphomatous angiokeratoma of children, APACHE, UVA, phototherapy

From: Division of Dermatology, Faculty of Medicine Ramathibodi Hospital, Mahidol University, Bangkok, Thailand

Corresponding author: Ploysyne Rattanakaemakorn MD., email: ploisyne@gmail.com

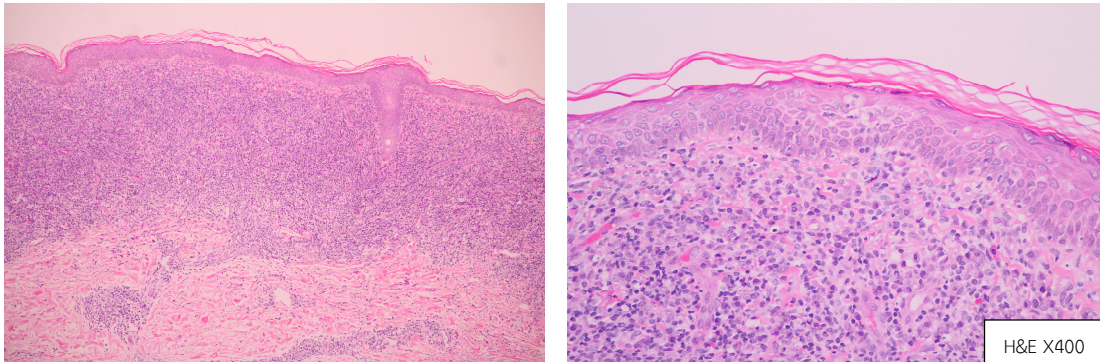
Acral Pseudolymphomatous Angiokeratoma of Children or APACHE was first described in 1988 by Ramsay, et al<sup>1-3</sup>. It is a rare, benign cutaneous disease with unknown etiology, characterized by multiple, asymptomatic erythematous to violaceous papules and nodules, usually located unilaterally on the acral distribution, mostly affecting children aged between 2 to 13 years<sup>2,4</sup>. However, cases with non-acral areas, solitary or linear lesion, and also adulthood onset have been reported, leading to different terms of the disease such as papular angiolymphoid hyperplasia, acral angiokeratoma-like pseudolymphoma, pseudolymphomatous angiokeratoma<sup>3,4</sup>. Nowadays approximately 25 cases has been reported in the literature.<sup>2</sup>



**Figure 1** A 12 year-old girl with 4 years history of multiple confluent non-blanchable erythematous

papules and plaques on posterior aspect of right arm.

We reported a 12 year-old girl presented with 4 years history of multiple confluent non-blanchable erythematous papules and plaques on posterior aspect of right arm, about 3 centimeters above elbow, previously diagnosed as chronic eczema. But the lesion was not improved by topical corticosteroids. Skin biopsied was done and showed dense lichenoid infiltration of lymphocytes in the upper dermis with lymphocyte exocytosis in the epidermis. Solitary mycosis fungoides was suspected. So the tissue was sent to Immunohistochemistry staining and it showed positivity of CD4, CD8, CD3, CD7 at lymphocytes which was not a typical feature of mycosis fungoides, mostly predominance of CD4 T-cell phenotype over CD8 and loss of CD7. However, T-cell receptor gene rearrangement study was sent and pending for the result. She was provisional diagnosed as solitary mycosis fungoides and treated with 29 sessions of local NBUVB phototherapy (starting dose at 200 mJ/cm<sup>2</sup>, twice weekly, increment 20%, fixed dose at 1,600 mJ/cm<sup>2</sup>) and topical 0.25% desoximetasone. The lesion was but not complete disappear. Three months after discontinue phototherapy due to inconvenient of the patient, the rash was relapsed.

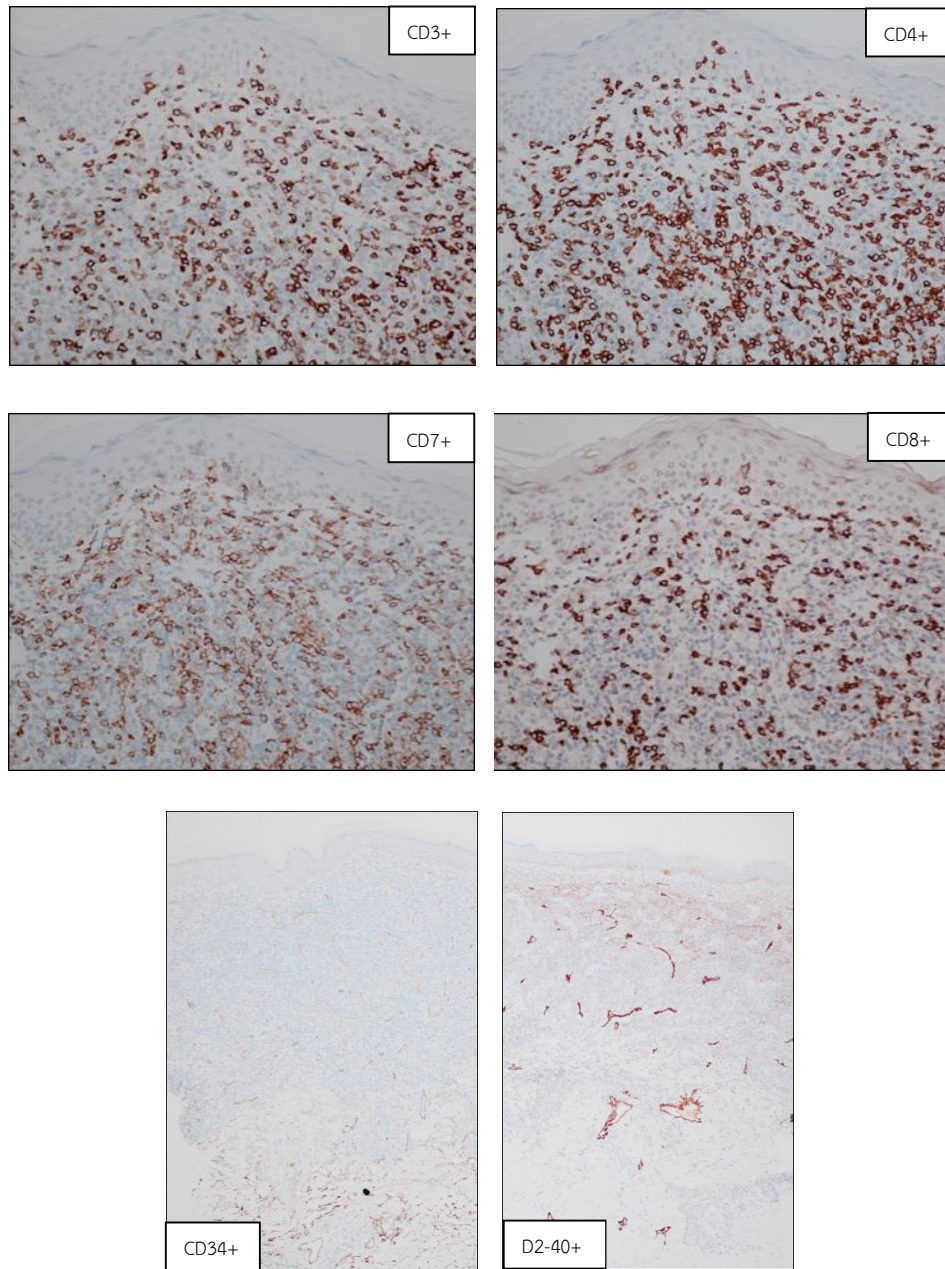


**Figure 2** Repeat skin biopsy showed dense diffuse inflammatory cells infiltration in the upper dermis composed of lymphocytes admixed with some plasma cells, prominent thick-walled blood vessels, and exocytosis of some lymphocytes.

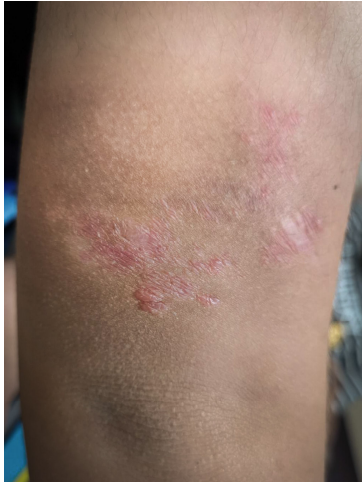Skin biopsy was performed and showed dense diffuse inflammatory cells infiltration in the upper dermis composed of lymphocytes admixed with some plasma cells, prominent thick-walled blood vessels, and exocytosis of some lymphocytes within lower epidermis. The feature of proliferation of thick wall blood vessels is not compatible with mycosis fungoides. Immunohistochemistry staining was sent and revealed a positivity of CD4, CD8, CD3, CD7 at lymphocytes same as previous results. Moreover, it was positive for CD20 (marker of B-cell), CD34 (marker of blood vessels), and D2-40 (marker of lymphatic channels) at vascular channels. T-cell receptor gene rearrangement revealed polyclonality. Acral Pseudolymphomatous

Angiokeratoma of Children or APACHE was definitely diagnosed.

In the past, APACHE was described as a vascular malformation or tumor of vascular nature.<sup>3</sup> In present, APACHE was described as one type of pseudolymphoma due to histopathological study, including immunohistochemistry which revealed a dense subepidermal lymphocytic infiltration admixed with numerous histiocytes, plasma cells and occasionally eosinophils<sup>5</sup>, prominent blood vessels with plump endothelium, included forming of lymphoid follicles in some cases<sup>1,3</sup>. The feature of dense lymphocytic infiltration was a sign of pseudolymphoma while other findings supported the lymphoid hyperplasia entity<sup>3</sup>.



**Figure 3** Immunohistochemistry staining revealed a positivity of CD4, CD8, CD3, CD7, CD20, CD34 and D2-40



**Figure 4** After 31 sessions of local UVA phototherapy and 3 treatments of intralesional corticosteroids the lesion was significantly flat.

Immunohistochemistry demonstrated the admixture of B- (CD20+) and T- (CD3+) lymphocytes with variety in proportion<sup>1,3</sup> as well as CD8+ and CD4+ T-cell, even equal in number<sup>3,5</sup>. Antibodies against kappa or lambda light chains of B cells did not showed any evidence of light chain restriction<sup>5,6</sup>. APACHE also showed a vascular component, the expression of CD34 and podoplanin (D2-40) in the immunohistochemistry suggested a vascular malformation in nature<sup>3,7</sup>. However, there was a literature reported the expression of Wilms tumor-1 (WT-1), which is found to be useful in distinguishing vascular malformations (which would be negative) from proliferative endothelial lesions (which would be positive), with lack of D2-

40 by the vascular component of the case explained a proliferative endothelial nature rather than malformation<sup>3</sup>. By the way, APACHE is classified as a distinct type of pseudolymphoma at present<sup>2,3,8</sup>. The exact nature of this disease remains undetermined.<sup>7</sup>

The differentiation of cutaneous pseudolymphoma from malignant lymphoma is one of the most challenging problems in dermatopathology<sup>8</sup>. Further investigations should be performed to exclude malignant cell populations<sup>2,8</sup>. The band-like cell infiltration pattern in APACHE was similar to histopathologic feature of mycosis fungoides (MF), the lack of or minimal epidermotropism could differentiate cutaneous lymphoma from MF<sup>8</sup>. However, there were some report of exocytosis of lymphocytes in APACHE<sup>6</sup>. So the immunohistochemical study and demonstration of clonal T-cell rearrangements and aberrant T-cell phenotype could be used to distinguish APACHE from MF and also from cutaneous lymphoma<sup>6,8,9</sup>.

Many modalities were reported as a treatment of APACHE, included surgical excision, curettage, shave excision followed by electrocautery, intralesional triamcinolone injection, cryotherapy, and radiotherapy<sup>2,4</sup>. However, only surgical excision, curettage, and shave excision followed by electrocautery have been performed with resulting in disappearance of the lesion without recurrence<sup>4</sup>. To our knowledge, UVA

phototherapy, one of the first line therapy of pseudomycosis fungoides and as the effective treatment for solitary mycosis fungoides<sup>10</sup>, has ability to induce T-lymphocyte apoptosis and more depth of penetration than NB-UVB. It can reduce the inflammatory cells in the dermis leading to a curative of the lesion. In our case, because the lesion located near the elbow joint which excision may increase risk of scar and affect joint movement. Moreover, the lesion relapsed after NB-UVB phototherapy and side effects of psoralen limited its use in this patient. A local UVA phototherapy (Waldmann® UVA 700L, Germany) was started in combination with intralesional corticosteroid injection. After 31 sessions of local UVA phototherapy (starting dose 10 J/cm<sup>2</sup>, once weekly, increment 5 J/treatment, fixed dose at 50 J/cm<sup>2</sup>) and 3 treatments of intralesional triamcinolone acetonide injection 10 mg/ml monthly the lesion was significantly flat. The phototherapy was continued alone. After 50 sessions of local UVA phototherapy the papules and plaques were improved leaving post inflammatory erythema and hyperpigmented patches.

In conclusion, acral pseudolymphomatous angiokeratoma of children or APACHE must be recognized in child presented with unilateral multiple, asymptomatic erythematous to violaceous papules and nodules on acral site. It is a benign disease which can be treated with UVA

phototherapy. By the way, phototherapy once weekly was continued in this case and long-term follow-up for relapse after stopped the treatment was required to determine the efficacy of UVA phototherapy and also relapse rate in treatment of APACHE.

### References

1. Ramsay B, Dahl MC, Malcolm AJ, Wilson-Jones E. Acral pseudolymphomatous angiokeratoma of children. *Arch Dermatol* 1990; 126: 1524-5.
2. Lessa PP, Jorge JC, Ferreira FR, Lira ML, Mandelbaum SH. Acral pseudolymphomatous angiokeratoma: case report and literature review. *An Bras Dermatol* 2013; 88: 39-43.
3. Fernandez-Flores A, Fierro S, Larralde M. Expression of WT-1 by the vascular component of acral pseudolymphomatous angiokeratoma of children. *J Cutan Pathol* 2015; 42: 50-5.
4. Kim Y, Dawes-Higgs E, Mann S, Cook DK. Acral pseudolymphomatous angiokeratoma of children (APACHE). *Australas J Dermatol* 2005; 46: 177-80.
5. Hagari Y, Hagari S, Kambe N, Kawaguchi T, Nakamoto S, Mihara M. Acral pseudolymphomatous angiokeratoma of children: immunohistochemical and clonal analyses of the infiltrating cells. *J Cutan Pathol* 2002; 29: 313-8.
6. Evans MS, Burkhart CN, Bowers EV, Culpepper KS, Googe PB, Magro CM. Solitary plaque on the leg of a child: A report of two cases and a brief review of acral pseudolymphomatous angiokeratoma of children and unilesional mycosis fungoides. *Pediatr Dermatol* 2018. doi: 10.1111/13686.

7. Tokuda Y, Arakura F, Murata H, Koga H, Kawachi S, Nakazawa K. Acral pseudolymphomatous angiokeratoma of children: a case report with immunohistochemical study of antipodoplanin antigen. *Am J Dermatopathol* 2012; 34: 128-32.
8. Lee MW, Lee DK, Choi JH, Moon KC, Koh JK. Clinicopathologic study of cutaneous pseudolymphomas. *J Dermatol* 2005; 32: 594-601.
9. Ally MS, Pawade J, Tanaka M, et al. Solitary mycosis fungoides: a distinct clinicopathologic entity with a good prognosis: a series of 15 cases and literature review. *J Am Acad Dermatol* 2012; 67: 736-44.
10. El Mofty M, Ramadan S, Fawzy MM, Hegazy RA, Sayed S. Broad band UVA: a possible reliable alternative to PUVA in the treatment of early-stage mycosis fungoides. *Photodermatol Photoimmunol Photomed* 2012; 28: 274-7.