Treatment of Becker's nevus : Comparison between Intense Pulsed Light and Frequency-double Q-switched Nd:YAG laser.

Prapawan Chawvavanich MD,

Jinda Rojanamatin MD.

ABSTRACT:

CHAWVAVANICH P, ROJANAMATIN J. TREATMENT OF BECKER'S NEVUS : COMPARISON BETWEEN INTENSE PULSED LIGHT AND FREQUENCY-DOUBLE Q-SWITCHED Nd : YAG LASE. THAI J DERMATOL 2008; 24: 177-184.

INSTITUE OF DERMATOLOGY, DEPARTMENT OF MEDICAL SERVICES, BANKOK, THAILAND.

Becker's nevus are notoriously difficult to clear, because of their hamartomatous pathophysiology. Several studies reported limited success with various lasers.

Objective: This study is a pilot study to compare the efficacy of intense pulsed light(IPL) and frequency-double Q-switched Nd:YAG laser in the treatment of Becker's nevus.

Methods: Ten patients with Becker's nevus were treated by IPL and frequency-double Q-switched Nd:YAG laser four times.

Results: The mean melanin index (MI) reduction after Q-switch Nd:YAG laser treated side is 8.516 ($p = 0.007$). The IPL treated side, the mean MI reduction is 1.857($p = 0.319$). The Q-switch Nd:YAG laser treated side show mild improvement in 2 patients, moderate improvement in 3 patients and significant improvement in 4 patients.None reported no improvement. The IPL treated side show mild improvement in 2 patients, moderate improvement in 1 patients and significant improvement in 1 patients. Five reported no improvement. Postinflammatory hyperpigmentation was observed in both sides but more severe in the IPL treated side.

Conclusion: Frequency-double Q-switched Nd:YAG in more effective than Intense pulsed light for Becker's nevus therapy.

Key words: Becker's nevus, Frequency-double Q-switched Nd:YAG Laser, Intense Pulsed Light

บทคัดย่อ :

ประภาวรรณ เชาวะวณิช, จินดา โรจนเมธินทร์ การศึกษาเปรียบเทียบประสิทธิภาพของการรักษา BECKER'S NEVUS โดยการใช้เครื่อง INTENSE PULSED LIGHT กับ FREQUENCY- DOUBLE Q-SWITCHED Nd:YAG LASER วารสารโรคผิวหนัง 2551; 24: 177-184.

สถาบันโรคผิวหนัง กรมการแพทย์

Becker's nevus เป็นปานชนิดหนึ่งที่พบได้บ่อยในบริเวณหัวไหล่ หน้าอก และสะบัก แต่อาจพบได้ในบริเวณใบหน้า แขนขา และหลัง ขนาดเส้นผ่าศูนย์กลางประมาณ 10-20 ซม. Becker's nevus รักษาให้หายได้ยาก เคยมีการรายงานศึกษาการรักษาด้วยเลเซอร์เม็ดสีหลายชนิดว่า ได้ผลจำกัด

วัตถุประสงค์: การศึกษานี้เป็นการศึกษานำร่องถึงผลการรักษา Becker's nevus เปรียบเทียบระหว่างการรักษาด้วยเครื่อง intense pulsed light (IPL) และเครื่องfrequency-double Q-switched Nd:YAG laser

วิธีการ: ผู้ป่วยที่มี Becker's nevus 10 คน ได้รับการรักษาด้วย IPL และ frequency-double Q-switched Nd:YAG laser ทั้งหมด 4 ครั้ง

ผลการศึกษา: รอยโรคด้านที่รักษาด้วยเครื่องfrequency-double Q-switched Nd:YAG laser (QS Nd:YAG)พบว่ามีการลดลงของmelanin indexของรอยโรคประมาณ 8.516 (p = 0.007) รอยโรคด้านที่รักษาด้วยเครื่องIPL มีการลดลงของ melanin indexของรอยโรคประมาณ 1.857 (p = 0.319) การหายของรอยโรคด้านที่รักษาด้วย QS Nd:YAG laser ดีขึ้นมาก 4 ราย ดีขึ้นปานกลาง 3 ราย ดีขึ้นเล็กน้อย 2 ราย การหายของรอยโรคด้านที่รักษาด้วย IPL ดีขึ้นมาก 1 ราย ดีขึ้นปานกลาง 1 ราย ดีขึ้นเล็กน้อย 2 รายและไม่ดีขึ้น 5 ราย ผลข้างเคียงที่พบทั้งสองด้านคือรอยดำหลังการอักเสบแต่พบความรุนแรงมากกว่าในด้านที่รักษาด้วยเครื่อง IPL แต่ในรายที่ผลการรักษาด้วยIPL แล้วได้ผลดีขึ้นมากจะมีลักษณะทางคลินิกที่กลมกลืนกับผิวหนังปกติดีกว่าการรักษาด้วย QS Nd:YAG laser

สรุป: การรักษา Becker's nevus ด้วยเครื่อง frequency-double Q-switched Nd:YAG laser ได้ผลดีกว่าการรักษาด้วยเครื่อง IPL

คำสำคัญ: ปาน Becker , เลเซอร์เม็ดสี, เครื่องแสงความเข้มสูง

Becker's nevus usually appear in childhood or early adult life on any body areas as a light-to-medium brown patch ranging in size from 2 to 40 cm in diameter. Lesions are variably hyperkeratotic, with an increase in coarseness of hair occurring during puberty. Incidence has been calculated to be 0.5% of the population. Histologically, these lesions show rete ridge elongation and basal cell hyperpigmentation with variable amounts of acanthosis and hyperkeratosis. Melanocytes appear to be increased and the dermis tends to be thickened. In addition. Hypertrophied sebaceous glands and bundles of smooth muscles fibers and enlarged pilar apparatus may be present. Therefore this lesion is more correctly considered an organoid harmatoma.[1]

Becker's nevus are notoriously difficult to clear, possibly because of their hamartomatous pathophysiology. Several studies have been reported limited success with a variety of lasers. Melanin-specific, high-energy, Q-switched laser systems can successfully lighten or eradicate a variety of benign epidermal and dermal pigmented lesions and tattoos with minimal risk of untoward effects.[2] Epidermal lesions (solar lentigines, ephelides, cafe´- au-lait macules, and seborrheic keratoses), dermal and mixed epidermal/dermal lesions (melanocytic nevi, blue nevi, nevi of Ota/Ito, infraorbital hyperpigmentation, drug-induced hyperpigmentation, Becker's nevi, and nevus spilus), and amateur, professional, and traumatic tattoos have all been shown to improve after laser treatment.[3-7] The Q-switched ruby, alexandrite, and Nd:YAG lasers can effectively target the increased pigmentation in Becker's nevus, but recurrence is common.[1]

Intense pulsed light (IPL) sources emit in the 500–1200 nm range and allow variation of pulse length/mode, delay between pulses, and fluence energy. This flexibility in parameters allows hair removal, treatment of vascular lesions, and, in theory, removal of either superficial or deep melanocytic, lesions. However, a few reports on treatment of melanocytic lesions have been published.[8]

The target of laser and IPL treatment of melanocytic lesions is the melanosome, a natural chromophore of the skin. Selective thermal damage has been observed with a wide range of wavelengths, from 351 to 1064 nm. Short wavelengths (500–600 nm) reach 200 nm beneath the epidermis and are safe for treatment of superficial melanocytic lesions due to preservation of the dermis, while longer wavelength (1064 nm) penetrate up to 3.7 mm and are more suitable for dermal melanocytic lesion removal. Both green and red Q-switched lasers (alexandrite, Nd:YAG, and ruby) have been used for pigmented lesion treatment. Q-switched systems emit very short pulses (nanosecond range) of high energy that lead to nuclear and cellular lysis of exposed melanocytes. These systems efficiently eliminate both superficial and deep melanocytic lesions with minimal side effects. Theoretically, long pulses, greater than the melanosome TRT, may lead to coagulation necrosis due to heat diffusion beyond the target, with potential deleterious side effects. However, removal of

superficial melanocytic lesions has been observed after treatment with 300-msec pulses (510 nm pulsed dye laser) without important side effects.[8]

Regarding wavelengths, IPL sources can be used with cutoff filters as low as 515 nm for superficial pigmentation with good results.[9] Higher filters may be used for deeper melanocytic pigmentation.[10] This study is a pilot study to compare the efficacy of intense pulsed light (IPL) and frequency-double Q-switched Nd:YAG laser in the treatment of Becker's nevus.

Patients and Methods

The treatment protocol was approved by the Medical Ethics and Human Reserch Committee of the Institute of Dermatology, Department of Medical Services, Ministry of Public Health, Thailand. Ten consenting adult volunteers participated in the study. There were 7 women and 3 men enrolled. The mean age was 23.4 years, and the number of the patients with the following Fitzpatrick skin types were as follow : type III= 1, and type IV = 9(total n = 10). None of the patients received any previous treatment. Body areas treated included the chest (n = 2) ,upper back (n = 5),buttock (n = 1), hand (n = 1) and leg (n = 1) . Exclusion criteria included pregnancy, history of keloid or excessive scar formation, use of photosensitizing medication and photosensitive disorders. Each lesion was divided into 2 parts . The first part was treated by frequency-double Q-switched Nd:YAG laser (532nm) (Medlite C3, HOYA ConBio, CA, USA) four times with the following parameters : 532 nm, 4 mm spot size, fluence energy of 1.1-1.6 J/cm2 at 6-8week interval. The second was treated by a noncoherent flash-pumped IPL device (Quantum SR, ESC Medical Systems Ltd., Yokneam, Israel) four times with the following parameters: 560 and 590 nm filter, fluence energy of 20-26 J/cm , pulse width of 3-5 msec, double mode, and a delay of 40 -50 msec, at 6-8 week intervals. The wound was left open and applied on topical tetracycline ointment during the first week after treatment.

During each treatment visit, standardized digital photographic documentations were collected. Each patient was measured for Melanin Index (MI) using a reflectance spectrophotometer (DSM II ColorMeter, Cortex Technology, Denmark) in order to obtain objective measurement of skin color at base line and each follow-up visit. The three darkest areas of the involved skin were measured and then calculated for mean MI.

Complications were assessed at each subsequent follow-up visit and 24 week after treatment. Clinical improvement was globally assessed by dermatologist ranking the degree of improvement as significant improve>75%, moderate=50-<75%, mild=25-<50% or none less than 25%. Melanin index and the standard deviations at baseline were compared using a paired t-test.

Results

All patients experienced a reduction in pigmentation of the lesions on the Q-switch Nd:YAG laser treated side. Nine patients complete the study. There is one

patient who can't complete the treatment because he can't tolerate the pain from QS Nd:YAG laser treatment. Overall, the mean MI reduction on the Q-switch Nd:YAG laser treated side is 8.516 (p = 0.007). On the IPL treated side, the mean MI reduction is 1.857(p = 0.319). The clinical improvement was globally assessed by dermatologist, the Q-switch Nd:YAG laser treated side show mild improvement in 2 patients(22.22%), moderate improvement in 3 patients(33.33%) and significant improvement in 4 patients(44.44%). None reported no improvement. The IPL treated side show mild improvement in 2 patients(22.22%), moderate improvement in 1 patients(11.11%) and significant improvement in 1 patients(11.11%), five reported no improvement(55.55%). (Table 1)

All patients developed hyperpigmentation on the IPL treated sides (Figure 1) and hypo-hyperpigmentation on the QS Nd:YAG laser treated side (Figure 2). Hyperpigmentation from IPL was treated with 3% hydroquinone in triamcinolone cream. There were significant pain in the QS Nd:YAG laser treated side. Five patients prefered IPL treatment than QS Nd:YAG laser because there was less pain in IPL treated side and the colour improvement was homogeneous than QS Nd:YAG. A marked difference in skin colour was observed in the transitional area between Becker's nevus and normal skin in QS Nd:YAG laser treated side(figure 2). No clinical scarring was observed.

One patient got a significant improvement on both side of treatments. (Figure3).

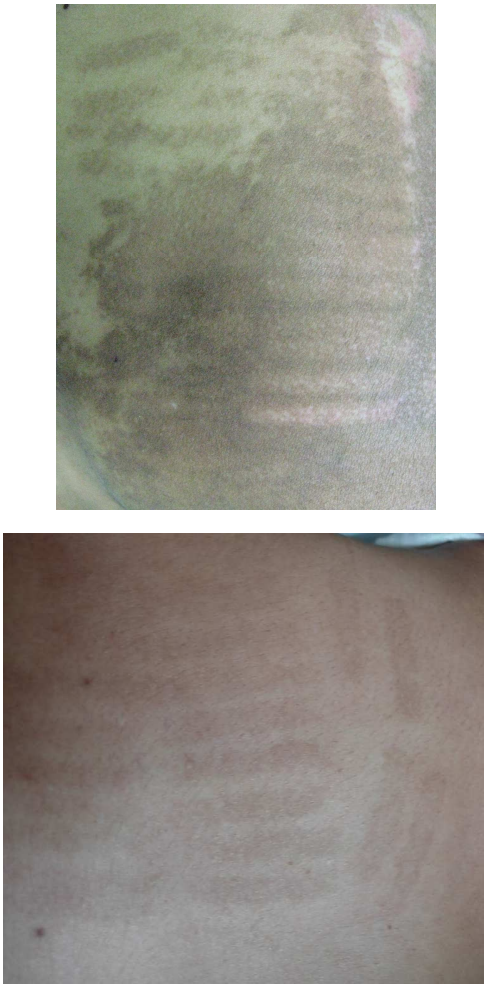

Figure 1 Hyperpigmentation after IPL treatment



Figure 2 Hypo-hyperpigmentation after QS Nd:YAG laser treatment

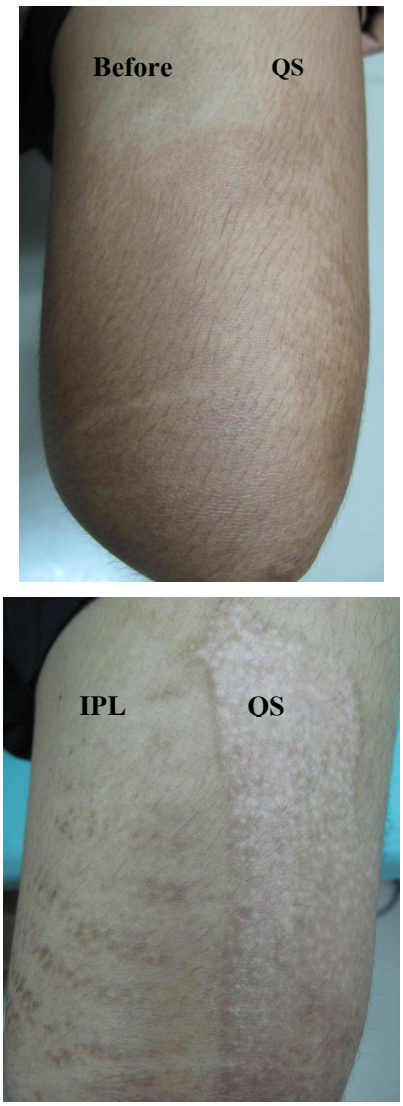

Figure 3 Significant improvement in the both side: before and after treatments (Q=QS Nd:YAG)

Table 1

Clinical improvement	QS Nd:YAG treated side (*n*=9)	IPL treated side (*n*=9)
Significant improvement	4	1
Moderate improvement	3	1
Mild improvement	2	2
No improvement	-	5

Discussion

Becker's nevus is an uncommon hamartoma and a treatment challenge for the physician. In the past, treatment of this skin condition included mechanical abrasion, surgical excision or cryotherapy. However, final cosmetic results were unfavourable and scarring or repigmentation was common after treatment.[11]

The development of more pigment-specific laser systems led to better treatment for Becker's nevus.

Becker's nevus are notoriously difficult to clear, possibly because of their hamartomatous pathophysiology. Several studies have been reported limited success with a variety of lasers. The Q-switched ruby, alexandrite, and Nd:YAG lasers can effectively target the increased pigmentation in Becker's nevus, but recurrence is common.

Intense pulsed light (IPL) sources emit between 500–1200 nm with variation of pulse length/mode, delay between pulses, and fluence energy. The flexibility parameters make it an effective tool for hair removal, treatment of vascular lesions, and, theoretically, removal of either superficial or deep melanocytic lesions. However, only few reports about treatment of melanocytic lesions have been published.

This study, showed statistically significant improvement in reduction of melanin index after QS Nd:YAG laser treatment. The clinical improvement was globally assessed by dermatologist, the QS Nd:YAG laser treated side show mild improvement in 2 patients, moderate improvement in 3 patients and significant improvement in 4 patients. None reported no improvement. Marked difference in skin colour was observed in the transitional area between Becker's nevus and normal skin in QS Nd:YAG laser treated side. There is one patient who cannot complete the treatment because he can't tolerate the pain from QS Nd:YAG laser treatment. On IPL treated side there was no statistically significant improvement in reduction of melanin index. Only one patient showed significant improvement after IPL treatment. However, IPL treatment produced less contrast of pigment. (figure 3)

In conclusion, QS Nd:YAG laser is more effective in treatment of Becker's nevus than IPL. Moderate to significant improvement after 4 treatments with QS

Nd:YAG was observed in 77.77% of the patients but only 22.22% in IPL treated sides.

References

1. Kilmer SL, Goldman MP, Fitzpatrick RE. Treatment of benign pigmented cutaneous lesions. In: Goldman MP, Fitzpatrick RE, Cutaneous laser surrgey, 2nd ed Missouri: Mosby 1999; 179-211.
2. Tanzi EL, Lupton RJ, Alster TS. Laser in dermatology : Four decades of progress. J Am Acad Dermatol 2003; 49: 1-31.
3. Kilmer SL. Laser eradication of pigmented lesion and tattoos. Dermatol Clin 2002;20:37-53.
4. Alster TS, Lupton JR. Laser therapy for cutaneous hyperpigmentation and pigmented lesions. Dermatol Ther 2001;14:46-54.
5. Alster TS. Laser treatment of pigmented lesions. In: Alster TS. Manual of cutaneous laser techniques. 2nd ed. Philadelphia: Lippincott, Williams & Wilkins; 2000. p. 53-70.
6. Kilmer SL, Garden JM. Laser treatment of pigmented lesions and tattoos. Semin Cutan Med Surg 2000;19:232-44.
7. Stratigos AJ, Dover JS, Arndt KA. Laser treatment of pigmented lesions-2000. How far have we gone? Arch Dermatol 2000;136: 915-21.
8. Moreno Arias GA, Ferrando J. Intense pulsed light for melanocytic lesions. Dermatol Surg 2001; 4: 397-400.
9. Weiss RA, Goldman MP, Weiss MA. Treatment of poikiloderma of Civatte with an intense pulsed light source. Dermatol Surg 2000; 26:823–8.
10. Gold MH, Foster TD, Bell MW. Nevus spilus successfully treated with an intense pulsed light source. Dermatol Surg 1999;25:254–5.
11. M.A. Trelles, I. Allones, G.A. Moreno-Arias and M. Ve´lez. Becker's naevus: a comparative study between erbium:YAG and Q-switched neodymium:YAG; clinical and histopathological findings. Br J Dermatol 2005; 152:308–313
12. Nanni CA, Alster TS. Treatment of a Becker's nevus using a 694-nm long-pulsed ruby laser. Dermatol Surg 1998; 24:1032–4.