Thai J Ophthalmol 2026;40(1):37-47.

Case Report/รายงานผู้ป่วย

Central Serous Chorioretinopathy Coincident with Suprasellar Meningioma: A Case Report

Thikumporn Chanpoo, MD[1*], Poramaet Laowanapiban, PhD, MD[2], Chutiporn Kiratikajonchai, MD[3]

Abstract

A 41-year-old woman with systemic lupus erythematosus (SLE) presented with blurred vision in her right eye for 3 months. A few weeks later, she developed progressive painless visual loss with an involved central area of vision in her right eye. Ophthalmological examination and OCT macula scan revealed serous subretinal fluid in the right macular region. Fundus fluorescein angiography (FFA) and indocyanine green angiography (ICGA) were subsequently performed a few weeks later. The patient underwent focal laser photocoagulation at an extrafoveal leakage site in the right eye, guided by FFA and ICGA findings. However, her visual function continued to deteriorate. Visual field testing demonstrated a significant bitemporal hemianopic defect. Contrast-enhanced magnetic resonance imaging (MRI) of the brain and orbit revealed a suprasellar mass compressing the optic chiasm, consistent with a meningioma.

This case report describes an SLE patient receiving systemic corticosteroids who developed central serous chorioretinopathy (CSCR) and was subsequently found to have a suprasellar meningioma compressing the optic chiasm. The concurrence of CSCR and meningioma in this patient is best interpreted as a coincidental coexistence, and no causal association is implied. Although neuroimaging is not routinely indicated for typical CSCR, it should be considered when visual function is disproportionately poor, when symptoms progress, when perimetry suggests a chiasmal pattern, or when visual impairment persists despite apparent anatomical resolution of subretinal fluid.

Keywords: Central serous chorioretinopathy, Suprasellar meningioma, Systemic lupus erythematous.

[1] Vitreoretinal unit, Department of Ophthalmology, Mettapracharak (Watraikhing) Hospital, Nakhon Pathom, Thailand.

[2] Neuro-Ophthalmology unit, Department of Ophthalmology, Mettapracharak (Watraikhing) Hospital, Nakhon Pathom, Thailand.

[3] Radiology unit, Department of Radiology, Mettapracharak (Watraikhing) Hospital, Nakhon Pathom, Thailand

Introduction

Central serous chorioretinopathy (CSCR) is a common retinal disorder characterized by the accumulation of subretinal fluid beneath the neurosensory retina. This is the condition that separates neurosensory retina from retinal pigment epithelium cells (RPE), typically involving the macular region. The exact pathophysiology of CSCR remains unclear, but it is believed to involve increased choroidal thickness and dysfunction of the RPE pump mechanism associated with choroidal vascular hyperpermeability and venous congestion, leading leakage at the RPE level.[1-3] It predominantly occurs in young to middle-aged between 20-50 years, reported male-to-female ratio ranges from 2:1 to 6:1.[4-6] The most common risk factor of CSCR is corticosteroid exposure. Exogenous corticosteroid administration - include oral, intravenous, intranasal, intra-articular, inhaled, topical dermal and intravaginal routes – has been strongly associated with the disease even at low dose.[7-14] A meta-analysis of six case control studies found the odds of developing CSCR with exogenous corticosteroids to be 4.05 compared with patients who did not use corticosteroids.[14] The other risk factors are hyperaldosteronism[15-17], elevated serum testosterone levels[15-17], pregnancy[18], systemic hypertension[19], organ transplantation[20-21], psychological stress and type A personality traits[22], genetic and family history[23], use of phosphodiesterase-6 inhibitors[24], sleep disturbance and obstructive sleep apnea[25-27], hyperopia[28] and Helicobacter pylori infection[10]. CSCR can present as an acute, self-limiting condition or a chronic, recurrent form. The chronic type may result in persistent subretinal fluid, irreversible photoreceptor damage and permanent visual impairment. Clinically, patients often experience decreased central vision accompanied by central scotoma, metamorphopsia, dyschromatopsia, micropsia and reduced contrast sensitivity[29].

Suprasellar meningiomas are benign extra-axial intracranial tumors that may cause progressive visual dysfunction due to optic chiasm compression, classically presenting with visual field loss that respects the vertical meridian. When retinal pathology coexists with a compressive optic pathway lesion, retinal findings may initially appear to account for the patient's symptoms and delay recognition of a neuro-ophthalmic cause of visual loss.

In the present case, we report a patient with systemic lupus erythematosus (SLE) receiving systemic corticosteroids who developed CSCR and was subsequently diagnosed with a suprasellar meningioma. This report describes a coincidental coexistence rather than implying a mechanistic or causal association, and it highlights clinical red flags that should prompt neuro-ophthalmic evaluation and neuroimaging.

Case Report

A 41-year-old woman with SLE for 5 years presented to the hospital with a complaint of blurred vision in her right eye for 3 months, which had progressively worsened over the central visual field within the preceding 2 weeks. Her best-corrected visual acuity (BCVA) was counting finger at 3 feet, improving to $20/70^{-2}$ with a pinhole in the right eye and $20/20^{-2}$ in left eye on the Snellen chart. Intraocular pressure was within normal limit, and anterior segment examination revealed no significant abnormalities.

Fundoscopic examination (Figure 1) and macular optical coherence tomography (OCT) (Figure 2) revealed the presence of subretinal fluid involving the macular area of the right eye. A detailed medication history revealed that she had been receiving oral prednisolone for SLE, which had been gradually tapered from a higher dose over the preceding 2 years to 5 mg once daily. She had been maintained at 5 mg/day for approximately 4 months prior to the onset

of visual symptoms. She had also been receiving hydroxychloroquine 200 mg once daily, which was reduced to 200 mg every other day approximately 1 month after the onset of blurred vision. She denied other forms of corticosteroid exposure (e.g., inhaled, intranasal, topical, or intra-articular) in the months preceding symptom onset. Given the strong association between systemic corticosteroids and CSCR, steroid-associated CSCR was considered a major diagnostic possibility, and the patient was co-managed with a rheumatologist to taper and finally discontinue systemic corticosteroids as clinically feasible.

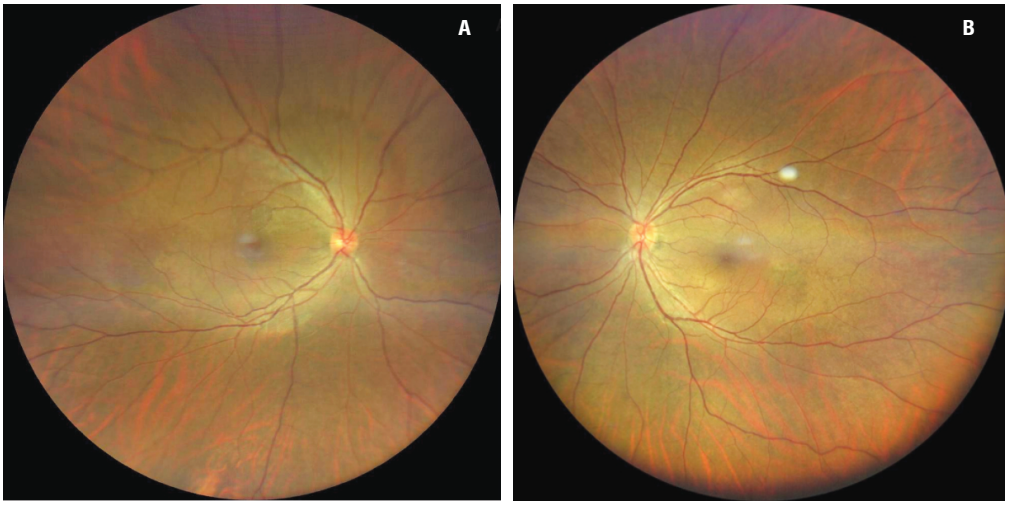

Figure 1 Color fundus photography of the right eye demonstrates a well-demarcated, dome-shaped serous retinal detachment at nasal macular area and extending to superior to optic disc, due to accumulation of subretinal fluid (Figure 1A). No subretinal fluid seen in left eye (Figure 1B).

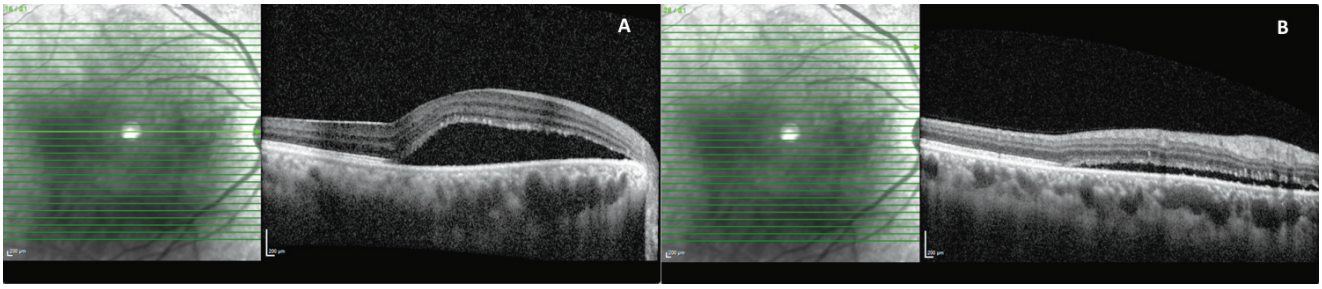

Figure 2 Macular optical coherence tomography (OCT) of the right eye shows significant serous retinal detachment and separation of the neurosensory retina and retinal pigment epithelial layer in the right eye at nasal macula (Figure 2A) and extends to superior optic disc area (Figure 2B).

After discontinuing oral prednisolone for 1 month, OCT macula (Figure 3A and B) still demonstrated persistent subretinal fluid in the right eye. The fundus fluorescein angiography (FFA) and indocyanine green angiography (ICGA) were performed, revealing leakage at an extrafoveal site (Figure 3C to H). The patient subsequently underwent focal laser photocoagulation targeting the leakage point.

Subsequent focal laser for a month, the subretinal fluid had decreased but was still present. Her visual acuity remained counting fingers at 3 feet, improving to $20/50^{-2}$ with pinhole correction in the right eye, while

the left eye maintained 20/20^{-2} vision.

After 4 months after focal laser treatment, the subretinal fluid had completely resolved; however, the patient's visual acuity showed no improvement, remaining counting fingers at 3 feet with pinhole correction to 20/70^{-2} in the right eye. OCT of the macula showed anatomical integrity with minimal alteration at the photoreceptor–RPE junction (Figure 4). Visual field testing revealed a significant bitemporal hemianopic defect, raising suspicion of an intracranial lesion (Figure 5). The patient was referred to a neuro-ophthalmologist for further evaluation.

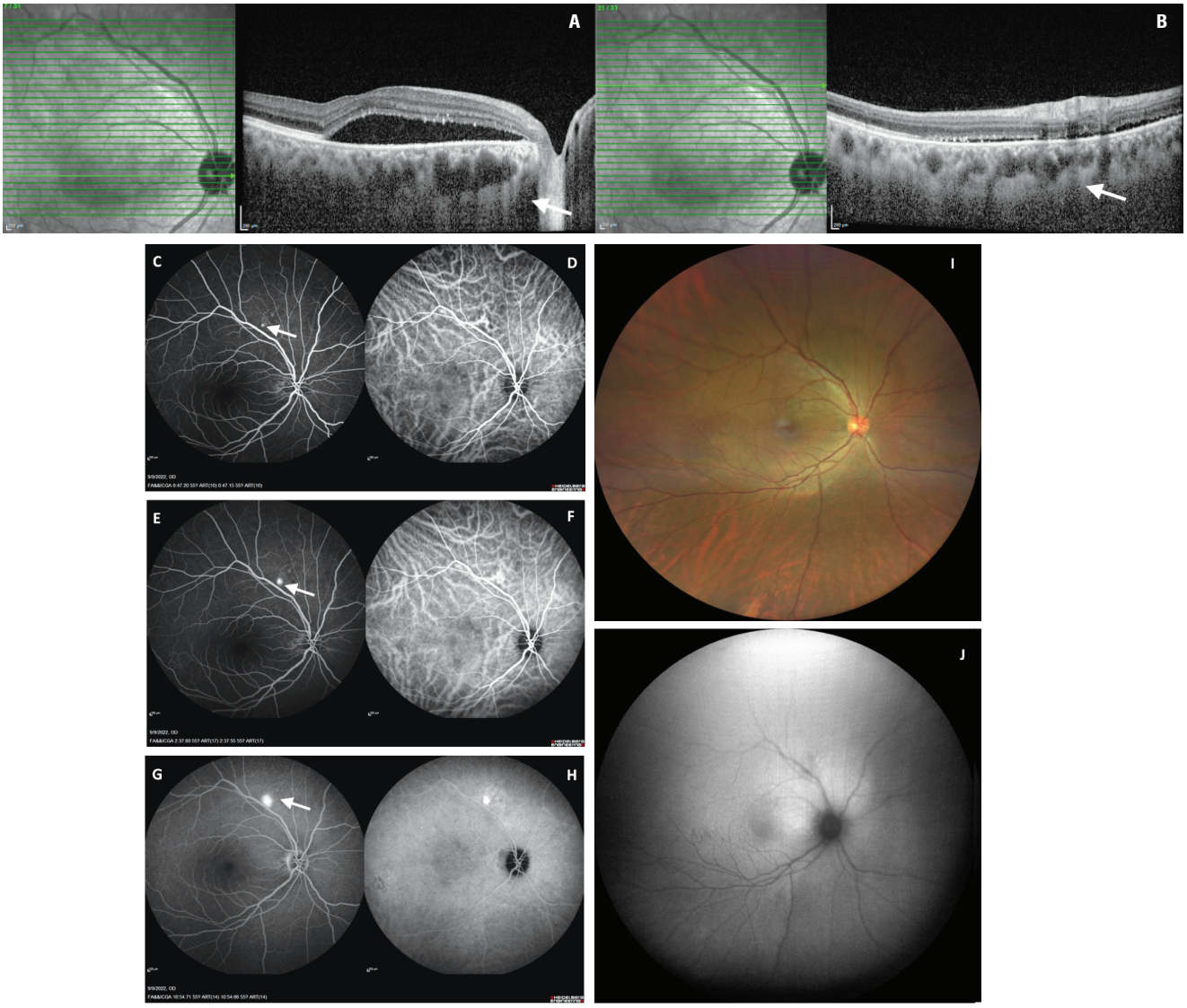

Figure 3 Multimodal imaging of 41-year-old woman with central serous chorioretinopathy (CSCR) on right eye followed up after stopped oral prednisolone. Optical coherence tomography (OCT) in enhanced depth imaging (EDI) mode demonstrated serous subretinal fluid extending from the nasal subfoveal area to the superior macula, approximately four-disc diameters in size, overlying a thickened choroid with pachyvessels (white arrows, Figure 3A, B). Fundus fluorescein angiography (FFA) revealed a focal hyperfluorescent dye leakage in the early phase, which enlarged in the late phase forming an "ink-blot" pattern (white arrows, Figure 3C, E, G). On indocyanine green angiography (ICGA), there is a large pattern as in the fluorescein angiography with additional hyperfluorescent areas of choroidal vascular hyperpermeability (Figure 3 D, F, H). Color fundus photography (Figure 3I) and fundus autofluorescence (Figure 3J) demonstrated hyperautofluorescent changes involving the macula and the superior optic disc region.

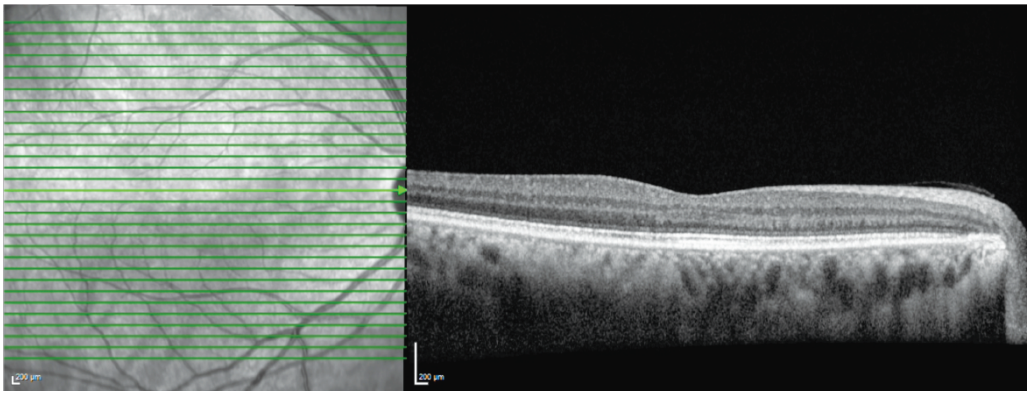

Figure 4 Optical coherence tomography (OCT) of macula shows no serous retinal detachment with insignificant anatomical alternation of junction between photoreceptor and retinal pigment epithelium layer.

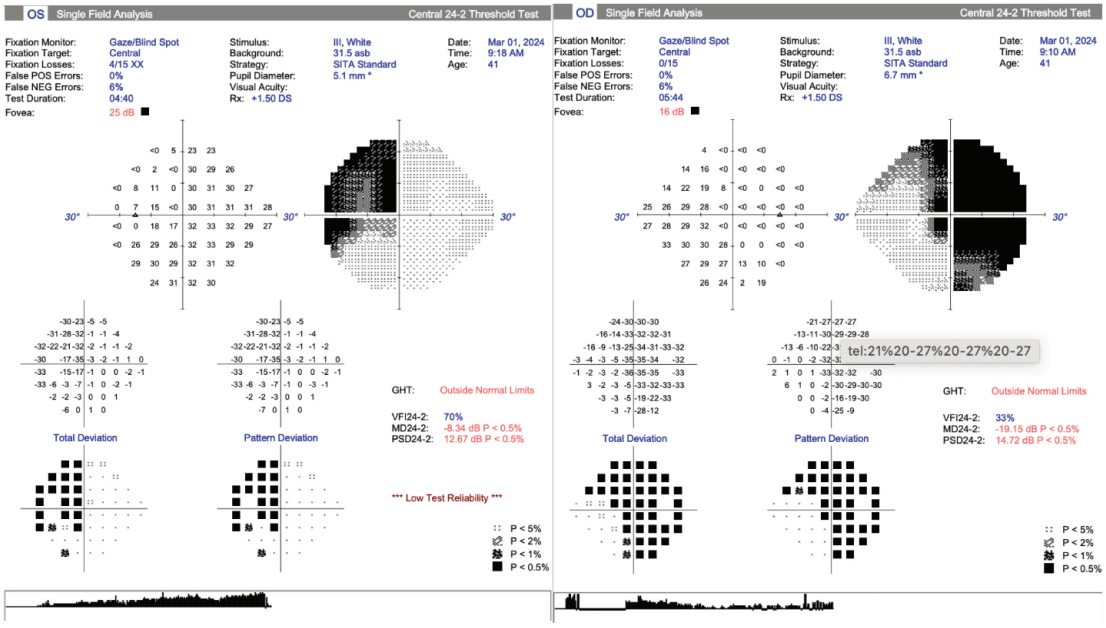

Figure 5 Visual field examination showed significant visual field defect in the right and left eyes as bitemporal hemianopia pattern.

The neuro-ophthalmologist sent the patient for magnetic resonance imaging (MRI) brain and orbit. MRI brain and orbit (Figure 6) revealed 2.4 × 2.2 × 2.0 cm enhancing suprasellar mass exerting pressure on the optic chiasm and bilateral pre-chiasmatic optic nerves. The lesion corresponded to the bitemporal hemianopic field defect observed clinically. Differential diagnoses included pituitary macroadenoma and meningioma. The patient was referred to a neurosurgeon for definitive management. Based on radiologic features, a suprasellar meningioma was suspected. The patient underwent surgical excision of the suprasellar mass, and histopathologic examination confirmed a meningothelial meningioma, WHO grade I. Given the suprasellar location, a dedicated endocrine evaluation was not performed at our center prior to neurosurgical referral, which is a limitation of this report.

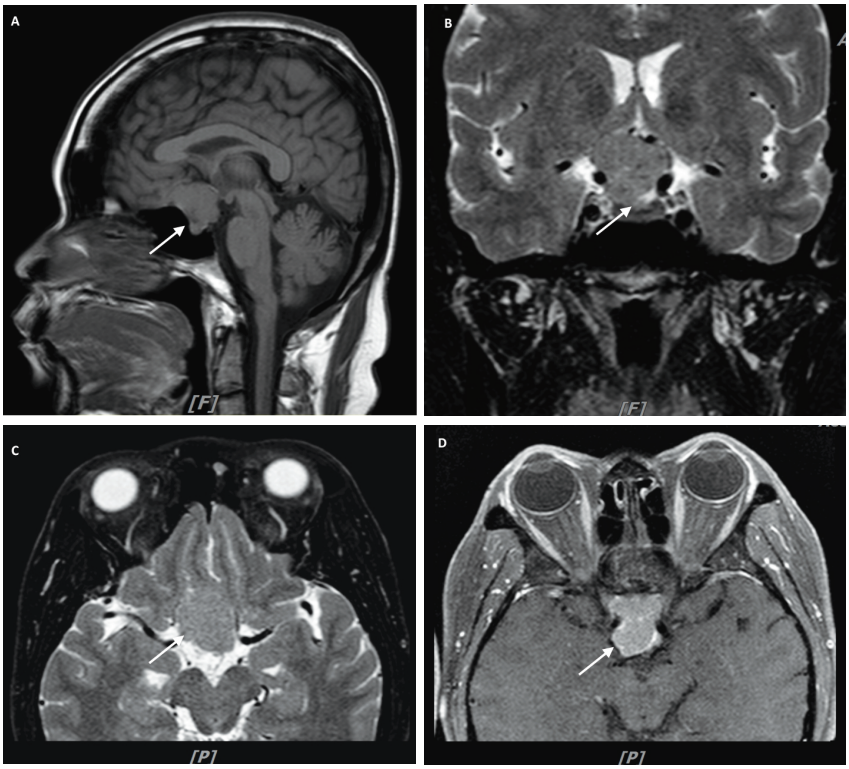

Figure 6 Contrast-enhanced magnetic resonance imaging (MRI) brain and orbit (Figure 6A to D). Sagittal T1 and coronal T2-weighted sequences reveal an enhancing suprasellar lesion, measured about 2.4x2.2x2.0 cm in AP isointense T1 and hyperintense on T2. It superiorly extends to suprasellar region causes pressure effect on optic chiasm and bilateral pre-chiasmatic optic nerves (white arrows, Figure 6A to D).

At 6 months postoperatively, follow-up visual field testing (Figure 7) demonstrated improvement of the bitemporal hemianopic defect in the left eye, with residual deficit in the right eye. Her BCVA improved slightly to counting fingers at 3 feet, with pinhole correction to $20/50^{-2}$ in the right eye, and remained stable at $20/20^{-2}$ in the left eye.

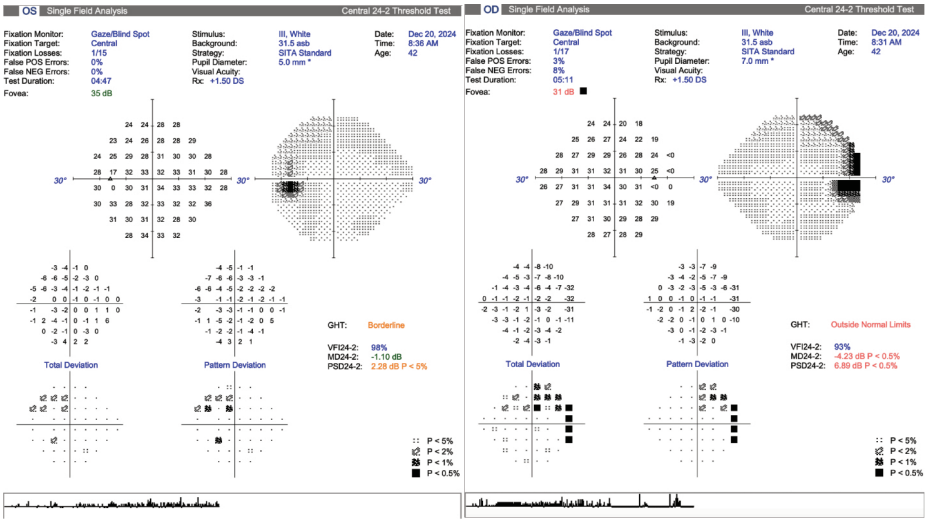

Figure 7 The visual field examination revealed improvement of bitemporal hemianopia visual field defect pattern in left eye and residual in right eye after surgical removal suprasellar meningioma for 6 months.

A clinical timeline is summarized as follows: the patient presented after 3 months of blurred vision with markedly reduced visual acuity in the right eye; systemic prednisolone was discontinued after presentation; 1 month later, subretinal fluid persisted and multimodal angiography confirmed an extrafoveal leakage point; focal laser photocoagulation was performed with gradual anatomical improvement; complete resolution of subretinal fluid was observed approximately 4 months after focal laser, yet visual acuity did not recover; subsequent perimetry demonstrated bitemporal hemianopia, prompting brain and orbital MRI that revealed a suprasellar mass compressing the optic chiasm; the tumor was surgically excised and histopathology confirmed WHO grade I meningothelial meningioma.

Discussion

Suprasellar meningiomas represent a rare subset of intracranial neoplasms that can give rise to a broad range of ophthalmic manifestations. Although visual field defects, optic atrophy, and reduced visual acuity are well-documented clinical findings, presentation in the form of CSCR is exceedingly uncommon.

CSCR is a well-recognized retinal disorder characterized by serous detachment of the neurosensory retina, most commonly involving the macular region. On macular OCT, typical CSCR findings include serous subretinal fluid accumulation with or without pigment epithelial detachment (PED). The subretinal fluid usually forms a dome-shaped elevation of the neurosensory retina, and leakage points are typically located within the macular area, often associated with disruption of the RPE.

In this case, a patient with SLE developed CSCR while receiving a relatively low dose of glucocorticoid (5 mg daily). A previous case report described the development of atypically severe CSCR shortly after corticosteroid initiation, which improved rapidly after dose reduction and the addition of an immunosuppressive agent[30]. In contrast, our patient showed no improvement in subretinal fluid 1 month after discontinuing prednisolone. Nevertheless, focal laser therapy successfully achieved anatomical resolution. Despite this, the patient's central visual acuity in the right eye did not improve and even slightly worsened during 4 months of follow-up. Re-evaluation with visual field testing revealed an unexpected asymmetric bitemporal hemianopic defect respecting the vertical midline, more prominent in the right eye. The defect slightly crossed the midline and involved the fixation point, explaining the persistent central vision loss. These findings prompted neuroimaging to evaluate possible chiasmal involvement.

An additional noteworthy aspect of this case is the atypical CSCR presentation that deviated from its classic pattern. OCT imaging showed subretinal fluid extending from the optic nerve head—an uncommon finding in typical CSCR. Such atypical fluid distribution raised suspicion of other causes, such as optic nerve pathology or a compressive lesion along the visual pathway.

In this patient, systemic corticosteroid exposure represents a major confounding factor and a well-established precipitant of CSCR, including at low systemic doses. In addition, SLE and its treatment may contribute to susceptibility to choroidal/RPE dysfunction. Therefore, the occurrence and persistence of CSCR in this case can be sufficiently explained by steroid exposure and underlying systemic disease, without requiring a mechanistic link to the intracranial tumor.

This case demonstrates that a chiasmal meningioma can coexist with CSCR in a patient with SLE. Meningiomas along the visual pathway usually cause slowly progressive visual decline, often

manifesting as visual field loss. The pattern and rate of visual impairment depend on the tumor's size, growth rate, and proximity to critical visual structures. In our patient, the lesion was centered in the sellar region, and the bitemporal visual field defect indicated compression of the optic chiasm. As the meningioma enlarged, it likely compressed the non-crossing retinal fibers involving the ipsilateral distal optic nerve or proximal optic tract, ultimately affecting central fixation. This mechanism may explain the persistent or slightly worsening blurred vision in the right eye despite the anatomical resolution of CSCR.

Epidemiologic studies have reported an increased risk of central nervous system (CNS) tumors, including meningiomas, in patients with SLE compared with the general population.[31] Although a direct causal relationship between meningioma and CSCR in SLE has not been established, their coexistence may stem from overlapping risk factors. Corticosteroid therapy—commonly used to manage SLE and peritumoral edema in meningioma—is a well-recognized precipitating factor for CSCR.

The association between meningioma and SLE is rare. In a cohort of 546 SLE patients, only three cases of meningioma were identified[31]. More recently, two additional cases of high-grade spheno-orbital meningioma were reported[32]. Meningiomas in SLE may present with various neurological or ocular symptoms, including headache, proptosis, seizures, or psychosis, depending on tumor size and location. Many SLE patients are treated with long-term immunosuppressive agents such as corticosteroids, hydroxychloroquine, cyclosporine, azathioprine, and mycophenolate mofetil. Whether the increased risk of meningioma arises from the autoimmune disease itself, its treatment, or both remains unclear and warrants further study.

Importantly, the patient's presenting visual acuity was markedly reduced and appeared disproportionate to typical acute CSCR, in which visual acuity is often relatively preserved. This atypical severity should raise suspicion for an additional masquerading process along the visual pathway, and it supported a low threshold for formal perimetry and neuro-ophthalmic evaluation when visual function failed to improve despite anatomical resolution.

CSCR and suprasellar meningioma may occur concurrently, and retinal findings can initially obscure a neuro-ophthalmic cause of visual loss. In patients diagnosed with CSCR, neuroimaging is not routinely indicated; however, it should be considered when visual function is disproportionately poor, when symptoms progress, when perimetry suggests a chiasmal/retrobulbar pattern (e.g., defects respecting the vertical meridian), or when visual impairment persists despite apparent resolution of subretinal fluid. This case underscores the importance of integrating retinal imaging with functional testing and multidisciplinary collaboration to avoid delayed recognition of compressive optic pathway lesions. Given the inherent limitations of a single case report, no causal inference regarding an association between CSCR and meningioma can be made, and the concurrence in this patient is best interpreted as coincidental.

References

1. Kaye R, Chandra S, Sheth J, Boon CJF, Sivaprasad S, Lotery A. Central serous chorioretinopathy: an update on risk factors, pathophysiology and imaging modalities. Prog Retin Eye Res. 2020;79:100865. doi:10.1016/j.preteyeres.2020.100865
2. Spaide RF, Cheung CMG, Matsumoto H, et al. Venous overload choroidopathy: a hypothetical framework for central serous chorioretinopathy and allied disorders. Prog Retin Eye Res. 2022;86:100973. doi:10.1016/j.preteyeres.2021.100973

3. Warrow DJ, Hoang QV, Freund KB. Pachychoroid pigment epitheliopathy. Retina. 2013;33(8):1659-72. doi:10.1097/IAE.0b013e3182953df4
4. Spaide RF, Campeas L, Haas A, et al. Central serous chorioretinopathy in younger and older adults. Ophthalmology.1996;103(12):2070-9.
5. Kitzmann AS, Pulido JS, Diehl NN, Hodge DO, Burke JP. The incidence of central serous chorioretinopathy in Olmsted County, Minnesota, 1980–2002. Ophthalmology. 2008;115(1):169-73. doi:10.1016/j.ophtha.2007.02.032
6. Liew G, Quin G, Gillies M, Fraser-Bell S. Central serous chorioretinopathy: a review of epidemiology and pathophysiology. Clin Experiment Ophthalmol. 2013;41(2):201-14. doi:10.1111/j.1442-9071.2012.02848.x
7. Carvalho-Recchia CA, Yannuzzi LA, Negrão S, et al. Corticosteroids and central serous chorioretinopathy. Ophthalmology. 2002;109(10):1834-7.
8. Nicholson B, Noble J, Forooghian F, Meyerle C. Central serous chorioretinopathy: update on pathophysiology and treatment. Surv Ophthalmol. 2013;58(2):103-26. doi:10.1016/j.survophthal.2012.07.004
9. Tsai DC, Chen SJ, Huang CC, et al. Risk of central serous chorioretinopathy in adults prescribed oral corticosteroids: a population-based study in Taiwan. Retina. 2014;34(9):1867-74. doi:10.1097/IAE.0000000000000159
10. Liu B, Deng T, Zhang J. Risk factors for central serous chorioretinopathy: a systematic review and meta-analysis. Retina. 2016;36(1):9-19. doi:10.1097/IAE.0000000000000837
11. Araki T, Ishikawa H, Iwahashi C, et al. Central serous chorioretinopathy with and without steroids: a multicenter survey. PLoS One. 2019;14(2):e0213110. doi:10.1371/journal.pone.0213110
12. Tittl MK, Spaide RF, Wong D, et al. Systemic findings associated with central serous chorioretinopathy. Am J Ophthalmol. 1999;128(1):63-8. doi:10.1016/S0002-9394(99)00075-6
13. Haimovici R, Koh S, Gagnon DR, Lehrfeld T, Wellik S. Risk factors for central serous chorioretinopathy: a case-control study. Ophthalmology. 2004;111(2):244-9.
14. Ge G, Zhang Y, Zhang Y, Xu Z, Zhang M. Corticosteroid usage and central serous chorioretinopathy: a meta-analysis. Graefes Arch Clin Exp Ophthalmol. 2020;258(1):71-7. doi:10.1007/s00417-019-04486-w
15. Nudleman E, Witmer MT, Kiss S, Williams GA, Wolfe JD. Central serous chorioretinopathy in patients receiving exogenous testosterone therapy. Retina. 2014;34(10):2128-32. doi:10.1097/IAE.0000000000000198
16. van Dijk EH, Nijhoff MF, de Jong EK, et al. Central serous chorioretinopathy in primary hyperaldosteronism. Graefes Arch Clin Exp Ophthalmol. 2016;254(10):2033-2042.
17. Çiloğlu E, Unal F, Doğan NC. The relationship between central serous chorioretinopathy, choroidal thickness, and serum hormone levels. Graefes Arch Clin Exp Ophthalmol. 2018;256(6):1111-6.
18. Jiang MS, Xu XL, Yang T, Li F, Zhang XD. Comparison of choroidal thickness in preeclamptic, healthy pregnant, and nonpregnant women: a systematic review and meta-analysis. Ophthalmic Res. 2019;62(1):1-10. doi:10.1159/000499916
19. Karadağ MF. A new potential risk factor for central serous chorioretinopathy: blood pressure variability. Eye.2021;35(8):2190-5. doi:10.1038/s41433-020-01222-1
20. van Dijk EHC, Soonawala D, Rooth V, et al. Spectrum of retinal abnormalities in renal transplant patients using chronic low-dose steroids. Graefes Arch Clin Exp Ophthalmol. 2017;255(12):2443-9. doi:10.1007/s00417-017-3823-6
21. Fawzi AA, Holland GN, Kreiger AE, Heckenlively JR, Arroyo JG, Cunningham ET Jr. Central serous chorioretinopathy after solid organ transplantation. Ophthalmology. 2006;113(5):805-13.e5.
22. Yannuzzi LA. Type-A behavior and central serous chorioretinopathy. Trans Am Ophthalmol Soc. 1986;84:799-845.
23. Miki A, Kondo N, Yanagisawa S, Bessho H, Honda S, Negi A. Common variants in the complement factor H gene confer genetic susceptibility to central serous chorioretinopathy. Ophthalmology. 2014;121(5):1067-72.
24. Vance SK, Imamura Y, Freund KB. The effects of

sildenafil citrate on choroidal thickness as determined by enhanced depth imaging optical coherence tomography. Retina. 2011;31(2):332-5.
25. Pan CK, Vail D, Bhattacharya J, Cao M, Mruthyunjaya P. The effect of obstructive sleep apnea on absolute risk of central serous chorioretinopathy. Am J Ophthalmol. 2020;218:148-55.
26. Ji Y, Li M, Zhang X, Peng Y, Wen F. Poor sleep quality is a risk factor for central serous chorioretinopathy. J Ophthalmol. 2018;2018:9450297. doi:10.1155/2018/9450297
27. Tien PT, Lai CY, Lin CJ, et al. Increased risk of central serous chorioretinopathy among patients with nonorganic sleep disturbance. J Ophthalmol. 2020;2020:1712503. doi:10.1155/2020/1712503
28. Ersöz MG, Arf S, Hocaoglu M, Sayman Muslubas I, Karacorlu M. Patient characteristics and risk factors for central serous chorioretinopathy: an analysis of 811 patients. Br J Ophthalmol. 2019;103(6):725-9.
29. Daruich A, Matet A, Dirani A, et al. Central serous chorioretinopathy: recent findings and new physiopathologic hypotheses. Prog Retin Eye Res. 2015;48:82-118. doi:10.1016/j.preteyeres.2015.05.003
30. Sato H, Takeda A, Tanaka Y, Otsuka N, Koike T. Atypical severe central serous chorioretinopathy in a patient with systemic lupus erythematosus improved with rapid reduction of glucocorticoid. Mod Rheumatol. 2013;23(1):172-4.
31. Castellino G, Govoni M, Padovan M, Rizzo N, Bosi S, Trotta F. Meningioma and systemic lupus erythematosus: a matter of pure coincidence? Lupus. 2009;18(7):650-4.
32. Abdulqader SB, Al-Taie AH, Al-Mahdawi AM, Al-Azzawi MA, Al-Attar ZM, Al-Obaidi SM, et al. High-grade spheno-orbital meningioma in patients with systemic lupus erythematosus: two case reports and literature review. Surg Neurol Int. 2020;11:367.

ภาวะจอตาบวมน้ำที่พบร่วมกับเนื้องอกของเยื่อหุ้มสมอง : รายงานผู้ป่วย





Thikumporn Chanpoo, MD[1*]
ทิฆัมพร จันทร์ภู่, พ.บ.[1*]

Poramaet Laowanapiban, PhD, MD[2]
ปรเมศร์ เลาวณาภิบาล, พ.บ.[2]

Chutiporn Kiratikajonchai, MD[3]
ชุติภรณ์ กีรติขจรชัย, พ.บ.[3]

บทคัดย่อ:

วัตถุประสงค์: เพื่อรายงานกรณีผู้ป่วยที่มีเนื้องอกของเยื่อหุ้มสมองชั้นเหนือเซลล่า (Suprasellar meningioma) ซึ่งมีลักษณะทางคลินิกคล้ายกับภาวะจอตาบวมจากน้ำรั่ว (Central serous chorioretinopathy) และแสดงให้เห็นถึงความสำคัญของการตรวจหาความผิดปกติในสมอง เมื่อการมองเห็นไม่ดีขึ้นภายหลังการรักษาโรคของจอตา

รายงานผู้ป่วย: ผู้ป่วยหญิงอายุ 41 ปี มาพบแพทย์ด้วยอาการตาขวามัวมา 3 เดือน อาการตามัวค่อยๆ เป็นมากขึ้น และมีการสูญเสียการมองเห็นส่วนกลางโดยไม่มีอาการปวดตา ตรวจร่างกายทางจักษุวิทยาและการตรวจโดยการถ่ายภาพตัดขวางจอตา (OCT) พบว่ามีน้ำใต้ต่อจอตาบริเวณจุดรับภาพชัดของตาขวา ซึ่งเข้าได้กับภาวะจอตาบวมจากน้ำรั่ว (CSCR) ผลการตรวจจอตาด้วยการฉีดสารเรืองแสงฟลูออเรสซีนและอินโดไซยานีนกรีน (FFA ICGA) แสดงให้เห็นจุดรั่วซึมของน้ำนอกบริเวณจุดรับภาพชัด ผู้ป่วยจึงได้รับการรักษาโดยการใช้เลเซอร์โฟโตโคแอกกูเลชั่น ภายหลังการรักษาผู้ป่วยยังคงมีการมองเห็นแย่ลง ผลการตรวจลานสายตาพบลักษณะภาวะลานสายตาบกพร่องครึ่งซีกด้านนอกทั้งสองข้าง (Bitemporal hemianopia) ทำให้สงสัยรอยโรคในเส้นทางการมองเห็น (visual pathway) ผู้ป่วยจึงได้รับการตรวจคลื่นแม่เหล็กไฟฟ้า (MRI) บริเวณสมองและเบ้าตา พบก้อนเนื้องอกของเยื่อหุ้มสมองบริเวณเหนือเซลล่าซึ่งกดเบียดเส้นประสาทตา สุดท้ายผู้ป่วยได้รับการผ่าตัด และผลการตรวจชิ้นเนื้อเป็นเนื้องอกเยื่อหุ้มสมอง

สรุป: ประเด็นสำคัญของกรณีศึกษาผู้ป่วยรายนี้ คือ โรคเนื้องอกในสมองอาจมีอาการแสดงคล้ายหรืออาจเกิดร่วมกันกับความผิดปกติทางจอตา ซึ่งทำให้การวินิจฉัยทำได้ยากขึ้นหรือวินิจฉัยได้ล่าช้า ในผู้ป่วยที่ยังคงมีการสูญเสียการมองเห็นแม้ว่าภาวะจอตาบวมจากน้ำรั่วดีขึ้นแล้ว ควรนึกถึงโรคหรือภาวะอื่น การตรวจภาพทางระบบประสาทโดยเฉพาะการทำ MRI สมองและเบ้าตาจะช่วยให้สามารถตรวจพบรอยโรคในสมองและนำไปสู่การรักษาที่รวดเร็วยิ่งขึ้น

คำสำคัญ: ภาวะจอตาบวมจากน้ำรั่ว, เนื้องอกเยื่อหุ้มสมองชั้นเหนือเซลล่า, โรคลูปัส

[1] หน่วยจอตาและวุ้นตา ภาควิชาจักษุวิทยา โรงพยาบาลเมตตาประชารักษ์ (วัดไร่ขิง) จังหวัดนครปฐม ประเทศไทย
[2] หน่วยจักษุประสาทวิทยา ภาควิชาจักษุวิทยา โรงพยาบาลเมตตาประชารักษ์ (วัดไร่ขิง) จังหวัดนครปฐม ประเทศไทย
[3] หน่วยรังสีวิทยา ภาควิชารังสีวิทยา โรงพยาบาลเมตตาประชารักษ์ (วัดไร่ขิง) จังหวัดนครปฐม ประเทศไทย

Footnotes and Financial Disclosures
Originally receive: 25/11/2025
Final revision: 23/2/2026
Accepted: 13/3/2026
Corresponding author: **Thikumporn Chanpoo, MD**
Vitreoretinal unit, Department of Ophthalmology, Mettapracharak (Watraikhing) Hospital, Nakhon Pathom, Thailand.
Tel : +6634388700 Email : fernthikumporn@gmail.com
Financial Disclosure(s): The authors report no conflicts of interest in this work.