Thai J Ophthalmol 2026;40(1):1-13.

Original Article/นิพนธ์ต้นฉบับ

A Real-World Evaluation of Optical Coherence Tomography Angiography and Clinical Risk Factors for Mild Non-Proliferative Diabetic Retinopathy

Soramon Chaichan, MD*, Tanapat Ratanapakorn, MD, Suthasinee Sinawat, MD, Yosanan Yospaiboon, MD

Abstract

Objectives: To evaluate the clinical utility of optical coherence tomography angiography (OCTA) metrics for detecting mild non-proliferative diabetic retinopathy (NPDR) and to identify clinical risk factors associated with mild NPDR.

Methods: This prospective cross-sectional study included patients with type 2 diabetes mellitus (DM). OCTA metrics—including superficial and deep capillary plexus vessel densities (SVD and DVD), ganglion cell complex (GCC) thickness, and foveal avascular zone (FAZ) area—were measured in the parafoveal region using the Optovue Solix OCTA system. Logistic regression analysis adjusted for potential confounders was performed to evaluate associations between OCTA metrics, clinical risk factors, and mild NPDR.

Results: A total of 236 patients were enrolled, including 118 patients without DR and 118 with mild non-proliferative diabetic retinopathy (NPDR). SVD was significantly lower in the mild NPDR group compared to the no DR group (48.37 ± 2.25% vs. 49.22 ± 2.82%, $p = 0.011$), whereas other OCTA parameters showed no significant differences between groups. In adjusted logistic regression analyses, the presence of mild NPDR was significantly associated with SVD ($p < 0.001$), DVD ($p = 0.003$), and age ($p = 0.001$).

Conclusions: Although SVD was statistically reduced in patients with mild NPDR, the magnitude of difference was not clinically meaningful. Nonetheless, vessel density metrics and age were significantly associated with mild NPDR. While OCTA provides valuable quantitative assessment of retinal microvasculature, its utility as a routine screening tool for mild NPDR remains limited. Clinical fundoscopy continues to be the primary method for diagnosing mild NPDR.

Keywords: Optical coherence tomography angiography, Superficial vessel density, Deep vessel density, Non-proliferative diabetic retinopathy, Hemoglobin A1c (HbA1c), Diabetes duration

KKU Eye Center, Department of Ophthalmology, Faculty of Medicine, Khon Kaen University

Introduction

Diabetic retinopathy (DR) is a sight-threatening global health challenge, affecting approximately one-third of diabetic patients worldwide.[1] Optical coherence tomography angiography (OCTA) has emerged as a transformative, non-invasive imaging modality that enhances the understanding and management of DR.[2] OCTA provides detailed visualization of the retinal and choroidal microvasculature, enabling the detection of early microvascular changes in the parafoveal capillary plexus of diabetic patients. Reduced vessel density of the parafoveal capillary plexus is strongly associated with the severity of DR, reflecting underlying microvascular damage and ischemia.[3-5] Most previous studies have compared OCTA metrics between diabetic patients with or without retinopathy and healthy participants, consistently finding that the diabetic group exhibits a significant decrease in vessel density in both the superficial and deep capillary plexus compared to the control group.[6-8]

In real-world practice, however, DR screenings are typically conducted on patients already diagnosed with diabetes mellitus (DM), making the comparison to healthy individuals more relevant in research than in clinical settings. To date, in Thailand, there is no previous study that has directly compared vessel density between diabetic patients without DR and those with mild NPDR — a clinically relevant comparison that reflects actual screening practice. This knowledge gap underscores the need to evaluate whether OCTA metrics can distinguish between these two groups in a real-world setting.

This study aims to explore the true clinical utility of OCTA metrics, specifically superficial and deep capillary plexus vessel density (SVD and DVD), in detecting mild NPDR. The focus is on diabetic patients without DR and those with mild non-proliferative diabetic retinopathy (NPDR), examining whether differences in SVD and DVD measured by OCTA can distinguish between these two groups based on conventional fundus findings. Furthermore, we seek to assess the practical benefit of clinical risk factors and OCTA in routine clinical practice. Therefore, the objective of the study is to determine whether OCTA metrics can predict the presence of mild NPDR in diabetic patients. A secondary objective is to identify factors associated with the presence of mild NPDR.

Patients and Methods

This prospective cross-sectional study was performed in accordance with the tenets of the Declaration of Helsinki, and approved by the Khon Kaen University Ethic Committee for Human Research. Patients were recruited for ophthalmological examination and OCTA imaging between April of 2023 and April of 2024 at the outpatient department of KKU Eye Center, Khon Kaen University, Thailand. We obtained signed informed consent from each patient before examination and imaging.

Participants

Patients were eligible if they had a diagnosis of type 2 DM. One side of the eye, primarily right, was selected from each participant to avoid inter-eye correlation. Exclusion criteria were eyes with other macular or retinal diseases, history of previous ocular surgery, macular laser or have been receiving intravitreal therapies. We also excluded eyes with significant media opacities to avoid compromising OCTA image quality. We only included eyes with an OCTA scan quality of 7 (out of 10) or higher. Those who were unable to provide blood collection for hemoglobin A1c (HbA1c) level analysis were also excluded.

In this study, the level of DR included DM without DR and mild NPDR. Moderate, severe NPDR and PDR were not included in the study because our main

emphasis was on the initial microvascular alterations observed during the early stages of DR development. Color fundus photographs were taken at the same visit as OCTA imaging and were classified based on International Clinical Diabetic Retinopathy severity scale.

Mild NPDR was defined as the earliest stage of DR, characterized by the presence of microaneurysms — tiny areas of balloon-like swelling in the retina's blood vessels — without other DR lesions, based on the International Clinical Diabetic Retinopathy (ICDR) severity scale.

DR grading was performed based on color fundus photography by the primary investigator, a resident physician in ophthalmology, with confirmation by retinal specialists. Fundus photographs were graded independently, with the primary investigator masked to patients' clinical data during classification.

Since no previous study has compared vessel density between DM without DR and mild NPDR, we conducted a pilot measurement with 20 patients in each group. The superficial vessel density was 49.13 ± 3.05% in the No DR group and 48.03 ± 2.98% in the mild NPDR group. Based on a significance level of 0.05, a power of 80%, and a two-sided test, the required sample size per group was calculated to be 118 eyes.

OCTA Imaging

We used the Optovue Solix OCTA system (Optovue, Inc., Fremont, CA, USA) to capture 3 × 3 mm OCTA images of a parafoveal region centered on the fovea. The parafoveal region was defined as an annulus centered on the fovea, with inner and outer ring diameters of 1 mm and 3 mm, respectively. Vascular layer segmentation was performed using the automated AngioVue Analytics software. Superficial capillary plexus vessel density (SVD) was defined as the capillary density measured in the layer from the internal limiting membrane to the inner plexiform layer, while deep capillary plexus vessel density (DVD) was measured from the inner plexiform layer to the outer plexiform layer. Vessel density was calculated as the area of vessel pixels divided by the total area of interest and reported as a percentage. SVD and DVD were automatically computed by the software, alongside other metrics such as foveal avascular zone (FAZ) area and macular ganglion cell complex (GCC) thickness. All OCTA images were reviewed individually by the primary investigator for segmentation errors and image artifacts. If a decentered scan or segmentation error was identified, manual correction was performed using the built-in editing tools of the AngioVue Analytics software, including recentering of the scanning grid, with repeat scanning performed when necessary to achieve acceptable image quality. Only images meeting a minimum quality score of 7 out of 10 were included in the analysis. Each eye was scanned once provided the quality threshold was met; repeat scans were performed solely to correct image quality or segmentation issues.

Statistical analysis

Data were analyzed using Stata Statistics Software: Release 18 ((StataCorp LLC, College Station, TX). Continuous variables were present as mean and standard deviation, while categorical variables were present as number and percentage. Variables exhibiting non-normal distribution, as assessed by the Shapiro-Wilk test, were reported as median and interquartile range (IQR) and compared between groups using the Mann-Whitney U test. Receiver operating characteristic (ROC) curve analysis was performed to evaluate the discriminative ability of SVD for detecting mild NPDR, with the optimal cutoff determined by the Youden Index. To analyze the differences between patients with no DR and those with mild NPDR, we used independent samples *t*-tests for continuous variables

and Chi-square test for categorical variables. Binary logistic regression was used to investigate the factors associated with the presence of mild NPDR. The factors analyzed included age, HbA1c levels, SVD, DVD, GCC thickness, FAZ area, duration of DM, gender, hypertension, and dyslipidemia. The logistic regression analysis generated odds ratios (ORs) and confidence intervals (CIs) for both the crude and adjusted models. We first examined the crude odds ratios to determine the initial association of each factor with mild NPDR. Subsequently, we adjusted for potential confounders to compute adjusted odds ratios, which provided a more refined understanding of each factor's effect while controlling for other variables. Statistical significance was set at $p < 0.05$.

Results

A total of 236 patients with DM were enrolled, consisting of 148 females (62.71%) and 88 males (37.29%). The mean age of the patients was 55.12 ± 9.02 years and the mean hemoglobin A1c (HbA1c) level was 7.36 ± 1.41%. Among the 236 patients, 118 (50.00%) had no DR, while 118 (50.00%) had mild NPDR, based on the ICDR severity scale. The median duration of DM was 60 (IQR, 60-84) months in the no DR group and 60 (IQR, 27-120) months in the mild NPDR group. Additional demographic details are provided in Table 1. OCTA metrics, including SVD, DVD, GCC thickness, and FAZ area, are summarized in Table 2.

Table 1 Demographic data of patients in the study

Demographic Data	Total (n = 236)	No DR (n = 118)	Mild NPDR (n = 118)	*P*-value*
Age (years), mean ± SD	55.12 ± 9.02	57.17 ± 9.26	53.07 ± 8.31	< 0.001
HbA1c (%), mean ± SD	7.36 ± 1.41	7.20 ± 1.12	7.51 ± 1.64	0.092
Duration (months), median (IQR)†	60 (36, 96)	60 (60, 84)	60 (27, 120)	0.659
Gender: female, n (%)	148 (62.71)	73 (61.86)	75 (63.56)	0.893
Hypertension: yes, n (%)	75 (31.78)	35 (29.66)	40 (33.90)	0.576
Dyslipidemia: yes, n (%)	73 (30.93)	36 (30.51)	37 (31.36)	1

† Duration reported as median (IQR) due to non-normal distribution.

* Independent t-test used for continuous variables; Chi-square test for categorical variables; Mann-Whitney U test for duration.

Abbreviation: HbA1c = hemoglobin A1c, IQR = interquartile range, SD = standard deviation

Table 2 Optical coherence tomography angiography (OCTA) findings of patients in the study (n = 236)

Collected Data	Mean ± SD	Min	Max
SVD (%)	48.79 ± 2.58	39.5	55.4
DVD (%)	51.60 ± 3.06	37.4	56
GCC thickness (μm)	103.01 ± 9.90	59	139
FAZ area (mm^2)	0.32 ± 0.12	0.08	0.7

Abbreviation: DVD = deep capillary complex vessel density, FAZ = foveal avascular zone area, GCC = ganglion cell complex thickness, SD = standard deviation, SVD = superficial capillary complex vessel density.

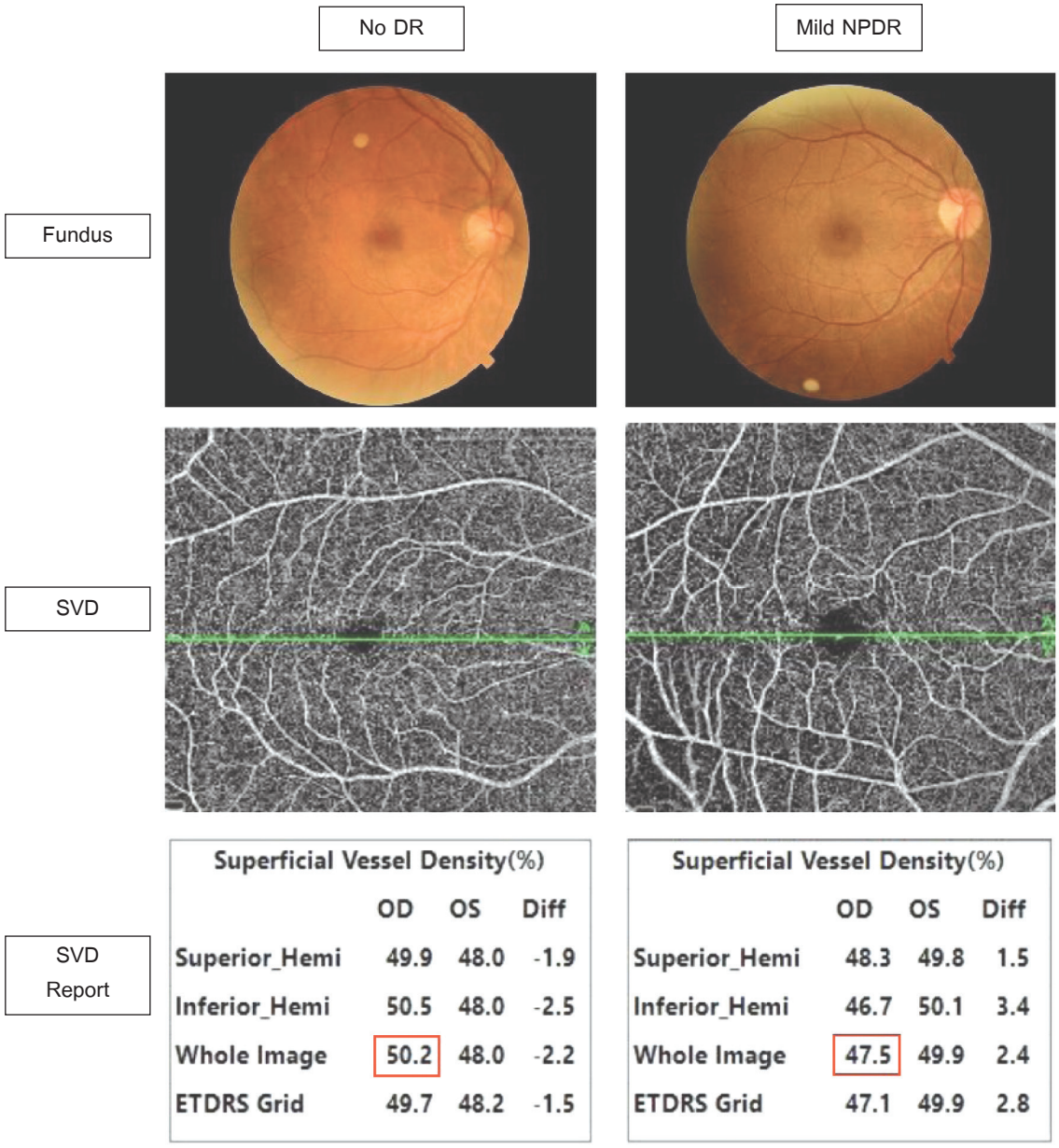

Figure 1 Demonstrating differences in superficial vessel density (SVD) between patients with no diabetic retinopathy (No DR) and those with mild non-proliferative diabetic retinopathy (Mild NPDR)

Regarding OCTA metrics, SVD was significantly reduced in the mild NPDR group compared to the no DR group (mean ± SD: 48.37 ± 2.25% vs. 49.22 ± 2.82%, $p = 0.011$) as shown in Figure 1. Although DVD was slightly higher in the mild NPDR group, this difference was not statistically significant (mean ± SD: 51.69 ± 3.01% vs. 51.51 ± 3.11%, $p = 0.644$). Similarly, no significant differences were observed in GCC thickness (mean ± SD: 102.62 ± 11.45 μm vs. 103.40 ± 8.09 μm, $p = 0.545$) or FAZ area (mean ± SD: 0.30 ± 0.12 mm² vs. 0.33 ± 0.12 mm², $p = 0.075$), as detailed in Table 3.

For clinical data, a significant difference in age was observed between the two groups: patients with no DR were significantly older (mean ± SD: 57.17 ± 9.26 years) compared to those with mild NPDR (mean ± SD: 53.07 ± 8.31 years, $p < 0.001$). Although the mild NPDR group had a slightly higher mean ± SD HbA1c level, this difference did not reach statistical significance (7.51 ± 1.64% vs. 7.20 ± 1.12%, $p = 0.092$). No significant difference in the median duration of DM was observed between groups ($p = 0.659$), as detailed in Table 3.

Table 3 Comparison between diabetics with no diabetic retinopathy (DR) and mild non-proliferative diabetic retinopathy (NPDR) groups

Variables	No DR (n = 118)	Mild NPDR (n = 118)	Mean difference (95% CI)	*P*-value
SVD (%), mean ± SD	49.22 ± 2.82 (48.70, 49.73)	48.37 ± 2.25 (47.96, 48.78)	0.85 (0.19, 1.50)	0.011
DVD (%), mean ± SD	51.51 ± 3.11 (50.94, 52.08)	51.69 ± 3.01 (51.15, 52.25)	-0.18 (-0.97, 0.60)	0.644
GCC thickness (μm), mean ± SD	103.40 ± 8.09 (101.93, 104.87)	102.62 ± 11.45 (100.53, 104.71)	0.78 (-1.76, 3.33)	0.545
FAZ area (mm²), mean ± SD	0.33 ± 0.12 (0.31, 0.36)	0.30 ± 0.12 (0.28, 0.33)	0.03 (0.0002, 0.061)	0.075
Age (year), mean ± SD	57.17 ± 9.26 (55.48, 58.86)	53.07 ± 8.31 (51.55, 54.58)	4.10 (1.85, 6.36)	< 0.001
HbA1c (%), mean ± SD	7.20 ± 1.12 (6.99, 7.41)	7.51 ± 1.64 (7.21, 7.81)	-0.31 (-0.67, 0.05)	0.092
Duration (month), median (IQR)†	60 (60–84)	60 (27–120)	—	0.659
Gender: female, n (%)	73 (61.86%)	75 (63.56%)		0.788
Hypertension: yes, n (%)	35 (29.66%)	40 (33.90%)		0.485
Dyslipidemia: yes, n (%)	36 (30.51%)	37 (31.36%)		0.888

† Mann-Whitney U test was used for diabetes duration due to non-normal distribution.

Abbreviation: CI = confidence interval, DVD = deep capillary complex vessel density, FAZ = foveal avascular zone area, GCC = ganglion cell complex thickness, HbA1c = hemoglobin A1c, IQR = interquartile range, SVD = superficial capillary complex vessel density, SD = standard deviation

Binary logistic regression was performed to assess both continuous and categorical factors, including crude and adjusted ORs. SVD was significantly associated with DR in both crude and adjusted models (crude OR: 0.88, 95% CI: 0.79, 0.97, $p = 0.013$; adjusted OR: 0.70, 95% CI: 0.58–0.83, $p < 0.001$), indicating that lower SVD was associated with an increased risk of DR. DVD was significantly associated with DR in the adjusted model (adjusted OR: 1.24, 95% CI: 1.07, 1.43; $p = 0.003$), demonstrating that higher DVD was associated with an elevated risk of DR. Age was significantly associated with DR in both models (crude OR: 0.95,

95% CI: 0.92, 0.98; $p = 0.001$; adjusted OR: 0.94, 95% CI: 0.91, 0.98; $p = 0.001$), suggesting that older age was associated with a lower risk of DR. Other factors, including GCC thickness, FAZ area, HbA1c, diabetes duration, gender, hypertension, and dyslipidemia, did not show significant associations with DR in the adjusted model, as outlined in Table 4.

To evaluate the screening performance of SVD for detecting mild NPDR, ROC analysis was performed. SVD yielded an AUC of 0.601 (95% CI: 0.524–0.673), indicating poor discriminative ability. At the optimal cutoff of 50.90%, determined by the Youden Index, SVD demonstrated a sensitivity of 28.8% and a specificity of 93.2%. These findings further support the limited utility of SVD as a standalone screening tool for mild NPDR in clinical practice.

Table 4 Factors associated with diabetic retinopathy (DR) analyzed by binary logistic regression

Factors	Crude odds ratio (95% CI)	*P*-value	Adjusted odds ratio (95% CI)	*P*-value
SVD (%)	0.88 (0.79, 0.97)	0.013	0.70 (0.58, 0.83)	< 0.001
DVD (%)	1.02 (0.94, 1.11)	0.642	1.24 (1.07, 1.43)	0.003
GCC thickness (μm)	0.99 (0.97, 1.02)	0.543	0.99 (0.96, 1.03)	0.778
FAZ Area (mm^2)	0.11 (0.01, 1.00)	0.050	0.23 (0.02, 2.77)	0.245
Age (year)	0.95 (0.92, 0.98)	0.001	0.94 (0.91, 0.98)	0.001
HbA1c (%)	1.18 (0.97, 1.43)	0.098	1.13 (0.91, 1.39)	0.274
Duration (month)	1.00 (0.99, 1.01)	0.300	1.00 (0.99, 1.01)	0.058
Gender	0.93 (0.55, 1.58)	0.788	1.00 (0.55, 1.79)	0.987
Hypertension	1.22 (0.70, 2.11)	0.485	1.26 (0.63, 2.52)	0.541
Dyslipidemia	1.04 (0.60, 1.81)	0.888	1.05 (0.52, 2.11)	0.883

Abbreviation: CI = confidence interval, DVD = deep capillary complex vessel density, FAZ = foveal avascular zone area, GCC = ganglion cell complex thickness, HbA1c = hemoglobin A1c, SVD = superficial capillary complex vessel density

Discussion

To address our primary objective of determining whether OCTA metrics can distinguish between mild NPDR and no DR group in a real-world setting, our results showed a significant reduction in SVD in the mild NPDR group. However, no significant differences were observed in other OCTA metrics or HbA1c levels between these two groups.

Previous studies have compared vessel density between healthy individuals and those with DR[6-8], showing more pronounced differences due to the marked contrast between healthy and diabetic-compromised microvasculature. In contrast, our study focused on diabetic patients with no DR and those with mild NPDR, an early stage near the transition from no DR to DR. While the differences in vessel density at this stage were subtle, our findings still demonstrated a significant reduction in SVD in the mild NPDR group. However, the approximately 0.85% difference in SVD between the groups, though statistically significant, was clinically subtle.

For the secondary objective, our study identified

three significant factors associated with the presence of mild NPDR: age, SVD and DVD. Contrary to the conventional understanding that advancing age increases DR risk[9,10], we observed a negative association between age and the risk of DR. Typically, older age is associated with a longer duration of DM, which is known to increase DR risk.[1,11,12] A cross-sectional retrospective study from Thailand found that DR prevalence peaked in individuals aged 50–59.9 years, rising steadily until age 60, after which it declined.[11] The discrepancy in our findings may be due to the age distribution of our cohort. Differences in diabetes management strategies and methodological approaches may also contribute to the variation between our study and previous research.

In terms of SVD, we found that lower density was associated with an increased risk of mild NPDR. This is consistent with findings by Mokrane et al.[4] and Li et al.[5], which demonstrated that reduced SVD correlated with more severe DR and might serve as an early marker of retinal microvascular changes. Changes in SVD are likely more reliable than those in DVD, as SVD is less prone to noise and projection artifacts, even when artifact-removal algorithms are applied.[13] Moreover, our study showed that higher DVD was associated with an elevated risk of DR, a result that contrasts with findings from Kim et al.[6] and Ashraf et al.[7], which linked decreased DVD to more advanced DR stages. This discrepancy may be due to differences in patient populations, imaging techniques, or the stage of DR in the studied cohorts.

FAZ area and GCC thickness were not associated with DR development, which aligns with recent studies indicating that these measures may not directly influence DR incidence. Liu et al. found no significant difference in FAZ areas between individuals with mild DR and control subjects, suggesting that while FAZ alterations may occur, they do not significantly correlate with DR development.[14] Similarly, Salvi et al. reported that while GCC thickness was affected in patients with type 2 DM, it reflected diabetic polyneuropathy rather than DR.[15] Thus, while FAZ and GCC provide valuable information about retinal structure, their role in predicting DR onset remains uncertain.

The relationship between diabetes duration and the risk of DR is generally well-established, with longer diabetes duration traditionally being considered a major risk factor for DR.[1,11,12] However, this study did not show this relationship. This may be due to various factors such as genetic diversity, early disease detection, and improved diabetes management. Some individuals with long-term diabetes may have a genetic predisposition that offers protection against DR. Patients with long-standing diabetes but good glycemic control over time might have a lower risk of developing DR, even with longer disease duration. Biases from self-reported diabetes duration may also contribute to this variation.

Previous studies have associated gender, hypertension, and dyslipidemia with DR development,[5,16-19] although some studies, like the systematic review by Zhou et al., found no significant differences in lipid levels between DR and non-DR patients.[20] In our cohort, these clinical factors were not significantly associated with DR development, possibly because our DR group consisted only of patients with mild NPDR. In more advanced stages of DR, these factors may play a larger role.

Interestingly, our study found that HbA1c was not associated with the development of mild NPDR, a finding that contrasts with several recent studies.[21,22] Zegeye et al. emphasized that good glycemic control, reflected by HbA1c, is crucial in preventing DR onset and progression.[21] Similarly, a meta-analysis by Zhang et al. concluded that HbA1c has good diagnostic value

for DR screening.[22] The discrepancy in our study may be attributed to that participants in both groups had already undergone early microvascular changes in DM, but the differences in HbA1c level might be subtle. With a larger sample size and more diverse DR stages, the relationship between HbA1c and DR development might become more prominent.

The differences between the crude and adjusted models highlight concepts such as collinearity, suppression effects, and confounding. Collinearity occurs when independent variables are highly correlated, distorting their individual contributions. We addressed collinearity by including all relevant variables in our models. Suppression effects, where additional variables reveal hidden relationships, were evident in our study, as DVD became significant predictors in the adjusted models, despite not being significant in the crude analysis. Confounding, where extraneous variables affect both independent and dependent variables, was accounted for by controlling factors such as age, HbA1c, hypertension, dyslipidemia, and diabetes duration, revealing significant associations in the adjusted models.

This study offers several strengths. To our knowledge, it is the first to focus primarily on diabetic patients with no DR and mild NPDR, reflecting real-world DR screening practices. Another strength is the comprehensive evaluation of both clinical risk factors and OCTA metrics, providing a detailed understanding of their relationships with DR. The use of high-resolution OCTA imaging allows for precise measurements of retinal microvasculature. Furthermore, the study employs both crude and adjusted logistic regression models, improving the accuracy and generalizability of the findings.

However, there are limitations. The cross-sectional design limits causal inferences and the ability to track DR progression over time. The focus on mild NPDR restricts the generalizability of findings to more advanced DR stages. Potential measurement and reporting biases, including variability in OCTA measurements and self-reported diabetes duration, may also influence the results. Moreover, the exclusion of patients based on image quality and ocular comorbidities may result in selection bias and reduce external validity for real-world screening. Addressing these limitations will improve the applicability of findings related to DR risk factors.

Future research should adopt longitudinal approaches, include diverse populations, and examine a broader range of DR severities. Standardizing OCTA imaging protocols and validating self-reported data with objective measures will enhance the accuracy of findings.

Conclusions

In this study, SVD statistically differs between diabetic patients with no DR and those with mild NPDR, but the difference is clinically subtle. Moreover, vessel density metrics and age are important factors associated with the risk of mild NPDR. While OCTA shows potential in reflecting the microvascular status of diabetic patients, our study explored its practical application in detecting mild NPDR in real-world settings and demonstrated that there are small differences in SVD between diabetic patients without DR and those with mild NPDR. Since there may be individual variation in vessel density metrics and no established classification of DR stages by vessel density, it is difficult to use SVD for screening. Although previous research has suggested that OCTA provides significant biomarkers for diagnosing DR, it may not be suitable for detecting mild NPDR in routine screenings. Its role in mild NPDR screening remains limited, with clinical fundoscopy continuing to be the primary diagnostic tool.

Data Sharing Statement

The study protocol and the clinical data collected during the study, after deidentification, could be shared on personal request.

Acknowledgments

The authors would like to thank Dr. Kaewjai Thepsuthammarat, Clinical Epidemiology Unit, Faculty of Medicine, Khon Kaen University, for statistical analyses.

This study was granted by Faculty of Medicine, Khon Kaen University, Thailand (Grant Number IN68016)

Declaration of generative AI in scientific writing:

During the preparation of this work the authors used ChatGPT and Claude in order to improve the readability and language of the manuscript. After using this service, the authors reviewed and edited the content as needed and takes full responsibility for the content of the publication.

Confirmation that this article:

Has never been published elsewhere and is not currently under consideration for publication in any other journal.

Financial disclosure

The authors report no conflicts of interest in this work.

References

1. Yau JWY, Rogers SL, Kawasaki R, et al; Meta-Analysis for Eye Disease (META-EYE) Study Group. Global prevalence and major risk factors of diabetic retinopathy. Diabetes Care. 2012;35(3):556-564.
2. Ong CJT, Wong MYZ, Cheong KX, et al. Optical coherence tomography angiography in retinal vascular disorders. Diagnostics. 2023;13(9):1620.
3. Durbin MK, An L, Shemonski ND, Soares M, et al. Quantification of retinal microvascular density in optical coherence tomography angiography images in diabetic retinopathy. JAMA Ophthalmol. 2017;135(4):370-376.
4. Mokrane A, Zureik A, Bonnin S, et al. Retinal sensitivity correlates with the superficial vessel density and inner layer thickness in diabetic retinopathy. Invest Ophthalmol Vis Sci. 2021;62(11):28.
5. Li X, Yu Y, Liu X, Shi Y, et al. Quantitative analysis of retinal vessel density and thickness changes in diabetes mellitus evaluated using optical coherence tomography angiography: a cross-sectional study. BMC Ophthalmol. 2021;21:259.
6. Kim T-Y, Song Y-Y, Il-Jung, et al. The impairment of the deep vascular complex in prolonged type 2 diabetes patients without clinical diabetic retinopathy. PLoS One. 2022;17(6):e0269182.
7. Ashraf M, Sampani K, Clermont A, et al. Vascular density of deep, intermediate, and superficial vascular plexuses are differentially affected by diabetic retinopathy severity. Invest Ophthalmol Vis Sci. 2020; 61(8):53.
8. Zeng Y, Cao D, Yang D, et al. Retinal vasculature-function correlation in non-proliferative diabetic retinopathy. Doc Ophthalmol. 2020;140(2):129-138.
9. Li Q, Wang M, Li X, et al. Aging and diabetic retinopathy: Inherently intertwined pathophysiological processes. Exp Gerontol. 2023;177:112138.
10. Leley SP, Ciulla TA, Bhatwadekar AD. Diabetic retinopathy in the aging population: A perspective of pathogenesis and treatment. Clin Interv Aging. 2021;16:1367–1378.
11. Zhang Z, Lv D, You Y, et al. Assessing the importance of risk factors for diabetic retinopathy in patients with type 2 diabetes mellitus: Results from the classification and regression tree models. J Family Community Med. 2024;31(3):197-205.
12. Boonsaen T, Choksakunwong S, Lertwattanarak R. Prevalence of and factors associated with diabetic retinopathy in patients with diabetes mellitus at Siriraj Hospital – Thailand's largest national tertiary referral

center. Diabetes Metab Syndr Obes. 2021;14:4945–4957.
13. Waheed NK, Rosen RB, Jia Y, et al. Optical coherence tomography angiography in diabetic retinopathy. Prog Retin Eye Res. 2023;97:101206.
14. Liu J, He Y, Kong L, et al. Study of foveal avascular zone growth in individuals with mild diabetic retinopathy by optical coherence tomography. Invest Ophthalmol Vis Sci. 2023;64(9):21.
15. Salvi L, Plateroti P, Balducci S, et al. Abnormalities of retinal ganglion cell complex at optical coherence tomography in patients with type 2 diabetes: a sign of diabetic polyneuropathy, not retinopathy. J Cell Sci. 2024;137(15):260290.
16. Vision Loss Expert Group of the Global Burden of Disease Study, GBD 2019 Blindness and Vision Impairment Collaborators. Global estimates on the number of people blind or visually impaired by diabetic retinopathy: a meta-analysis from 2000 to 2020. Eye. 2024;38:2047-57.
17. Liu L, Quang ND, Banu R, et al. Hypertension, blood pressure control and diabetic retinopathy in a large population-based study. PLoS One. 2020; 15(3):e0229665.
18. Zhang M, Wu J, Wang Y, et al. Associations between blood pressure levels and diabetic retinopathy in patients with diabetes mellitus: A population-based study. Heliyon. 2023;9(6):e16830.
19. Chou Y, Ma J, Su X, et al. Emerging insights into the relationship between hyperlipidemia and the risk of diabetic retinopathy. Lipids Health Dis. 2020;19:241.
20. Zhou Y, Wang C, Shi K, et al. Relationship between dyslipidemia and diabetic retinopathy: a systematic review and meta-analysis. Medicine (Baltimore). 2018;97(36):e12283.
21. Zegeye AF, Temachu YZ, Mekonnen CK. Prevalence and factors associated with diabetic retinopathy among type 2 diabetic patients at Northwest Amhara Comprehensive Specialized Hospitals, Northwest Ethiopia. BMC Ophthalmol. 2023;23:9.
22. Zhang B, Zhang B, Zhou Z, et al. The value of glycosylated hemoglobin in the diagnosis of diabetic retinopathy: a systematic review and meta-analysis. BMC Endocr Disord. 2021;21:82.

การประเมินบทบาทของการถ่ายภาพหลอดเลือดจอประสาทตา (Optical coherence tomography angiography) ในการวินิจฉัยภาวะเบาหวานขึ้นจอประสาทตาระยะเริ่มต้นในเวชปฏิบัติจริง และปัจจัยเสี่ยงทางคลินิกที่เกี่ยวข้อง



Soramon Chaichan, MD*
ศรมน ชัยชาญ, พ.บ.*

Tanapat Ratanapakorn, MD
ธนภัทร รัตนภากร, พ.บ.

Suthasinee Sinawat, MD
สุธาสินี สีนะวัฒน์, พ.บ.

Yosanan Yospaiboon, MD
ยศอนันต์ ยศไพบูลย์, พ.บ.

บทคัดย่อ:

วัตถุประสงค์: เพื่อประเมินประโยชน์ทางคลินิกของตัวชี้วัดจากการถ่ายภาพหลอดเลือดจอตา (optical coherence tomography angiography; OCTA) ในการตรวจวินิจฉัยภาวะเบาหวานขึ้นจอประสาทตาชนิดไม่เพิ่มหลอดเลือด (non-proliferative diabetic retinopathy; NPDR) ระยะเริ่มต้น (mild NPDR) และศึกษาปัจจัยเสี่ยงทางคลินิกที่สัมพันธ์กับภาวะดังกล่าว

วิธีการศึกษา: การศึกษานี้เป็นการศึกษาเชิงภาคตัดขวางแบบไปข้างหน้าในผู้ป่วยเบาหวานชนิดที่ 2 โดยพิจารณาตัวชี้วัดจาก OCTA ได้แก่ ความหนาแน่นของหลอดเลือดในชั้น superficial capillary plexus (SVD) และ deep capillary plexus (DVD) ความหนาของ ganglion cell complex (GCC) และพื้นที่ของ foveal avascular zone (FAZ) ในบริเวณ parafoveal โดยใช้เครื่อง Optovue Solix OCTA และวิเคราะห์ความสัมพันธ์ระหว่างตัวชี้วัดจาก OCTA และปัจจัยเสี่ยงทางคลินิกกับภาวะเบาหวานขึ้นจอประสาทตาระยะเริ่มต้น ด้วยการวิเคราะห์ถดถอยโลจิสติก โดยปรับค่าตัวแปรกวนที่เกี่ยวข้อง

ผลการศึกษา: ผู้เข้าร่วมการศึกษาทั้งหมด 236 ราย แบ่งเป็นกลุ่มที่ไม่พบภาวะเบาหวานขึ้นจอประสาทตา 118 ราย และกลุ่มที่มีภาวะเบาหวานขึ้นจอประสาทตาชนิด mild NPDR 118 ราย พบว่า ค่า SVD ในกลุ่ม mild NPDR ต่ำกว่ากลุ่มที่ไม่พบภาวะเบาหวานขึ้นจอประสาทตาอย่างมีนัยสำคัญทางสถิติ (48.37 ± 2.25% เทียบกับ 49.22 ± 2.82%, p = 0.011) ในขณะที่ตัวชี้วัดอื่นไม่แตกต่างกันอย่างมีนัยสำคัญ อย่างไรก็ตามการวิเคราะห์ถดถอยโลจิสติก หลังปรับค่าตัวแปรกวนพบว่า การเกิด mild NPDR มีความสัมพันธ์อย่างมีนัยสำคัญกับค่า SVD (p < 0.001), DVD (p = 0.003), และอายุ (p = 0.001).

สรุปผล: แม้ค่า SVD ในกลุ่ม mild NPDR จะลดลงกว่ากลุ่มที่ไม่พบภาวะเบาหวานขึ้นจอประสาทตาอย่างมีนัยสำคัญทางสถิติ แต่ยังไม่แตกต่างกันอย่างที่มีนัยสำคัญทางคลินิก อย่างไรก็ตามความหนาแน่นของหลอดเลือดจาก OCTA และอายุ เป็นปัจจัยที่สัมพันธ์กับการเกิด mild NPDR ดังนั้นแม้ OCTA มีคุณค่าในการประเมินหลอดเลือดของจอประสาทตา แต่ประโยชน์ในด้านการใช้เป็นเครื่องมือคัดกรอง mild NPDR ยังมีข้อจำกัด และการตรวจจอประสาทตาทั่วไปทางคลินิก (clinical fundoscopy) จึงยังคงเป็นวิธีหลักสำหรับการวินิจฉัยภาวะเบาหวานขึ้นจอประสาทตาชนิด mild NPDR

คำสำคัญ: เครื่องถ่ายภาพหลอดเลือดจอตา, ความหนาแน่นของหลอดเลือดชั้นตื้น, ความหนาแน่นของหลอดเลือดชั้นลึก, เบาหวานขึ้นจอประสาทตาชนิดไม่เพิ่มหลอดเลือด, ฮีโมโกลบิน เอ วัน ซี, ระยะเวลาการเป็นโรคเบาหวาน

ภาควิชาจักษุวิทยา คณะแพทยศาสตร์ มหาวิทยาลัยขอนแก่น

Footnotes and Financial Disclosures
Originally receive: 12/2/2026
Final revision: 8/4/2026
Accepted: 17/4/2026
Corresponding author: Soramon Chaichan, MD
KKU Eye Center, Department of Ophthalmology, Faculty of Medicine, Khon Kaen University
Financial Disclosure(s): The authors report no conflicts of interest in this work.