

Abstracts
July 20, 2013

Matrix Training Program

Hung-to Luk, MBBS (HKU), FRCS (Ed), FRCPS (Glas), FCSHK; FHKAM (Surg)

President, The College of Surgeons of Hong Kong

The training of a surgeon in Hong Kong is based mainly on the United Kingdom model being related to the history of Hong Kong. The beginning of formal surgical training can be dated back to about 50 years ago when the Royal College of Surgeons of Edinburgh conducted Fellowship Examination in Hong Kong. The training program is basically a time based program and it is on job training with Part 1 and Part 2 Examinations.

When Hong Kong returned to China in 1997, we had to make changes in terms of post-graduate education. The College of Surgeons of Hong Kong was established in 1990 to oversee surgical education and standard of practicing surgeons in Hong Kong. It is by law that post-graduate training not less than 6 years with an intermediate and then final examination leading to Fellowship and Specialist Registration in Hong Kong. It is still a time based model with reference to training program of Royal College of Surgeons of Edinburgh and the 2 Colleges conduct conjoint examinations.

As time changes, the time based on job training model becomes inadequate to equip our young surgeons with the skills required for their practice in particular with the emergence of work hours limitation. The trend is moving towards a competencies based learning where teaching of a surgeon becomes more structured. Competencies that we expect our trainees learning from their trainers role modelling such as communication skills and team work are now included in the training program where courses are available. Training of a surgeon includes technical and non-technical skills where both are of equal importance.

Despite the world trend of competencies based learning, our College found that clinical exposure in terms of training in technical and non-technical skills still plays an important role. Therefore we proposed a matrix model in training where a trainee can complete his/her training only when all competencies are met and also completing a minimal time frame in terms of clinical exposure. The time frame chosen is 6 years as at present. We will monitor the standard achieved by

Saturday, July 20, 2013

08.30-10.00	S	Sattahip
-------------	---	----------

our trainees to refine our training program as there are still challengers ahead like limited work hours, aging population and the increasing knowledge and complexity of surgical operations.

The Challenges of Post Graduate Surgical Training and Education in Developing Economy

Ranil Fernando M.S. (Col), FRCS (Edin), FRCS (Eng), FCPS (Pak), FASI (India)

President of College of Surgeons of Sri Lanka

The task of training and educating Postgraduates in surgery is a challenging endeavour as it has to, of necessity, evolve and change constantly.

These changes must be cognizant of the resources required, the educational value of change, the health needs of the country/community, emerging global trends and the aspirations of the postgraduates. The interplay of all these factors makes the task of educating and training postgraduates in surgery a challenge even in a developed country. When there is limitation in resources, the task becomes more challenging, if not daunting.

Sri Lanka is a developing country and the state is the main provider of funding for postgraduate education and training. The state requires competent specialists to provide equitable health care for the population. The Postgraduate Institute of Medicine is the only (PGIM) organization that undertakes postgraduate training in Sri Lanka. The PGIM collaborates with the university grants commission, ministry of higher education and the ministry of health in carrying out this task. The bureaucracy and the conflicts within this chain of command throw up challenges to training regularly. In order to overcome this, a proposal for the establishment of an independent institute which deals directly with the ministry of finance has been proposed and accepted.

The main issue in training postgraduates in surgery is to define what type of surgeon/surgeons a country needs. While the needs of the community are of importance if the aspirations of the trainee are ignored, the training programme is unlikely to be successful as no one will undertake training. Striking the right balance between the needs and the aspirations has been a constant challenge faced by the PGIM in Sri Lanka. The Ministry of health requires generalists to man the state hospitals and the emphasis in the training programme has been to provide a good overall general training. To cater to the aspirations of the trainees, some specialty training has been permitted. To make general surgery more rewarding, in keeping with the global trends, all generalists are required to select

an area of special interest and obtain additional training, but they will work mainly as generalists. The other aspect that needs special emphasis is research. Research requires resources and in developing economy, this is indeed a challenge. Yet it is important to inculcate a 'research culture' in the modern surgical trainee and hence research presentations and publications have been made mandatory in the training programme.

Despite many challenges the surgical training & education in Sri Lanka attempts to maintain the right balance between academic aspirations and the health needs of the country.

Surgical Education & the Philippine College of Surgeons: The changing landscape of Surgical Training in the Philippines

Alfred H. Belmonte MD FPCS, FPSGS

President, Philippine College of Surgeons

The Philippine College of Surgeons is one of the oldest Colleges in Asia, founded in 1936 with the goal of improving the standard of surgical care available in the country through continuing surgical education. At its inception, it encompassed all specialties of surgery, ophthalmology & ENT, even Obstetrics & Gynecology. CSE found a common ground that crossed all boundaries with no problems.

After celebrating its 75th Anniversary two years ago, the PCS struggled to remain relevant as an “umbrella” organization of the surgical specialties, with no one even sure how an umbrella was supposed to function. General Surgery, which was and remains as the backbone of the College was devolved to the Philippine Society of General Surgeons a little more than a decade previously with the College left with no training programs, no certifying Board and no accrediting bodies. Its component societies had grown in numbers and capabilities, their Fellows given the option of applying for Fellowship to the College. A good number chose to obtain membership only in their specialty, opting not to become Fellows of the College. Only the Philippine Society of General Surgeons imposed a mandatory period for entry in to the College under pain of revocation of Fellowship.

This presentation discusses the path to renewed relevance taken by the College with the hope that it shall not only invite suggestions from the international gathering of surgeons who have faced similar situations but also provide lessons to those who shall encounter it in their future.

Surgical Training with Simulation

Mark W. Bowyer, MD, FACS, DMCC

Professor of Surgery

Director of Surgical Simulation

National Capital Area Medical Simulation Center

Uniformed Services University; Bethesda, Maryland; USA

Surgical training has never been more difficult. The advent of work hour restrictions, fears of malpractice, and diminishing surgical volume have made the traditional see one - do one - teach one apprenticeship model obsolete. Surgical educators must ensure that trainees are highly competent independently functioning experts who can perform as advertised. The training of trauma surgery has fallen on even harder times as most trauma cared for in 2013 is managed non-operatively. One potential solution for this problem is to use non-patient models to train to a proscribed level of proficiency before being allowed to practice on a living human. Animals provide one such mode and are excellent for bleeding and tissue tool interaction, but are poor for teaching human anatomy and are politically incorrect. Cadavers are another viable alternative but are limited by cost, availability, and variable quality/anatomy.

Surgical simulation will likely provide a solution to many of the problems described above. Though this field is in its relative infancy it is rapidly expanding and new simulators are being developed and validated.

This presentation will review the current state of surgical simulation for trauma surgery training as well as the near future which will include standardized physical or virtual reality models with surgically correct human anatomy which bleed and that one can operate with actual surgical instruments and techniques. The key to success of these simulators will be incorporating them into robust and validated curricula that will eventually allow for training of trauma surgical skills and high stakes testing.

Procedure Based Assessment: Current Situation in Thailand

Chalermpong Chatdokmaiprai

Plastic Surgery Devision, Department of Surgery, Faculty of Medicine at Ramathibodi Hospital, Mahidol University

PBA (procedure based assessment) is a tool for assessing the competency of surgical trainees in terms of clinical skills (factual knowledge, psychomotor, decision making and communication skills). PBA requires agreement of developing, using, and collecting the data among the training program hospitals. This process should be highlighted.

To develop each PBA is crucial, demanding brain storm, knowledge and the agreement to mandate the PBA as the universal assessment tool. This tool also requires the validity and should be collected as the formative evaluation which is easily to retrieved and analyzed regularly by the training program director. Without agreement to have this mandatory assessment, PBA will never be possible.

The current situation of PBA in Thailand is in the phase of developing the indicative PBAs and trials. In plastic surgery training program, there is the agreement to develop 4 indicative procedures, cleft lip repair, fixation of zygomatic fracture, upper blepharoplasty and neck dissection. The pilot using of this PBA gain the positive feedback from the trainers and trainees. The data collection for the formative evaluation should be computerized as much as possible to be easily retrieved for analysis. The development of application is still under constructed in the same software of the resident E-logbook

The success of the PBA is deeply depended on the cooperation among the training program hospitals.

Trauma Surgery is not Emergency General Surgery: The Training of a Trauma Surgeon

K. D. Boffard

Professor and Head of Surgery

Charlotte Maxeke Johannesburg Academic Hospital

University of the Witwatersrand, Johannesburg, South Africa

Traditional surgical training has required a very strong knowledge of anatomy, and pathology. Increasingly, the training has been biased towards an anatomical approach using such technological advances laparoscopy, diagnostic imaging, and computer simulation. It is mandatory to have an understanding of the pathology which is the focus of the surgical intervention.

Although increasingly non-operative, trauma surgery has become more “scientific” and much more strongly based in the intensive care unit. The modern trauma surgeon must not only have an appreciation of the surgical problems associated with both blunt and penetrating trauma, but must also have an appreciation of the physiology of the human body, how it reacts to metabolic and physical stressors, and the trauma surgeon must understand and support the physiological requirements which result. Consequently the training of the trauma surgeon has diverged from that of the general surgeon, including that of emergency surgery, and would now include the management of major trauma, including its prevention, Burns surgery, and disaster management. The modern needs of this training will be analysed in the light of global trauma training experience.

Surgical Quality Improvement: Lessons from the Airline Industry

Siew Kheong LUM, MBBS, FAMM, FRCSEd, FACS, FRACS(Hon), FAMS(Hon)

The recently released Francis report in the UK gives valuable insights on the discordance between the public view of quality compared with the tunnel vision view of quality held by many in the health profession. Robert Francis QC opined, “This is a story of appalling and unnecessary suffering of hundreds of people. They were failed by a system which ignored the warning signs and put corporate self interest and cost control ahead of patients and their safety..... There was lack of care, compassion, humanity and leadership. The most basic standards of care were not observed and fundamental rights to dignity were not respected.” There was no mention of specifics like MRSA infection rate, volume-outcomes and anastomotic leak rate of each surgeon etc.

128

It is important to understand quality in the way we rate an airline experience. Every step of the passenger encounter is factored into the perception of QUALITY. The check-in experience, the punctuality of the take off and landing time, the in-flight experience, the interaction with the stewardess, the response time of the stewardess to pressing of the overhead light, the quality of the food, the functioning of the headset, TV and working toilets are important. The passenger also records unconsciously the leadership structure in the plane between the pilot, chief steward and stewardesses, the professionalism and collegiality among the stewardesses, their teamwork, their communication skills and their commitment to hospitality. This comprehensive experience is always subjective and as the saying goes, “you can easily recognise quality care when you experience it.” It is unlikely that a passenger will ask for information like, “How many times has the pilot flown this aircraft. Is he competent?” A passenger has explicit trust that a reputable airline would have done the right thing to ensure the plane is air worthy, the pilot is fit and healthy, not fatigued, had regular simulation practice to clock a certain number of hours and followed checklists for key operations. Quality is dependent on comprehensive perception. It is not the work of one outstanding individual but the result of teamwork. When one weak link fails, the

Saturday, July 20, 2013

10.30-12.00

S

Sattahip

entire system fails. This is the direction to follow in improving quality care. The lecture will focus on the areas the Health authorities and surgeon can improve quality with lessons from the airline industry.

Delivering Equitable Surgical Care in a Developing Economy

Ranil Fernando M.S. (Col), FRCS (Edin), FRCS (Eng), FCPS (Pak), FASI (India)

President of College of Surgeons of Sri Lanka

The delivery of surgical care is a complex and demanding task. It tends to be labour intensive and resource driven. Delivering such care in a developing economy such as in Sri Lankan economy is indeed a formidable challenge. Delivering equitable care seems almost a utopian concept.

The state sector is the main provider of health in Sri Lanka with the private sector playing an increasing role in larger cities. The State health care system is free to all patients and it is indeed commendable that a reasonable standard of surgical care is available in most parts of the country.

The country has a state hospital network which caters to the surgical needs of the majority particularly from the lower socio-economic strata. The main problem encountered is the dearth of surgeons to man the hospital and the lack of infrastructure facilities to provide surgical care in the more distant parts of the country. The total number of general surgeons available in the country does not exceed 150; if all the surgical specialties are included and the surgeons employed in universities are counted the number would not exceed 250. This is indeed a low surgeon/patient ratio compared to some countries, yet most patients have access to surgical services with a radius of about 50 miles from their home.

The main question is; is it equitable care? This is difficult to assess both in terms of the quality of services and the general care received by the patients. 'The brain drain' where the country loses many surgeons to developed countries has made the provision of equitable care a problem.

Trauma constitutes a significant portion of the emergency workload, yet the availability of ambulances and other transport facilities are not satisfactory. Efforts have been made to eliminate single man stations and develop centres of excellence where tertiary and high level care can be delivered to the surgical patients and even transplants are done free of charge in the state sector hospitals. The training programme too has undergone revisions to accommodate the changing needs of the country. General surgery with special interest is the main area of emphasis while opportunities are provided for training of subspecialties as well. Training of more surgeons and the provision of infrastructure facilities such as

10.30-12.00	S	Sattahip
-------------	---	----------

better hospital facilities, better housing and other incentives for surgeons and development of centres of excellence with an organized referral system will be required to provide equitable surgical care in the future.

Trauma Quality Improvement Program- WHO Initiative

Dr. Ranjith Ellawala MBBS (Sri Lanka), MS (Sri Lanka), FRCS (Glas),

Honorary Fellow of the College of Surgeons of Sri Lanka

The World Health Organization has extended its help in many ways towards developing and improving trauma care globally. Apart from fulfilling its primary function of advocacy, the WHO strives to provide guidance to its member nations through the resolutions passed in the World Health Assembly. Although the organization acts as a catalyst for the advancement of trauma care globally, its influence is most helpful for those in the developing world.

The WHO identifies injury prevention and care as one of its foremost priorities, which has resulted in a number of commendable initiatives. One such measure, the VIP short course on Quality Improvement in Trauma Care was formulated by the Violence and Injury Prevention department in 2009. A major portion of the work is carried out by the Trauma Emergency Care Service Committee, along with other stake holders such as IATSIIC.

The Trauma Quality Improvement Program is a short course spanning 2-3 day and is structured along a modular format. 8 such modules cover a wide range of techniques of Trauma QI which are applicable in any country or context. The program addresses the appropriateness of different techniques at different health care facilities whilst stressing on the importance and methods of data collection and usage. It includes PowerPoint presentations and facilitator's guide. The course manual is printed in English, Spanish and Portuguese to facilitate language accessibility.

Surgical Quality Improvement in Australia and New Zealand

Ian Civil

Immediate Past President, Royal Australasian College of Surgeons

Quality surgical care is an expectation of patients, funders and the providers of healthcare but there are many examples where the quality of healthcare has been sadly lacking and intervention by those aware of the limitations absent. In both Australia and NZ there are organisations such as the Clinical Excellence Commission in NSW and the Health Quality and Safety Commission (HQSC) in NZ that have been established to stimulate quality improvement. In both countries introduction of the WHO surgical safety checklist has occurred to reduce error around the time of surgery and simultaneously initiatives to increase VTE prophylaxis, decrease SSI, reduce in-hospital falls and medication errors are all designed to improve the quality of the surgical journey. While there are few examples of a surgical quality improvement process such as run in the USA under the auspices of the American College of Surgeons, the development of Australian Trauma Quality Improvement Program (AuTQIP) under the auspices of the National Trauma Research Institute has been developed to identify process and outcome markers of quality surgical care and allow hospitals to monitor and benchmark their performance in the delivery of trauma care. The HQSC in NZ similarly has developed a set of process and outcome markers for similar reasons and appropriate timing of antibiotic and VTE prophylaxis and the frequency of these adverse events are being monitored and fed back to healthcare providers. Sentinel event recording and the investigation of these events similarly provides important feedback to providers.

Surgical quality requires a process where a standard is set, markers of that standard are developed, and data is recorded. Without data, baselines are unknown and the effect of any change speculative. Once data is available this must be used to inform change in an evidence based way. Presently there are many examples where standards have been set but many fewer where relevant process and outcome markers are recorded. There is still a long way to go to ensure process which can guarantee a quality surgical experience for patients in Australia and NZ.

CPD and Revalidation in Australia and New Zealand

Ian Civil

Immediate Past President, Royal Australasian College of Surgeons

An intrinsic component of professionalism by both the traditional and modern definitions is maintenance of competence. This expectation of the professional has been largely filled in the past by tacit expectations laid at the foot of the practitioner with a framework described by Colleges' continuing professional developments. Society is no longer satisfied with this as it does not necessarily confirm the competence of the individual practitioner. Thus revalidation, a concept whereby some form of appraisal allows a third party to determine the currency, competence and fitness to practice of a practitioner. Within Australia and New Zealand this process is in its infancy. CPD requirements are becoming more specific and in particular demonstration of some form of multisource feedback is now a requirement by the RACS on an annual basis. While revalidation in some time away, assessment in the form of practice visits is a recommendation of the Medical Council of NZ. The NZ Orthopaedic Association has had such a practice visit scheme running for some years and is enthusiastic while simultaneously noting that it is resource intensive.

Intrinsic to revalidation must be a process to assist those who struggle with the process. Until the resource implications as well as a range of options for the various outcomes are considered and available, targeted CPD and a reliance on professionalism to ensure competence will of necessity remain.

International Collaboration in Surgery “Surgical Leadership”

Professor Dhananjaya Sharma

MS, PhD (Doctor of Philosophy), DSc (Doctor of Science),

FRCS (Glasgow), FRCST (Hon)

Head, Department of Surgery

Government Medical College and Allied Hospitals

Jabalpur (MP) India 482 003 E-mail: dhanshar@gmail.com

Surgeons, by themselves are specially gifted individuals; to provide leadership to this special class requires many extraordinary qualities. I have suggested 10 Commandments for a Surgical Leader:

1. You shall strike the right balance between clinical/ surgical work, teaching, and academics/ research!
2. You shall choose your working style carefully: graceful and elegant!
3. You shall be ambitious, proud and humble at the same time!
4. You shall innovate not emulate!
5. You shall empower other team members!
6. You shall know your resources and optimize them!
7. You shall not stop learning and moving forward!
8. You shall be a good mentor!
9. You shall be knowledgeable as well as wise!
10. You shall be a leader, not a boss!

Good Judgement Comes from Experience. Experience Comes from Bad Judgement: The Need for Global Collaboration

K. D. Boffard

Professor and Head of Surgery

Charlotte Maxeke Johannesburg Academic Hospital

University of the Witwatersrand, Johannesburg, South Africa

136

The world is a safer place. At least in some places. In the developed countries of the first world, good trauma prevention programs, and effective law enforcement, have resulted in a dramatic fall in the incidence of major trauma particularly that associated with motor crashes, as well as reduction in inter-personal violence. In developing countries and those that are resource challenged, trauma is much more prevalent; however these same countries do not have the infrastructure to deal with the burden of the trauma disease, nor do they have the resources including diagnostic and therapeutic, to manage it well. These countries are often short of manpower, including doctors, nurses, and support staff, and as a result the patients do not always get the treatment that they deserve. Recent conflicts as well as terrorist incidents have shown that, unfortunately, doctors in the major countries of the West have less and less experience in the management of major trauma and in some situations, patients have suffered as a result.

Thomas L Friedman in his renowned book, “The World is Flat”, analysed the effects of globalisation on world markets. In a landmark lecture given at the International Society of surgery in 2009, Donald the Trunkey in his lecture “The Medical World is Flat Too explored this concept, and showed that the medical world has to adapt to this and embrace the same concept.

The ways in which the trauma community can become global to mutual benefit will be explored.

Innovation in Laparoscopic HBP Surgery

Anusak Yiengpruksawan

United States

The speaker will talk about current status, new development, and technique of minimally invasive HPB surgery. The main focus, however, will be on robotic application and intraoperative fluorescence imaging with detailed discussion and video presentations of “Firefly Imaging” technique.

Advanced Surgical Instruments & Setting in Opened Surgery

Warisara Tuvayanon, APN, MNS

Current laparoscopic surgery is widely popular. But there are some limitations, such as the progression of the disease, tumors in organs that are not too big. Therefore, laparotomy (opened surgery) is important in patients who were not suitable for laparoscopic surgery. The principle of laparotomy is the good surgical field, which is the key of successful in general surgery.

The retractors are necessary for access the intraabdominal organs effectively. Upto now, we use the handheld retractors for exposed surgical field. But in the last decade, the table-fixed retractor system has been widely adopted for abdominal surgery. This system is used to retract the abdomen for good exposure of operative field, good visualization and very simple by combination rotation, tilt and self-retraining into a single ratchet, such as BookWalter retractor system, Thompson retractor set. The adjustment forms of the instruments set depend on type of operative field and surgeon expertise.

In addition, the amount of blood loss during surgery can't be ignored in opened surgery. But sometimes it's difficult to control even with the careful planning of surgery as well. Nowadays, intraoperative cell salvage and autologous blood transfusion has become an important method of blood conservation¹. The principles of cell salvage are collecting, washing, filtering and re-infusion the red blood cell. Aim of the cell salvage is to reduce need for allogeneic blood transfusion, which strongly evidence supporting in cardiac and orthopedic surgery¹. However, large volume of the transfusion more than 3000 ml associated with coagulopathy because the processing of the salvaged blood removed platelets and coagulating factors². The AAGBI guideline identified indications of intraoperative cell salvage as anticipated blood loss >1000 ml or >20% of blood volume, anemia, and in patients who refuse to receiving allogeneic blood product³.

References

1. Ashworth A, Klein AA. Cell salvage as part of blood conservation strategy in anesthesia. British Journal of Anaesthesia 2010; 105(4): 401-16.

2. Li MH, Yan LN, Wang SR. Autologous transfusion with modified total hepatic vascular exclusion for extracapsular resection of giant cavernous hemangioma. *Hepatobiliary Pancreat Dis Int* 2007;6:43-8.
3. The Association of Anaesthetists of Great Britain and Ireland (AAGBI) Safety guideline-blood transfusion and the anaesthetist: Intraoperative cell salvage. 2009. Available from http://aagbi.org/publication/guidelines/docs/cell%20salvage_2009_amended.pdf (retrieved on June 14, 2013)

Abstracts
July 21, 2013

Update in Stress Urinary Incontinence

Professor Wachira Kochakarn, MD,FACS, FRCST

Urinary incontinence is a common symptom experienced by significant numbers of adult in both women and men. Stress urinary incontinence (SUI) is the most frequently encountered type and affects around 50% of incontinent females. Pathophysiologies of SUI are included hypermobility of urethra and intrinsic sphincter deficiency. Recent years have seen the development of several new and popular techniques for the treatment of this condition. Once the diagnosis SUI or mixed urinary incontinence (MUI) with a predominant “stress component” is made with confidence then treatment modalities should be fully discussed with the patient and all options, both surgical and non-surgical, should be outlined. Initial management should start with lifestyle advice, physical therapies, scheduled voiding, behavioral therapies and medication. Lifestyle advice includes caffeine reduction, weight loss for the overweight person, treatment of constipation, decrease in fluid intake in patients who are over hydrating and efforts to decrease chronic cough.

Pelvic floor muscle training (PFMT) should be offered as first-line therapy for SUI. Intensive and supervised PMFT is recommended if available. The benefit of biofeedback is unknown but might be helpful enhancing result of behavioral therapy. Vaginal cones can be offered for treatment for SUI or MUI, but its use may be limited due to discomfort. Pessaries may be considered in the treatment of SUI even without concomitant pelvic organ prolapsed. The injection of bulking agents sub-mucosal in the female urethra is intended to aid continence via apposition of the urethral wall. It is thought to be most useful in the treatment intrinsic sphincter deficiency. As well as its use in female SUI, this technique is also reported in males and children and can be carried out under local anesthesia. The advantages of this technique include the low associated morbidity. Retropubic suspension procedures are mainly intended for the treatment of SUI secondary to urethral hypermobility and a wide variety of different techniques are available. All have the common underlying principle of elevating and fixing the bladder neck and proximal urethra in a retropubic position to enhance support. The most widely used technique is the Burch colposuspension and this procedure has been used

as a gold standard with which to compare newer surgical treatments for SUI. The development of the TVT led to trials of a similar low tension sub-urethral tape but using a different route of access; the trans-obturator tape (TOT) again uses mid-urethral tape placement but instead of anchoring supra-pubic route like a TVT, it anchors through the obturator foramen. It is not recommended for routine surgical treatment of SUI. The patient with SUI has a large number of surgical options to consider and this review can help with counseling for health care providers within this clinical area. The comparison between the proven long-term efficacy but associated risk of surgical complications of open colposuspension versus the less invasive, low morbidity but relatively scarce long term data associated with sub-urethral tapes do not clearly favor either procedure. Equivalence at 5 years has been demonstrated many urologists believe that longer term efficacy will again be comparable leading to TVT becoming the gold standard surgical procedure for SUI on the basis of equivalent effect for reduced morbidity when compared with open colposuspension. Newer techniques should be compared to TVT and evaluated in terms of clinical efficacy, patient acceptability, and cost-effectiveness.

Current Management of Urinary Incontinence Following Prostate Surgery

Roger Roman Dmochowski

Professor

Department of Urology and Obstetrics and Gynecology

Vanderbilt University, Nashville, Tennessee, USA

Urinary incontinence following prostatectomy continues to be a source of significant patient dissatisfaction and some morbidity. Incontinence may occur either due sphincteric dysfunction (most likely), bladder dysfunction, or a combination of both. Preoperative workup is critical to assessing not only to establish urinary tract functional status, but also to establish anatomic integrity and lack of obstructive phenomenon especially in the urethra. Once evaluation has been performed, intervention may be considered. The treatment of sphincteric dysfunction includes behavioral as well as surgical. The most common surgical interventions include male urethral sling and artificial urinary sphincter. Results of both procedures are beneficial for the majority of patients; however, limitations of these procedures are critical to identify an appropriate patient selection as based upon these known results. Men with super imposed lower urinary tract symptoms prior to prostatectomy, may be at greater risk for voiding dysfunction and incontinence long term regardless of therapy chosen for sphincter dysfunction.

Basic Urodynamic Study for the General Urologist

Roger Roman Dmochowski

Professor

Department of Urology and Obstetrics and Gynecology

Vanderbilt University, Nashville, Tennessee, USA

Urodynamics continues to be the most important objective evaluation of lower urinary tract storage and emptying. A variety of tailored urodynamic testing modalities exist, dependent upon patient type and problem being evaluated. The combination of non-invasive uroflowmetry in multi-channel system metrics provides the most frequently utilized tandem of urodynamic assessment for lower urinary tract symptoms in general. However specific patient types require more focused assessment. Fluoroscopy is a very useful addition in patients with neurogenic disease or lower urinary tract obstruction where the point of obstruction is not clearly identified based upon other assessments (cystoscopy). In addition to flow and cystometry, pressure flow evaluation is critical for the assessment of presumed outlet obstruction, and also may be beneficial in the patient with dyssynergic pelvic floor function. Urodynamics provides delineation of complicated patients and postoperative failures. The assessment also provides some degree of postoperative prediction for certain types of operative intervention. The general urologist should be familiar with the different indications for urodynamics and the appropriate selection of study for unique patient and unique diagnosis.

Urology Surgery II: Challenging Cases in Female Urology Panel Bladder Outlet Obstruction in Women

Phitsanu Mahawong, M.D.

The exact prevalence of bladder outlet obstruction (BOO) in women is unknown because an acceptably diagnostic criteria is still lacking. Since voiding physiology in women is a bit different from in men, the male nomograms and bladder outlet obstruction index (BOOI) cannot be used for diagnosing female BOO. It is also difficult to construct a nomogram due to no predominant etiology of BOO in women. Even Nitti and Grazia reported their nomograms in 2000 and 2004, consecutively; their clinical applications are still debatable. The concept of obstruction is the same as in men but the acceptable cut-point values are still controversial. The detrusor pressure (Pdet) of higher than 20, 25, or 30 H₂O accompanied with maximal flow rate (Q_{max}) of lower than 10, 12, 15 ml/sec have been proposed by some authors. Nowadays, videourodynamic study (VUDS) is the most important tool for diagnosis of female BOO which is able to clarify the level of obstruction during pressure-flow study.

The two most common causes of female BOO are primary bladder neck obstruction (PBNO) and dysfunctional voiding (DFV). Treatments of PBNO are oral α_1 blocker, bladder neck dilation, and transurethral incision of the bladder neck (TUIBN). Treatment of DFV is complex and consisting of urethral dilation, behavioral therapy, biofeedback, pelvic floor rehabilitation and neuromodulation. The treatment outcome of DFV is variable and sometime may need clean intermittent catheterization (CIC). Long-term follow up is required for detecting complications and recurrence after treatment in these special patients.

Treatment of Hepatoblastoma

Prof. Riccardo A. Superina

Robert E. Schneider Chair in Transplantation

Professor of Surgery

Division Chief, Transplant Surgery

Co-Director, Siragusa Transplant Center, USA

Accepted practice for the treatment of hepatoblastoma requires complete surgical excision in addition to chemotherapy for cure. In the majority of patients, excision of the tumor is usually possible with or without neo-adjuvant chemotherapy, but in cases in which the tumor cannot be safely excised, liver transplantation has proven effective even in cases that may have initially presented with metastatic disease. Controversy exists regarding what constitutes the best therapy for tumors that are very large or critically positioned and impinge on essential vascular structures, or tumors that are multicentric and present in all four sectors of the liver before neo-adjuvant therapy. It has been proposed that all PRETEXT stage IV tumors and centrally placed PRETEXT stage III, particularly those that are intimately involved with vascular structures, should be transplanted after a course of neo-adjuvant chemotherapy. Our experience with extensive resection of liver tumors that were considered unresectable after neo-adjuvant chemotherapy came about primarily because of referrals for transplantation from other centers. There were 11 POSTEXT III and 3 POSTEXT IV tumors in this cohort of patients who had received between 2 and 7 cycles of neo-adjuvant chemotherapy. 14 patients were safely and effectively resected. All tumors were successfully excised using a variety of surgical techniques including extended hepatectomy with additional excision of nodules of tumors either not adjacent to the dominant mass, or extending into a fourth sector, skeletonization of hepatic veins, and careful dissection of hilar structures away from the adjacent tumor mass. The left hepatic duct was also removed in two patients when the tumor in segment IV could not be comfortably separated from the duct. Duct reconstruction was obviously necessary in these patients. The three POSTEXT IV patients underwent, a trisectionectomy, mesohepatectomy and trisectionectomy plus wedge resection respectively. In the last patient, pre-operative CT had failed to show a small deposit in the left segment III and it was decided to go ahead with the local

excision after removal of the right lobe and segment IV. Most of the POSTEXT III patients underwent trisectionectomy since the tumor always involved two of the three hepatic veins and impinged on the third requiring in many cases a left extended hepatectomy with sparing of segments VI and VII with skeletonization of the right hepatic vein or an extended right with skeletonization of the left hepatic vein. Interestingly, two patients with microscopic residua of tumor at the resection margins have done well. One child recurred four years after the initial resection and responded well to re-resection. Only one child of the cohort of 14 transplantable patients died of tumor recurrence. Our experience strongly indicates that in many patients who fulfill indications for transplantation as the most appropriate treatment for hepatoblastoma, aggressive surgical resection is equally effective and does not impact the scarce organ pool for children or expose the patient to the long-term risks of immune suppression.

Surgery for Portal Hypertension in Children

Prof. Riccardo A. Superina

Robert E. Schneider Chair in Transplantation

Professor of Surgery

Division Chief, Transplant Surgery

Co-Director, Siragusa Transplant Center, USA

Portal hypertension in children can be divided into four main types: Pre-hepatic, sinusoidal, post-hepatic and hyper dynamic. Examples of these include portal vein obstruction and thrombosis for the first type, intrinsic liver disease such as cirrhosis or congenital hepatic fibrosis for the second type, post chemotherapy venocclusive disease and Budd-Chiari syndrome for the third type and arterio-venous fistulae for the last.

The surgery for these various conditions may include portal vein re-construction for children with portal vein obstruction, selective and non selective portosystemic shunts for children with well compensated parenchymal disease, liver transplantation or portosystemic shunting for children with venous outflow problems, and surgical ligation or embolization of patients with arterio-venous fistulae.

Over 100 patients have undergone surgery for portal hypertension secondary to portal venous thrombosis. Most patients can be successfully reconstructed with a meso Rex bypass. This not only relieves the symptoms of portal hypertension but also restores liver metabolic function to normal. Comparison of results in over 100 children treated surgically for portal hypertension secondary to portal vein thrombosis, demonstrates that meso Rex bypass and portosystemic shunting are equally effective in relieving the symptoms of portal hypertension but differ in the results of resolution of hyperammonemia, poor growth and restitution to normal of liver dependent coagulation factors. Imaging studies are critical in determining candidacy for meso Rex bypass, but most non-invasive imaging including MRI and CT arteriography and venography are relatively insensitive in determining the patency of the intrahepatic portal vein and tend to have a high false negative rate. Direct surgical exploration of the recessus of Rex is advised in patients with significant symptoms of portal hypertension to determine the status of the portal vein inside the liver. In patients in whom more efficient porto-

systemic shunting is not advised for resolution of symptoms of portal hypertension, more direct visualization of the portal vein inside the liver with transjugular portal venography is advised

Children with well-compensated cirrhosis or hepatic fibrosis are well served with selective porto-systemic shunting. A single procedure with high success and minimal morbidity can substitute for repeated endoscopy and use of medication including beta-blockers for control of portal hypertensive bleeding from the gastro-esophageal area.

Patients with poor liver function and portal hypertension require liver transplantation and possible transjugular intrahepatic porto- systemic shunt (TIPS) for temporizing relief of bleeding and uncontrolled ascites while awaiting transplantation.

As the experience with vascular surgery obtained with liver transplantation has grown, the success rate in venous anastomotic procedures in all children including babies has improved to the point where surgery for the control of bleeding from gastro-esophageal varices, advanced hyper-splenism and other symptoms of portal hypertension from a variety of causes should be considered early in the course of treatment decision making.

Glissonean Approach for Hepatectomy

Masakazu Yamamoto

Department of Surgery, Institute of Gastroenterology, Tokyo Women's Medical University, Tokyo, Japan

The Glissonean pedicle approach in liver surgery provides new knowledge of the surgical anatomy and progresses the technique of liver surgery. The Glissonean pedicle is wrapped by the connective tissue referred to as the Walaeus sheath and includes the hepatic artery, the portal vein, the bile duct, the nerves and the lymphatic vessels. This approach provides extra-fascial access to the hepatic hilus, and the secondary Glissonean pedicles are taped and ligated at the hepatic hilus without liver dissection. The approaching point must be over the hilar plate; therefore, surgeons do not have to consider any variation of the artery or bile ducts. The tertiary branches can be approached through the hepatic hilus or in the liver on the borderlines between the segments. Any anatomical hepatectomy can be done using this technique which allows simple, safe and easy liver surgery. Liver surgeons should, therefore, know the fundamental concept of the Glissonean pedicle approach.

ภาพรังสีรอยโรคถุงน้ำหรือคล้ายถุงน้ำในตับอ่อน (Imaging Studies in Pancreatic Cystic Diseases)

รองศาสตราจารย์ แพทย์หญิง สุวลิ พงมานวิพุธ

ภาควิชารังสีวิทยา คณะแพทยศาสตร์ มหาวิทยาลัยเชียงใหม่

152

อุบัติการณ์ของรอยโรคที่ให้ลักษณะถุงน้ำหรือคล้ายถุงน้ำในตับอ่อนได้เพิ่มมากขึ้นเรื่อยๆ ซึ่งอาจเนื่องมาจากในปัจจุบันมีการตรวจวินิจฉัยทางรังสีมากขึ้น ทั้ง ultrasound (US), Computed Tomography (CT) และ Magnetic Resonance Imaging (MRI) ในกลุ่มผู้ป่วยที่มีความผิดปกติในช่องท้องทั้งจากตับอ่อนเองและอวัยวะอื่นๆ ในช่องท้อง และรังสีแพทย์ได้เฝ้าระวังโรคนี้มากขึ้น ทำให้มีการตรวจพบรอยโรคนี้ได้บ่อยขึ้น รอยโรคที่ให้ลักษณะถุงน้ำหรือคล้ายถุงน้ำในตับอ่อนมีสาเหตุที่หลากหลาย สาเหตุส่วนใหญ่ คือ pseudocyst รองลงมาเป็นกลุ่มเนื้องอกหรือมะเร็ง (neoplasm) ทั้ง benign และ malignant ซึ่งที่พบได้บ่อยในกลุ่มนี้ คือ Mucinous cystic tumor (MCT) Serous cystadenoma (SCA) Intraductal papillary mucinous neoplasm (IPMN) Solid pseudopapillary epithelial neoplasm (SPEN) Cystic neuroendocrine tumor และ Metastasis การวินิจฉัยโรคกลุ่มนี้ได้อย่างถูกต้องจึงมีความสำคัญต่อการรักษาผู้ป่วย

การวินิจฉัยแยกโรคในกลุ่มนี้ นอกจากจะต้องอาศัย อายุ เพศ ประวัติการเจ็บป่วยและผลการตรวจทางห้องปฏิบัติการแล้วลักษณะทางรังสีของรอยโรคถุงน้ำ ได้แก่ ความหนาของผนังถุงน้ำ ลักษณะ unilocular หรือ multilocular จำนวนและขนาดของช่อง (locule) ภายในก้อน multilocular การมีก้อนเนื้อภายในถุงน้ำ (mural nodule) ลักษณะความขุ่นของช่องเหลวที่อยู่ภายในถุงน้ำ การมีหินปูน การมีรอยต่อระหว่างท่อตับอ่อนและรอยโรคถุงน้ำ และการอักเสบของเนื้อตับอ่อนโดยรอบ เป็นต้น จะมีส่วนช่วยในการวินิจฉัยแยกโรค นอกจากนี้แล้วการตรวจทางรังสียังสามารถช่วยบอกความรุนแรงและการลุกลามของโรคเพื่อช่วยในการวางแผนการผ่าตัดได้

Truncervical Gunshot Wounds: Practical Approach to a Potentially Difficult Problem

Col (ret) Mark W. Bowyer, MD, FACS, DMCC

Professor of Surgery

Chief, Division of Trauma and Combat Surgery

Uniformed Services University; Bethesda, Maryland; USA

The neck is in military parlance “a target rich environment” containing many vital structures that when injured have high propensity for morbidity or mortality. Gunshot wounds to the neck in particular may result in significant damage and can be associated with high mortality.

This presentation will review a practical approach for managing patients with these particularly challenging injuries with an emphasis on the principles of damage control. When confronting a patient with a suspected truncervical GSW priority must be given to the ABC’s associated with trauma. Any hemorrhage or swelling in the neck can result in compromise of the airway and early intubation or surgical cricothyroidotomy may be lifesaving. Injuries to the airway may also occur and initial treatment may well be intubation, either orotracheally or through the injury or via separate surgical approach. Bleeding from carotid arteries or jugular veins may be torrential and rapid control with direct pressure, utilization of massive transfusion protocols and urgent surgical exploration is key to successful outcomes.

Contamination from the oropharynx or the esophagus must also be aggressively ruled in or out as contamination from these structures can lead to significant consequences if not diagnosed and treated. Additionally the neck contains the cervical spine and injuries to either the bony structures or nerves must also be identified and treated as appropriate.

A pragmatic approach to the initial and subsequent surgical control of these injuries will be presented.

References:

Rizzo A, Bowyer M: Operative Exposure in Neck Trauma: Exposure of the Carotid Artery and Jugular Vein. In Advanced Surgical Skills for Exposure in Trauma Manual, American College of Surgeons Committee on Trauma, Chicago, 2012, pp 42-47.

Bowyer M: Operative Exposure in Neck Trauma: Exposure of the Vertebral Artery in the Neck. In Advanced Surgical Skills for Exposure in Trauma Manual, American College of Surgeons Committee on Trauma, Chicago, 2012, pp 52-54.

Trauma I Challenging injuries: What do I do? Transpelvic Gunshot Wounds

อ.บพ.กำธน จันทรแจ่ม

Transpelvic gunshot wounds หมายถึง การบาดเจ็บจากกระสุนปืนที่แนวของการบาดเจ็บ (Trajectory) ผ่านบริเวณอุ้งเชิงกราน (Pelvic cavity) บริเวณอุ้งเชิงกรานของผู้ป่วยนั้นประกอบด้วยอวัยวะที่สำคัญ หลายระบบอยู่ใกล้ ๆ กัน ทำให้เกิดการบาดเจ็บต่ออวัยวะต่างๆ เหล่านั้นได้ และ มักจะเป็น complex injuries ได้แก่ อวัยวะของทางเดินอาหาร เช่น small bowel, large bowel และ rectum อวัยวะของระบบปัสสาวะ เช่น ureters และ urinary bladder เส้นเลือดใหญ่บริเวณช่องท้อง ได้แก่ iliac vessels อวัยวะของระบบสืบพันธุ์สตรี เช่น uterus, ovaries รวมทั้งส่วนของกระดูกเชิงกรานด้วย ทำให้การดูแลรักษาผู้ป่วย Transpelvic gunshot wounds จำเป็นต้องใช้ศัลยแพทย์หลายๆ ระบบดูแลร่วมกันในทางตรงกันข้าม บริเวณอุ้งเชิงกรานนี้เองก็ประกอบไปด้วย soft tissue กล้ามเนื้อ และกระดูกที่ค่อนข้างหนาแน่น ทำให้มีโอกาสนในการที่กระสุนปืนอาจไม่ผ่านเข้าไปทำการบาดเจ็บต่ออวัยวะภายในดังกล่าวได้เช่นกัน

ผู้ป่วยที่มาด้วยเรื่อง Gunshot wounds ที่บริเวณลำตัวนั้น จำเป็นต้องตรวจให้ละเอียด ในขั้นตอนของ Exposure เนื่องจากบางครั้งอาจมีแผลกระสุนอยู่ที่บริเวณ pelvic และ perineum ร่วมด้วย นอกจากนั้นควรต้องทำ logrolling เพื่อดูแผลที่บริเวณหลังด้วย ที่สำคัญต้องดูแผลที่บริเวณ buttock ด้วย ซึ่งบ่อยครั้งที่แผลกระสุนบริเวณ buttock นั้น ทะลุเข้าช่องท้อง ซึ่งมีอวัยวะบาดเจ็บที่ต้องได้รับการผ่าตัด 22-36%และมีโอกาสที่เป็นลักษณะของ transpelvic gunshot wound ด้วย การรักษาในปัจจุบันนิยมรักษาแบบ selective management โดยขึ้นอยู่กับอาการและอาการแสดงของผู้ป่วย สำหรับ mandatory laparotomy นั้นไม่นิยมเนื่องจากพบ non-therapeutic laparotomy และ complications มากขึ้นได้ ข้อบ่งชี้ในการผ่าตัดในผู้ป่วยกลุ่มนี้ได้แก่ ผู้ป่วยที่มี Hemodynamic unstable, ผู้ป่วยที่มี peritoneal signs, มีGross Hematuria และผู้ป่วยที่มี GI bleeding

ในผู้ป่วยที่มี Hemodynamic stable การตรวจร่างกายโดยละเอียดและการส่ง Plain X-ray Abdomen และ Pelvis ในท่า AP และ lateral ซึ่งควรจะติด metallic

marker บริเวณกระดูกสันหลังทั้งหมดนั้น สามารถที่จะบอกแนว (trajectory) คร่าวๆ ได้ โดยการลากเป็นเส้นตรงจากรูเข้าถึงรูออก หรือ จากรูเข้าถึงกระดูกสันหลังที่พบในภาพ X-ray แนวของการบาดเจ็บที่ผ่านบริเวณของเขตของ iliac crest จนถึง perineum ถือว่าเป็น transpelvic trajectory หรือมี transpelvic gunshot wounds การตรวจร่างกายโดยละเอียดมีความสำคัญมากใน transpelvic gunshot wounds นอกจากการดูบาดแผลกระดูกสันหลังทั้งหมด โดยการตรวจช่องท้องอย่างละเอียด ตรวจ per rectal examination (PR), ตรวจ per vaginal examination (PV) ตรวจชีพจรส่วนปลายของขาตั้งแต่ femoral pulse ลงมา ใส่สายสวนปัสสาวะเพื่อดูว่ามี gross hematuria หรือไม่

ในผู้ป่วยที่การตรวจร่างกายเบื้องต้นปกติดี ควรจะทำการตรวจเพิ่มเติม ได้แก่ proctosigmoidoscopy และอาจทำ CT scan with IV contrast และ CT cystogram ซึ่งสามารถประเมินการบาดเจ็บของอวัยวะต่างๆ ในอุ้งเชิงกรานได้ดี รวมทั้งสามารถทำเป็น CT Angiography ในกรณีที่สงสัยการบาดเจ็บของเส้นเลือด ในผู้ป่วยที่มี extrapelvic trajectory หรือ จากการตรวจเพิ่มเติมไม่พบการบาดเจ็บของอวัยวะภายในอุ้งเชิงกราน สามารถรักษาโดยการสังเกตอาการได้อย่างปลอดภัย

ในการผ่าตัดรักษาผู้ป่วย transpelvic gunshot wounds นั้นมีหลายสิ่งที่ต้องพิจารณา เนื่องจากเกิดการบาดเจ็บต่ออวัยวะต่างๆ หลายระบบร่วมกัน เช่น การที่มีหลอดเลือดได้รับบาดเจ็บร่วมกับ GI contamination, bladder injury ร่วมกับการที่มีหลอดเลือดได้รับบาดเจ็บร่วมกับ GI contamination, bladder injury ร่วมกับการบาดเจ็บของ rectal injury รวมทั้งการดูแลกระดูกเชิงกรานที่แตกจาก gunshot wound เพื่อให้ผู้ป่วยมีโอกาสเกิดภาวะแทรกซ้อนได้น้อยที่สุด

The Evolution of Reconstruction in Lower Extremity

Prof. Joon-Pio Hong

South Korea

The early history of lower extremity reconstruction dates back to Hippocrates (460-370 BC) and amputation and procedures trying to improve the success of amputation and survival has been the main practice up to World War I.

Although the term flap originated in the 16th century from the Dutch word *flappe*, meaning something hanging by one side, and the concept dates back as far as 600 BC when Sushruta Samhita described nasal reconstruction using a cheek flap, it was not until the First and Second World War that pedicled flaps were used extensively for reconstruction of the extremity. The next evolution came as surgeons started to use axial pattern flaps. The term “axial pattern” used to describe flaps with named pedicles was presented by McGregor and Morgan and this concept along with contributions from many surgeons led to the understanding of hemodynamic aspect of flap circulation. The first muscle flap for lower extremity coverage was first described by Stark for coverage of debridement sites for osteomyelitis but went unnoticed till Ger reported that the leg muscles were reliable for leg coverage with abundant blood supply. These progresses led to the distinction between axial and random flaps and muscle and musculocutaneous flaps which led to the introduction of free tissue transfer.

Prior to introduction of microsurgery, limitations existed to reconstruct large and extensive wounds including bone defects. With opening the era of microsurgery, tissue coverage for extensive and complex defects even after severe trauma and radical debridement, truly allowed advances in lower extremity coverage. In 1986, a landmark publication for reconstructive microsurgery in extremity was presented by Marko Godina where he established the principle of early debridement, free tissue transfer and aggressive rehabilitation to achieve functional limb after salvage. Based on this principle and advances made in the new millenium, treatment for infected wounds like osteomyelitis, complicated wounds such as diabetic foot ulcers and ischemic limb, and large defect after cancer ablation now turns routinely to soft tissue coverage using microsurgery. With respect to function, free functioning muscle transfer using rectus femoris muscle and gracilis

muscle and composite free flaps such as dorsalis pedis with extensor tendons or fibula osteocutaneous flaps may achieve acceptable functional results in extremity with composite defects. Innervated flaps utilizing microsurgical coaptation of nerves may help regain early protective sensation for sole reconstruction. Tissue expansion technique combined with or without microsurgery may allow coverage for large chronic defect or healed scars minimizing donor morbidity.(19) The most recent advances in flap surgery came in the 1990s with the introduction of perforator flaps. Koshima and Soeda described the use of an inferior epigastric artery skin free flap without rectus abdominis muscle for reconstruction. This implied reduction of donor site morbidity, being able to be tailored regarding thickness, and increased freedom of orientation of pedicle allowing more flexibility while providing coverage of the defect. Advances in wound healing science have synergistically made closure of lower extremity wounds more successful. The vacuum-assisted closure may provide stable temporary dressing which allows increased blood flow and decreased bacterial counts to allow better environment for flap coverage.

Currently, state-of-the art technologies in tissue engineering, genetic engineering, diagnostic technology, wound healing, limb transplantation, and supermicrosurgery will widen the possibility for increased salvage with better function and appearance. Nevertheless, the concept of soft tissue coverage with or without microsurgery will remain as an essential part of functional and cosmetic recovery for lower extremity reconstruction.

Use of Skin Substitute in Various Type of Wounds

รองศาสตราจารย์นายแพทย์ อภิชัย อังสพัทธ์

หน่วยศัลยศาสตร์ตกแต่งและเสริมสร้าง

ภาควิชาศัลยศาสตร์ คณะแพทยศาสตร์ จุฬาลงกรณ์มหาวิทยาลัย

ผิวหนังเป็นอวัยวะที่ใหญ่ที่สุดในร่างกายมนุษย์มีหน้าที่เป็นด่านแรกในการป้องกันการติดเชื้อโรค ป้องกันการสูญเสียน้ำ ช่วยควบคุมอุณหภูมิของร่างกาย และยังเป็นอวัยวะรับรู้ความรู้สึกที่สำคัญ(2) ความสมบูรณ์ของผิวหนังมีผลต่อการดำรงชีวิตอยู่ของมนุษย์ ถ้าผิวหนังมีการเสียหายหรือถูกทำลายไปเป็นจำนวนมาก เช่น ในแผลไฟไหม้ จะทำให้ผู้ป่วยพิการหรือเสียชีวิตได้จากการสูญเสียน้ำ เกือบแรม โปรตีนและจากการติดเชื้อ หรือถ้าผิวหนังมีการเสียหายที่ไม่มาก เช่น แผลเรื้อรังแผลเบาหวานที่เท้า ก็สามารถก่อให้เกิดความพิการและมีผลทำให้คุณภาพชีวิตของผู้ป่วยลดลง)

กระบวนการหายของแผลนั้นเกิดจากการทำงานร่วมกันของ epithelial และ mesenchymal cell โดยมี extracellular matrix ทำหน้าที่เหมือนเป็นโครงสร้างสำหรับการซ่อมแซมเนื้อเยื่อ การดูแลรักษาบาดแผลได้มีการพัฒนามาอย่างต่อเนื่อง โดยในปี ค.ศ.1871 Reverdin ประสบความสำเร็จในการปิดบาดแผลด้วย autologous skin graft ซึ่งได้กลายมาเป็นวิธีการปิดแผลที่ปฏิบัติกันจนถึงปัจจุบัน แต่ในผู้ป่วยที่สูญเสียผิวหนังจำนวนมาก เช่น ในผู้ป่วย massive burn หรือ มีความจำเป็นต้องตัดผิวหนังออกเป็นปริมาณมาก เช่น ในผู้ป่วย giant congenital nevi จะเกิดปัญหาในการปิดบาดแผลเนื่องจากมีผิวหนังที่จะเป็น donor ไม่เพียงพอ จึงได้มีการพัฒนาผิวหนังทดแทน (skin substitutes) เพื่อใช้ในการปิดบาดแผล ทั้งกรณีปิดแผลชั่วคราว หรือปิดแผลถาวร

ในช่วง 20 ปีที่ผ่านมา มีความก้าวหน้าทางด้านวิทยาศาสตร์และเทคโนโลยีที่ใช้ในการเพาะเลี้ยงเนื้อเยื่อเป็นอย่างมากซึ่งความรู้เหล่านี้นำมาสู่การพัฒนา bioengineered skin) โดยในปี ค.ศ.1975 Rheinward และ Green ประสบความสำเร็จในการเพาะเลี้ยง keratinocyte ในหลอดทดลอง และได้มีการพัฒนาขึ้นมาเป็นผิวหนังทดแทน (skin substitutes) ชนิดแรกคือ autologous keratinocyte sheet หรือ cultured epithelial autograft (CEA) แต่ยังใช้ปิดบาดแผลไม่ค่อยดีนัก เนื่องจากมีความเปราะบางมาก และเป็นเพียงชั้น epidermis โดยไม่มีชั้น dermis จึงทำให้เกิด wound contraction ได้มาก นักวิจัยจึงได้พยายามพัฒนาผิวหนังทดแทนที่มีส่วนประกอบของชั้น dermis เพื่อแก้ไขปัญหาที่เกิดขึ้น

Critical Limb Ischemia: Update on Endovascular Therapy

Venkatesh Ramaiah, MD, FACS

Medical Director - Arizona Heart Hospital

Director - Peripheral Vascular and Endovascular Research

Objectives:

- 1) Understanding the magnitude of the problem and the socio economic cost to society
- 2) Reviewing the data and limb salvage rates with traditional and endovascular approaches
- 3) Learning the current techniques and technology available to save limbs including latest endovascular options.

Chronic critical limb ischemia (CLI) occurs as a result of reduced arterial blood flow resulting in: (1) ischemic limb pain at rest, (2) non-healing ischemic ulceration, or (3) gangrene. CLI is a chronic condition that must be differentiated from acute limb ischemia, which is an acute medical emergency related to abrupt arterial occlusion requiring emergency treatment. The pathophysiology of CLI is related to inadequate arterial limb perfusion that is below the threshold needed to meet the metabolic demands of the limb, resulting in resting ischemia with skin breakdown and eventual tissue necrosis.

If untreated, gangrene ensues with the eventual loss of the limb (from amputation or mummification) and perhaps life (from sepsis). The severity of symptoms from limb ischemia may be classified using either the Fontaine or Rutherford schemes. Chronic CLI is associated with systemic atherosclerotic vascular disease involving the coronary and cerebral vascular beds. It is a progressive disorder associated with a high morbidity and mortality. As many as 24% of the patients with CLI will die within the first year after presentation. In addition to revascularization, atherosclerotic risk factor modification, lifestyle changes and pharmacological therapies must be aggressively implemented in this population to minimize morbidity and mortality. The optimal treatment for CLI is prompt revascularization.

In selected patients, percutaneous transluminal angioplasty (PTA) is the initial therapy of choice to avoid the morbidity associated with vascular surgery. Endovascular intervention does not preclude the possibility of subsequent sur-

gery, and in fact there is often a role for both modalities. In patients who are poor candidates for surgery, such as those with poor distal targets, a lack of adequate saphenous vein for bypass grafting, and those with severe medical comorbidities, endovascular therapy may offer the only opportunity for limb salvage.

The Bypass versus Angioplasty in Severe Ischemia of the Leg (BASIL) trial compared PTA with surgery in 452 patients with rest pain, ulceration or gangrene of the leg secondary to infra-inguinal disease. The primary end-point, amputation-free survival, was similar for PTA and surgery at 1 year (71% vs 68%, $p = \text{NS}$) and 3 years (52% vs 57%, $p = \text{NS}$) (Figure 2). Although there was no significant difference in mortality between the groups at 30 days, surgery was associated with a higher post-procedure morbidity. The mortality within the entire cohort over the course of the study (5.5 years) was 37%, which underscores the poor prognosis due to cardiovascular diseases of patients who present with CLI. During the initial hospitalization, almost three times as many patients treated with surgery required admission to the intensive care or high dependency unit compared to those treated with angioplasty (27% vs 7.5%), which resulted in the cost of hospitalization being higher in the surgical group. PTA was associated with a higher immediate failure rate and 12-month re-intervention rates in the BASIL study. This did not affect the patients' candidacy for a second percutaneous procedure or subsequent surgery. Post hoc analysis demonstrated that surgery was associated a lower rate of amputation and death (hazard ratio 0.34, CI 0.17-0.71) in patients alive at 2 years with the treated limb intact. The authors suggested that healthier patients (i.e. those with a life expectancy exceeding 2 years) may benefit from surgical intervention as an initial therapy for limb-threatening ischemia. BASIL demonstrated that endovascular therapy and surgery were comparable as first-choice therapy for CLI, but that PTA was less expensive and did not preclude subsequent treatment with surgery. Therefore, PTA should be chosen first if a patient is a candidate for either procedure, particularly if the patient's life expectancy is less than 2 years and death (hazard ratio 0.34, CI 0.17-0.71) in patients alive at 2 years with the treated limb intact.

The authors suggested that healthier patients (i.e. those with a life expectancy exceeding 2 years) may benefit from surgical intervention as an initial therapy for limb-threatening ischemia.

BASIL demonstrated that endovascular therapy and surgery were comparable as first-choice therapy for CLI, but that PTA was less expensive and did not

preclude subsequent treatment with surgery.

Therefore, PTA should be chosen first if a patient is a candidate for either procedure, particularly if the patient's life expectancy is less than 2 years.

Endovascular Therapy:

Endovascular treatment has indeed become the primary line of treatment in CLI. The latest endovascular techniques and modalities will be discussed. Available data on these modalities will be highlighted. A brief synopsis of how we manage patients with critical limb ischemia AT Arizona Heart Institute and our results will be presented.

Evar for Ruptured AAA

Venkatesh Ramaiah, MD, FACS

Medical Director - Arizona Heart Hospital

Director - Peripheral Vascular and Endovascular Research

Objectives:

1) Understanding the mortality and morbidity associated with rupture and results of open surgical repair

2) Evolution and Acceptance of EVAR and Supporting Data

3) Tips and Tricks and Establishing a Ruptured AAA Program

In recent years, major improvements have been made, making elective repair of abdominal aortic aneurysms (AAA) a safe procedure. In selected series, mortality rates are less than 5% (1). Many of the patients with AAA, however, remain asymptomatic until they present with rupture (2). Once rupture has occurred, the overall mortality approaches 90% (3, 4). Despite many advances in the management of ruptured AAA, the mortality rate of conventional open surgery has not improved significantly during the last 50 years and remains around 48% (5). Over the last decade, endovascular techniques have been used increasingly to repair AAA, and there is now evidence that elective endovascular aneurysm repair (EVAR) is technically feasible and safe for AAA exclusion (6, 7, 8), with a reduced physiological impact (9, 10). Two recent randomized studies have demonstrated that EVAR can be performed on good risk and asymptomatic patients with less perioperative mortality than conventional surgery (11, 12). The feasibility of EVAR for ruptured AAA was proven in a case report by Yusuf et al in 1994 (13). Since then there have been reports from specialized vascular units limited to selected and stable patients. A variety of aortic ruptures have been included, such as aorto-caval, aorto-renal vein and enteric fistula, ruptured false aneurysms following open repair. Recently, larger series (14, 15, 16) and prospective studies (17, 18) have been reported, showing that EVAR could offer another option to patients with a ruptured AAA.

Endovascular Management of Deep Venous Thrombosis

Venkatesh Ramaiah, MD, FACS

Medical Director - Arizona Heart Hospital

Director - Peripheral Vascular and Endovascular Research

Objectives:

- 1) Understanding the magnitude and pathophysiology of DVT
- 2) Learning the indications for intervention
- 3) Review of Current Endovascular modalities and relevant data

Deep vein thrombosis (DVT) is a manifestation of venous thromboembolic (VTE) disease. VTE encompasses both DVT and pulmonary embolism (PE). DVT itself refers to thrombus which has formed in the deep veins of the body which usually parallel an artery of the same or similar name and follow a deep course within an extremity. Formation of thrombus in these vessels frequently results in local and systemic complications leading to significant morbidity and mortality. The Acting Surgeon General Steven K. Galson, MD, MPH, recently released a call to action to reduce the number of cases of DVT and pulmonary embolism in the United States, stressing that collectively DVT and PE contribute to at least 100,000 deaths each year.¹

An often overlooked yet significant complication of DVT is the post-thrombotic syndrome (PTS - formerly postphlebitic syndrome). PTS is characterized by chronic pain and swelling in the affected limb. PTS patients are considered a subset of those with chronic venous insufficiency. They are prone to the skin changes of chronic venous stasis disease, namely hyperpigmentation, lipodermatosclerosis, and atrophie blanche. In the most advanced cases, venous stasis ulcers may occur. Overall, PTS leads to lower quality of life.^{2,3}

This article focuses on the epidemiology and treatment of DVT and PTS, including the most recently updated management guidelines from the American College of Chest Physicians (ACCP 2008) and the Acute Venous Thrombosis: Thrombus Removal with Adjunctive Catheter-Directed Thrombolysis Trial. The goal is to enable the reader to understand the appropriate management of DVT and recognize the indications for more aggressive treatment of acute symptomatic DVT.

Epidemiology

Approximately 350,000 individuals are affected by DVT/PE each year in the United States. Many cases are not recognized and the actual number of cases could be twice as high.¹ Studies show that patients with PE demonstrate a 3 month all-cause mortality of 15% to 30%.^{1,4,5} As many as 4% of patients with PE will progress to chronic thromboembolic pulmonary hypertension (CTEPH).⁶ PTS will affect nearly 30% of individuals with DVT over a five-year period.⁷ It is estimated that the annual direct cost in the United States for PTS is \$200 million, with an indirect cost of 2 million lost work days annually due to leg ulcers.⁸

Ultrasound studies have shown that patients with symptomatic venous thromboembolism are most likely to have DVT in the proximal deep veins of the legs; however, only 11% will have upper extremity clot and 15% will have isolated calf DVT.⁹ There is general agreement that proximal or iliofemoral distribution DVT is clinically significant and warrants treatment with anticoagulation and or more aggressive measures for severe cases; however, there is with less uniform agreement on the management of calf or infrageniculate DVT.¹⁰ Furthermore, patients with an initial episode of symptomatic DVT are at high risk for recurrent episodes. In a study of 355 patients followed for 8 years after a symptomatic DVT, the cumulative incidence of recurrent VTE was 17.5% after 2 years, 24.6% after 5 years, and 30.3% after 8 years.¹¹ Recurrence rates are higher if there is residual thrombus in the vessel.¹² Recurrence, particularly of ipsilateral DVT, is a strong risk factor for PTS.^{2,7} The cumulative incidence of PTS in these patients increased likewise from 22.8% at 2 years to 29.1% at 8 years.

Diagnosis and Medical Management of Acute Pulmonary Embolism

Asst. Prof Nattapong Jaimchariyatam, MD, MS, FCCP

Acute pulmonary embolism (Acute PE) is not uncommon and is often fatal condition. It is a relatively common cardiovascular emergency. Emboli may lead to acute life-threatening condition with potentially reversible right ventricular failure. The most common cause is thrombus which originated elsewhere in the body, less common causes include air bubbles, fat droplets, or tumor and parasites (this topic will focus on acute PE due to thrombus). It can be easily classified into massive, submassive and small PE with pulmonary infarction. Massive PE causes hypotension associated with right ventricular dysfunction (RVD), PE associated with RVD but hypotension will be classified as submassive PE. Nevertheless, acute pulmonary embolism, unfortunately, usually manifests non-specific and highly variable symptoms including dyspnea, cough, hemoptysis, chest pain, or syncope, rendering accurate diagnosis more difficult. Thus, additional tests are helpful to further confirm or exclude diagnosis of acute PE. Acute PE is found to be associated with mortality rate of approximately 30% without treatment, primarily due to recurrent emboli. However, the mortality rate can be reduced to 2 to 8% in case with prompt diagnosis and appropriate treatment.

When acute pulmonary embolism is suspected, the patient should undergo appropriate tests. The modified Wells criteria should also be applied to determine whether PE is likely (score \geq 4) or unlikely (score \leq 4). On the other hands, Wells score can be used to classify PE into high clinical probability (score \geq 6), moderate clinical probability (score 2-6), and low clinical probability (score \leq 2). The criteria includes deep vein thrombosis [DVT] (3 points), other diagnosis less likely than PE (3 points), heart rate \geq 100 (1.5 points), immobilization \geq 3 days or surgery in previous four weeks (1.5 points), previous DVT/PE (1.5 points), hemoptysis (1 point), and malignancy (1 point). The patients classified as PE unlikely should undergo D-dimer testing with a quantitative rapid ELISA assay or a semiquantitative latex agglutination assay. The diagnosis of PE can be excluded if the D-dimer level is $<$ 500 ng/mL or negative. The patients classified as PE likely and patients

classified as PE unlikely who have a D-dimer level >500 ng/mL should undergo computer tomography pulmonary angiography (CTPA). A positive CTPA confirms the diagnosis of PE and negative CTPA may exclude PE. Ventilation-perfusion lung scan (V/Q scan) is alternatively used in patients with contraindication for undergoing CTPA or in the setting of CTPA unavailability. Normal V/Q scan, or low probability V/Q scan plus low clinical probability can exclude PE; since high probability V/Q scan plus high clinical probability confirm PE. In rare situation in which CTPA and/or V/Q scan is inconclusive, other modalities including pulmonary angiography may be helpful to further investigate. In cases of massive PE, hypotensive state may prevent patients from obtaining CTPA or V/Q scan. Accordingly, echocardiography is increasingly utilized to confirm diagnosis of PE, particularly in hypotensive state where CTPA or V/Q scan may not be suitable candidate.

When the patient is suspected for acute PE, initial management should focus on stabilize patients in terms of oxygenation and hemodynamics. Oxygen supplementation, intravenous fluid and vasopressor administration should be prompt, when appropriate. Anticoagulation is the mainstay therapy for acute PE. When the diagnostic tests confirm PE, the patient should prompt initiation of anticoagulation therapy; however, empirical anticoagulant therapy is sometime initiated during the process of diagnosis and resuscitation depending on the likelihood of PE and risk of bleeding. Thrombolytic treatment is often indicated in the setting of massive or refractory submassive PE. Patients who fail thrombolysis or have contraindications to thrombolysis, should undergo catheter or surgical embolectomy. Long term anticoagulant therapy usually depends on risk for recurrent PE. The inferior vena cava filter is alternatively option for patients with acute PE who have a high risk for bleeding, complications of anticoagulation, or recurrent PE despite adequate anticoagulation.

Mediastinal Traverse

Kenneth L. Mattox

Distinguished Service Professor

Michael E. DeBakey Department of Surgery, Baylor College of Medicine

Chief of Staff/Chief of Surgery, Ben Taub General Hospital, Houston, Texas

The majority of patients with gunshot wounds traversing the mediastinum die prior to arrival at treatment facilities or are hemodynamically unstable upon presentation. These arriving unstable require an immediate thoracotomy via an incision deemed to be the most expeditious based on the initial imaging studies. In general, incision is made on the side with the most severe injury. For stable patients with mediastinal traverse, a methodical workup is done to determine if an operation is needed, position for surgery, incision choices, and treatment options.

IPOM

พญ.กนกกาญจน์ เทพมาลัย

ศส.บพ.สุเทพ อุดมแสงกรัพย์

ภาวะไส้เลื่อนบริเวณหน้าท้องที่เกิดตามหลังการผ่าตัดที่หน้าท้องเจอได้บ่อยในเวชปฏิบัติ หากปล่อยทิ้งไว้ไม่ได้รับการรักษาอาจเกิดภาวะลำไส้ติดค้าง เน่าหรืออุดตัน และมีการขยายขนาดของรูดังกล่าวได้ การรักษาเดิมใช้วิธีการผ่าตัดแบบเปิดแผลที่หน้าท้องและทำการเย็บซ่อมเนื้อเยื่อให้ติดกันใหม่ ซึ่งโอกาสการเกิดเป็นซ้ำค่อนข้างสูง ต่อมาได้มีการพัฒนาผนังหน้าท้องเทียม (mesh) ขึ้นทำให้ลดโอกาสการเกิดเป็นซ้ำลงได้ มีวิธีการวางผนังหน้าท้องเทียมหลายแบบ ขึ้นอยู่กับตำแหน่งเมื่อเทียบกับกล้ามเนื้อหน้าท้อง โดยตำแหน่งที่นิยมคือการวางผนังหน้าท้องเทียมไว้เหนือ (onlay) หรือใต้ (underlay) ต่อกลิ้ามเนื้อหน้าท้องซึ่งสามารถทำได้ทั้งการผ่าตัดแบบเปิดและการผ่าตัดแบบส่องกล้อง ปัจจุบันพบว่าการทำผ่าตัดผ่านกล้องสามารถลดความเสี่ยงของอัตราการเกิดแผลติดเชื้อ ลดความเจ็บปวดและมีการฟื้นตัวได้เร็วกว่า และหากเกิดการบาดเจ็บของลำไส้ขณะผ่าตัดก็สามารถตรวจพบพร้อมกับซ่อมแซมได้ง่ายกว่า นอกจากนี้ ยังสามารถจะมองเห็นรูไส้เลื่อนอื่น (Swiss-cheese) ที่ตรวจร่างกายไม่พบได้ ปัจจุบันการผ่าตัดซ่อมภาวะไส้เลื่อนผ่านกล้องจึงเป็นที่นิยมเพิ่มมากขึ้น

เทคนิคการผ่าตัดไส้เลื่อนหน้าท้องโดยวิธีการส่องกล้อง ประกอบไปด้วยการจัดวางport ที่เหมาะสมเพื่อให้การผ่าตัดราบรื่น เนื่องจากส่วนใหญ่แล้ว ผู้ป่วยไส้เลื่อนหน้าท้องมักจะผ่านการผ่าตัดและอาจจะมีพังผืดในช่องท้องจำนวนมาก ซึ่งทำให้การใส่เครื่องมือ (port) เข้าไปในช่องท้องทำได้ยาก เทคนิคการใส่ port แรกจึงเป็นสิ่งสำคัญและต้องระมัดระวังการบาดเจ็บของลำไส้ ตำแหน่งของเครื่องมือควรจะอยู่ไกลที่สุดจากผนังหน้าท้องส่วนที่เป็นปัญหาเพื่อให้การวางและทำการยึดติดผนังหน้าท้องเทียมได้ง่าย การตัดเลาะพังผืดในท้องและการเลาะส่วนลำไส้กลับเข้าไปในช่องท้องเป็นขั้นตอนที่ใช้เวลานาน ต้องอาศัยความระมัดระวังในการตัดเลาะ แนะนำให้ใช้กรรไกรและลดการใช้เครื่องมือความร้อนชนิดต่างๆ เพื่อป้องกันการเกิดอันตรายต่อลำไส้ หลังจากนั้นจึงทำการวัดขนาดรูไส้เลื่อนทั้งหมด แล้วทำการเลือกขนาดของผนังหน้าท้องเทียม โดยจะต้องให้มีขนาดใหญ่กว่ารูไส้เลื่อนและทับซ้อนเนื้อเยื่อที่ปกติด้านละ 3-5 ซม. เป็นอย่างน้อย

เพื่อป้องกันการกลับเป็นซ้ำ ภายหลังการทำผ่าตัดทั้งแบบเปิดและแบบส่องกล้องสามารถจะเกิดseromaขึ้นได้ทั้งสองวิธี แต่เนื่องจากการผ่าตัดแบบส่องกล้องมักจะได้ไม่ไฝ่ที่อธิบายหลังการผ่าตัด จึงทำให้มีการสะสมของน้ำเหลืองได้มากกว่า แต่ส่วนใหญ่มักจะหายได้เองภายในเวลา 6-8 สัปดาห์ ผู้ป่วยบางรายอาจจะมีความรู้สึกเจ็บได้ตรงจุดที่มีการใช้ไหมเย็บผูก(transfix suture) ซึ่งมักจะดีขึ้นเอง และได้ผลดีด้วยการใช้ยาแก้ปวด (NSAIDs) หรือการฉีดยาชาเฉพาะที่ แม้ว่าราคาของผนังหน้าท้องเทียมจะมีราคาสูงในประเทศไทย แต่ระยะเวลาในการนอนโรงพยาบาลและการฟื้นตัวของผู้ป่วยเป็นไปได้เร็วกว่า จึงทำให้ค่าใช้จ่ายโดยรวมไม่ต่างกับการผ่าตัดแบบเปิดมากนัก ในอนาคตการพัฒนาวัสดุผนังหน้าท้องเทียม อุปกรณ์ที่ใช้ยึดติด หรือการพัฒนาเทคนิคใหม่ๆ อาจจะช่วยลดอัตราการเกิดเป็นซ้ำ และอาจทำให้ผู้ป่วยมีผลการรักษาที่ดีขึ้นได้

Gastric Plication

Panot Yimcharoen, MD

Bhumibol Adulyadej Hospital

When we talk about bariatric surgery, we think about Adjustable gastric banding, Laparoscopic Sleeve gastrectomy (LSG) or laparoscopic Roux-En-Y gastric bypass (LRYGBP). Now we have heard about gastric plication (GP) which is the one procedure become more popular in this era. Actual name of GP is laparoscopic greater curve plication (LGCP). However, many bariatric surgeons feel this title is overstated. Other simpler terms include gastric pleat and gastric imbrication. This procedure is attracting patients around the world due to no stomach stapling or removal, no bypass, no foreign body (i.e.band), potentially reversible or modifiable to another procedure if need. Furthermore this operation is lower cost than other bariatric procedures, reduces the chances for vitamin deficiency and short hospital stay. The main drivers in this practice are to lower costs, improve outcomes and reduce side effects.

Patients seem to intuitively understand that there should be fewer leaks with this technique over a LRYGBP or a LSG. Patient selection criteria for GP are very similar to those for sleeve gastrectomy. In Brazil, surgeons do not perform GP on patients with a BMI greater than 50 kg/m^2 because they feel that without malabsorption the patients will not be able to lower their high BMIs to acceptable levels. Ramos et al., 42 patients which means BMI 41 kg/m^2 , reported that mean operative time 50 minutes, length of stay (LOS) 36 hours without major complications, mean excess weight loss (EWL) was 62% at 18 months. In Greece, Skrekas et al., 135 patients who underwent GP which mean operative time was 40-50 minutes and LOS was 1.9 days, showed EWL 65% with mean follow up time was 22 months. In 2007, 100 cases of GP with long term follow up 4 years, this series which have been reported by Talebpour M. who is pioneer in GP, he used term “Laparoscopic Total Gastric Vertical Plication (LTGVP)”, he found that mean EWL was 55%. And he also reported 12 years experiences of GP 800 cases in 2012, mean EWL was 70% and 55% at 24 and 60 months respectively. Major complication rate was 1.6% and 1% reoperation (perforation and obstruction). Shen et al., prospective non-randomized study comparison between GP and LSG, reported only operative cost was less than LSG but EWL and loss of hunger

were not better than LSG. But animal study, Guimaraes et al., SG compared to GP and they found no difference in weight loss but GP group displayed lower body fat content and leptin levels compared to control.

In conclusion GP appeared to be an effective emerging bariatric procedure for the treatment of obesity. Early postoperative complications are minimal, without any important late complications and major complication rate was acceptable. Variations in technique need to be addressed and GP should be considered investigational at present. Longer term outcomes data are needed to assess its potential and risk profile.

Pancreatic Surgery in the Digital Era

Anusak Yiengpruksawan, M.D., FACS, FRCST (Hon.)

USA.

Surgery has entered a new era with the introduction of the daVinci robotic system. This new technology has, for the first time, integrated digital or information technology into the surgical analog platform. Whether or not this technology is considered or will lead to the paradigm shift in surgery will be the main focus of this talk. The speaker uses pancreatic surgery as an example since it is best suited for robotic application. Topics of discussion will range from advantages of robotic pancreatectomy compare to laparoscopic approach, application of this technology in training, teaching, and networking among institutions, to future direction of digital surgery.

The American College of Surgeons, Quality and Surgical Care: Liver Surgery as a Paradigm

John M. Daly

Vice-President, American College of Surgeons,
USA.

Throughout its history, the American College of Surgeons (ACS) has espoused quality in patient care, education and research. The American healthcare system is undergoing major changes whereby pay for performance and quality indicators are becoming transparent to medical personal and patients alike. The ACS is leading the medical profession in setting standards, creating new paradigms of care, creating risk-adjusted benchmarks and educating practicing surgeons and surgeons of the future.

One area of surgical care is that of the treatment for patients with meta-static colorectal cancer. The evaluation, operative management and postoperative multidisciplinary care of these patients are described.

Quality of surgical care, professionalism, communication and continuing education are the hallmarks of the American College of Surgeons and its programs.

The Art & Science of Oncoplastic Breast Surgery

Dr. P. Raghu Ram

MS, FRCS (Edin), FRCS (Eng), FRCS (Glasg), FRCS (Irel)

Director & Consultant Oncoplastic Breast Surgeon

KIMS - USHALAKSHMI Centre for Breast Diseases, Hyderabad, India

Breast Surgery is now a recognized subspecialty of General Surgery abroad with structured training for designated 'Oncoplastic Breast Surgeons'. Oncoplastic Breast surgery is probably one of the most interesting and challenging new developments over the past 20 years - it is an innovative and sophisticated subspecialty within Breast Surgery, and equally, an essential skill for the dedicated Breast Specialist.

Oncoplastic surgery should not be confused with breast reconstructive surgery after mastectomy. Oncoplastic Breast Surgeon requires the combination of knowledge in three different specialties: Surgical oncology, Plastic surgery and Breast radiology. The aims of Oncoplastic breast surgery are wide local excision of the cancer coupled with partial reconstruction of the defect to achieve a cosmetically acceptable result. Avoidance of mastectomy and consequent reduction of psychological morbidity are the principal goals in the development of various oncoplastic techniques.

The use of plastic surgical techniques not only ensures good cosmetic outcome, but also allows the surgeon to remove the tumour with greater volume of surrounding tissue, thus extending the boundaries of breast conserving surgery. Proper patient selection and careful planning after proper radiological and clinical assessment are the two essential prerequisites before undertaking oncoplastic breast surgery. Oncoplastic surgery involves both volume displacement and volume replacement techniques. The need for adjustment of contralateral breast should also be anticipated at the time of planning breast conserving surgery, which can be done either at the same time as breast cancer surgery or as a delayed setting.

In this era of Oncoplastic breast surgery, it would be unreasonable to remove a breast lesion and allow a seroma to fill the wound resulting in subsequent deformity. There is clearly a growing demand for cosmetically acceptable breast conserving surgery the world over. Breast cancer surgery must be carried out with due consideration to cosmetic outcome without oncological compromise as disfiguring and mutilating excisions are neither justified nor acceptable.

Abstracts
July 22, 2013

Innovation in Surgical Education: Procedure Based Assessment in Surgical Training

Chalermpong Chatdokmaiprai

Plastic Surgery Division, Department of Surgery, Faculty of Medicine at Ramathibodi Hospital, Mahidol university

PBA (procedure based assessment) is a tool for assessing the competency of surgical trainees in terms of clinical skills (factual knowledge, psychomotor, decision making and communication skills). The modern surgical training is not to produce well-rounded surgeons who are capable of multi-field operation, but, instead, to train the surgeons who are competent in the more specific field as well as organizing the members of operative theater. And the PBA is the tool to assess these capability with the prompt feedback to the trainees

To develop each PBA is crucial, demanding brain storm, knowledge and the agreement to mandate the PBA as the universal assessment tool. This tool also requires the validity and should be collected as the formative evaluation which is easily to retrieved and analyzed regularly by the training program director. Without agreement to have this mandatory assessment, PBA will never be possible.

In conclusion, PBA is a tool in order to facilitate the training program, not to make more difficult assessment.

Radiation Concern in Endourologic Surgery

Bannakij Lojanapiwat, M.D.

Professor of Urology
Chiangmai University

International Commission on Radiation:-

The occupation limit of radiation expose is 20 msv / yr over 5 year on average which no more 50 msv in any year. The limited dose of skin / extremity is 500 msv and the len of eye is 150 msv.

Factors of radiation induced malignancy risk are sex, age of exposure ,amount of radiation and life expectancy.

Factor effect fluoroscopic time (FT): Reduction of FT is female, distal ureteral stone and feedback system and the increase of FT is presence of hydro-nephrosis (URS), ureteral access sheath usage, ureteral balloon dilatation and placement of ureteral stent.

Prevention is very important

- Feedback system:-After receive feedback; Fluoroscopic time decrease 24% during URS.
- Protocol of the as-low-as-reasonably achievable (ALARA) principle
- Use some technique such as visual and tactile guidance (Fluoroless URS, PCNL).

Conclusion

- The awareness of hazard effect of radiation exposure for surgeon and team, minimizing the radiation exposure is very important.
- Patients with calculi usually received ionizing radiation studies during pre-operative, intraoperative, postoperative studies.
- Feedback system and protocol of the as-low-as-reasonably achievable (ALARA) principle is one the key of reduction radiation
- Fluoroless URS and ultrasound guide PCNL are the alternative technique for reduction the radiation exposure.

HOW DO I DO IT? [Laparoscopic Nephrectomy, Cystectomy, Prostatectomy, Percutaneous nephrolithotomy (PCNL), Ureterorenoscopy (URS)]

Tanet Thaidumrong, MD

Section of Urology, Division of Surgery, Rajavithi Hospital, Bangkok, Thailand

In the era of laparoscopic and endoscopic urology, urologists have moved toward from tradition of open surgery approach to minimal invasive approach. To date, numerous article and literature have been report about technique and efficacy in laparoscopic and endoscopic surgery that can be benefit same or superior to traditional open surgery.⁽¹⁻¹¹⁾ Before those changes can be come available, surgeon must be gain experience to develop the new technique with less morbid treatment for disease. The most of the operation with laparoscopic and endoscopic surgery can be record with video recorder. This element is more important to review your operative technique and complication that can be improve your experience in laparoscopic and endoscopic urology. This video session will be share my experience in laparoscopic and endoscopic urology especially, critical and important step on each procedure in laparoscopic and endoscopic urology. Laparoscopic nephrectomy I was preferred transperitoneal approach because excellent visualization of anatomic landmark and large workspace. The procedure are include: trocar placement, incise the line of Toldt and mobilize the colon, identify and secure the ureter, mobilized the lower pole kidney within Gerota's fascia. secure the hilar vessel, dissect upper pole and lateral attachments, divide the ureter, entrap the specimen, remove specimen through a small incision, and closed the incision. Laparoscopic radical cystectomy procedure include; trocar placement, bilateral pelvic lymph node dissection, identify both ureter and ligation, dissect posterior aspect of bladder until apex of prostate gland, ligation of bladder and prostate vascular pedicle, created Retzius space, control dorsal vein complex, transection of urethra to complete radical cystectomy, entrap the specimen, remove specimen through minimal incision of umbilicus. The urinary diversion procedures are perform extracorporeal through mini incision of umbilicus except total intracorporeal urinary diversion procedures are perform in selected case.⁽⁷⁾ Laparoscopic radical prostatectomy i was preferred extraperitoneal ap-

proach because this approach don't disturb intestine that made patient is early to return normal intestinal function. The procedures after create Retzius space and trocar placement are include; identify and dissect bladder neck, open bladder neck, dissect seminal vesicle and vas deference, posterior prostate dissection, control vascular pedicle and neurovascular bundle preservation, control dorsal vein complex, prostatic apical dissection and division of urethra, vesicourethral anastomosis, insert Foley catheter, insert tube drain, entrap specimen and remove through mini incision, and close incision.⁽⁸⁾ PCNL procedure include; cystoscopy and insert ureteric catheter, access percutaneous tract under fluoroscope, dilate tract by metal dilator, insert ampuz sheath, insert nephroscope, identify stone and perform lithotripsy.⁽¹⁰⁾ URS procedures are include; cystoscopy ,identify the ureteric orifice, dilated ureteric orifice over guide wire, insert ureteroscope, identify ureteric stone, remove stone by stone basket or lithotripsy by Holmium LASER. The gold of this video session is to share experience in different operative techniques learned through repetition, mistakes, and perseverance. I hope this session will be benefit for improve the surgical technique to treat our patient in the future.

References

1. Dunn MD et al. Laparoscopic versus open radical nephrectomy: a 9-year experience. J Urol2000;164:1153-1159
2. Cathelineau X, Arroyo C, Rozet F, Barret E, Vallancien G. Laparoscopic assisted radicalcystectomy: the montsouris experience after 84 cases. EurUrol 2005;47:780-4.
3. Gaston R, Heidenreich A. Open versus laparoscopic radical cystectomy. EurUrolSuppl2006;5:385-94.
4. Gaston R, Barmoshe S, Pansadoro A, Lufuma E, Mugnier C, Hoepffner JL, et al. Laparoscopic radical cystectomy: review 100 cases. EurUrolSuppl 2006;5: 23.
5. Guillonneau B, Vallancien G. Laparoscopic radical prostatectomy: the Montsouris technique. J Urol 2000;163:1643-9.
6. Thaidumrong T, Akarasakul D, Doungkae S. Laparoscopic radical prostatectomy technical aspects and experience with 100 cases in Rajavithi Hospital. J Med Assoc Thai 2011;94 (Suppl 2):S29-34.
7. Thaidumrong T. Laparoscopic Radical Cystectomy with Total Intracorporeal Ileal Neobladder: First Case Report in Thailand. J Med Assoc Thai

2013;96 (Suppl. 3);S109-113.

8. Basiri A, Ziaee AM, Kianian HR, et al. Ultrasonographic versus fluoroscopic access for percutaneous nephrolithotomy: a randomized clinical trial. J Endourol 2008;22:281-4.
9. Preminger GM, Assimos DG, Lingeman JE, et al. Chapter 1: AUA guideline on management of staghorn calculi: diagnosis and treatment recommendations. J Urol 2005;173(6):1991-2000.
10. Miller NL, Matlaga BR, Lingeman JE. Techniques for fluoroscopic percutaneous renal access. J Urol 2007;178:15-23.
11. Preminger GM, Tiselius HG, Assimos DG, et al. 2007 guideline for the management of ureteral calculi. J Urol 2007;178:2418-34.

Crew Resource Management: Are the Lessons Applicable to Surgery?

K.D. Boffard

Professor and Head of Surgery

Charlotte Maxeke Johannesburg Academic Hospital

University of the Witwatersrand,

Johannesburg, South Africa.

Crew Resource Management has been defined as “the ability to turn a potentially dangerous situation or environment into a safe one, by a combination of risk management, crew management including crew interaction, and environmental management”.

The flying environment has many similarities to that of the surgical environment, including the use of surgical checklists, staff interaction, and high stakes, including death, should something go wrong. For that reason there has been a large degree of exploration of the similarities between Crew resource management in the flying environment and the philosophies of the management applied to the surgical environment.

These similarities and differences will be explored, and ways in which the philosophy of the pilot’s environment can be brought into that of the surgeon’s will be discussed.

Resuscitation and Interventional Radiology

Ian Civil

Immediate Past President, Royal Australasian College of Surgeons

Innovations in resuscitation and developments in interventional radiology have seen both areas of practice converge in the area of stabilisation and haemostasis in the trauma patient. Resuscitation is no longer just a matter of getting the right amount of volume into a patient to restore circulation. Recognising that coagulopathy is part of the presenting biochemistry of patients with severe trauma and shock, resuscitation is increasingly being cognisant of point of care coagulation testing and resuscitating patients with products designed to address the specific deficiencies in their coagulation profile. This approach may deal with each patient as a individual or the data in general may be used to establish a massive transfusion protocol which, when activated, will see patients resuscitated with appropriate proportions of red cells and components of the coagulation cascade and may include tranexamic acid.

Interventional radiology is also changing dramatically, with technologies available to recognise and treat bleeding in many different areas of the body in a prompt and less invasive way than with traditional open surgery. Point of care radiology and immediate targeted intervention can see early arrest of haemorrhage, decrease in the need for volume infusion, and a decrease in the collateral damage (ARDS, TRALI, ACS) previously seen in massive haemorrhage.

These new paradigms of care are dramatically changing the way trauma patients are approached in the Emergency Department and are making different demands on hospital infrastructure and personnel. More than ever, Trauma Committees, team leaders, and pre-emptive decision-making are required to maximise the benefits inherent in these advances.

Critical Judgement in Trauma: Do or Die.

K. D. Boffard

Professor and Head of Surgery
Charlotte Maxeke Johannesburg Academic Hospital
University of the Witwatersrand,
Johannesburg, South Africa.

“Good judgement comes from experience; experience comes from bad judgement”

In the trauma environment time is of the essence, and it is not always possible within the time available, to fully explore the possibilities or analyse what might be wrong. In many situations the surgeon is faced with the situation of “Any decision is better than no decision at all”.

Cases which fall into this situation will be analysed with audience participation.

Principles of Liver Surgery

Prof. Riccardo A. Superina

Robert E. Schneider Chair in Transplantation

Professor of Surgery

Division Chief, Transplant Surgery

Co-Director, Siragusa Transplant Center, USA

General surgery has been progressively undergoing sub specialization- for the last several decades. Fields now include colorectal, oncological, head and neck and hepato-biliary surgery. For pediatric surgeons to consistently deliver excellence in outcomes in children with complex hepatobiliary problems comparable to what adult hepatobiliary surgeons may deliver, it is postulated that further training may be necessary than what is normally possible in a two year fellowship. In order to improve surgical skills, great familiarity is needed with hepatic anatomy including segmental and sectoral nomenclature, and how to access venous, biliary and arterial structures in their normal and their more common variations in a predictable and atraumatic fashion.

Decisions about major resections for tumors must be made in the context of when to referral for possible transplantation, and resection of advanced tumors involving three or even four sections should ideally be made by the same team who performs the transplants. Most pediatric surgery fellowships offer limited opportunities to become involved with many liver resections because of the diffuse nature of where patients are referred. Reconstructive procedures for portal venous hypertension require knowledge of the internal anatomy of the portal vein as well as expertise in fine vascular anastomosis.

Common causes for biliary reconstructions include those for iatrogenic injuries of the common hepatic ducts, choledochal cysts with possible bile duct anatomical abnormalities, and bile leaks following major resections for tumors.

Many of the techniques necessary for successful outcome in complex non-transplant hepatobiliary surgery are learned during liver transplantation on children. Reduction and split liver techniques allow the pediatric surgeon to become familiar with the liver in ways that would not otherwise be possible. Vascular reconstructive techniques in vessels less than 5 mm in diameter have become

13.30-15.00	S	Banbung
-------------	---	---------

commonplace and may be required in non-transplant cases. Furthermore, improved results have been linked to a higher volume of cases performed. Cases like biliary atresia, liver resections and biliary and vascular reconstructive procedures should be limited to as few centers as possible in order to ensure that these designated centers have the opportunity to benefit the most number of patients possible. This will ensure that the most appropriate procedures are done with the best outcomes and at the lowest possible cost.

The Progress of Neonatal Surgery in Osaka

Akio Kubota

Professor of Pediatric Surgery

Second Department of Surgery, Wakayama Medical University, Japan

According to a national survey on neonatal surgery carried out every five years by the Japan Society of Pediatric Surgeons since its foundation in 1964, in all of the past four surveys the three disorders with the highest mortality have been congenital diaphragmatic hernia (CDH), omphalocele (OMC), and gastrointestinal perforation. To these we can add congenital functional intestinal atresia (Hirschsprung disease and related conditions), an uncommon condition of unknown clinical pathology for which no treatment has yet been found, as constituting the four most important disorders for neonatal surgery, and we have been working to discover their pathophysiology and improve their therapeutic outcomes. The increased use of prenatal diagnosis for CDH and OMC, as well as the sudden increase in the birth of extremely low birth weight (ELBW) infants, are both significantly affecting both therapeutic outcomes and the frequency with which these conditions occur. This phenomenon is a hitherto unprecedented experience for practitioners of perinatal medicine, and raises some serious problems.

In CDH, dramatic improvements in therapeutic outcomes have been obtained as a result of the application of respiratory and circulatory management methods for congenital heart disease. At the same time, serious ethical issues are currently being raised concerning the prenatal prediction and fetal diagnosis and treatment of extremely severe cases that could not be saved by post-natal treatment. OMC is the only disorder for which the death rate has actually risen during the past five years. Methods of treating severe cases must be developed, and prenatal diagnosis and ethical issues may again be coming into question. The high mortality from gastrointestinal perforation is probably the result of an increase in the absolute number of ELBW infants owing to dramatic improvements in the number and survival rate of such children, meaning that the frequency of three ELBW-specific conditions - necrotizing enteritis (NEC), focal intestinal perforation (FIP), and meconium-related ileus (MRI) - has also increased. Formerly, abnormal bacterial flora in the premature intestinal tract was emphasized as the

cause of NEC, but recently the involvement of systemic inflammatory response syndrome (SIRS) as a pathological condition has also come under scrutiny. We have also encountered cases whose onset could be attributed to SIRS, and the elucidation of the clinical pathophysiology of this condition and the development of treatment methods may be important in future. Some information, albeit scant, is known about the clinical pathophysiology of FIP and MRI, and the accumulation of evidence will be indispensable for elucidating their pathophysiology and improving therapeutic outcomes. Information on the cause and clinical pathophysiology of Hirschsprung disease and related conditions is still lacking. Its definition and categorization vary between authors. We have attempted to categorize this condition in terms of histopathology and manometric tests, and to predict its prognosis. We have encountered eight cases of hypoganglionosis (HG), of who six died. We have also encountered six cases of chronic idiopathic intestinal pseudo-obstruction syndrome (CIIPS), in whom no morphological abnormalities of the intramural plexus were observed, but these included patients who could not be taken off total parenteral nutrition and were thus unable to attend school or find a job. To elucidate its clinical pathology and establish a method of treatment are urgent tasks. At the same time, for disorders such as CIIPS that can never be completely cured, as well as for those disorders that are expected to leave after-effects, it is also necessary to consider therapeutic strategies that take account of patients' quality of life (QOL) for the rest of their lives, starting from infancy.

Approach to Esophageal Cancer: What's New

Tatsuyuki Kawano, MD, PhD

Department of Esophageal and General Surgery

Tokyo Medical and Dental University

Chief, Esophageal and Gastric Surgery, TMDU Hospital, Japan

Over the last 30 years, dramatic advances in esophageal cancer management have been achieved in Japan. In the 1980s, the easy detection of early esophageal cancer was made possible using iodine-chromo endoscopy, and new techniques, such as endoscopic musosal resection (EMR) and thoracoscopic esophagectomy, were developed in the 1990s. In the 2000s, chemo-radiotherapy was firmly established as one of the standard treatment modalities for resectable esophageal cancer and neo-adjuvant chemotherapy gained in popularity in combination with surgery. Recent topics of investigation in esophageal cancer management include establishing effective minimally invasive treatments for esophageal cancer, e.g. clarifying the indications for endoscopic treatments (EMR, ESD, APC-SEA), popularizing the techniques of thoracoscopic esophagectomy (prone or left lateral position with pneumothorax) and CRT followed by salvage esophagectomy, and elucidating the optimal management for Barrett's adenocarcinoma. Some of the recent topics of interest regarding esophageal cancer management in Japan and at TMDU will be presented.

Early Esophageal Cancer: Early Detection and Treatment

Tatsuyuki Kawano, MD, PhD

Department of Esophageal and General Surgery

Tokyo Medical and Dental University

Chief, Esophageal and Gastric Surgery, TMDU Hospital, Japan

The technique of iodine-chromo endoscopy made it possible to easily detect superficial esophageal cancer lesions in the early 1980s in Japan. Concerning the early diagnosis of esophageal cancer new therapeutic modalities were needed to avoid performing unnecessary esophagectomies. Based on this situation in the late 1980s, we devised new techniques for performing endoscopic mucosal resection (EMR) for the treatment of superficial esophageal carcinoma. Since that time, various new techniques for both the diagnosis and treatment of superficial esophageal cancer have developed, including endoscopic ultrasonography, magnifying endoscopy, endocytoscopy, endoscopic submucosal dissection (ESD) and argon plasma coagulation with sub-epithelial ablation (APC-SEA), and the concept of early esophageal cancer was also established as mucosal cancer. Furthermore, the introduction of high-quality nasal endoscopy has deepened our understanding of field cancerization, including the head, neck and esophageal regions. Our experiences in the early detection and treatment of esophageal and oro-pharyngeal cancer have led to changes in the concept of minimally invasive treatment for esophageal cancer from the viewpoint of carrying out function-preserving management.

Difficult Laparoscopic Cholecystectomy

Assoc.Prof. Sukij Panpimanmas MD.

Department of Surgery, Rajavithi Hospital, College of Medicine, Rangsit University

Laparoscopic cholecystectomy (LC) is now the treatment of choice for removing gallbladder in most gallbladder disease, especially gallstone that it take only half to one hour for operation time. LC is safe, minimal surgical wound, short hospitalization and rapid return to work with very low complication rate (<0.6%). But in some cases LC is not easy to do (Difficult LC) because of complex problem mostly acute cholecystitis or empyema gallbladder with thick wall, severe adhesion, severe impacted stone, cholecystoduodenal fistula or cirrhotic liver. Optimal time to do LC in these patients is the time that they are in good condition and stable, we are not depend on golden period (72 hrs.) concept now. Technique of L.C. in difficult situation should be studied and remember step by step such as needle aspiration for tensed gallbladder before grasping, precisely identify Calot's triangle, fundus down dissection, partial dissection of gallbladder wall and if the patient is severe critically ill, tube cholecystostomy may be the best option. The most serious complication is bile duct injury as we follow type of injury described by Bismuth and Strasberg. In case of difficult L.C., bile duct injury may be up to 1 % or more in some hospitals.

In conclusion, difficult L.C. can be done safely in experienced surgeon with good technique and good decision making.

Innovations in Plastic Surgery: Difficulties are opportunity

Dr. Pawan Agarwal

MS, MCh, (PLASTIC SURGERY) DNB, MNAMS, PhD, FICS

Associate Professor

Medical College Jabalpur

In this presentation I highlight the innovations and modifications for treatment of different plastic surgical problems which we have faced over the past ten years. This presentation underlines the importance of innovation which a surgeon should do when facing a difficult and unusual situations.

Plastic surgery is changing at a rapid pace. Plastic surgery is not hugely dependent on expensive technology, instrumentation or prosthetic implantation for its innovation. Unlike some other surgical specialties, our innovations tend to be based on creative techniques, adapting and utilizing existing resources.

Our unit of plastic surgery at NSCB Medical College Jabalpur is fairly busy unit and having a patient's load of 1200 patients per year. We treat wide variety of general and specialized plastic surgical problems like congenital, trauma, reconstructive, cancers and cosmetic. Top ten innovations for dealing with above problems have been presented.

The goal of this presentation is to foster dialog among busy clinicians, researchers and surgeons with a focus on innovation in order to develop new technology which simplify the management and improve the quality of patient care.

Innovations in Pediatric Surgery: Changing Ideas in to Reality

Vikesh Agarwal

India

Objective: To describe the need of surgical innovation in the field of pediatric surgery.

Methods: The presentation will highlight the technical modifications (tinkering and technical innovations), and technological substitute adopted to achieve optimum results in various pediatric surgical situations.

Results: Following heads and their example will give a broad idea about the contents:

1. Eased Surgical Approach: Lung delivering approach for Tracheo-esophageal fistula repair in patients with bilateral severe pneumonitis etc
2. Technical Modifications for better outcome: "Advanced MAGPI" a fistula-less repair with prepuce preservation for distal hypospadias etc.
3. Minimal access open approach: Trans-umbilical open approach for various abdominal problems like Giant Hydronephrosis due to Pelviureteric Junction Obstruction etc.
4. Minimal access endoscopic approach: Single incision Laparoscopic Surgery with conventional instruments and Subcutaneous Endoscopic approach for surface surgery in children etc.

Conclusion: There is always a need of innovation in surgery and therefore surgeon has to discover and translate the thoughtful ideas in to needful reality. An innovation is effectual only if it makes a technique/technology feasible, applicable and accessible to/for most of the patients and the surgeons.

Spectrum of Abdominal Tuberculosis

Arjun Saxena

Associate Professor & Unit Incharge

Department of Surgery, Govt NSCB Medical College

Jabalpur (MP-India)

Abdominal tuberculosis is a great mimicker of intestinal inflammatory diseases. Despite considerable progress in therapy, it remains one of the single largest cause of intestinal obstruction. This study aims at describing the clinical presentation and surgical management, including minimal access surgery, of abdominal tuberculosis in a tertiary referral hospital in a developing country. This descriptive study was conducted on histopathologically diagnosed cases of abdominal tuberculosis. Detailed history and clinical examination was performed in all cases. Preoperative anatomical site and type of lesion was noted. Variable clinical presentations were seen. Abdominal pain, fever, vomiting and weight loss are the commonest symptoms. The commonest lesion was ileocaecal mass and ileal strictures. The main surgical options were definitive surgical procedures like resection and anastomosis, stricturoplasty and right hemicolectomy. Minimal access surgery has a definite role in the diagnosis and management of abdominal tuberculosis. Surgeons should be aware of the entire spectrum of abdominal tuberculosis - clinical and pathological - so as to avoid misdiagnosis and offer prompt and adequate surgical treatment.

Sphincter-preserving Surgery for Locally Advanced Anorectal Cancers: Expanding the Indications

Arpan Mishra

MBBS, MS, M.Ch. (Surgical Oncology)

Assistant Professor and Head Surgical Oncology Division

Department of Surgery

NSCB Government Medical College and Allied Government Cancer Hospital

Madhya Pradesh University of Health Sciences, Jabalpur (M.P.), India

Introduction: Ultra low anterior resection and intersphincteric resection is well established mode of sphincter preserving rectal surgery but not feasible for locally advanced cancers which forms maximum number in Indian scenario. The above approach demands use of stapler which is not a cost-effective option. We evaluated the role of sphincter preservation in patients with invasion of external sphincter but uninvaded puborectalis. We also highlight the role of anterior sagittal sphincter splitting approach for ultra-low anterior resection which doesn't need staplers.

Method: Two techniques which are highlighted in this paper include Abdomino-Anterior Sagittal Low Anterior Resection (AASLAR), and Trans-sphincteric resection for anorectal cancer (TSRAR)

Technique	Type of cancer	N
AASLAR	Rectal adenocarcinoma	8 (7 females, 1 male)
TSRAR	Rectal adenocarcinoma	2 (1 Male, 1 female)
TSRAR	Anal Melanoma	1 (female)

Completion chemoradiation was done according to recommendations in all patients.

Results: All patients had acceptable continence level with minimal complications on mean follow-up of 3 years. Two patients had anastomotic stricture and one developed rectovaginal fistula.

Conclusion: Sphincter preservation is possible in locally advanced anorectal cancers inspite of external sphincter involvement but Intact puborectalis is prerequisite.

Thoracoabdominal Wounding

Kenneth L. Mattox

Distinguished Service Professor

Michael E. DeBakey Department of Surgery, Baylor College of Medicine

Chief of Staff/Chief of Surgery, Ben Taub General Hospital, Houston, Texas

Historically, combined thoracoabdominal wounds have brought fear, indecision, confusion and frustration to surgeons relating to which cavity to operate on first, positioning, incisions, traps, and priorities. A significant number of legacy tactics should be abandoned. A number of new advanced techniques are available to the acute care surgeon. In up to 50% of patients with thoracoabdominal wounding, the wrong cavity is operated upon first. Three anatomic transition areas exist (thoracic outlet, diaphragmatic region, and abdominal outlet), and each presents special diagnostic, exposure, and management challenges.

Dr. Kenneth Mattox will give three talks at the Royal College of Surgeons of Thailand meeting in 2013.

Resuscitation from Sever Shock

GREGORY J. JURKOVICH, MD, FACS

Chief of Surgery

Denver Health and Hospitals

Vice-Chairman and The Rockwell Distinguished Professor of Surgery

University of Colorado

Denver, Colorado

Shock is the clinical end result of inadequate tissue perfusion and end organ oxygen utilization. The currently accepted concept was first described in 1918 by Walter B. Cannon. There are multiple causes of shock; however the common pathway is an imbalance in oxygen delivery and utilization, and ultimately cellular dysfunction. Cellular hypoxia induces the production of inflammatory mediators that may further compromise tissue perfusion through changes in the microvasculature. If this vicious cycle is not interrupted, multi-organ failure and death result.

transfusion of banked blood.

There are three priorities in the treatment of shock. First, the diagnosis and underlying cause of shock must be diagnosed and corrected. Second, resuscitation for shock must rapidly restore tissue perfusion and optimize oxygen delivery, hemodynamics and cardiac function. Third, end-organ failure must be prevented or repleted. Often resuscitation will be initiated prior to or simultaneously with identifying the underlying etiology.

For resuscitation, a reasonable goal of therapy is to achieve normal mixed venous oxygen saturation and arteriovenous oxygen-extraction ratio, while simultaneously, the elevated systemic vascular resistance should return to normal. Oxygen delivery may be enhanced by improving haemoglobin concentration, arterial oxygen saturation and cardiac output, individually or simultaneously. An algorithm for the resuscitation of the shocked patient is shown in the figure (from: Hsu JM and Maier RV: in *Acute Care Surgery*. Ed: Britt, Peitzman, Barie and Jurkovich, Wolters Kluwer, Philadelphia, 2012, pp 34-47).

Exsanguinating Pelvic Trauma

Gregory J. Jurkovich, MD, FACS

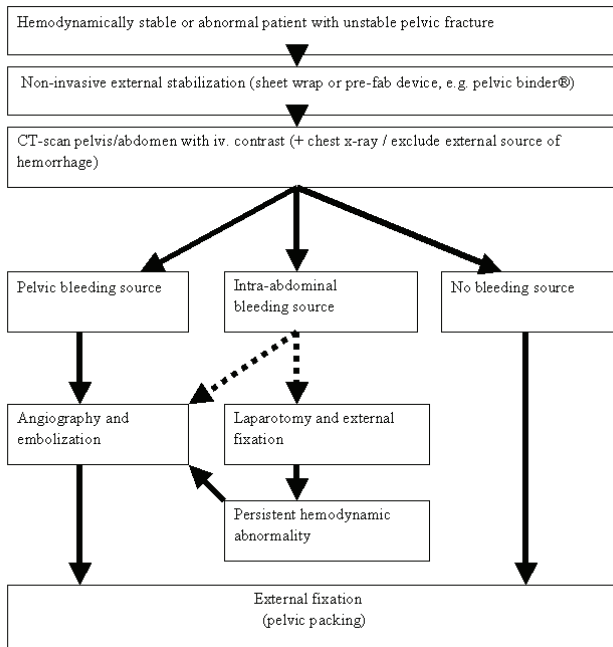
Chief of Surgery

Denver Health and Hospitals

Vice-Chairman and The Rockwell Distinguished Professor of Surgery

University of Colorado, Denver, Colorado

Modern management of severe pelvic boney trauma includes the recognition of the high likelihood of exsanguinating hemorrhage occurring from the pelvic vessels. Managing this hemorrhage can include boney fixation and stabilization, packing of the retro-peritoneum, interventional radiology and embolization, or direct operative attack on bleeding vessels. The following algorithm is one method of addressing this complex problem. But this discussion will suggest the alternatives in management and decision making in this complex and life-threatening entity.



Advanced Wound Dressing

สองศาสตราจารย์นายแพทย์อภิชัย อังสพิทักษ์

หน่วยศัลยศาสตร์ตกแต่งและเสริมสร้าง

ภาควิชาศัลยศาสตร์ คณะแพทยศาสตร์ จุฬาลงกรณ์มหาวิทยาลัย

การเข้าใจกระบวนการหายของแผลและการดูแลบาดแผลที่ถูกต้องเหมาะสมกับบาดแผลแต่ละชนิดเป็นเรื่องที่สำคัญอย่างยิ่งสำหรับการหายของแผล การดูแลบาดแผลที่ดีจะหมายถึงการที่ผู้ทำการรักษาได้ใช้ความรู้ความเข้าใจในกระบวนการหายของบาดแผลมาประยุกต์ใช้เพื่อช่วยให้กลไกตามธรรมชาติของร่างกายของผู้ป่วยสามารถรักษาบาดแผลที่เกิดขึ้นได้อย่างมีประสิทธิภาพที่สุด ผู้ทำการรักษาพึงตระหนักเสมอว่าการหายของบาดแผลนั้นเกิดขึ้นจากกระบวนการตามธรรมชาติ การเลือกใช้เวชภัณฑ์บำบัดแผลที่เหมาะสมจะเป็นองค์ประกอบหนึ่งในการช่วยให้กระบวนการดังกล่าวดำเนินไปอย่างมีประสิทธิภาพ ขณะเดียวกันการเลือกใช้เวชภัณฑ์บำบัดแผลที่ไม่เหมาะสมก็จะทำให้กระบวนการดังกล่าวถูกรบกวนและสูญเสียสมรรถภาพไป

เวชภัณฑ์บำบัดแผล ในปัจจุบันมีการพัฒนาไปอย่างมากยิ่งเรารู้เรื่องรายละเอียดของกระบวนการหายของแผลละเอียดขึ้นเท่าไร รู้ถึงเหตุที่ทำให้สภาวะการหายของแผลดีขึ้นหรือแย่ลง การผลิตเวชภัณฑ์บำบัดแผลก็จะพัฒนาไปตามความรู้เหล่านี้ การที่เรามีพื้นฐานเข้าใจในกระบวนการหายของแผลดีจะทำให้สามารถเลือกเวชภัณฑ์และวิธีการทำแผลที่เหมาะสมได้ดี แต่นอกจากบาดแผลเองแล้วยังมีปัจจัยรองอื่นอีก ดังนั้นข้อควรพิจารณาว่าจะเลือกใช้เวชภัณฑ์บำบัดแผลใดคือ ตำแหน่งของแผล (anatomical site) ปริมาณน้ำเหลือง (amount of exudate) พื้นที่ใต้แผล (dead space) ผิวหนังบริเวณรอบแผล (surrounding skin) ความสามารถของผู้ให้การรักษา (caregiver ability) ราคาที่เหมาะสมกับเศรษฐกิจของผู้ป่วยและสถานพยาบาล

ลักษณะของแผล (wound status)

ขณะเดียวกันวัตถุประสงค์ในการใช้เวชภัณฑ์บำบัดแผลโดยรวมแล้วได้แก่ ให้สภาพของแผล เอื้อต่อการหายของแผลมากที่สุด ปกป้องแผล และเนื้อเยื่อรอบๆ แผล ป้องกันการติดเชื้อ ลดความเจ็บปวด ควบคุมอุณหภูมิ ควบคุมหรือขจัดกลิ่น หยุดหรือห้ามเลือด ซึมซับเลือด หรือน้ำเหลือง ความสะอาดทidyต่อคนไข้ ส่งเสริมสภาพทางจิตใจและคุณภาพชีวิตของผู้ป่วย

Early Excision and Burn Debridement

Att Nitibhon, MD.

Major burn injury needs multiple aspects of treatment. Closure of the wound is one of the most complicated management in burn. The conservative approach awaits spontaneous separation of burn eschar was conventional practiced. Aggressive surgical debridement to remove necrotic tissue before it becomes infected shows some advantage over conservative approach. Excision of necrotic tissue is performed by sharp instrument such as dermatome, knife or scissors and hydrosurgery. Tangential excision is for deep partial and full thickness burn wound and fascial excision for deep down to muscle burn wound. Skin grafting should be done as early as possible after excision. For burn less than 20% TBSA, it may be done immediately after complete necrotic tissue excision. But for burn more than 20% TBSA may need to be delayed until infection is definitely cleared, and should be done as sequential grafting, each time about 20% TBSA. Early excision of necrotic tissue in operating room within the first week after injury, although needs more blood transfusion, demonstrates reducing mortality, length of hospital stay and leaving time from work.

Guidelines for Surgical Specialist Undertaking on Aesthetic Medical/surgical Practice in Malaysia

Peter Wong Toh Lee, MBBS, FRCSd, FRCSG

President, College of Surgeons of Malaysia

An outline on the evolution of guidelines for aesthetic medical practice in Malaysia is presented. The basic considerations in the formulation are discussed. Definitions which are deemed important are highlighted. Medical practitioners who perform aesthetic practice are categorized into three groups. They are registered under three separate chapters, namely, Chapter 1 for the general practitioners, Chapter 2 for the medical specialists and Chapter 3 for the surgical specialists. Under the guidelines, aesthetic medical procedures are classified into non-invasive, minimally invasive and invasive procedures. In general, invasive procedures may only be carried out by the surgical specialists. Depending on their specialties and experience, surgical specialists are assessed and credentialed for those aesthetic procedures which are listed under the scope of practice.

The process of application and registration for aesthetic medical practice is described. Some difficulties in the enforcement of the guidelines are to be expected.

Hyperbaric Oxygen Therapy

Supaporn Opasanon, M.D., FRCST, FICS

Division of Trauma Surgery, Department of Surgery

Faculty of Medicine Siriraj Hospital, Thailand

Introduction: Hyperbaric oxygen therapy (HBO, HBOT, HBO2) serves as primary or adjunctive therapy for a various range of medical conditions. Most of the efficacies of HBO are explained by the simple physical relationships determining gas concentration, volume, and pressure. The therapy's purpose is to increase the amount of oxygen in the blood. Problem wounds are the challenge medical conditions. Hyperbaric oxygen is a new modality of treatment that is used for hypoxic wounds.

What Is Hyperbaric Oxygen Therapy?

Hyperbaric oxygen therapy is a high dose oxygen inhalation therapy in which a patient breathes pure oxygen while inside a pressurized hyperbaric chamber at an atmospheric pressure greater than normal sea level (1 ATA). At the same time, the pressure surrounding the patient's body is slowly increased to two to three times normal atmospheric pressure. Hyperbaric oxygen therapy allows the blood to carry more oxygen to the tissues. This helps all the functions of your body that require oxygen. A high level of oxygen in the blood helps to promotes new tissue and blood vessel growth, and assists in the healing process by permitting skin grafting or spontaneous healing. In addition, it helps to fight infections caused by a variety of bacteria, some that only live in the absence of oxygen. It also enables white blood cells to destroy many kinds of bacteria more efficiently. Hyperbaric oxygen therapy is a non-invasive course of treatment. Traditionally used to treat diving complications, hyperbaric oxygen therapy now has new indications from the specialties of: Surgery, Plastic Surgery, Maxillofacial & Oral Surgery, Orthopedics, Infectious Disease, Radiation Oncology and Emergency Medicine. Hyperbaric oxygen acts as a drug, eliciting varying levels of response at different treatment depths, durations, and dosages and has proven effective as adjunctive therapy for specifically indicated conditions.

Indications for Hyperbaric oxygen therapy

Utilizing knowledge gained from clinical experience and basic sciences research, the Undersea and Hyperbaric Medical Society's Committee on Hyperbaric Oxygen has approved the use of HBOT as adjunctive or primary treatment for the following diseases and conditions:

The Hyperbaric Oxygen Committee of the Undersea and Hyperbaric Medical Society (UHMS) has approved treatment in 2009 for these conditions⁽⁴⁾:

Primary treatment

1. Air or gas embolism
2. Decompression sickness (DCS)

Preferred treatment

3. Carbon monoxide (CO) poisoning and CO poisoning complicated by cyanide (CN) poisoning

Adjunctive treatment

4. Clostridial myositis and myonecrosis (Gas gangrene)
5. Crush injury, compartment syndrome and other acute traumatic ischemia
6. Arterial insufficiencies
 - Central artery occlusion
 - Enhancement of healing in selected problem wounds
7. Exceptional Blood Loss (Anemia)
8. Intracranial abscess
9. Necrotizing soft tissue infections (subcutaneous tissue, muscle, fascia)
10. Osteomyelitis (refractory)
11. Radiation tissue damage (osteoradionecrosis, soft tissue radionecrosis)
12. Compromised graft and flaps
13. Thermal burns

14. Idiopathic Sudden Sensorineural Hearing Loss (New! approved on October 8, 2011 by the UHMS Board of Directors)

Role of HBO in Problem wounds

Wound healing is arrested by decreased fibroblast proliferation collagen production, and capillary angiogenesis in an hypoxic environment. Hypoxia also allows growth of anaerobic organisms, further complicating wound healing. Investigations of problem wounds in animal models suggested that elevation of wound oxygen tension to normal enhanced wound healing. Sheffield and associates^(5,6) confirmed hypoxia in chronic, indolent, human wounds and demonstrated

elevation of wound oxygen tension with hyperbaric oxygen treatment. Transcutaneous oximetry has become increasingly popular as a method of patient selection for hyperbaric oxygen treatment. Hyperbaric oxygen therapy provides a significant increase in tissue oxygen tension. It influences to enhance fibroblastic proliferation, increase collagen synthesis, promotes neo-vascularization, and bacterial clearance in wounds. HBO may be useful when underlying osteomyelitis is present or to improve the soft tissue envelope for reconstruction. However HBO is adjunctive to standard wound care.

Conclusion

Hyperbaric oxygen therapy is a drug with well defined physiological and pharmacological effects that is used for helping all the functions of the body that require oxygen. It offers many benefits. The treatment should only be administered under the close monitoring of highly trained physicians and nurses. HBO is not designed to replace other proven methods of treatment but to supplement other forms of treatment such as surgery, antibiotics and wound care. Researches are needed and are undergoing.

References

1. Medicare Coverage Issues Manual. Publication no. HCFA-Pub6 Transmittal 129, Department of Health and Human Services (DHHS), Health Care Financing Administration (HCFA), 2000. www.cms.hhs.gov/manuals/pm_trans/R129CIM.pdf.
2. Hart GB. The Monoplace Chamber. In: Kindwall EP, Whelan HT, (eds). Hyperbaric Medicine Practice. Flagstaff, AZ: Best Publishing 1999:99-126.
3. Hart GB. The Multiplace Chamber. In: Kindwall EP, Whelan HT, (eds). Hyperbaric Medicine Practice. Flagstaff, AZ: Best Publishing 1999:127-49.
4. Gesell LB. Hyperbaric Oxygen Therapy Indications. The Hyperbaric Oxygen Therapy Committee Report. Durham NC: Undersea and Hyperbaric Medical Society, 2008.
5. Sheffield PJ, Dunn JM. Continuous monitoring of tissue oxygen tension during HBOT, In: Proceedings of 6th Int Cong on Hyperb Med, Aberdeen Univ Press 1979: 125-9.
6. Sheffield PJ. Tissue oxygen measurements with respect to soft-tissue wound healing with normobaric and hyperbaric oxygen. Hyperb Oxyg Rev 1985; 6:18-46.
7. Kindall EP. Contraindications and side effects to hyperbaric oxygen treatment. In Kindall EP, Whelan HT, (eds). Hyperbaric Medicine Practice, 3rd Ed. Flagstaff, AZ:

Best Publishing 2008;273-88.

8. Kindall EP. The use of drugs under pressure. In Kindall EP, Whelan HT, (eds). *Hyperbaric Medicine Practice*, 3rd Ed. Flagstaff, AZ: Best Publishing, 2008;245-62.
9. Plafki C, Peters P, Almeling M, et al. Complications and side effects of hyperbaric oxygen therapy. *Aviat Space Environ Med* 2000;71:119.
10. Davis JC. Hyperbaric oxygen therapy. *J Intensive Care Med* 1989;4:55.
11. Clements KS, Vrabec JT, Mader JT. Complications of tympanostomy tubes inserted for facilitation of hyperbaric oxygen therapy. *Arch Otolaryngol Head Neck Surg* 1998;124:278.
12. Tibbles PM, Edelsberg JS; *N Engl J Med* 1996; 334:1642-8.
13. Leach RM, Rees PJ, Wilmshurst P. Hyperbaric oxygen therapy. *BMJ* 1998;317:1140-3.

Mid-term Outcomes of Fenestrated Endovascular Grafting for Juxtarenal Abdominal Aortic Aneurysms

Khamin Chinsakchai MD, Kiattisak Hongku MD, Worawong Slisatkorn MD, Chumpol Wongwanit MD, Pramook Mutirangura MD

Faculty of Medicine Siriraj Hospital, Mahidol University

Objective: To evaluate outcomes of the Zenith Fenestrated AAA endovascular graft (Cook Medical, Bloomington, Ind) incorporating the visceral aortic segment with graft material in the setting of juxtarenal aneurysms.

Materials and methods: A prospective analysis of patients undergoing implantation of an endovascular device with graft material proximal to the renal arteries was conducted. All patients were deemed unacceptable candidates for open surgical repair. Fenestrations were customized to accommodate aortic branch anatomy based upon CT angiography. Selective visceral ostia were treated with balloon expandable covered stents following endograft deployment. All patients were evaluated with CT angiography and/or duplex ultrasound, at 1, 6, 12 months and annually.

Results: A total of 14 patients (85.7% men; mean age, 74.4 years) with a mean aneurysm size of 54.7 mm were enrolled in the trial. Endograft design included bifurcated (9) and aortic tube (5) systems. In these 14 patients, 34 visceral vessels (mean of 2.43 per patient) were accommodated by fenestrations located within the sealing segment of the grafts. The most commonly included both renal arteries and the SMA. Technical success rate was 97% (33/34 branch graft). One renal artery was lost. The mean follow-up was 9.35 months (range 1-23 months). No type I or type III endoleaks were observed. The endoleak type II rate was 7.1% (1/14) at 1 and 6 months. There was no aneurysm sac expansion during follow-up period. There were no secondary interventions. Two patients had transient elevation of serum creatinine without requiring hemodialysis. Of the 33 vessels incorporated, there were no visceral stent occlusions during follow-up. Two patients died of unrelated causes during the follow-up period.

Conclusions: The mid-term outcome of the fenestrated endovascular grafts is safe and effective. It remains critical to follow the status of stented visceral vessels, and establish the long-term efficacy of this type of repair.

Surgical Innovation in Australia

A/Prof. Michael Hollands

President, Royal Australasian College of Surgeons, Australia

The history of surgery is one of innovation leading to better outcomes for patients. When considering innovation it is tempting to approach it purely as technological change. Change however is not just the opportunity to do something new. It comes with responsibility. How do we assess innovation, is it safe, cost effective? How do we train surgeons in its correct application? Do we licence them to use it? How do we ensure patient safety? How do we monitor its incorporation into surgical practice? The role of surgical Colleges as responsible lead organisations in this process is crucial. My presentation will consider these questions with a focus on the Australian environment.

S3

Hong Kong Innovations in Surgery

Hung-to Luk, MBBS (HKU), FRCS (Ed), FRCPS (Glas), FCSHK; FHKAM (Surg)

President, The College of Surgeons of Hong Kong

Hong Kong is just a small city with a population of over 7 million. The practice of western medicine is based on United Kingdom model relating to our history. With different ethnic group, social culture and environment; we are having different disease pattern or problems that we cannot take reference to foreign experience and hence we have to device our own protocols and the following are some examples.

Tuberculosis had been endemic in Hong Kong in mid twentieth century. It affects multiple organs and the spine is an example. It courses bony necrosis and obviously it is necessary to remove the necrotic bone and to bridge the gap left afterwards. Anterior spinal fusion with introduction of bone segments from iliac crest was developed.

Tuberculosis causing cystitis and fibrosis of urinary bladder markedly reduced the bladder volume and part of the stomach or colon was used to replace the shrunken urinary bladder.

In hepatobiliary system, recurrent pyogenic cholangitis had been a condition causing might mares to local surgeons. The biliary tree with multiple strictures and filled with mud and stones causes recurrent life threatening infections. The classical triad of right upper quadrant abdominal pain, fever and jaundice was a common presentation. Surgeries to improve bile drainage like hepaticoduodenostomy and hepaticojejunostomy were performed and that is of course before the era of ERCP.

Liver transplantation is a local problem because of lack of cadaveric donors. Hence surgeons in Hong Kong based at Queen Mary Hospital, the only liver transplant centre in Hong Kong had made much contribution in living related liver transplantation.

Squamous cell carcinoma of esophagus is an entity common locally. Esophagectomy is still the choice of management in early cases. Prof. GB Ong showed that the stomach tube is best serving as a conduit after esophagectomy

and it becomes norm of today.

Nasopharyngeal carcinoma is another common malignancy in Hong Kong. Surgical excision is extremely difficult because of location of the tumour. Prof. William Wei developed the maxillo-facial swing approach leading to direct access to tumour making surgical resection of nasopharyngeal carcinoma possible.

The above are just some examples of contributions from Hong Kong and we look forward to collaboration with world surgical community to improve on surgical care to patient world-wide.

Successful Cannulation in ERCP

Panot Yimcharoen, MD

Bhumibol Adulyadej Hospital

Nowadays the role for diagnostic ERCP alone is scarce due to noninvasive imaging techniques such as CT scans, endoscopic ultrasound [EUS], magnetic resonance cholangiopancreatography [MRCP] have been widely used. Conversely therapeutic aspect of ERCP has become more important and clinically helpful for patients who has significant suspicion of obstructing, inflammatory, or neoplastic pancreatobiliary lesions that, if detected or ruled out, would alter clinical management.

This chapter present about how to succeed biliary cannulation without or less complications. As we known ERCP has a risk of pancreatitis, bleeding or even perforation, and most contraindications of ERCP are relative, and the degree of risk must be balanced against the potential benefit. In patients who have indications for ERCP such as suspected biliary ductal disorder (jaundice, acute cholangitis, gallstone pancreatitis, biliary fistula, etc.), direct endoscopic therapy (sphincterotomy and biliary drainage), direct endoscopic tissue and fluid sampling (biopsy, brush, fine needle aspiration and bile collection), preoperative ductal mapping (malignant tumors, benign strictures and chronic pancreatitis) and perform manometry, we have to achieve our goal which is cannulation for accessing to bile duct. We focus on variations of the standard technique that can be used by advanced endoscopists. The variations in technique have to be performed with caution and adapted to the individual case. Before attempts at cannulation, fluoroscopic visualization of the field of interest should be performed to look for stents, calcifications, masses, and residual contrast media.

Finding the papilla, an atraumatic ERCP catheter or sphincterotome can be helpful to lift and separate folds. Duodenal diverticula have to be inspected carefully. One way to expose the inner side of the diverticulum is to push the mucosa gently from the outer rim of the diverticular ring caudally with an ERCP catheter. The papillary orifice often appears by being pulled from the inner side of the diverticulum toward the edge of the opening. In some cases, submucosal injection into the bottom of the diverticulum has been considered to lift the papillary opening. However, we should be aware of the very thin wall diverticulum with

the risk of complications such as perforation and retroperitoneal leak and a potential edematous compression of the ampulla opening. The choice of initial cannulation tool is a personal preference. We recommend starting with a simple single-lumen 5-Fr polyethylene catheter, with or without a guidewire, which are successful cannulation in many cases. A guidewire (soft-tipped wires) may be used at any point to aid cannulation or maintain intraductal stability. A sphincterotome is a good starting tool, if the orifice appears small, a more tapered tip catheter or sphincterotome may be chosen. A long papillary roof delineating the distal bile duct above the horizontal fold (plica horizontalis) may be helpful in determining its direction. For cannulation of the CBD, the papilla should be viewed from below, and the catheter direction should be steep and within the axis of the papilla. The catheter tip is introduced into the papillary orifice and gently pushed forward while the elevator is lifted and the bile duct is cannulated.

For pancreatic duct (PD) cannulation, the endoscope position remains at the level of the papilla, and the catheter direction is roughly horizontal. Sometimes pancreatic cannulation is easier than biliary cannulation so we often start with a standard 5-Fr catheter and add a guidewire or a sphincterotome for assistance. If the cannulation angle fails to achieve adequate cephalad orientation, a sphincterotome or curved top guidewire generally helps to achieve that angle. There are observational studies showed that initial use of a guidewire facilitates cannulation and decreases post-ERCP pancreatitis. About precut sphincterotomy involves cutting the papilla to gain deep intraductal access to the biliary tree. Precutting can be achieved by impaction of a short-nosed pull-type sphincterotome into the papillary orifice with sequential shallow cephalad cuts until the biliary orifice is identified. Similar sequential shallow cuts can be made with a needle-knife. We prefer to place a 3-Fr to 5-Fr, 6-cm long, no intraductal flange polyethylene stent into the pancreatic duct first, if possible, and use the stent to guide needle-knife cutting. Other technique is double wire cannulation, in difficult biliary cannulation we can use catheter with guidewire cannulate in to PD first. We then left the guidewire in place for occupying PD opening, standard 5-Fr catheter or sphincterotome was used for cannulating bile duct at the same time. With this method, successful cannulation is high but sometimes it was difficult to use elevator for controlling the catheter.

In conclusion, many endoscopic tools are armamentariums for successful cannulation. Some technique should be done by experienced endoscopists only

and mostly applied in patients with a high clinical suspicion of obstructive pathology or jaundiced patients with dilated bile ducts on noninvasive imaging after standard techniques fail, or strong indication for ERCP.

Innovation in Laparoscopic Colorectal Surgery

Prof. Yoshiharu Sakai, MD

Professor, Department of Surgery, Kyoto University, Japan

I will introduce our on-going research in order to improve or develop laparoscopic instruments.

1) Re-evaluation of quality of linear staplers: It is important to select a stapler appropriate to thickness of rectal wall for secure anastomosis. An ideal stapler could automatically not only measure the thickness and hardness of rectal wall, but adjust the compression force and time before firing.

2) “Metastatic lymph node navigation surgery”: Sentinel node navigation surgery needs intraoperative pathological exam. Detection of metastatic lymph node using fluorescence could let us inform appropriate area of lymph node dissection.

3) Anatomical imaging for pelvic surgery: Mounting display of the anatomy of nerves or muscles in the pelvis would help our precise dissection.

Emergency Center Thoracotomy

Kenneth L. Mattox

Distinguished Service Professor

Michael E. DeBakey Department of Surgery, Baylor College of Medicine

Chief of Staff/Chief of Surgery, Ben Taub General Hospital, Houston, Texas

Because of an immediately unavailable operating room or the extreme urgency of a thoracic injury, a surgeon may elect to perform a thoracotomy in the emergency center, most often using a 4th interspace anterolateral thoracotomy. Specific indications and contraindications exist. Logistic, procedural, timing, and safety considerations are as important as are the specific technical steps EC thoracotomy. Complications exist with regard to logistics and instrument choice and are inherent when performing procedures in areas of chest wall, posterior mediastinum, pericardium and heart. A detailed review of each of these aspects will aid surgeons in being better prepared for the urgent emergency center thoracotomy.

Assessment & Management of Breast Lump

Dr. P. Raghu Ram

MS, FRCS (Edin), FRCS (Eng), FRCS (Glasg), FRCS (Irel)

Director & Consultant Oncoplastic Breast Surgeon

KIMS-USHALAKSHMI Centre for Breast Diseases, Hyderabad, India

The aim of assessment of a breast lump should be to obtain a definitive diagnosis in a timely manner. There should be only three routine assessment outcomes:

No significant problem

A diagnosis of a benign lesion

A diagnosis of cancer

Assessment ends at diagnosis and not before

Triple assessment (Clinical Breast Examination, bilateral Mammogram & Ultrasound of the breast combined with aggressive use of image guided core needle biopsy) is now considered to be the 'Gold Standard' in the evaluation of a breast lump. Triple assessment helps in obtaining accurate pre-operative diagnosis of breast cancer ensuring minimum number of women undergoing surgery for benign disease. Equally, pre-treatment patient counselling & informed surgical planning allows a single definitive surgical procedure taking away the need for frozen section. Core Needle Biopsy (CNB) has replaced Fine Needle Aspiration Cytology (FNAC) in the evaluation of solid breast lesions, except aspiration of cysts. The absolute sensitivity, specificity and positive predictive value of CNB is far superior to that of FNAC. Also, the false positive rate of CNB is 0%.

The Talk will highlight the issues relating to management of various benign and malignant breast lesions.

Management of Axilla - Something Old, Something New, Something Blue

Dr. P. Raghu Ram

MS, FRCS (Edin), FRCS (Eng), FRCS (Glasg), FRCS (Irel)

Director & Consultant Oncoplastic Breast Surgeon

KIMS-USHALAKSHMI Centre for Breast Diseases, Hyderabad, India

Axillary node involvement is one of the most important prognostic indicators in operable breast cancer. Clinical examination of the axilla is unreliable & PET/MRI scans have low sensitivity to detect abnormal lymph nodes. Ultrasound should be considered the first step in the evaluation of axilla in the pre operative setting at the time of triple assessment. Those found to have abnormal nodes on imaging can be straight away counseled for Axillary Node Clearance (ANC).

Traditionally, ANC has been considered to the 'gold standard' in evaluation and management of axilla in operable breast cancer. However, the morbidity associated with this procedure coupled with the fact that nearly 2/3rds of women with early breast cancer do not have nodal disease, higher expectations from patients, and equally, advances in technology has resulted in the evolution of Sentinel Node Biopsy (SNB) using a combination of radio isotope and blue dye.

Press releases have heralded the dawn of this remarkable new technology (SNB). Publications on this issue have increased exponentially and SNB is debated at most International meetings. However the dual technique SNB is not a viable option in developing Countries due to the enormous equipment costs in addition to costs associated with setting up and maintaining Nuclear Medicine facilities.

What do you do when you cannot identify abnormal node/s on pre operative Ultrasound? What do you do when your centre cannot afford the equipment to perform SNB? - **Perform Axillary Node Sampling (ANS)**. This is a technique that evolved in Edinburgh and has been subjected to two large Randomised Controlled Trials, which has shown near 100% detection rate, near 0% false negative rate, low morbidity, and above all, proven equivalent survival and relapse rate when compared with ANC. Moreover, there is no need for costly equipment & no need for expensive Nuclear medicine facilities. There is now

robust evidence to suggest that **Blue Dye alone Assisted Axillary Node Sampling (BDANS)** further enhances the sensitivity of ANS & can reliably predict the status of axilla with low false negative rate.

In Conclusion, it seems entirely appropriate that much research effort has gone into evaluation of SNB. However, in developing Countries, BDANS is a pragmatic, practical & economically attractive option for evaluating the axilla.

Laparoscopic Technique for Solid Organ Pathology: Laparoscopic Nephrectomy

Satit Siriboonrid, MD

Division of Urology, Department of Urology, Phramongkutklao Hospital and College of Medicine

Nephrectomy, both simple nephrectomy and radical nephrectomy, are simple procedures that surgeon familiar with its. More advanced radiographic investigations and early detection measurement bring patients with renal mass to our department more than the past. Laparoscopic nephrectomy is one of procedures for renal lesions management. Because of magnification, less pain, small surgical wound, minimal bleeding and decrease hospital stay, this procedure is interested. This topic will review about procedure, technique and tips that bring you success in this operation.

Key words: laparoscopic nephrectomy, simple nephrectomy, radical nephrectomy

Anatomy in Laparoscopic Rectal Surgery

Prof. Yoshiharu Sakai, MD

Professor, Department of Surgery, Kyoto University, Japan

Understanding of anatomical landmarks is very important for lap-LAR and lap-ISR, from functional as well as oncological point of view. I will present several anatomical landmarks, its histology and functional outcomes. In addition I would like to discuss the anatomy of pelvic floor.

LIFT : Past Present and Future

Arun Rojanasakul

ColorectalDivision, Department of Surgery, King Chulalongkorn Memorial Hospital,
Bangkok, Thailand

LIFT (ligation of intersphincteric fistula tract) is the total anal sphincters preserving procedure for fistula in ano. This technique was innovated in King Chulalongkorn Memorial Hospital in the year 2006. Before the LIFT period the author had used all the available techniques, which included fistulotomy, fistulectomy with primary closure, Hanley's fistulotomy, seton, advancement flap.

The outcome of these techniques were comparable to the literaturesbut with significant prize to pay, which are lifelong incontinence and perianal scar.

At present LIFT is the procedure of choice in our colorectal unit, and has been accepted world wide as an armamentarium for fistula in ano. However, reported non healing rate after LIFT were still high ranging from 10 to 40% , but we expect the high non-healing rate to be loweredwith improvement of surgical techniqueand device. The future of LIFT is promising , and I believe that LIFT can become the new gold standard for the treatment of fistula in ano.

Technique of Endoscopic Thyroidectomy

Suchart Chantawibul

Department of Surgery, College of Medicine, Rajavithi Hospital, Rangsit University, Bangkok, Thailand

Introduction: After the first published of endoscopic subtotal parathyroidectomy in 1996, the new era of endoscopic neck surgery was opened. Numbers of approach was introduced to the surgeons by various institutes around the world. In brief, there are mainly two ways to access to neck, cervical and extra-cervical. While the techniques that used to maintain the surgical space were carbon dioxide gas insufflations and gasless technique. Many papers reported the robotic usages.

Surgical Tips and Pitfalls: Axillary approach is one of the preferred extra-cervical technique. Our hospital was started the endoscopic thyroidectomy via axillary approach with carbon dioxide gas insufflations since 2001. Up to June 2013, more than 850 consecutive cases was done. The right thyroid lobectomy was easier to perform than the left side. The whole port sites on the left axilla should be 1-2 centimeters below than the right side. The beginners may selected the nodule around 2-4 centimeters, because the nodule that too small may be difficult to palpate during operation while the larger may occupied the working space and very limited area for surgical instruments. Each port should be place at minimum 3-4 centimeters apart. By using the instruments that have different length, it may be help you to avoiding of fighting of the instruments outside the ports. And also when the surgeon sit down on a operating chair while the assistants stand besides also help to separate the surgeon's and assistant's hand to working on a different 'plane'. Direct dissection through the strap muscles along its fiber will found the thyroid gland beneath it. In case of small nodule, direct approach through the strap muscle may be used. But in a large nodule, you can approach to the thyroid gland by dissect between the two heads of sternocleidomastoid muscles. Before cutting the superior thyroid artery, don't apply too much force on the grasping tissue at the first moment and let it 'work' on the artery about 5-6 seconds before cutting the tissue without tension. Rotate the 'hot blade' of the Harmonic scalpel away from the recurrent laryngeal nerve and keep in mind that the newly used blade is still hot!.

Don't selected the sharp teathed instrument to grasped the thyroid because it may be easily bleed and difficult to control. By opened the instrument and push-up the gland (instead of grasped it) you can easily dissected around the thyroid lobe. It's not necessary to drain when you perform lobectomy and make sure that the operative space was cleaned.

If your camera holder assistant has 'brand new', I advice you to use the rigid scope to avoid fighting effects. The flexible laparoscope is prefer in the larger nodule because of better viewing at difficult areas by varying angle of scenes.

Conclusions: What ever the instruments or techniques, the surgeons yourself are the most important part of the operation. Surgeons should be learned until he familiar and developed his own skills and technique. Finally, every surgeons should realized the limitation of the technique and don't hesitate to convert to traditional open surgery for patient's safety.

Lateral Lymph Node Dissection: Why and How

Prof. Yoshiharu Sakai, MD

Professor, Department of Surgery, Kyoto University, Japan

The criteria and efficacy of lateral lymph node dissection for low rectal cancer remain still uncertain. It has been reported that around 80% of local recurrences after preoperative CRT occurred in lateral nodes. I will present our current strategy and procedure of laparoscopic lateral lymph node dissection.

Recent Advances in Surgical Management of Diabetic Foot

Prof. Rama Kant

Dean, Career Institute of Medical
Sciences, Lucknow, India.

MS, FACS (USA), FRCSI (Honorary, Ireland), FRCS (Honorary, Edinburgh), F.R.C.S. (England),
FCSS (Honorary, SriLanka), MNAM, FICS, FNCASI (Honorary), FLCS, MIASGO

Diabetes has proved itself a silent killer disease. Today in the world maximum numbers of the patients are suffering from this disease, and moreover they are passing through the complications too. The World Health Organisation estimated that in the year 2000, 150 million people had diabetes mellitus, and it is predicted that this number will rise to 366 million by the year 2030.

Evidence prove that the pathophysiological process of diabetes have put the foot at increased risk for tissue damage. Tissue damage has occurred and the foot is at risk for end stage complication. **50% of all lower extremity amputations (LEA) are diabetes related.>70% of LEA's are preceded by a foot ulcer.** 3-10% of those with diabetes have a foot ulcer. 15% of all those with diabetes will, during their life time develop an ulcer. The international working group on the diabetic foot proposed the PEDIS classification: It grades the wound on the basis of 5 features1. i.e. perfusion, Extent (area), Depth, Infection and sensation.

Causation

Despite much intensive research, the pathophysiology remains unclear. The principal theories are of microvascular disease leading to neural hypoxia, and the direct effects of hyperglycaemia on neuronal metabolism. **To date no treatment which prevents or reverses development and progression of neuropathy has been identified.** Neuropathy is the most significant risk factor for diabetic foot ulcers and is present in over 80% of patients with diabetes and foot lesions. It is quite evident that in the majority of cases (56%), infection was the sole predominant feature while others had associated vasculopathy /neuropathy.

The polymicrobial infection has to be treated with proper wide spectrum in

adequate dose for adequate time. Local antibiotics infiltration and topical usage has an off label use. We have sufficient experience to advise its use.

Treatment: Precise diabetic control, proper broad spectrum antibiotics, vascular interventions, endovascular stents where indicated, vasodilators, treatment for neuropathy and aggressive debridement excising all dead and dying tissues and only leaving healthy tissue which must be profusely bleeding to be applied elastocrepe bandage and several feeding tubes can be left in the wound over tulle grass gauzes and the outer end is out of dressing. As soon as the granulation tissue is healthy free use of growth factors, skin grafts, pedicles or even free graft leads to gratifying results. All efforts can be totally crashed by allowing the patients of neuropathy, to move on deformed foot with pressure points leading to reulcerations and failure of the efforts to salvage the limb.

Conclusion: Recent alterations in overall treatment specially of surgical and endovascular advances have drastically changed the gloomy scenario, morbidities and results in management of Diabetic foot - The curse of present lifestyle.

Quality and Safety in the Operating Theatre

Dr. Leo G. Spierenburg

Business Development/Technical Manager

Sterile Barrier Solutions Pty. Ltd.

Postoperative complications are more often happening and are seemingly unavoidable. However postoperative complications are preventable and can be brought back to a minimum calculated risk.

With new strains of Methicillin-resistant *Staphylococcus aureus* (MRSA) being detected almost every day, more awareness needs to be created and new measures need to be put in place to prevent postoperative complications from becoming unavoidable.

Most of the postoperative complications are caused by the introduction of harmful pathogens into a human body during surgical procedures by surgical instruments, appliances and devices.

Contamination of surgical instruments, appliances and devices take usually place during the transition between the place of sterilization and the hand of the surgeon who is using it during an invasive surgical procedure.

Postoperative complications in general can be quite expensive to cure in the event there is a cure available. A prolonged stay in the ICU as well as an extensive use of medication is not a desirable option but in most cases unavoidable. Administering large volumes of postoperative medication, antibiotics, is only weakening an already compromised immune system caused by the procedure and anesthetics.

Prevention is therefore the best option. The best way of prevention is to make sure that all surgical instruments, appliances and devices are sterile when introduced into the human body.

Surgeons should be aware of the preventive measures that can be taken to make sure that all the surgical instruments, appliances and devices that they using are sterile and should be able to advise the Theatre and other hospital staff how to pack, wrap and handle surgical instruments, appliances and devices in order to avoid contamination.

Prevention is the best cure, saves lives, reduces cost and improves Patient care and safety.

Innovation in a Resource-poor Hospital: Virtue or Necessity?

Professor Dhananjaya Sharma

**MS, PhD (Doctor of Philosophy), DSc (Doctor of Science),
FRCS (Glasgow), FRCST (Hon)**

Head, Department of Surgery

Government Medical College and Allied Hospitals

Jabalpur (MP) India 482 003 E-mail: dhanshar@gmail.com

Innovation means “something new, which makes it better”; however, in a resource poor setting it means “something which lowers cost, and increases benefits”. Innovation is needed to produce quantum change. Six easy steps to innovation are as follows:

1. Identify a problem which needs solution
2. Brainstorming with Idea makers (Team) + Research (Read) + Enthusiasm
3. Identify a “good” idea (Learn from your failures)
4. Insure safety/ Get approval of ethics committee
5. Cadaveric study/ Pilot run/ Clinical trial
6. Disseminate/ Publish/ Peer acceptance

Prognosticating tools and surgical techniques can be modified in such a way that they do not need expensive equipment. This is ‘affordable/ appropriate technology’ for developing countries. These include simplifying prognostic scoring systems for daily use, simple and economical biochemical test to assess liver dysfunction, usage of economical alternatives for dressings and accessories, operations for Portal hypertension (Devascularization procedure), Cancer of esophagus (Easy technique for trans-hiatal resection) and Cancer of rectum (Low Anterior Resection).

Working in sub-optimal conditions the philosophy has to be “Modify-Simplify-Apply”. Even when working on a shoestring budget, standard results can be provided with the help of simple innovations in science and by striking the “right balance between science and technology”.

General Surgery
Free Paper I & II

Radical Superficial Vein Removal for the Treatment of Venous Ulcer

Burapa Kanchanabat, Wikoon Stapanavatr, Yutapong Wongmahisorn, Pong Kanchanasuttiruk, Wuttichai Saengprakai

Department of Surgery, Vajira Hospital, Navamindradhiraj University

Background: Previous studies suggested that the characteristic of chronic venous insufficiency (CVI) in Thai may differs from the west as they trend to be younger and has higher prevalence of superficial venous reflux. The deep vein reflux coexist in the majority of these patients. The role of superficial venous surgery has been suggested.

Objective: This study aimed to assess healing and recurrent rates after treatment with superficial venous eradication combining with compression therapy in Thai patients.

Material and methods: A retrospective cohort of patents with healed or active venous ulcer (C5-6) who had complete duplex doppler ultrasonography, history and physical examination record according to the standard protocol and had refluxive superficial veins remove with stripping or vein excision were reviewed.

Results: Between October 2006 and February 2013, There were 34 C5-6 legs in 27 patients with complete follow up for analysis with the median follow up time of 20 months. Of the 32 C6 legs, 24 legs had primary surgery and 8 legs (6 patients) had the superficial venous removal for the recurrent ulcer after previous surgery. The operation performed was 14 groin to ankle GSV removal, 6 groin to knee GSV removal, 4 knee to ankle GSV removal, 4 SSV removal, 3 combined groin to knee GSV and SSV removal and 3 combined knee to ankle GSV and SSV removal. The wound healing was achieved in 29 legs (91%) with the median healing time of 21 days (mean 44 day). The 30 days healing rate was 69% (20 legs) and the 14 days healing rate was 41% (12 legs). Only 3 legs in two patients that the ulcer healed beyond 60 days. The post operative venous severity score and venous disability score of the 35 C5,C6 legs, were significantly improved compare with pre-operative value (pre-operative and follow up VCSS and VDS were 12 (6-19), 3.6 (0-13) and 1(0-3), 0.4 (0-2) respectively, p= for VCSS p<0.0001 and for p=0.0042 VDS). The recurrent ulceration was found in 4 legs at the mean follow up time of 30 months (ranges 1-76 months). The 2- and 3-year recurrent rate were 4 percent and 25 percent respectively.

Conclusion: In contrast to many western series, satisfactory results from superficial vein surgery could be obtained in thai patients. The radical removal of peri ulcer refluxive vein in this series may responsible for this results.

The Rate and Mortality of Postoperative Venous Thromboembolism of Moderate Risk Surgery in Asian Patients Without Thrombo-prophylaxis: Systematic Review with Meta-analysis

Burapa Kanchanabat, Wikoon Stapanavatr, Sumonmal Manusirivithaya, Satid Srimantayamas.

Department of surgery, Vajira hospital. Navamindradhiraj University

Background: The general, gynecologic and neurologic surgeries are regard as carrying moderate risk for postoperative venous thrombo-embolism. This review analyzed the postoperative VTE rate of these surgeries in Asia.

Materials and Methods: Inclusion criteria were: prospective study; DVT diagnosed by venography ultrasonography or radionucleotide scan and no thromboprophylaxis. The pooled proportion was back calculated from Freeman-Tukey variant transformation, using random effect model.

Results: Medline, EMBASE, Cochrane Library, and KoreaMed were searched. Fourteen studies (total population of 1625) published from 1974 to 2008 were included. In general surgery, the pooled rate of all sites, proximal, isolated distal DVT was 13.4%, 2.1%, and 14.0% (radionucleotide scan). The cancer patients carried higher all site DVT rate (19.7% radionucleotide scan and 17.4% ultrasound). The gynecologic and neurologic surgery had 3.1% (ultrasound) and 3.8% (radionucleotide scan) all site DVT rate. The pooled rate of symptomatic DVT were 1.5%, 0.2% and 1.0% for general, gynecologic and neurologic patients and the overall pooled rate of symptomatic PE were 0.3%. No patients die from PE (pooled rate 0.2 %).

Conclusions: None of these Asian patients dies from VTE. Pooled rates of proximal and symptomatic DVT were lower than in Western reports.

Outcomes of Intraoperative Thrombolysis in Late Acute Arterial Embolism of Lower Extremity

Chanean Ruangsetakit, Vipavee Niyomnaitham, Khamin Chinsakchai, Chumpol Wongwanit, Nuttawut Sermsathanasawadi, Pramook Mutirangura, Suteekhanit Hahtapornsawan

Vascular Surgery Unit, Department of Surgery, Faculty of Medicine Siriraj Hospital, Mahidol University, Bangkok 10700, Thailand

Background: Acute limb ischemia is an emergency condition which may cause limb and life threatening in case of delayed or failed revascularization. Acute arterial embolism tends to produce more acute and limb-threatening ischemia than arterial thrombosis due to the lack of collateral circulation. In late presentation of acute arterial embolism which was the major group of patients presented with acute embolism, success rate of embolectomy with no adjunctive treatment was only 60-70% compared with more than 90% in early setting. Intraoperative intraarterial thrombolysis following embolectomy has been proved from many studies in improving the outcome of treatment in this group of patients without an increase in bleeding complications. However, in Thailand, intraoperative thrombolysis was not widely used due to lacking of recommended method and guideline for such treatment.

Objective: The objective of this study is to demonstrate the outcomes of intraoperative thrombolysis combined with surgical embolectomy in late acute arterial embolism of lower extremity presented with immediately threatened severity (Rutherford IIB) to use as a preliminary information to establish future limb ischemia management guideline for Thai patients.

Material and Method: Medical records of 33 late acute arterial embolism patients presented with immediately threatened severity who underwent embolectomy with intraoperative thrombolysis from January 1995 to December 2010 at the Faculty of Medicine Siriraj Hospital were reviewed. Data were recorded including patients' demographic data, intraoperative data, postoperative complications, limb salvagibility rate and mortality rate within 1 year.

Results: 33 patients were enrolled in this study. Mean duration before revascularization is 16.85 days (1-120). 22 patients (67%) were treated with streptokinase while 11 patients (33%) received rt-PA. The limb salvagibility rate within 1 month is 78.8% (26/33) and 60.9% (9/23) within 1 year. While the mortality rate within 1 month is 3% (1/33) and 16.7% (4/24) within 1 year. The postoperative complications include bleeding in 5 patients, rethrombosis in 6 patients, wound hematoma in 3 patients, postoperative MI in 1 patient, surgical site infection in 1 patient and infected gangrene in 1 patient.

Conclusion: Intraoperative thrombolysis can be safely used as an adjunct to embolectomy in order to increase limb salvagibility rate in late acute arterial embolism patients.

Outcome in Management of Chronic Venous Leg Ulcer with Compression Therapy

Ruangsetakit C, Luangareeporn T, Chinsakchai K, Wongwanit C, Sermsathanasawadi N

Department of Surgery, Faculty of Medicine, Siriraj hospital, Mahidol University

Background: Chronic venous leg ulcers are considered to be one of problems in the public health system because of their difficulties of healing. The incidence of these leg ulcers in United Kingdom is more than 1%. The standard management of this condition is complicated and has a high cost of treatment. The compression therapy that consists of compression bandaging and graduated compression stocking is one of the effective treatments and the ulcer can be healed about 50-70%.

Objectives: The purpose of this study was to assess the outcome in management with compression therapy.

Material and Methods: The retrospective chart review of patients with chronic venous leg ulcer between July 2004 and June 2009 at leg ulcer clinic, Siriraj hospital was established. The patients who had chronic venous ulcers and palpable distal pulses at ankle or ankle brachial pressure index (ABPI) more than 0.85 were included in this study. The patients were divided in healing within 24 weeks (H) and delayed healing more than 24 weeks (DH) groups. In healing group, they were also divided in non-recurrent (NR) and recurrent within 12 months (R) groups. The factors that may affect the healing or recurrence of the ulcers were studied.

Results: A total of 163 patients were studied. The 24-week healing rate was 60.12% and the duration of healing was 11.26 weeks. The 12-month recurrent rate was 26.53% and the duration of recurrence was 6.04 months. Factors that had significant statistical differences between healing and delayed healing groups were medial side of right leg (39.80% vs. 24.61%, $p = 0.045$), superficial reflux detected from Duplex scan (70.93% vs. 52.83%, $p = 0.031$) and history of varicose veins (64.29% vs. 46.15%, $p = 0.022$). Factor that had significant statistical differences between non-recurrent and recurrent groups was liver cirrhosis (2.77% vs. 15.38%, $p = 0.022$).

Conclusions: This study revealed that patients treated with compression therapy at Siriraj's leg ulcer clinic is effective and comparable with the other studies.

Midterm Overall Survival Rate of Emergency Endovascular Aortic Repair (EVAR) is Comparable to Elective Evar

Nuttawut Tanterdtham, Chumpol Wongwanit, Khamin Chinsakchai, Chanean Raungsetakit, Nuttawut Sermsathanasawadi, Pramook Mutirangura

Vascular Surgery Division, Department of Surgery, Siriraj Hospital, Mahidol University

Objective: To compare the outcomes of endovascular aortic repair (EVAR) between elective and emergency situation.

Materials and Methods: All abdominal aortic aneurysm (AAA) patients who underwent EVAR in Siriraj Hospital from August 2003 to December 2011, were retrospectively reviewed and analyzed. A total 100 consecutive patients were enrolled (78 men, mean age 74). Emergency cases were defined as ruptured AAA (10 cases) and acute non-ruptured (11 cases) who underwent repair within 24 hours. Seventy-nine patients were treated as elective cases and 21 patients were emergently repaired.

Results: The mean follow up time was 2 years and there was no difference between emergency and elective case in term of 30-day mortality rate (5% vs. 1%, $p=0.378$), and mid-term survival (60% vs. 80%, $p=0.109$). But survival free from additional procedure was lower in emergency group (44% vs. 82%, $p=0.017$). The operative time, contrast used, and blood loss were comparable between each group. Emergent EVAR were more likely performed under local anesthesia (33% vs. 3%, $p<0.001$) and less likely fixed by bifurcated stent-graft (43% vs. 73%, $p=0.026$). Higher complication rates in emergency group include infected graft (14% vs. 0%, $p=0.008$) and bleeding (14% vs. 1%, $p=0.028$), whereas there was no significant difference in other implant complication/ deployment complication/ systemic complication and endoleak rate. Greater regression rate of maximal aneurysm sac diameter was found in emergency group (37% vs. 13%, $p=0.008$).

Conclusion: Despite higher additional procedure rate, emergency EVAR might offer a comparable outcome compared to elective repair in term of survival rate.

Perioperative Complication and Mortality Following Radical Cystectomy and Urinary Diversion in Treatment Bladder Cancer in Ramathibodi Hospital

Leelapatree P, Kochakarn W

Division of Urology, Department of Surgery, Faculty of Medicine Ramathibodi Hospital, Mahidol University, Bangkok, Thailand

Background: Morbidity after radical cystectomy is common and associated with increased health care resource use. Accurate characterization of complication after cystectomy, associated patient specific risk factor, and perioperative process of care are essential to direct changes in perioperative management that will reduce morbidity and improve the quality of patient care.

Objective: To review perioperative complication and mortality rates after radical cystectomy in elderly patients and the relationship among age, pathological stage and outcome after this procedure

Methodology: Between 2005 and 2011, 106 medical charts were retrospectively reviewed. All patients underwent radical cystectomy with urinary diversion by resident and staff at Ramathibodi Hospital. Major complication and 90-day postoperative mortality rate were analyzed. Univariate and multivariate analysis were used to define predictor of complication and mortality.

Result: Age significantly affected perioperative morbidity and mortality rate of the patients undergoing radical cystectomy. 32.1% of patient experienced complication within 90 days after surgery and infectious complications were most common (15.9%), followed by wound-related complication (11.2%) and DVT (4.7%). The 90-day mortality rate was 8.4%.

Conclusion: Although age does not preclude radical cystectomy, careful surveillance is required. Excellent perioperative management may contribute to the prevention of morbidity and mortality of radical cystectomy, supplementary to the skill of the surgeon, and is probably a reason for the better perioperative result obtained in high-volume center.

The Efficacy and the Safety of Open Label Tadalafil 5 mg Once Daily Versus Open Label Tadalafil 20 mg Twice Weekly in Thai Males with Erectile Dysfunction

Sappaya Suppanuntaroek, Somphol Permpongkosol

Division of Urology, Department of Surgery, Faculty of Medicine Ramathibodi Hospital, Mahidol University, Bangkok, Thailand

234

Background: Tadalafil is a PDE5-inhiitor that used for restore erectile dysfunction , It is approved by the U.S. Food and Drug Administration (FDA) in October 2011.Tadalafil is used to treat patients with benign prostatic hyperplasia and/or erectile dysfunction. Tadalafil have long half-life (17.5) hours that result in longer duration of action, and so partly responsible for “The Weekend Pill”. The recommended starting dose in men is 10 mg before sexual activity that may be increased to 20 mg or decreased to 5 mg. Tadalafil 5 mg once daily is used in order to avoid the inconvenience of having program and plan for his sexual activity. The benefit and risk when taking tadalafil 5 mg once daily in a period of time will be evaluated.

Objective: To evaluated the efficacy and safety of tadalafil 5 mg once daily for 60 days compare with Tadalafil 20 mg twice a week in men with erectile dysfunction

Methodology: This randomized, open labeled, parallel group study was randomized in 30 patients who visited at our out patient urologic surgery department. Patients who were diagnosed as post operative erectile dysfunction , low testosterone level have been excluded. In this study, Patients were received tadalafil 5 mg or 20 mg for 2 months. Primary outcome was to evaluated the improvement of IIEF15 at 1 month and 2 months after received Tadalafil. Secondary outcome was to evaluated the improvement of IPSS assessment.

Result: Patients who received tadalafil 5, 20 mg have improved in clinical and IIEF score in both groups. One patient experienced headache and flushing that cannot continue in medication. Half of patients received tadalafil 20 mg on demand , all have significantly improved in sexual function. Patient who received tadalafil 5 mg once daily also have significantly improved in sexual function without serious side effect. Only one was drop out due to headache which improved after terminate tadalafil.

Conclusion: Tadalafil have successfully improved in clinical ED and IIEF score which no significantly difference in both groups. The side effect was minimize for both 5 and 20 mg tadalafil.

Medullary Thyroid Carcinoma in King Chulalongkorn Memorial Hospital: Natural History, Management, and Outcome

Natawat Narueponjirakul, Pasurachate Samorn

Department of Surgery, Faculty of Medicine, Chulalongkorn University

Background: Medullary thyroid carcinoma is a rare and a diagnosis difficulty disease. The purpose of this study was to review natural history, management and clinical outcome of medullary thyroid carcinoma.

Methods: Retrospective study of medullary thyroid carcinoma patients was performed at King Chulalongkorn Memorial Hospital from January 1, 2002 to December 31, 2011. Medical records were reviewed in terms of demographic data, clinical presentation, investigation, management and outcomes.

Result: 16 medullary thyroid carcinoma patients were taken into account for 1.06% of all thyroid carcinoma of the hospital. 12 were women and 4 were men. Mean age was 51.9 years. All of them were sporadic case. 75% presented with thyroid nodule. 87.5% underwent fine needle aspiration. Only 4 patients were positive for medullary thyroid carcinoma. Preoperative diagnosis was made only 25% of cases. Preoperative serum calcitonin levels and CEA levels were measured in 4 and 5 patients; the levels were increased in all cases. Regarding mode of treatment, total thyroidectomy, near total thyroidectomy and subtotal thyroidectomy were applied for 11, 2 and 2 patients respectively. In patients with advance disease, cervical lymphadenectomy were adopted (2 prophylactic central neck dissection, 4 prophylactic ipsilateral neck dissection, 6 therapeutic ipsilateral neck dissection and 1 contralateral neck dissection). Median follow up period was 41 months. There was no mortality in this study.

Conclusions: Preoperative diagnosis is still a problem. Only 25% were achieved. Since the lacking of an accurate preoperative evaluation and planning, the treatment varies especially in patients with cervical lymphadenectomy. The operation depends on surgeon's preferences. Although some patients were lost follow up, favorable outcomes and no mortality were noticed in the study.

Cost Effective Analysis of Endoscopic Hemithyroidectomy versus Conventional Open Hemithyroidectomy in Roi-Et Hospital

Chaloemphon Boonmee, Niramon Arayajarernwong, Uemporn Summart

Roi-Et Hospital, Thailand

Background: Endoscopic thyroidectomy recently have been performed to avoid unpleasant neck scar. In Roi-et hospital, total trans-axillary endoscopic thyroidectomy has been developing since 2011. The aim of this study was to evaluate cost of endoscopic hemithyroidectomy compare with conventional open hemithyroidectomy.

Study design: A cost effective study and chart review.

Material and Method: Twenty cases of endoscopic hemithyroidectomy and conventional open hemithyroidectomy in Roi-et hospital between 1st March 2011 to 1st March 2013 were reviewed retrospectively. Total cost, operative cost, anesthesia cost, pathologic and investigation cost data were obtained and statistically analyzed.

Result: Mean total cost (Thai bahts) of endoscopic hemithyroidectomy was higher than conventional open hemithyroidectomy. (16,127.50 versus 25,055.00, P-value<0.01) Operative cost was higher in endoscopic group. (6,789.00 versus 9,775.00, P-value <0.01) Anesthesia cost also was lower in conventional open group. (3,096.00 versus 5,588.80, P-value<0.01) Pathologic and investigation cost were not significantly difference (2,223.00 versus 2,860.00, P-value=0.09)

Conclusion: Cost of endoscopic hemithyroidectomy in Roi-et hospital was higher than conventional open hemithyroidectomy.

Cardiac Output Monitoring During Traumatic Shock Resuscitation Using a Totally Noninvasive Method: Results of A Prospective Study

Nanak Wibonkwan¹, Burapat Sangthong¹, Komet Thongkhao¹, Osaree Akaraborworn¹, Rassamee Sangthong²

¹Department of Surgery, ²Epidemiology Unit, Songklanagarind Hospital, Prince of Songkla University, Songkhla, Thailand

Purpose: Cardiac output (CO) is regarded as one of the most important haemodynamic variables for the assessment and guidance of shock resuscitation in trauma patients. The invasiveness of the standard CO monitoring technique however often precludes the use. We conducted the study to determine the accuracy of a bioelectance-based Non Invasive Cardiac Output Monitoring (NICOM) system by comparing it with the transpulmonary indicator dilution (TPID) technique as a reference method during active shock resuscitation.

Methodology: We enrolled 10 critically ill trauma patients meeting shock resuscitation protocol requiring TPID cardiac output measurement. The resuscitation protocol was a goal-directed process to attain an oxygen delivery index (DO₂I) ≥ 500 mL/min/m² and/or to reduce blood lactate to < 2.5 mmol/L within 24 hrs. The patients were also monitored by the NICOM system and cardiac index (CI) values obtained by the two systems were recorded continuously. Linear regression and the Bland-Altman statistics were used for analysis.

Results: Continuous recording was performed on 10 patients, providing 5,294 simultaneous measurements for each device. Overall, CI was 4.3 ± 1.3 L/min/m² for CI(TPID) and 3.9 ± 1.2 L/min/m² for CI(NICOM). Linear regression revealed no evidence of correlation between CI(TPID) and CI(NICOM) ($r = -0.01$, $p = 0.312$). The mean bias between the two techniques was -0.3 ± 1.7 L/min/m².

Conclusion: Despite the noninvasiveness, CI values obtained with the NICOM system still showed a limited agreement with the reference method. The technology is not suitable to replace invasive CO monitoring at present in trauma patients during active shock resuscitation.

Factors Affecting Intra-abdominal Infection at Maharaj Nakorn Chiang Mai Hospital

Krerkrit Kijpongpan, Kaweesak Chittawatanarat

Department of Surgery, Maharaj Nakorn Chiang Mai Hospital, Chiang Mai, Thailand

Background: Intra-abdominal infection (IAI), especially secondary peritonitis, is a common surgical disease and an important cause of mortality and morbidity. The goal of current research is to identify factors that affect mortality of IAI patients.

Methods: Patients with IAI treated at a Maharaj Nakorn Chiang Mai hospital over 4 years (January 2008- December 2011) were retrospectively reviewed. Collected data included demographics, source of infection, Charlson Comorbidity Index, history of steroid usage, preoperative nutritional status, APACHE II score, SOFA score at admission and postoperative day 3, 7, 14, 21 (POD-3, 7, 14, 21 respectively), type of intervention (operation versus percutaneous drainage), interval from diagnosis to intervention, type and amount of antibiotic usage, type and number of organism from intra-abdominal culture and postoperative complications.

Results: A total of 4,515 IAI cases, of which 494 had valid microbiological data. The most common source of IAI was hepatopancreatobiliary system (n=233, 47.17%). The analysis demonstrated that Charlson comorbidity index (mean = 2 points, $p<0.001$), pre-operative serum albumin (mean = 2.6mg/dl, $p=0.001$), APACHE II score (mean = 11 points, $p<0.001$), SOFA score day 0 ($p<0.001$), day 3 ($p<0.001$), day 7 ($p<0.001$), day 14 ($p=0.008$), day 21 ($p<0.001$), hospital stay (mean = 11days, $p<0.001$), ICU stay (mean = 4days, $p=0.003$) were independent risk factors for mortality. The most common antibiotic usage was combined regimens (n=446, 90.28%), Ceftriazone plus Metronidazole were more frequently. The most common detected organisms were *Escherichia coli* and *Klebsella pneumonia* respectively.

Conclusion: These results suggest mortality from IAI is strongly related to the Charlson comorbidity index, pre-operative serum albumin, APACHE II score, SOFA score.

The Role of Hospital Information Systems (HIS) and Electronic Medical Records (EMR) in Robotic Surgery

Hermann Gruenwald

Burapha University

The purpose of this study is to explore the role Hospital Information Systems (HIS) and Electronic Medical Records (EMR) play in robotic surgery. Computer assisted surgery has come a long way from the PUMA 560 system of 1985 to the current day Da Vinci Surgical System. It certainly offers great potentials and benefits for both the surgeons and the patients. One has to be aware of the limitations of the surgical system as well as its best application for various surgical procedures ranging from general, urology, gastrointestinal, to neurosurgery. This study exams how computer assisted surgical systems can be integrated with the Hospital Information System (HIS), Laboratory Information System (LIS) and medical images from the Computer Axial Tomography (CAT) scans and Magnetic Resonance Imaging (MRI) along with digital x-rays from the Picture Archiving and Communication System (PACS) to form the clinical part of the electronic medical record of the patient. The study looked at public (Siriraj, Ramathibodi) and private (Bangkok) hospitals in Thailand and their preparedness to implement robotic surgery in conjunction with electronic medical records and hospital information systems. The methodology used was grounded theory with in-depth probing open ended interviews, secondary information was collected from public sources. In summary the study showed that computer assisted surgical systems generate a tremendous amount of electronic data and medical records which can lead to data overload and are best dealt with through integrated Hospital Information Systems (HIS). In conclusion robotic surgery results in more EMR, which require the integration with the HIS to be useful for clinical and administrative purposes.

Characteristic and Treatment Outcome of Necrotizing Fasciitis of Maharaj Nakorn Chiang Mai Hospital

Kaweesak Chittawatanarat¹, Poj Panapisal²

^{1,2}Department of Surgery, Maharaj Nakorn Chiang Mai Hospital, Faculty of Medicine, Chiang Mai University, Chiang Mai, Thailand

Background: Necrotizing fasciitis is a life threatening soft tissue infection. Prompt diagnosis and immediate aggressive surgical debridement of all compromised tissues are critical to reducing morbidity and mortality in these rapidly progressive infection.

Objectives: The purposes of research were to analyse the necrotizing fasciitis in Maharaj Nakorn Chiang Mai Hospital, in terms of mortality rate, clinical feature, location of infection, microbiology, drug sensitivity, type of therapy, outcome (discharge type) and to identify factors that impacted on mortality.

Materials & Methods: Patients of a tertiary referral university hospital in the Northern of Thailand were retrospectively reviewed. Medical records of 195 patients who were diagnosed and treated for necrotizing fasciitis from 2005 to 2012 were collected. Others skin and soft tissue infection were excluded.

Results: Of these 8-year data collection, 195 patients were enrolled (152 survive and 43 dead). The prevalence of this disease was higher in males than females with the ratio of 1.64:1. An average age of patients was 58 (range, 5-96). The diabetes mellitus (35.9%) was the most common predisposing disease. The most common etiology of infection was ulcer (55.90%). The most common location was lower leg (50.26%). Common clinical manifestations include swelling (100.00%), pain (96.92%), erythema (96.92%) and hemorrhagic bleb (84.62%). The apache 2 score (18.6% VS 49.7%, $p < 0.0001$) and SAPS 2 score (67.2% VS 12.8%, $p < 0.0001$) were significant lower in survive group than in the dead group. Treatment include emergency operation (92.82%), surgical debridement (82.32%). The overall mortality rate was 16.41%. Follow up status was complete recovery (46.15%) and functional limitation (31.79%). Pus culture was positive at the rate of 70.56%. The most common identified organism was *Streptococcus pyogenes* (43.62%). Risk factors significantly associated with mortality were age ($p=0.009$, odds ratio (OR) = 1.03) and hypotension ($p= 0.005$, odds ratio (OR) = 3.01).

Conclusions: Early recognition and treatment of necrotizing fasciitis and operative debridement reduce mortality of the patients. A high index of suspicious is important in view of the paucity of specific cutaneous finding in the early course of disease.

??

Relationship between Values of CA 15-3 and CEA and Staging, Recurrence Rate and Type of Recurrence in Breast Cancer Patients in King Chulalongkorn Memorial Hospital

Chotitath Sattayakijakorn, Sopark Manasnayakorn

Department of Surgery, Faculty of Medicine, Chulalongkorn University

Background: The utility of carbohydrate antigen 15-3 (CA 15-3) and carcinoembryonic antigen (CEA) as prognostic factors in staging and recurrence aspect in primary breast cancer is unclear, especially in Thai patients.

Objective: To evaluate relationship between values of CA 15-3 and CEA and staging, recurrence rate and type of recurrence in breast cancer patients in King Chulalongkorn Memorial Hospital

Design: Retrospective descriptive study

Setting: Department of Surgery, Faculty of Medicine, Chulalongkorn University

Materials and Methods: We retrospectively studied CA 15-3 and CEA in the sera of 826 patients with untreated primary breast cancer diagnosed between 2006 and 2010.

Result: Increased CA 15-3 (>30 kU/L) and CEA (>5 mcg/L) values were found in 10.41% and 12.35% of the patients, respectively, and one or both tumor markers were increased in 17.14%. Increases in each tumor marker correlated with larger tumor size, nodal involvement, presence of metastasis and staging. Local recurrence and distant metastasis were found in 5.36% and 10.26% of the patients with increased CA 15-3 (>30 kU/L), respectively, and found in 10.71% and 11.95% of the patients with increased CEA (>5 mcg/L), respectively. In comparison of the values of CA 15-3 between before and after treatment, 12.25% of the patients with higher values after treatment developed local recurrence and 9.03% of them developed distant metastasis. Similarly in CEA, 7.81% of the patients with higher values after treatment developed local recurrence and 7.29% of them developed distant metastasis.

Conclusion: CA 15-3 and CEA are correlated with tumor size, nodal status, presence of metastasis and staging of breast cancer. Because of a lack of sensitivity, especially for early disease, preoperative values might be combined with other prognostic factors for predicting outcome. The most important clinical application of CA 15-3 and CEA is monitoring therapy.

Management of Liver Injury: Predictors for the Need of Operation and Damage Control Surgery

Sirinawin Chayatat

Department of surgery, Faculty of medicine, Chulalongkorn university

Background: Liver is the most common solid organ injuries in blunt abdominal trauma. In the new era, management of liver injury is multidisciplinary approach such as Non-operative management, damage control surgery, angiogram embolization etc.

Objectives: In this study, we reviewed our experience of trauma patients with liver injury in our institute and aimed to assess predictors for the need of operative management and damage control surgery.

Patients and Methods: This retrospective study was done by review 218 patients with liver injury who were admitted at King Chulalongkorn Memorial hospital from May 2002 to April 2011. The demographics data, ED parameter (SBP, PR, GCS, ISS, RTS, TRISS, Hct and BE), Grade and anatomy of liver injury, type of management, outcomes (blood components transfusion, complications, ICU day, ventilator day, length of stay and mortality rate) were collected and compared by logistic regression multivariate analysis.

Results: Two hundred and eighteen patients with liver injuries were identified. 154 patients had blunt mechanism, 62 patient had penetrating and 2 patients had combined mechanism. 64 patients were treated with non-operative management (NOM), 6 patients was failed NOM then convert to operative management and mortality rate of NOM was 1.6%. 160 patients (include 6 patient who failed NOM) were treated with operative management and mortality rate was 24%. The independent predictors for the need of operative management were penetrating mechanism, RTS, pulse rate and the independent predictor for damage control surgery was ISS > 15.

Conclusion: In our institute mortality rate of liver injury patients was acceptable (overall mortality rate 17.4%). The factors that have impact for management were penetrating mechanism, RTS, pulse rate, ISS > 15.

Outcome of Autogenous Hemodialysis Access in Siriraj Hospital

Panuwat Chuemor, Khamin Chinsakchai, Chumpol Wongwanit, Chanean Ruansetakit, Pramook Mutirangura

Department of Surgery, Siriraj Hospital, Bangkok

Background: Majority of hemodialysis cases in Thailand use arteriovenous fistula. According to KDOQI guideline 2006 recommendation, Siriraj Hospital has incorporated duplex ultrasonography for pre-operative vascular mapping for years. This is the first study to assess the rate of maturation and to identify whether vein diameter is a major predictor of outcome.

Methods: All autogenous arteriovenous fistulas created in Siriraj Hospital from July 1, 2010 to February 28, 2012 were included in retrospective review. Patients with incomplete data and arteriovenous bridge graft were excluded.

Results: A total of 150 autogenous arteriovenous fistulas were analysed. Wrist radiocephalic arteriovenous fistulas were accounted for 37% with maturation about 80%. Brachiocephalic arteriovenous fistulas were accounted for 24% with maturation about 85%. Brachio-antecubital arteriovenous fistulas were accounted for 33% with maturation about 94%. Brachio-basilic arteriovenous fistulas were accounted for 6% with maturation about 100%. Selection of vein diameter greater than 3 mm for radiocephalic fistula creation led to maturation of 100%. Failure to maturation occurred in 20% of radiocephalic fistula with vein diameter less than 3 mm.

Conclusion: Brachio-antecubital, brachio-basilic fistulas have rate of maturation more than brachio-cephalic and radiocephalic arteriovenous fistula, respectively. For radiocephalic arteriovenous fistula, vein diameter greater than 3 mm matured about 100%.

The Prognostic Role of Human Epidermal Growth Factor Receptor 2 Overexpression/Amplification in Woman with Node-Negative Breast Cancer

**Laliphat Kongpanichakul¹, Somrit Mahattanabol¹,
Pleumjit Boonyaphiphat², Srila Samphao¹**

¹Department of Surgery, Faculty of Medicine, Prince of Songkla University, Hat Yai, Songkhla, Thailand 90110

²Department of Pathology, Faculty of Medicine, Prince of Songkla University, Hat Yai, Songkhla, Thailand 90110

Objective: Overexpression/amplification of human epidermal growth factor receptor 2 (HER-2) is associated with a poorer outcome in node-positive breast cancer, but the results are conflicting in node-negative disease. We wish to evaluate the prognostic impact of HER-2 positive in node-negative breast cancer.

Methods: All patients with node-negative breast cancer was identified among 571 patients who underwent HER-2 testing at Songklanagarind hospital from 8/2005 to 12/2009. Patient features and tumor characteristics, including adjuvant therapy were compared between patients with HER-2 positive and HER-2 negative cancers. Relapse-free survival (RFS), distant relapse-free survival (DRFS), breast cancer-specific survival (BCSS) and overall survival (OS) were compared between groups.

Results: We identified 152 patients with node-negative breast cancer. Thirty-five (23%) patients had HER-2 positive and 108 (77%) had HER-2 negative cancers. Over half (63%) of HER-2 positive cohorts was younger than 50. No difference between operative procedures performed between the two groups.

Most of patients had stage I (57% vs 52%), invasive ductal carcinoma (94% vs 81%). However, 80% of the HER-2 positive group had grade 2-3 tumors, compared with 56% in the HER-2 negative group ($p=0.005$). One thirds of patients in each group had ER negative tumors. Almost all patients (94%) in the HER-2 positive group received adjuvant chemotherapy and over half received adjuvant hormonal therapy.

Median time to follow-up was 52 months (range 1-83). There were trends to decrease RFS and DRFS in the HER-2 positive, compared with the HER-2 negative group (RFS: HR 2.46, 95%CI 0.75-8.06; DRFS: HR 2.38, 95%CI 0.64-8.88). In HER-2 positive patients, there were trends to decrease RFS and DRFS in patients younger than 50 (RFS: HR 2.57, 95%CI 0.29-23.00; DRFS: HR 1.78, 95%CI 0.18-17.15) and those who had ER positive tumors (RFS: HR 3.61, 95%CI 0.39-33.65; DRFS: HR 2.71, 95%CI 0.27-27.10). Adjuvant hormonal and chemotherapy were independent factors to improve RFS (HR 5.11, $p = 0.03$) and DRFS (HR 5.61, $p = 0.02$).

Conclusions: Patients with node-positive HER-2 positive breast cancer have a trend to increase risk of recurrence at 5 years of follow-up, particularly in younger and ER positive patients. Adjuvant hormonal and chemotherapy effect survival outcomes.

Outcome of Liver Transplantation in Hepatocellular Carcinoma Patients in Siriraj Hospital

***Yongyut Sirivatanauksorn¹, Vutthipong Sanphasitvong¹,
Prawat Kositamongkol¹, Ananya Pongpaibu², Somchai Limsrichamrern¹***

¹HPB and Transplantation Unit, Division of General Surgery, Department of Surgery, Faculty of Medicine Siriraj Hospital, Mahidol University, Bangkok 10700, Thailand

²Department of Pathology, Faculty of Medicine Siriraj Hospital, Mahidol University, Bangkok 10700, Thailand

Background: Hepatocellular carcinoma is the fifth most common cancer of the world and third leading cause of cancer death. Curative treatment of hepatocellular carcinoma are hepatectomy and orthotopic liver transplantation. But hepatectomy could be done in only 10- 30% of patients because of multifocal disease and cirrhotic liver. Liver transplantation is the only curative option for these unresectable patients whose tumors match Milan's criteria. In Siriraj Hospital, liver transplantation has been started since 2002. Between 2002 and 2011, 137 cases of liver transplantation have been done. 63 cases (45.9%) were hepatocellular carcinoma.

Objective: The aim of this study is to review 1 and 5 year survival rate of the patients and factors which determine survival or recurrent of disease.

Materials and Method: Medical records of all patients with hepatocellular carcinoma who underwent liver transplantation between 2002 and 2011 have been retrospectively reviewed. Data was collected including demographic data, underlying diseases, number of tumor, maximum size of tumor, extrahepatic metastases, vascular invasion, pathological report, survival duration, disease free duration, cause of death and bridging therapy data. The said data has been analyzed using SPSS version 18 in survival analysis and descriptive analysis.

Result: 1 year survival rate was 78% and 49% for 5 year survival, no significant difference was found for liver transplantation patients with hepatocellular carcinoma compared with all liver transplantation patients in Siriraj Hospital. Most common cause of death is recurrent disease. Most common comorbidity is hepatitis B viral infection. 98.4% of the patients matched Milan's criteria by clinical but only 63.5% by pathological report. Survival of both groups are not significantly different. Maximum tumor size greater than 8 cm and number of tumor more than 3 significantly affected survival rate of the patients. In contrary, bridging therapy has no effect on survival or recurrence rate. In addition, portal vein thrombosis was found as a significant factor determining recurrence.

Conclusion: 1 and 5 year survival rate of liver transplantation in hepatocellular carcinoma patients are 78% and 49%. Disease free survival at 1 and 5 years are 89% and 66%. Most common cause of death is recurrent disease. Tumor size greater than 8 cm and number of tumor more than 3 are significant factors of poor survival rate. Portal vein thrombosis is a significant risk factor of recurrent disease. Bridging therapy does not affect the outcome of the patients.

Young Investigator Award

Clinical Significant after Training with Virtual Laparoscopic Training Box

Taweesak Tongtawee, Somboon Subwongjaroen

Department of Surgery, Rajavithi Hospital, Bangkok 10400, Thailand

Background: To define the ability of a training box simulator to reflect clinical skill in surgical residents, we compared clinical laparoscopic performance and staff of department of surgery in Rajavithi hospital.

Methods: six postgraduate year residents were assessed during laparoscopic training box. Operative performance data were collected at the conclusion of procedures by Microsoft lifecam. During this period, all residents undertook iterative laparoscopic training box in three stations and laparoscopic training box data (mean time) were tested by Wilcoxon sign Ranktest and compared with training box data of staff in Rajavithi Hospital by Mann-Whitney U Test.

Results: Significant improve surgical skill performance after (post-test) training box programs. The statistical analysis shown reduced in all mean times (10.151, 3.245, 3.241) in three Training box station and significant ($p=0.028, 0.028, 0.028$) in all station after (post-test) Training box programs. we compared six postgraduate year resident with staff of Rajavithi hospital. The statistic analysis shown no significant ($p=0.33, 0.42, 0.150$) after (post-test) training box programs.

Conclusions: These data indicate that laparoscopic Training box simulator can improve surgical skill performance of six postgraduate year residents.

Metatarsal Bone Osteotomy (Transection) for Treating Recalcitrant Chronic Callous Forefoot Ulcer in Diabetic Patients

Taweesak Srikummoon

Theptarin Hospital, Bangkok, Thailand

Background: Diabetic foot ulcer will lead to toes or other major amputation and more complicated problems. Metatarsal bone osteotomy (transection) is a simple technique to treat recalcitrant chronic callous forefoot ulcer under the 3 middle lesser toe bases or the 2nd to 4th metatarsophalangeal joints (MTPJ) in diabetic patients.

Objective: To present the technique and early result of this operation.

Method: Ten diabetic patients underwent metatarsal bone osteotomy (transection) for treating recalcitrant chronic callous forefoot ulcer in 2 hospitals by single surgeon between 2009 -2011 were reviewed. Mean patients' age is 55.1 years old, 7 males and 3 females. The surgical technique consisted of metatarsal osteotomy(transection) performed through a dorsal approach without fixation and trimming of the plantar callous ulcer under ankle block and/or local field block, one night hospital stay and no post-op.casting.

Result: Early ambulation in the first week, complete ulcer healing was 10 cases(100%) at an average of 4 weeks postoperatively without complications except slight dorsal swelling or bulge in 3 cases (30%). There was no case of callous ulcer recurrence using only simple diabetic shoes.

Conclusion: The recalcitrant chronic callus ulcer under the central MTPJ in diabetic foot is able to heal with this simple technique, metatarsal bone osteotomy (transection).

Key words: diabetic foot chronic recalcitrant callous forefoot ulcer, metatarsal bone transection or osteotomy, salvage procedure

Outcome of Treatment Large Common Bile Duct Stone by Spy Glass Cholangioscopy in Rajavithi Hospital

Suwitchakul C, Ratanachu-ek T, Wannapasert J, Panpimanmas S, Chantawibul S*

*Department of Surgery, Rajavithi Hospital, Bangkok, Thailand

Background: The SpyGlass peroral cholangiopancreatography system(Boston Scientific Corp, Natick, MA, USA) has been available since 2007.This novel technology provides the endoscopist with a direct intraluminal view of the biliary system.The goal of the system was to overcome the limitations of prior choledochoscopes and simplify peroral cholangioscopy.

Objective: The purpose of the present study was to study success rate and post-endoscopic complications in large common bile duct stone patients who underwent Spyglass cholangioscopy.

Reserch design: Retrospective descriptive study

Material and Method: All records of the patients who underwent Spyglass cholangioscopy between January 2010 and May2013 were reviewed. The success rate and complications were analyzed .

Results: From 1728 patients, 11 patients met the inclusion criteria. Only 0.6% of large common bile duct stone need SpyGlass cholangioscopic guided therapy. Overall success rate was 90.9%. Almost patients presented with single large stone. Nine patients failed to remove large CBD stones by multimodality conventional method but can decrease size from 2.34 ± 0.86 cm to 1.87 ± 0.51 cm before used Spyglass system.

Conclusion: SpyGlass cholangioscopy with laser lithotripsy is safe and effective for management of patients with bile duct stone who have failed conventional endoscopic approaches. Despite its effectiveness, the SpyGlass system has been underutilized mainly due to its fiber optic image quality which is inferior to its fiber optic image quality.

Keywords: Spyglass cholangioscopy

Comparison between Laparoscopic Sleeve Gastrectomy and Laparoscopic Roux-En-Y Gastric Bypass Effect on Diabetes Control: A Preliminary Report of A Prospective Randomized Clinical Trial

Ajjana Techagumpuch, Pakkavuth Chanswangphuvana, Soravith Vijitpornkul, Teeranun Tiyanpanjanit, Chadin Tharavej, Suppa-ut Pungpapong, Patpong Navicharern, Suthep Udomsawaengsup

Department of Surgery, King Chulalongkorn Memorial University, Bangkok, Thailand

Background: Bariatric surgery has been demonstrated efficacy on weight loss and also the comorbidity resolution especially diabetes. Gastric bypass(LRYGB) is still the standard procedure and thought to have the major role in glucose homeostasis and diabetes control. Sleeve gastrectomy(LSG) is gaining the popularity as an option procedure in morbid obese patient with comparable outcome to gastric bypass in previous study. However there is still lack of data in Thailand.

Objective: Primary end point is to glycemic control at 6 months after LSG and LRYGB surgery. Secondary outcome is to evaluation of excess weight loss.

Method: A prospective, randomized clinical trial in morbid obese patient with type 2 diabetes (T2DM). This study performed in Thai patient with age between 15-60 years, BMI 32.5-60, history of T2DM less than 10 years and preoperative HbA1c more than 7.0. At 6 months after surgery to evaluate fasting plasma glucose, HbA1c, % excessive weight loss and the reduction of antihyperglycemic drugs use.

Result: 28 patients were randomized to 15 patients in LSG group and 13 patients in LRYGB group. Average EWL was 32.76% in LSG group and 55.07% in LRYGB group ($P=0.02$). reduction in mean HbA1c level from 9.01 to 5.72 in LSG group and from 8.93 to 5.56 in LRYGB group ($P=0.124$). Both groups show decrease of FPG and antidiabetes drugs use after surgery but no statistic significant difference between two groups.

Conclusion: LRYGB is more effective on weight loss with statistic significant. However Sleeve gastrectomy may have comparable effect in diabetic control to LRYGB.

Resident Papers Award

The Size of Upper Midline Incision in Laparotomy Witzel Jejunostomy Technique Associated with Small Bowel Obstructions: 6 Years Retrospective Analysis in Esophageal Cancer Patients at King Chulalongkorn Memorial Hospital (Pilot Study)

Benjaporn Nimitrvanich, Chadin Tharavej

Department of surgery, King Chulalongkorn Memorial Hospital

Backgrounds: Open Witzel jejunostomy jejunostomy was selected in esophageal cancer patients at King Chulalongkorn Memorial Hospital to correct nutritional status. The small bowel obstructions occurred. The size of upper midline incision was the key factor for this complication. We tried to find out the correlation between the size of upper midline incision and the occurrence of small bowel obstructions after this operation be done.

254

Table 1 comparison of primary outcome between the 2 incisions

Size of incision	Small bowel obstruction	Reoperation rate	Postoperative hospital stays (day)
Small size (n=69)	11(15.94%)	11(15.94%)	10
Large size(n=37)	0	1(2.7%)	7
p-value	0.01	0.04	0.063

Objectives: To analyze the size of upper midline incision in open Witzel jejunostomy associated with small bowel obstructions, the reoperation rate, postoperative hospital stays, and the peak postoperative pain score between 2 groups of incisions.

Materials and Methods: Retrospective analysis in 106 esophageal cancer patients' data underwent open Witzel jejunostomy at King Chulalongkorn Memorial Hospital from December, 2007 to May, 2013. We used either Mann-Whitney U test for ordinal data variables and non-distribution numerical data or Chi-square for nominal variables. Significance was defined as $p < 0.05$. All values are given as either the mean \pm SD, median or a percentage.

Results: The small bowel obstructions occurred 11 cases (10.4%), all 11 cases (15.94%) in the small size group (N =69 cases) significantly developed small bowel obstructions. No small bowel obstruction occurred in the large size incision group (N=37 cases).12 cases (11.3%) had to re-operate, significantly in small incisions (11 cases, 15.94%), and 1 patient (2.7%) in the large incision. The postoperative hospital stays in the large incision were insignificantly

lessened as described in the table1. The peak post-operative pain score during the day in both incisions was depicted in the figure 1.

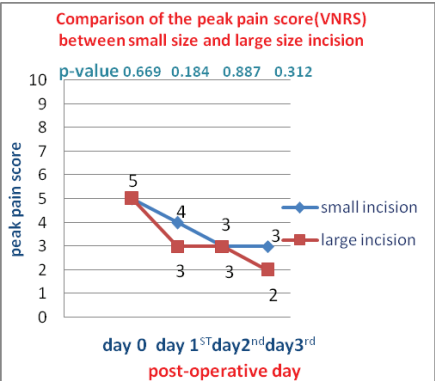


Figure 1 Comparison of pain score by using Verbal Numerical rating Scale (VNRS) between 2 incisions

Conclusions: In the large size incision, significantly none in the small bowel obstruction lessened in the re-operations and insignificantly lowered postoperative hospital stays. Meanwhile, the peak post-operative pain score during the day was the same. The large incision had no drawbacks in this operation.

Endoscopic obstruction determines risk of acute events requiring emergency operation in colorectal cancer patients

Virote Chaleawpanyawong¹, Teeranut Boonpipattanapong^{1,2}, Paradee Prechawittayakul³, Surasak Sangkhathat^{1,2}

¹Department of Surgery, Faculty of Medicine, Prince of Songkla University, Hat Yai, Songkhla, Thailand 90110

²Tumor Biology Research Unit, Faculty of Medicine, Prince of Songkla University, Hat Yai, Songkhla, Thailand 90110

³Cancer Registry Unit, Songklanagarind Hospital, Faculty of Medicine, Prince of Songkla University, Hat Yai, Songkhla, Thailand 90110

Introduction: Unplanned emergency operation in colorectal cancers (CRC) is generally associated with increased risk of operative complications. This study aimed to evaluate an association between an endoscopic finding of obstructing tumor and subsequent need for emergency operation, with an aim to use this finding to select CRC cases who requires an urgent operation.

Methods: CRC cases operated on in our institute during the years 2002-2011 were retrospectively reviewed regarding their endoscopic obstruction (eOB), defined as luminal obstruction of the colon or rectum at the severity that a colonoscope could not be passed beyond the tumor. eOB was analyzed against outcomes in terms of need for emergency operation, surgical complications and overall survival (OS).

Results: A total of 329 CRCs had complete colonoscopic data and were operated on during the study period. eOB was diagnosed in 209 cases (64%). Occurrence of eOB was not correlated with clinical symptoms. Colon cancer had more incidence of eOB (70%) when compared to rectal cases (50%, p -value < 0.01). eOB was significantly associated with higher tumor size and more advanced T-stage (p < 0.01). Twenty-two cases (7%) required an emergency operation before their scheduled elective surgery. The cases with eOB had a significantly higher risk of requiring an emergency operation (p -value < 0.01), which had more post-operative complications (36%) than elective procedures (13%, p -value 0.01) and poorer OS (p -value < 0.01).

Conclusion: Regardless of the presenting symptom, evidence of luminal obstruction at the degree that a colonoscope could not pass should prompt a CRC patient for an urgent surgery.

Role of Matrix Metalloproteinases (MMP-11) Expression in Cholangiocarcinoma Specimens

Supachai Chanvitan¹, Kawin Leelawat^{1,2}, Niphol Praditpol³, Supathip Jujinda⁴

¹Department of Surgery, Rajvithi Hospital, Bangkok, 10400, Thailand

²Colleges of Medicine, Rangsit University, Bangkok, 10400, Thailand

³Department of Pathology, Rajvithi Hospital, Bangkok, 10400 4Immunohistochemistry section, Rajvithi Hospital, Bangkok, 10400, Thailand

Background: Cholangiocarcinoma is known as one of the most aggressive malignant tumors associated with local invasion and a high rate of metastasis. A crucial step in the invasion process is the proteolytic degradation of the extracellular matrix (ECM) and basal membranes. Among the enzymes responsible for ECM degradation, several studies have shown a critical role played by matrix metalloproteinases (MMPs). MMP-11 is found over expression in almost every aggressive malignancy. However, until now there has been no research about the expression of Matrix metalloproteinase (MMP-11) in Cholangiocarcinoma specimens.

Objective: Detection of matrix metalloproteinase-11 expression in cholangiocarcinoma specimens and analyzing the relationship between expression matrix metalloproteinase-11 and survival time

Materials and Methods: This was a retrospective analysis of 30 patients with cholangiocarcinoma in Rajvithi hospital, who had undergone immunohistochemistry staining of MMP-11. Statistical analysis of the association between clinicopathological data and the expression of Matrix Metalloproteinase (MMP-11) in cholangiocarcinoma specimens was performed using the χ^2 test or Fisher's exact test. The Kaplan-Meier method was used to estimate survival as a function of time, and the survival differences were analyzed by log-rank test. A p-value <0.05 was considered statistically significant.

Results: MMP11 expression were found in 15 specimens (50%). The overall mean survival time is 236.97 days (95% CI 135.44-338.49, standard deviation of 271.88). Specimens with a positive MMP-11 had an average survival time of 136.73 days (95%CI 50.33-223.13, standard deviation of 156.019). Survival differences was analyzed by log-rank method, between the positive MMP-11 and negative MMP-11 (p-value = 0.22), between well differentiated tumor and moderate to poor differentiated tumor (p-value = 0.755), between CA19-9 level of > 1,000 and < 1,000 (p-value = 0.488), and, between advanced staging and non-advanced staging (p-value = 0.388).

Conclusion: Expression of matrix metalloproteinase-11 in cholangiocarcinoma specimens significantly correlates with survival outcome.

Pre-operative Plasma Fibrinogen Level Correlates with Lymphatic and Distant Metastasis in Colorectal Cancer

Daryth Suwannarat¹, Teeranut Boonpipattanapong^{1,2},

Samornmas Kanngern^{2,3}, Surasak Sangkhathat^{1,2}

¹Department of Surgery, Faculty of Medicine, Prince of Songkla University, Hat Yai, Songkhla, Thailand 90110

²Tumor Biology Research Unit, Faculty of Medicine, Prince of Songkla University, Hat Yai, Songkhla, Thailand 90110

³Anatomical Pathology Unit, Department of Pathology, Faculty of Medicine, Prince of Songkla University, Hat Yai, Songkhla, Thailand 90110

Introduction: Activation in the coagulation system and hyperfibrinogenemia has been implicated in various malignancies including colorectal cancer (CRC). Fibrinogen may involve in tumor progression and metastasis. This study aimed to evaluate correlation between plasma fibrinogen and tumor stage in CRC.

Methods: The study was a prospective cohort that recruited CRC patients who underwent definitive surgery in Songklanagarind Hospital during the period from December 2012 - May 2013. Eighty-three patients, 30 rectal cancers and 53 colonic cancers, were tested for plasma fibrinogen and d-dimer at pre-operative date, post-operative day (POD) 1 and POD7. Data were analyzed against their clinical and pathological parameters.

Results: Mean pre-operative plasma fibrinogen level was 623 mg/dl, with 90% of patients had a level of more than 400 mg/dl. Pre-operative fibrinogen in N1-2 CRC (666 mg/dl) was significantly higher than that of N0 (579 mg/dl) (p-value 0.02). Consistently, CRC with distant metastasis had significantly higher pre-operative fibrinogen level (704 mg/dl) than those with locoregional disease (595 mg/dl) (p-value < 0.01). In addition, d-dimer in metastatic CRC (2.6 ug/ml) was also significantly elevated when compared to non-metastatic cases (1.1 ug/ml) (p-value < 0.01). Compared to the pre-operative level, plasma fibrinogen on the POD1 and POD7 raised by 7.3% and 17.5%, respectively. However, the post-operative fibrinogen level was not correlated with the metastatic status.

Conclusion: Hyperfibrinogenemia in CRC patients correlates with lymph node and distant metastasis. Pre-operative plasma fibrinogen is a potential biomarker of advanced disease in patients diagnosed with CRC.

Resident Papers Award

The Role of Vascular Endothelial Growth Factor Polymorphisms in Breast Cancer Susceptibility and Aggressiveness

Doonyapat Sa-nguanraksa¹, Tuenjai Chuangsuwanich², Tawatchai Pongpruttiparn², Suwattanee Kooptiwut³, and Pornchai O-charoenrat¹

¹Division of Head-Neck and Breast Surgery, Department of Surgery, Faculty of Medicine, Siriraj Hospital, Mahidol University, Bangkok, Thailand

²Department of Pathology, Faculty of Medicine, Siriraj Hospital, Mahidol University, Bangkok, Thailand

³Department of Physiology, Faculty of Medicine, Siriraj Hospital, Mahidol University, Bangkok, Thailand

Breast cancer is the most frequent cancer of women worldwide and also in Thailand. Angiogenesis, the formation of new blood vessels, has an important role in the development and progression of breast cancer. Polymorphisms in the promoter and 5' untranslated region of vascular endothelial growth factor (VEGF) have been associated with susceptibility and aggressiveness in several cancers.

To investigate the role of VEGF polymorphisms in breast cancer, VEGF -2578C/A, -1498C/T, -1154G/A and -634G/C were genotyped in 483 breast cancer patients and 524 healthy controls employing amplification refractory mutation system-polymerase chain reaction (ARMS-PCR) and PCR-restriction fragment-length polymorphism (PCR-RFLP). Levels of VEGF mRNA expression in breast cancer tissue were determined by quantitative reverse transcription-PCR (RT-PCR). Activity of VEGF promoter bearing different polymorphisms was determined.

Patients with -634GC and -634CC genotype had increased risk of breast cancer when compared to -634GG genotype. VEGF-634GC genotype was associated with larger tumor size, more advanced stages, presence of perineural invasion, and lower disease-free survival. Patients with VEGF-634CC genotype had significantly higher VEGF mRNA levels than those with -634GG or -634GC genotype. High VEGF mRNA expression was correlated with larger tumor size, presence of axillary nodal metastasis, and presence of lymphovascular invasion. Functional analysis in breast cancer cell line revealed that the promoter bearing -1498T/-634C haplotype had highest transcriptional activity.

These findings suggested that VEGF-634G/C polymorphisms have a significant role in breast cancer susceptibility and aggressiveness and may be used for the identification of patients suitable for anti-VEGF therapy.

Simplified Rat Model for Assessment of Functional Recovery after Facial Nerve Repair

***Santi Kuladee, Narong Punyahotra, Kidakorn Kiranantawat,
Noppadol Laphjareonsap, Dissaya Lohavech, Yaowanit Suwinchai,
Ariya Unprasoet***

Division of Plastic and Maxillofacial Surgery, Department of Surgery,
Department of Pathology, Faculty of Medicine, Ramathibodi Hospital Department of Central
Animal Facility, Faculty of Science, Mahidol University

Introduction: The standard treatment for peripheral nerve transection remains the primary tensionless repair. Basic knowledge is usually acquired from experiments in animal models. The authors are trying a rat facial nerve model which the outcome of nerve regeneration is simply assessed by vibrissae movement. The study compares the outcome between interpositioned nerve graft to a reverse nerve graft repair in a segmental defect of buccal branch of facial nerve, while the donor nerve is also a motor nerve, the marginal mandibular branch of the ipsilateral facial nerve.

Objectives: 1. To learn more on facial nerve model in rat.

2. To study the functional outcome of using reversed nerve graft segment and from another motor nerve donor to repair a segmental defect of a motor nerve.

Methods: Fourteen rats were divided into two groups, seven rats in each group. Group I - A 5 mm nerve segment was resected from the buccal branch of left facial nerve. This gap was bridged with a nerve graft from the ipsilateral marginal mandibular branch of facial nerve by microsurgical technique. Group II - Reverse nerve graft was used in the similar defect. Direct nerve stimulation and nerve biopsy for axonal count were performed 8 weeks after operation. Functional outcome was scored by degrees of vibrissae movement, grade 0 - 4, comparing to the normal right side of the face, by three independent observers.

Results: The onset of recovery time of the vibrissae movement were between 4 - 6 weeks after the operation. The vibrissae movement after 8 weeks was in grade 2-3. There were no differences between two groups in onset of recovery time and grading of vibrissae movement. The vibrissae movement was also observed, during direct nerve stimulation, only on repaired buccal branches in both groups. There was no difference of axon count between two groups.

Conclusions: This rat model for evaluation of functional recovery after facial nerve repair is simple. Comparing of the vibrissae movement between left and right side of the face is also simple for the observers. The quality of life of experimented rat should be better than paralysis of hindlimbs in sciatic nerve study model. The study also shows that reversal of nerve graft segment, from another motor nerve, has no effect on recovery of the motor function.

LED Light Effect on Proliferation of Fibroblast from Human Diabetic Tissue

Chinaroonchai K, Sangkhathat S, Chansanti O, Chititavorn V, Chotikasemsri P*

Department of Surgery, Faculty of Medicine, Songklanagarind Hospital

*Biomedical Engineering Institute, Faculty of Medicine, Songklanagarind Hospital

Diabetic wounds are one of the common wound that caused health problem due to their impaired healing ability. Slow diabetic fibroblast proliferation rate and impaired in its migration property are ones of many defects in healing pathway of diabetic wounds. Improvement of diabetic fibroblast proliferation and its migration ability may increase healing rate. This study focused on LED light effect on cell proliferation and migration properties of human diabetic fibroblast cell. MTT assay and wound healing assay (scratching assay) were used to demonstrate proliferation and migration abilities of fibroblast in both control and treatment groups. LED light can increase both normal and diabetic fibroblast proliferation at 24 hrs after light treatment. And LED light can promote cell migration in diabetic fibroblast at 12 hrs, 18 hrs and 36 hrs after light exposure. Proper wavelength and energy of LED light can enhance cell proliferation and migration abilities of diabetic fibroblast.

Prospective Randomized Controlled Trial Comparative Study between Effects of Bone Wax Versus Oxidized Regenerated Cellulose on Sternotomy Wound in Patient Undergoing Open Heart Surgery

Omchai Rattananont*, Chawannuch Reungsri*, Suppaneewan Chaowisit**, Panuwat Lertsittichai*, Suchart Chaiyaroj*

*Cardiovascular Thoracic Surgery Unit, Department of Surgery, **Department of Radiology, Faculty of Medicine, Ramathibodi Hospital, Mahidol University

Background: Bone wax is routinely used following median sternotomy for sternal hemostasis. Oxidized regenerated cellulose (ORC) is introduced as an alternative for sternal bleeding control. However there are few evidences verifying the application of two hemostatic agents and their beneficial and adverse effects on hemostasis, sternal healing, and infection in open heart surgery patient.

Objectives: To compare the effects of hemostasis, healing, and infection of sternum between using bone wax versus ORC in patient undergoing open heart surgery.

Methods: From November 2011 to May 2012, 64 consecutive open heart surgery patients were prospective randomized into two groups comparing 32 patients using bone wax (group I) and 32 patients using ORS (group II). Hemostasis indicators including sternal bleeding control time, blood loss, and blood product usage were recorded. Measurement of serum procollagen type I amino-terminal propeptide (PINP) level at different time spots, amount of bone callus formation, sternal pain score were used to determine bone healing effect. Events of sternal infection and mediastinitis were observed. Risk factors analysis for sternal hemostasis, healing and infection were performed by means of logistical regression analysis.

Results: No operative mortality occurred. Hemostasis parameters were not significantly different in group I versus group II, means \pm SD (bleeding control time was 3.1 ± 0.2 minutes versus 3.0 ± 0.18 minutes, $p = 0.78$; amount of blood loss at 12 hours was 381.3 ± 47.6 ml versus 349.4 ± 45.7 ml, $p = 0.63$; red blood cells 314.8 ± 40.3 ml versus 351.1 ± 49.8 ml, $p = 0.576$; platelet concentrates 110.5 ± 37.8 versus 101.3 ± 38.39 ml, $p = 0.87$), fresh frozen plasma 51.7 ± 24.43 ml versus 48.6 ± 24.25 ml, $p = 0.93$), and cryoprecipitate 25.8 ± 11.08 ml versus 8.4 ± 4.77 ml, $p = 0.16$). Serum PINP level at different time spots were higher in group I without significant different ($p > 0.05$). Sternal pain score tests were almost identical in both groups. Amount of callus formation from computed tomography of sternal bone was 10 ± 3.0 % in group I versus 6.11 ± 1.64 % in group II, $p = 0.31$. There was one deep sternal wound infection in group I and one superficial wound infection in group II.

Conclusions: ORC as well as bone wax can be used effectively and safely in sternotomy wound. Our study showed no significant difference in sternum hemostasis, bone healing, and infection between using both hemostasis agents.

The First Smartphone Application for Microsurgery Monitoring; Silpa Ramanitor

Ngamcherd Sitpahul*, Surawej Numhom*, Pinyo Taeprasartsit, Kidakorn Kiranantawat***

*Division of Plastic Surgery, Department of Surgery, Ramathibodi Hospital, Mahidol University.

**Department of Computing, Faculty of Science, Silpakorn University, Thailand.

Background: Postoperative monitoring of tissue perfusion is vital to successful microvascular surgery. Unfortunately, the current monitoring devices are expensive and require experienced health care professionals. Thus, many healthcare providers strongly prefer an alternative monitoring system, that is reliable, inexpensive and easy-to-operate. Nowadays, the advancement of smart phone has provided the excellent opportunity for the development of new applications that may benefit patients and healthcare providers globally.

Objective: To develop a new monitoring system based on image analysis running on a smart phone and evaluate its potential utility in tissue perfusion assessment.

Methods: 42 normal subjects were included in the study. The photos of their 2 fingers (index and middle fingers) were taken by a customized smart phone application with different degrees of pressure applied on an index finger (partial venous occlusion, partial arterial occlusion, complete venous occlusion, complete arterial occlusion). To detect the abnormal perfusion, the newly developed smart phone application, SilpaRamanitor, is employed to analyze the photos with the unoccluded middle finger served as an internal control. The application computes the color difference between the internal control region and a monitored region to check whether the monitored region is in a normal condition.

Results: The sensitivity, specificity, accuracy, false negative, and false positive of the newly developed method were 94.05%, 97.62%, 95.24%, 5.9%, and 1.19% respectively. In addition, the accuracy of the proposed method in grading occlusion severity was evaluated. For the 39 cases correctly identified as venous outflow obstruction, the method correctly graded the occlusion severity in 33 cases (84.62%). Likewise, for the 40 cases correctly identified as arterial outflow obstruction, the method correctly categorize the obstruction severity in 33 cases (82.50%).

Conclusions: We developed a new, accurate system using a smart phone application for postoperative microvascular surgery monitoring. Our new monitoring system is also inexpensive and easy-to-use, making it applicable in any microsurgical settings.

A Comparison of the Party Ballon Assisted Valsalva with Conventional Valsalva Maneuver in Diagnosis of Superficial Venous Valvular Reflux of Lower Limb

Sermasathanasawadi Nuttawut, Pattarakittikul Kamolrat

Division of Vascular Surgery, Department of Surgery, Faculty of Medicine, Siriraj Hospital, Mahidol University, Bangkok, Thailand

Background: The conventional valsava maneuver (CV) is a standard procedure to exhibit reverse venous flow for valvular reflux examination by duplex ultrasonography (DUS). However, some patients especially the elderly patients could not perform CV to demonstrate the reverse flow. It has been reported that blowing party balloon can produce the same effect as CV in various conditions. However, valsava by blowing party balloon has not been evaluated in venous reflux examination.

Objective: This study was designed to compare the results of DUS in diagnosis of superficial reflux of lower limb by PBAV and CV induced reverse venous flow for valvular incompetence examination.

Design of study: The study design was a prospective randomized controlled trial, cross over study.

Subjects and Methods: 40 patients who had symptoms and signs suspected saphenofemoral junction incompetence were examined for superficial reflux using DUS with two techniques of valsava maneuver, PBAV and CV. Five segments of the deep and superficial veins of each affected limb were examined by DUS with CV and PBAV. Patients were randomized to 2 groups. The first group performed CV before PBAV. The other performed PBAV before CV. The timing for the instruction, reflux time, total timing of examination were compared between 2 groups.

Results: There was neither period effect nor treatment-period interaction between the PBAV and CV to examine superficial reflux. Both PBAV and CV could equally identify superficial reflux but teaching time and total examination time in PBAV was shorter than CV.

Conclusions: PBAV was the new option to exhibit reverse flow for superficial reflux examination by DUS. PBAV was easier to perform than CV and took a shorter time for examination.

Keywords: Venous valvular reflux, Varicose vein, Valsalva, Standardized valsava maneuver, Reverse Trendelenburg-15 degree position, Duplex ultrasonography

Predicting an Occurrence of Cancer-associated Colorectal Polyp by a Metabolic Risk Score

Nuengrutai Orannapalai¹, Worapat Attawettayanon¹, Samornmas Kanngern^{2,3}, Teeranut Boonpipattanapong^{1,3}, Surasak Sangkhathat^{1,3}

¹Department of Surgery, Faculty of Medicine, Prince of Songkla University, Hat Yai, Songkhla, Thailand

²Anatomical Pathology Unit, Department of Pathology, Faculty of Medicine, Prince of Songkla University, Hat Yai, Songkhla, Thailand

³Tumor Biology Research Unit, Faculty of Medicine, Prince of Songkla University, Hat Yai, Songkhla, Thailand

Purpose: To develop a metabolic risk score that can identify patients who are likely to have cancer-associated polyp (CAP) on a colonoscopy, based on metabolic syndrome-related clinical profiles.

Methodology: The clinical histories and anthropometric and metabolic profiles of patients who came for a screening colonoscopy at our institute during the period from June 2010 to December 2012 were prospectively collected. Data were analyzed for their association with the occurrence of CAP. Subsequently, six parameters were selected to construct a metabolic risk score that was correlated with the presence of CAP.

Results: Two-hundred and eighty-six subjects (132 males and 154 females), ages ranging from 19 to 85 years, participated the study. The colonoscopy detected polyps in 56 cases (20%). Anthropometric parameters that were significantly associated with CAP included body mass index of more than 23.4 kg/m² and waist circumference more than 32 inches in females. Laboratory profiles that were significantly associated with CAP were fasting blood sugar > 110 mg%, Hb A1C > 7%, SGOT > 40 IU/L, SGPT > 50 IU/L and uric acid > 7 mg%. When metabolic risk score was constructed, moderate risk (score 2-3) and high risk (score 4-6) was significantly associated with CAP at Odds ratio of 4.9 (95% CI 2.0-12.0) and 13.7 (95%CI 4.4-43.0), respectively. Association between the risk score and CAP was stronger in subgroup of patients aged less than 65 years.

Conclusion: The study found that it is possible to use metabolic profiles to construct a reliable scoring method to identify patients at high risk for polyps, and thus indicating more urgent colonoscopies.

The Utility of Serum Base Deficit Monitoring in Trauma Resuscitation: Help or Hype?

Tawiwat Surojnametakul, Burapat Sangthong, Komet Thongkhao, Osaree Akaraborworn, Rassamee Sangthong

Songklanagarind Hospital, Prince of Songkla University, Songkhla, Thailand

Purpose: The use of serum base deficit monitoring in trauma resuscitation remains controversial. We conducted the study to determine the prognostic value of serum base deficit measurements after haemorrhagic shock resuscitation in trauma patients.

Methodology: All trauma ICU patients meeting shock resuscitation protocol during August 2009 to July 2012 were reviewed. The protocol was a goal-directed process to attain an oxygen delivery index (DO₂I) >500 mL/min/m² and/or to reduce blood lactate to <2.5 mmol/L within 24 hrs. Serum base deficits were measured at admission and every 8 hrs for 24 hrs. To evaluate the prognostic values of base deficits on admission (T0) and at 24 hrs (T24) after resuscitation, receiver operating characteristic (ROC) curves for mortality were constructed with corresponding area under the ROC values (AUC).

Results: There were 388 patients (35 + 15 years old, 80% male, 74% blunt, ISS 26 + 12) during 3-year study period. Reduction of base deficit was associated with an improved survival. Two hundred and sixty-nine of 302 patients (89%) whose base deficits normalized in 24 hrs survived. Only 44 of the 86 patients (51%) who did not normalize their base deficits by 24 hrs survived ($p < 0.001$). The serum base deficits on admission and at 24 hrs after resuscitation reliably predicted mortality (T0AUC = 0.739 and T24AUC = 0.745).

Conclusion: Normalization of serum base deficit within the first 24 hrs is associated with improved survival. Prognostic value of serum base deficit monitoring during this critical period is ascertained.

Clinical Features and Survival of Women Diagnosed with Breast Cancer Age 40 and Younger Compared with Those Over 40 in Songklanagarind Hospital

Kriangkrai Munkong¹, Pattama Tana-anantarak², Somrit Mahattanobol¹, Srila Samphao¹

¹Department of Surgery, Faculty of medicine, Prince of Songkla University, Songkhla, Hat Yai, Thailand

²Department of Radiology, Faculty of medicine, Prince of Songkla University, Hat Yai, Thailand

Objective: Recent increases in breast cancer affect women around the world especially in Asian countries. The Asian women emerge with the earlier age at diagnosis and higher mortality rate, compared with the older. The prognostic factors include delayed in tumor detection, short tumor doubling times, high lymphovascular invasion and poor hormonal/erbB2 receptor expression. We wish to compare patient features and tumor characteristics, predictive factors and survival in women diagnosed with breast cancer age 40 and younger with those over 40 in Songklanagarind hospital.

Methods: Records review identified 1,360 women diagnosed with breast cancer from 1/1998 to 12/2007. Women age ≤ 40 ($n = 298$) and over 40 ($n = 1,062$) were compared in means of tumor detection, operative procedures, tumor characteristics, adjuvant treatment and survival.

Results: Overall, most of the patients presented with palpable mass. Only half the patients underwent mammography at the time of diagnosis. Younger women had lower rates of BIRADS 4/5, compared with the older (85.4% vs. 92.6, $p = 0.02$). There was no difference in operative procedures between the two groups, in favors of mastectomy with axillary lymph node dissection. Younger women had higher rates of lymphovascular invasion (32.2% vs. 25.2%, $p < 0.001$) and negative estrogen receptor status (40.3% vs. 36.4%, $p = 0.002$). There were no differences in adjuvant chemotherapy (81.2% vs. 78.8%), types of chemotherapy, either anthracycline or nonanthracycline-based regimens, adjuvant hormonal therapy (68.8% vs. 62.1%) and radiotherapy (38.6% vs. 43.4%) between the two groups.

At a median follow-up of 85 months, there were no differences in 5-year disease-free survival (62.4% vs. 65.7%), distant disease-free survival (65.8% vs. 69.1%) and overall survival (69.1% vs. 74.1%) between the two groups. Pathological staging (stage 3; HR 3.85, 95% CI 2.59-5.73, $p < 0.001$) and nodal involvement (HR 1.60, 95% CI 1.23-2.08, $p < 0.001$) were predictive factors for disease recurrence and death.

Conclusions: Young women with breast cancer have poor tumor detection and more aggressive disease. With equivalent local and systemic therapy, however, survival is comparable with the older. Pathological staging and nodal status are predictive factors for survival outcomes.

CVT
Free Papers

Prognostic Factors of Tumor Recurrence in Completely Resected Non-small Cell Lung Cancer

Apichat Tantraworasin¹, Somcharean Seateang¹, Nirush Lertprasertsuke², Nuttapon Arreyakajohn³, Choosak Kasemsarn⁴, Jayanton Patumanond⁵

¹General Thoracic Unit, Department of Surgery, Faculty of Medicine, Chiang Mai University Hospital, Chiang Mai, Thailand

²Department of Pathology, Faculty of Medicine, Chiang Mai University Hospital, Chiang Mai, Thailand

³Cardiovascular Thoracic Unit, Department of Surgery, Lampang Hospital, Lampang, Thailand

⁴Cardiovascular Thoracic Unit, Department of Surgery, Chest Institute, Nonthaburi, Thailand

⁵Department of Community Medicine, Faculty of Medicine, Chiang Mai University Hospital, Chiang Mai, Thailand

270

ABSTRACT

Background: Patients with completely resected non-small cell lung cancer (NSCLC) have an excellent outcome; however, tumor recurs in 30%-77% of patients. This study retrospectively analyzed the clinicopathologic features of patients with any operable stage of NSCLC to identify the prognostic factors that influence tumor recurrence, including intratumoral blood vessel invasion (IVI), tumor size, tumor necrosis, and nodal involvement.

Methods: From January 2002 to December 2011, 227 consecutive patients were enrolled in this study. They were divided into two groups: the “no recurrence” group and the “recurrence” group. Recurrence-free survival was analyzed by multivariable Cox regression analysis, stratified by tumor staging, chemotherapy, and lymphatic invasion.

Results: IVI, tumor necrosis, tumor diameter more than 5 cm, and nodal involvement were identified as independent prognostic factors of tumor recurrence. The hazard ratio (HR) of patients with IVI was 2.1 times higher than that of patients without IVI (95% confident interval [CI]: 1.4-3.2) ($P = 0.001$). The HR of patients with tumor necrosis was 2.1 times higher than that of patients without tumor necrosis (95% CI: 1.3-3.4) ($P = 0.001$). Patients who had a maximum tumor diameter greater than 5 cm had significantly higher risk of recurrence than patients who had a maximum tumor diameter of less than 5 cm (HR 1.9, 95% CI: 1.0-3.5) ($P = 0.033$).

Conclusion: IVI, tumor diameter more than 5 cm, and tumor necrosis are prognostic factors of tumor recurrence in completely resected NSCLC. Therefore, NSCLC patients, with or without nodal involvement, who have one or more prognostic factors of tumor recurrence may benefit from adjuvant chemotherapy for prevention of tumor recurrence.

Cardiac Surgery in HIV-infected Patients

Sirichai Woradit, Sompop Prathanee, Chusak Kuptarnond

Division of Cardiovascular and Thoracic Surgery, Department of Surgery, Faculty of Medicine, Khon-Kaen University, Khon-Kaen, 40002, Thailand.

Background: Highly active antiretroviral therapy (HAART) improved the survival rate of HIV-infected patients. They will be referred for cardiac surgery. We report HIV-infected patients who underwent open heart surgery with cardiopulmonary bypass.

Objectives: To evaluate clinical data, indications for surgery, postoperative complication, and result of treatment in HIV-infected patients compared with data from the review literatures, and to find out proper management.

Methods: Review medical records from patients who had HIV-infection between 1993 and 2012 in our institute.

Results: Two patients underwent open heart operation. Both of them were diagnosed with rheumatic heart disease and failure to medical treatment. One of them received HAART due to developed symptomatic HIV infection before surgery and restarted HAART immediately post-operation. Both of them were clinical improve.

Conclusions: The number of HIV-infected patients referred for cardiac surgery will be rising because improved survival rate and cardiovascular risk is reduced with the use of HAART. Multidisciplinary care is necessary to improve surgical outcome of HIV-infected patients.

EVAR in Complex Aortic Aneurysm

Worawong Slisatkorn

Division of Cardiothoracic Surgery, Department of Surgery, Siriraj Hospital

“A 64-year-old man with a history of peripheral arterial disease. His chest film was abnormal. CTA revealed saccular thoracic aortic aneurysm and two saccular juxtarenal and infra renal abdominal aortic aneurysms. He was informed about treatment options. Endovascular surgery was planned after discussion. The operation was thoracic endovascular aortic repair (TEVAR), left carotid to left subclavian artery bypass and fenestrated endovascular aortic repair at the same session. The procedure was successfully performed in hybrid operating theater. The patient was discharged home uneventfully. Postoperative CTA showed good patency of stent graft and all branches, without endoleakage.”

Plastic Surgery

Free Papers

A Stainless Steel-Grating Top Table as a Moveable Sterilized Burned Wound Dressing and Operating Table

Kriangsak Sirirak

Surgery Department, Prapokklao Hospital, Chantaburi, Thailand

A stainless steel-grating top table can be used as a moveable sterilized table for burned wound dressing or an operating table. Stainless steel-grating top can be sterilized by autoclaving as others surgical instruments and after sterilization, burned patients can lie on this sterilized area for burned wound cleansing or surgical manipulation. This sterilized area was easily controlled wound infection, few pain and comfortable for patients. The table can move from room to room like a trolley by wheel and its brake at each leg???. At Surgery Department of Prapokklao hospital, we used the stainless steel-grating top table as a sterilized table for burned wound cleansing with sterile solutions, warm saline and 4% chlorhexidine scrub, and when surgical intervention was indicated, we turned the table to sterilized operating table. This study covering a total of 88 patients, 213 times for wound cleansing (bathing,dressing) and 141 times as an operating table (excision, skin coverage operations) had shown to be easily used, comfortable for patients, less infection rate with good healing process, during October, 2009 to August, 2012. Standard burned wound care with early excision of burned tissues, infection controlling with nanocrystalline silver dressing, strict infection control practices and regular microbial burn wound culture were appropriated done until healing success.

Key words: burned wound dressing table, bathing therapy, burned wound care.

The Revolution of Photography Based Method for Wound Area Measurement

Somrit Sittipongpittaya*, Pinyo Taeprasartsit, Surawej Numhom***

*Division of Plastic and Maxillofacial Surgery, Department of Surgery, Ramathibodi Hospital, Mahidol University

**Department of Computing, Faculty of Science, Silpakorn University

Background: The measurement of wound dimension is an important component of successful wound management. Monitoring changes in wound area allows assessment of treatment efficacy and early detection of stasis or deterioration. Wound surface area calculations have been shown to be a valid and accurate indicator of wound progress. There are a wide variety of devices and methods available to measure wounds. But there was not any method in the present day that has shown ideally characteristic for wound area measurement. The aim of this study was to produce a simple method that is cheap, fast, easy, widely available and accurate, when measuring wound area in cases where a non-wound-contact method is desirable.

Methods: After image program for wound measurement software production was done. A total of 30 wounds were used for evaluate the reliability of our new method for wound area measurement. The evaluation was done in (1) intragroup(compared wound area from our new method between 3 users) and (2) intergroup(compared between our new method with Visitrak).

Results: Image program for wound measurement method was accurate that shown by intragroup result that there was no statistical difference ($P\text{-value} = 0.960$) between every users when measuring wound area by using the image program for wound measurement in every wound sizes. The comparison of wound area from the image program for wound measurement and from Visitrak (intergroup) was shown the statistical difference between the two methods when measuring wound area in 2 from 3 investigators (But the other one was shown no statistical difference between the two methods).

Conclusions: The image program for wound measurement method is a more appropriate technique for clean and uncontaminated wounds as contact with the wound bed is avoided, negating the risk of wound contamination, wound bed damage, and patient's discomfort. This method for wound measurement is accurate, cheap, fast, easy and widely available.

Pediatric Surgery
Free Papers

The Comparision of Pneumatic Reduction under Ultrasound Guidance and Hydrostatic Reduction under Fluoroscopy for Childhood Intussusceptions

Junsujee Wakhanrittee, Mongkol Laohapensang

Division of Pediatric Surgery, Department of Surgery, Siriraj Hospital, Mahidol University

Objective: To compare the efficacy and successful rate between two methods; pneumatic reduction under ultrasound guidance and barium reduction under fluoroscopy for treatment of childhood intussusception in Siriraj Hospital.

Methods: Retrospective study from January 1, 2003 to December 31, 2012. Eighty-two patients with intussusceptions were enrolled in our study. The patients were divided into two groups by the technique of reduction; the first is pneumatic reduction under ultrasound guidance and the other is barium reduction under fluoroscopy. The demographic data, presenting symptoms and signs, investigations, method of reduction, results of reduction, complications, operation after failure of reduction was reviewed from the electronic medical records. All data were analyzed and compared between two groups. Primary outcome of our study was the success rate in each reduction procedure.

Results: The pneumatic reduction under ultrasound guidance was success in 12 of 19 cases with success rate about 63.16%. The barium reduction under fluoroscopy was success in 25 of 63 cases with success rate about 39.68 %. In multivariate analysis, the pneumatic reduction under ultrasound guided was statistically significant higher success rate compared with the barium reduction under fluoroscopy (p value = 0.049). There was no complication after reduction with both methods. The recurrence after successful reduction was found in 4 cases.

Conclusion: Pneumatic reduction under ultrasound guidance seem to be a feasible and effective technique for childhood intussusception, with higher success rate. The pediatric surgeons can perform by themselves in both diagnosis and treatment at the same time, so it is the interesting choice for the surgeons in the treatment of intussusceptions.

The Study of Constipation Inanorectal Malformations after Posterior Sagittal Anorectoplasty (PSARP)

Niramon Sukarnjanaprai, Monwat Ngerenchum, Mongkol Laohapensang

Division of Pediatric Surgery, Department of Surgery, Siriraj Hospital, Mahidol University, Bangkok, Thailand

Background/Purpose: Postoperative anorectoplasty, constipation is a major functional problem after anorectal reconstruction related with poor quality of life. We aim to study about constipation and find the predictive factors of constipation in the ARMs patients after treatment with PSARP. The results may be knowledge for future management and long term follow up.

Methods: Retrospective review of 70 ARMs received PSARP from Siriraj hospital, Mahidol University between 1996 and 2010. Reviewed the medical data and sacral ratio measured from photo of pelvic plain film. All patients older than 3 years, they were interviewed about the current function of bowel movement. Constipation and soling were classified with the International classification (Krackenbeck) for postoperative results.

Results: Mean age of the patients at the interview was 8.7 years (range 3.09 - 20.99). Diagnostic ARMs type classification was 26 (37.1%) rectourethral fistula, 23 (32.9%) no fistula, 11 (15.7%) rectovesical fistula, 3 (4.3%) rectovaginal fistula, 2 (2.9%) vestibular fistula, and 2 (2.9%) perineal fistula. 37 (52.9%) patients had constipation; 15 (21.4%) constipation grade 1 and 21 (30.0%) constipation grade 2. The study relationship of postoperative results, that was found significant when the patients weren't have feeling of urge, they might have constipation. Analyzing the relationship between each variable by binary logistic regression, that found only the patients with associated anomalies had constipation more than the patients without associated anomalies (IRR = 1.34, P = 0.007, 95% CI 1.084 - 1.654).

Discussion: All patients with constipation were improved by diet and/ or laxative drug administration (constipation grade 1 and 2). No significant postoperative constipation between low type ARMs and non low type ARMs. The analysis of all probable variables found the significant relationship between the ARMs with associated anomalies and constipation. We suggest about the patients with severe associated as cardiac anomalies might be delay of PSARP. However, this variable included all organ associated anomalies. It might be a bias.

Conclusion: After PSARP, constipation is the common complication. Therefore, pre-operative information for the parents is important to awareness and agreement for postoperative follow up and treatment.

032

Bilateral Parovarian Cysts with Torsion in Children: A Case Report and Literature Review

Tipaporn Tubthong, Mongkol Laohapensang

Division of Pediatric Surgery, Department of Surgery, Faculty of Medicine, Siriraj Hospital,
Mahidol University

Background: Parovarian cysts are located in the broad ligament between the ovary and the fallopian tube. They are usually found incidentally but sometimes they presented with complicated feature, such as torsion. Clinically, torsion of a parovarian cyst is uncommon, and difficult to differential it from other cause of acute abdominal pain.

Materials and Methods: In this paper, we present a case of bilateral parovarian cysts which torsion on one side and causing acute abdominal pain mimicking acute appendicitis presentation.

Conclusions: A certain preoperative diagnosis of torsion parovarian cyst is very difficult, especially in the case presenting with acute abdominal pain because of uncommon. A careful history taking, physical exam, investigation and re-evaluated abdominal sign may help appropriate decision making before surgery.

The Accuracy of the Broselow Tape in Weight Estimation of Thai Children

Rattaporn Donnapee¹, Piyawan Chiengkraiwater², Sakda Patrapinyokul², Surasak Sangkathat²

¹General Surgery Unit, ²Pediatric Surgery Unit, Department of Surgery,

Faculty of Medicine, Prince of Songkhla University, Hatyai, Songkhla, 90110, Thailand

Objective: To determine the accuracy of the Broselow tape in weight estimation of Thai children.

Methods: This was a retrospective, observational, hospital-based study of 4,746 children under 14 years old over a 4-month period from January, 1, 2010, to April, 30, 2010 who visited the pediatric out-patient department of Prince of Songkhla University Hospital and were diagnosed as groups D, F, H, J, L and Z from the ICD-10. The collected data included birthdate, gender, OPD visit date, age on OPD visit, measured weight and measured height. The data were analyzed to determine the accuracy of the Broselow tape by calculating mean differences, and percentage differences and agreements in nine color-coded zones.

Results: The mean difference and mean percentage difference were -0.87 and -3.56% overall, respectively. The percentage agreement was 62.11% overall, and varied from 36.36% to 90.48% in the nine color-coded zones.

Conclusion: The Broselow tape slightly underestimates the weight of Thai children overall, and accuracy decreases as the child's weight increases, and is most accurate in children under 5 kg in weight. In overweight children, the Broselow tape should be used with caution.

Keywords: Accuracy, body weight, Broselow tape, estimation

Outcomes of Operative Management of Infantile Hypertrophic Pyloric Stenosis: A Single Center Experience - Songklanagarind Hospital

O. Sa-nguantrakul, P. Chiengkriwate,

Pediatric Surgery Unit, Department of Surgery, Faculty of Medicine,
Prince of Songkla University Thailand

Background: Infantile hypertrophic pyloric stenosis (IHPS) is characterized by thickening of the pyloric sphincter muscular layer which predominated in male infant 3-6 weeks old. Definite treatment is the Fredet-Ramstedt pyloromyotomy with usually excellent outcomes and rare complications. In our tertiary hospital where is the pediatric surgery center, the data of post operative outcomes had not been collected nor evaluated yet.

Objectives: To collect and evaluate postoperative outcomes after Fredet-Ramstedt pyloromyotomy in Songklanagarind hospital.

Methods: From Songklanagarind hospital patient registry, IHPS patients was identified and included in this study between Dec 1983 and Dec 2011. Data collection included general data, body weight, operations, length of hospital stay, times to starting oral feeding until reaches full feeding, post operative complications and follow up weights. Data was collected by Microsoft excel 2007 and we use program R for data analysis.

Results: Total 37 patients (30 males, 7 females) were included in this study. Mean age was 49 ± 19 days and mean body weight at diagnosis was $3,411 \pm 823.1$ gm. Majority of cases are term infants (95%, N=23) and only 1 case had family history of newborn gut obstruction. An average postoperative time to start feeding was 1.27 ± 0.72 days while to reach full feeding was 4.49 ± 5.19 days. Two patients had delayed full feeding time (14 days and 30 days) according to postoperative complication and patient comorbidity which were postoperative pneumonia in a girl who had congenital lung anomaly and a boy with hypoxic-ischemic encephalopathy with swallowing problem. No postoperative wound complications were recorded. Mean length of stay was 8.76 ± 10.37 days. Major complications were residual IHPS which needed reoperation and followed by third operation for lysis adhesion and 1 died from postoperative hypoxic cardiac arrest. Overall follow up weights were normal.

Conclusions: In our center; the outcomes after treatment of IHPS were acceptable though serious complications do exist. The reoperation of residual IHPS case was understandable. However, we failed to explain certain cause of the dead case by tracking our medical record at that time.

Keywords: infantile hypertrophic pyloric stenosis, pyloromyotomy, outcomes.

Complicated Abdominal Wounds Treated by Vacuum Assisted Closure Dressing in Pediatric Patients

Korbkarn Samuthananon, Tawan Imvised, Nathathai Kanoknark, Paisarn Vejchapipat

Pediatric Surgery Unit, Department of Surgery, Faculty of Medicine, Chulalongkorn University, Bangkok, Thailand

Background: An advantage of Vacuum Assisted Closure (VAC) dressing is its comfort for patients and medical staff. We report the use of VAC in patients with complicated abdominal wounds.

Materials and methods: All pediatric patients with complicated abdominal wounds treated by VAC between 2007 and 2012 were reviewed.

Results: 15 pediatric patients (0-14 years) were managed by VAC dressings for abdominal wounds as followed; 5 enterocutaneous (EC) fistulas, 2 infected wound dehiscence and 8 open abdomens after damage control surgery. All complicated wounds occurred after laparotomies. EC fistula was spontaneously closed in one patient whereas fistula wounds of the others were controlled and required surgery later. All patients, except one, survived (93% survival).

Groups	No. of pts.	VAC changes Median (range)	Hosp stay (days) Median (range)	Outcome
EC fistula	5	22 (2-29)	87 (52-207)	All alive
Dehiscence	2	2 (1-3)	82.5 (79-86)	All alive
Open abdomen	8	6 (2-16)	41 (18-149)	7 alive

Conclusion: VAC dressing is a simple and effective method. VAC dressing for complicated abdominal wounds can be used as an alternative to conventional open dressing method.

Early Outcome of Gastroschisis: An Experience of 53 Cases

Mahawong K, Decharun K, Rajatapiti P, Ruekwibunsri S, Vejchapipat P*, Viravaidya D.

Pediatric Surgery Unit, Department of Surgery, Faculty of Medicine, Chulalongkorn University, Bangkok, Thailand

Objective: The aim of this study was to review early outcome of gastroschisis treated at our hospital.

Materials and Methods: Newborns with gastroschisis treated by surgery between 2003 and 2012 was retrospectively reviewed. Demographic data, time of full enteric feeding, ventilator period, length of hospital days, complications and mortality were collected. Two methods of surgical treatment were used, primary fascial closure and staged closure. Whenever possible, primary fascial closure would be performed; otherwise, artificial sac coverage followed by staged closure was carried out. Data were analyzed using SPSS. Descriptive statistics, independent-sample T tests, or Pearson Chi-square tests were used where appropriate. Data were expressed as mean+SD.

Results: Fifty-three newborns with gastroschisis were identified. Prenatal diagnosis was achieved in 62% (33/53). Mean gestational age was 35.9+2.0 weeks with birth weight of 2,385+589 grams. C-section rate was 64% (34/53). Overall mortality within 90 days was 3.8% (2/53). Primary fascial closure was successful in 72% (38/53). There was no difference in birth weight between newborns treated by primary closure and those treated by staged closure. However, primary closure was significantly associated with less TPN duration (13+9 vs. 23+13 days, $P<0.01$) fewer GI-associated complications (50% vs. 80%, $P=0.04$), and shorter time of full enteric feeding (20+8 vs. 33+17 days, $P=0.01$).

Conclusions: Although gastroschisis is not an indication for C-section, the rate of C-section is high in our series. Overall survival for gastroschisis is 96.2%. Gastroschisis treatment policy by the attempt of primary fascial closure first, if not successful, followed by staged closure makes a good result.

Prognostic Indicators for Failure Nonoperative Reduction of the Intussusception

Jiraporn Khorana, Jakkraphan Siri Wongmongkol, Junsujee

Wakhanrittee* , Jesda Singhavejsakul, Mongkol Laohapensang*

Division of Pediatric surgery, Department of Surgery, Chiang Mai University Hospital

Division of Pediatric surgery , Department of Surgery, Siriraj Hospital, Mahidol University*

Background: Intussusception is the frequent cause of bowel obstruction in infant and preschool age. The incidence of intussusception is about 1:2000 infants and children. The treatments compose of nonsurgical and surgical treatments. If no contraindication, nonsurgical reduction can be attempt. There are 2 methods of reduction. Those are hydrostatic reduction and pneumatic reduction. Many factors influence in the term of failure reductions.

Objectives: To predict for the determinants of nonoperative reduction failure. Nonoperative failure defined as the intussusception that cannot be reduced nonoperatively. The parameters from patient factors, symptoms, signs, and investigations are used.

Materials & Methods: Intussusception patients who were treated with nonoperative reduction in Chiang Mai University Hospital (CMU) and Siriraj Hospital(SI)'s data was recruited between January 2006- December 2011 for CMU and January 2003 - December 3 2012 for SI. The inclusion criteria consisted of the intussusception patients who age 0-15 years old with no contraindication for nonoperative reduction. After the statistical regression was done by generalized linear model the significant prognostic indicators were obtained.

Results: 159 patients were included in the study. 87 patients from SI and 72 patients from CMU. The overall failure rate was 50.31%. The significant risk factors of failure reduction cluster by institution are female (RR=1.11, $p<0.001$), age more than 2 years (RR=2.60, $p<0.001$), present of rectal bleeding (RR=1.14, $p<0.001$), dehydration (RR=1.34, $p<0.001$), temperature more than 37.8 °C (RR=1.69, $p<0.001$), palpable mass (RR=1.44, $p=0.003$) and present of ultrasound poor prognostic sign (RR=1.39, $p=0.033$). The failure rate will increase if the method of reduction is hydrostatic (RR=1.43, $p<0.001$). The prediction affinity of this model is 82.14% from the area under ROC.

Conclusions: Many factors were proved that can significantly predict the failure of nonoperative reduction. Nevertheless the contraindication of the nonoperative reduction still are peritonitis, free air in abdominal x-ray and nonresponsive shock. This study is just to identified the risk factors of failure reduction and in next study we will perform the scoring system for the prediction.

Precipitation of Lipid Emulsion within an Implantable Central Venous Device in Pediatric Patients Receiving Parenteral Nutrition

Surasak Sangkhathat, Montira Tantanuch, PodchanapornGraidist, PiyawanChiangkriwate, SakdaPatrapinyokul

Department of Surgery, Faculty of Medicine, Prince of Songkla University, Hat Yai, Songkhla, Thailand 90110

Department of Biomedical Science, Faculty of Medicine, Prince of Songkla University, Hat Yai, Songkhla, Thailand 90110

Introduction: Totally implantable vascular access device (TIVAD) has been widely used in pediatric patients receiving long-term parenteral nutrition (PN). A number of TIVAD is removed because of obstruction. In this study, we aimed to analyze for a cause of obstruction in the TIVAD system used in pediatric PN.

Methods: Precipitating substance found in a port chamber at its removal from 6 patients whose port chamber was used for long-term parenteral nutrition was analyzed by infrared spectrometry, scanning electron microscopy (SEM), energy dispersive X-Ray fluorescence spectrometer (EDX) and gas chromatograph-mass spectrometer (GC-MS).

Results: Infrared spectrometry of precipitation from 6 patients showed identical pattern of transmittance. SEM revealed homogenous substance mixed with destroyed red blood cells. EDX identified carbon and oxygen as main elements of this substance. GC-MS pattern was compatible with lipid emulsion used in PN.

Conclusion: Lipid emulsion used in PN can precipitate with blood within a chamber of a TIVAD system and may cause catheter occlusion. Care should be taken to clear this substance from the chamber before its precipitation.

Clinical Presentations of Meckel's Diverticulum in Infancy and Childhood

Pattarin Lertnuwat, Rangsan Niramis,

Varaporn Mahatharadol, Maitree Anuntkosol

Department of Surgery, Queen Sirikit National Institute of Child Health,
Bangkok, Thailand

Background: Meckel's diverticulum is the remnant of omphalomesenteric or Vitelline duct and is the most common congenital abnormality of the gastrointestinal tract. It may present symptomatology at any age.

Objective: To study clinical presentation of Meckel's diverticulum and outcomes of the treatment during a 10-year period.

Materials and Methods: A retrospective study of patients with symptomatic Meckel's diverticulum and other vestiges of omphalomesenteric duct treated at our institute between 2003 and 2012 was conducted. Clinical presentations and outcomes of the treatment were evaluated.

Results: Fifty-five patients, 36 males and 19 females, were enrolled in the study. Clinical presentations of these patients were categorized into 5 groups as the followings: Group 1 persistent omphalomesenteric duct with or without small omphalocele in 16 cases (29%), Group 2 weeping umbilicus in 5 cases (9%), Group 3 intestinal obstruction due to intussusception and complications of congenital mesodiverticular band in 13 cases (23.6%), Group 4 gastrointestinal bleeding in 12 cases (21.8%) and Group 5 inflammation due to Meckel's diverticulitis in 9 cases (16.4%). Mean ages of onset presented at 1 day in the first group and 3.2 ± 2.5 weeks, 38.6 ± 32 , 43.3 ± 30.9 and 14.9 ± 18.1 months in the second to the fifth groups. All of the 55 patients underwent surgical segmental ileal resection or wedged excision of Meckel's diverticulum. The postoperative complications were surgical wound infection (12.7%), septicemia (9.0%) and anastomotic leak (3.6%). Five patients (9%) died postoperatively because of trisomy 13 and 18 with multiple severe associated anomalies (4) and septicemia (1).

Conclusion: Principal presentations of Meckel's diverticulum were persistent omphalomesenteric duct occurring at birth, and intestinal obstruction and gastrointestinal bleeding developing in infancy and childhood period. Mortality in these patients mostly depended on multiple severe associated anomalies.

Monday, July 22, 2013



Poster Presentation for Competition

Laparoscopic Repair of Incisional Hernia Located on Abdominal Border: A Novel Technique Transabdominal Preperitoneal Approach

**Ajjana Techagumpuch, Pakkavuth Chanswangphuvana,
Soravith Vijitpornkul, Chadin Tharavej, Suppa-ut Pungpapong,
Patpong Navicharern, Suthep Udomsawaengsup**

Department of Surgery, King Chulalongkorn Memorial University Hospital

Background: Border hernia is an incisional hernia located near the borders of abdominal wall usually close to bones such as iliac crest, pubic symphysis and costal margin. An unusual location of this hernia makes it is technically difficult to repair and has increased risk of injury to retroperitoneal organs especially bladder and colon if using standard laparoscopic intraperitoneal onlay technique.

Objective: To demonstrate the feasibility of the transabdominal preperitoneal technique for unusual location incisional hernia

Method: The procedure was performed in a 52-year-old female patient who suffered from incisional hernia located at right lower part of abdomen which is the inferior border of the defect, is iliac crest. After insertion of trocars intraperitoneally, pneumoperitoneum was created and the peritoneum was dissected approximately 5 cm away from borders of defect to create the peritoneal flap. Retropubic space was meticulously dissected to provide adequate space for mesh placement without injury to bladder and other retroperitoneal organs. Thereafter mesh was placed preperitoneally and the peritoneum was placed to cover over it. Using this technique, we can safely use a non-absorbable mesh and subsequently reduce the cost of the procedure.

Results: The operation was performed successfully without complication. Operative time was 65 minutes and hospital stays was 4 days. No recurrence was found after 3-month follow-up.

Conclusion: The transabdominal preperitoneal incisional hernia repair is feasible for incisional hernia located on abdominal border that is difficult for standard IPOM technique.

A Prospective, Multicenter Study on Efficacy of Long-acting Testosterone Undecanoate, if Desired in Combination with Vardenafil, in Late Onset Hypogonadal Patients with Erectile Dysfunction

Sompol Permpongkosol**, *Krisada Ratana-olarn**, *Anupan Tantiwong, *Kavirach Tantiwongse****, *Apichat Kongkanand******

*Department of Surgery, Faculty of Medicine, Ramathibodi hospital, Mahidol University

**Department of Surgery, Faculty of Medicine, Siriraj Hospital, Mahidol University.

***Department of Surgery, Chulalongkorn University, King Chulalongkorn Memorial Hospital

Background: There is substantial evidence suggesting the additive effect on erectile function (ED) of testosterone and phosphodiesterase (PDE)-5 inhibitors. But the combination of long-acting testosterone undecanoate (TU), in combination with the PDE5-I vardenafil in men with late-onset hypogonadal patients (LOH) with (ED) has not yet been studied.

Objectives: To evaluate the effects of TU i.m., and if desired, the PDE5-I vardenafil in LOH patients with ED measured with the International Index of Erectile Function (IIEF-5).

Materials and Methods: A prospective study was performed following four administrations of TU in week 0, 6, 18, 30. If no improvement of ED assessed with IIEF-5 or the Global Assessment Questionnaire (GAQ) in week 12, the PDE5 inhibitor vardenafil was added. The final evaluation was in week 46. Aging Male Symptom (AMS) score, IIEF-5 score, and International Prostate Symptoms Score (IPSS) at each visit were summarized as mean with standard deviation; while GAQ was summarized using frequency and percentage. Scores at each visit were also categorized into different levels of symptom severity.

Results: AMS score decreased significantly at week 12, 30 and 46. IIEF-5 score increased but a significant change was found only at week 30 and 46. The GAQ assessment indicated erection and sexual intercourse already improved at the first assessment continuing thereafter. IPSS score decreased from baseline at week 46. Levels of total, free and bioavailable testosterone had increased significantly from baseline at all visits. Hematocrit, hemoglobin and prostate specific antigen increased significantly from baseline. Adverse events were rare with pain at injection site found in one patient. The two events were non-serious in type, mild in their intensity and recovered.

Conclusions: Therapy with TU , and if desired, combined with the PDE5 inhibitor vardenafil improved sexual activity in LOH patients with ED.

Key words: testosterone, hypogonadism, erectile dysfunction, phosphodiesterase (PDE)-5 inhibitors

Urologic Laparoscope Surgeries in Elderly: Analysis of Pre-operative Risk Factors and Postoperative Complications

Sompol Permpongkosol

Division of Urology, Department of Surgery, Faculty of Medicine, Ramathibodi Hospital, Mahidol University, Bangkok, Thailand

Introduction: The aging of the population leads to increases in the prevalence of symptomatic urologic diseases.

Objectives: The aim of this study is to analyze pre-operative risk factors and postoperative complications in patients over the age of 60 years undergoing elective laparoscopic urologic surgery.

Patients and Methods: A retrospective study was conducted of 113 patients 60 years of age or older who underwent urologic laparoscopic surgery by a single surgeon. The pre-operative physical status and systemic complications, operation time, postoperative complications, postoperative hospital stay and other clinical features of the patients were reviewed. Complications were classified according to the recently revised Clavien classification system. Statistical analysis was done using the Fisher Exact test and Relative risk.

Results: Laparoscopic urologic surgery was performed on 113 patients who were 60 years old and over, with an average age of 69.6 years. Associated diseases were found in 92% of them. Pelvic surgery (65, 57.5%) was the main reason for surgery. There were 5 (4.4%) conversions to open surgery and 0% mortality. The overall complication rate was 10 patients (8.8%). Among 9 (7.96%) patients with post-operative complications; Grade I, II, IIIa, IIIb and V complications were observed in 1.77%, 12.8%, 3.53%, 0.88% and 0.88% of cases, respectively. Complications correlated with male, operative time ≥ 250 and cancer with high-risk ratio (2.76, 2.11 and 3.02, respectively); however, the correlations of all of preoperative risk factors and postoperative complications showed no statistically significant differences.

Conclusions: Laparoscopic surgical treatment of urologic disease in elderly patients performed is feasible and well tolerated, with low perioperative morbidity and a good overall survival rate.

Key word: Urologic, laparoscopic surgery, elderly, complications, risk factors, Clavien

Selective Glissonian Pedicle Control: A Useful Technique in Laparoscopic Liver Resection

Rawisak Chanwat

Chairat Bunchaliew

Thiravud Khuaprema

Surgical Oncology Unit, National Cancer Institute, Bangkok, Thailand

Background: Laparoscopic liver resections are becoming a common procedure and bleeding remains the major concern during parenchymal transection. Pringle's maneuver can be performed but ischemic reperfusion injury can lead to postoperative morbidity. Selective hemihepatic inflow control can reduce the severity of visceral congestion and total liver ischemia.

Objective: The purpose of this report was to describe our experience with laparoscopic selective Glissonian pedicle control for minor hepatic resection.

Methods: Ten patients submitted to laparoscopic liver resection in our institute due to malignant lesion.

Results: The technique was successfully performed without complication. Mean diameter of tumor was 4.3 cm (range, 2.5-8.0 cm). Mean operative time consumed to achieve complete control of right or left pedicle was 26.5 min (range, 18-46 min). Mean intraoperative blood loss was 150 ml (range, 50-300 ml) and no blood transfusion was needed. The postoperative course of the patients was uneventful and they were discharged an average of 4.8 days (range, 3-7 days) after the operation.

Conclusion: Safe laparoscopic liver surgery requires knowledge of the regular techniques of vascular occlusion for on-demand use when necessitated to reduce blood loss.

Total Pancreatectomy in Extensive Cystic Neoplasm of Pancreas : A Case Report

Panchan V, Bunchaliew C, Chanwat R, Mounthard H, Khuhaprema T

Department of surgery, National Cancer Institute, Thailand.

Introduction: Pancreatic cystic lesions are increasingly identified on routine imaging. These lesions have the probability of malignant potential requiring surgical resection. Total pancreatectomy was performed in a patient with extensive lesion and highly suspicious of pancreatic malignant neoplasm.

Method: A case of 54-year-old female underwent modified radical mastectomy for breast cancer. After ultrasonography work up for liver metastasis, the imaging showed a cystic lesion at pancreatic head. During 2-year follow up with CT scan followed by MRI, there were increased in size and number of cystic lesions throughout pancreas. According to imaging lesion, surgical resection was planned for lesion removal because of unable to distinguish malignant neoplasm.

Result: Total pancreatectomy was performed due to multiple cystic lesion along pancreas. Postoperative serum glucose was monitored and controllable with minimal dose insulin. Pathological diagnosis was serous cystadenoma of pancreatic head, body and tail.

Conclusion: It is difficult to make a definite preoperative diagnosis of pancreatic cystic neoplasm. Observation or surgical resection depends on clinical and radiological finding. Total pancreatectomy may be mandatory if cystic lesions were entirely distribute along a pancreas.

An Aggressive Behavior of Primary Hepatic Leiomyosarcoma: A Case Report

Worawat Kaewwichian¹, Siri Chau-in¹, Ake Pugkhem¹

Aumkhae Sookprasert², Chawalit Pairojku³, Nittaya Chamadol⁴

¹Department of Surgery, ²Department of Medicine, ³Department of Pathology, ⁴Department of Radiology, Faculty of Medicine, Khon Kaen University, Khon Kaen, Thailand

Background: The primary malignant mesenchymal tumor of the liver is very rare. There are few reports about this tumor. The nature of the disease and the treatment strategy are not clearly defined.

Objective: We aim to report a primary hepatic leiomyosarcoma case, its aggressive behavior and the surgical outcome.

Case report: A 64-year-old man was admitted in February 2013. During hepatitis B viral cirrhotic liver surveillance, he presented with abdominal tightness for 1 month. On physical exam, an ill-defined mass at epigastric region was detected. Computed-tomography (CT) scan of chest and whole-abdomen revealed a hypodense hepatic lesion with faint peripheral enhancement and centripetal filled-in, measured about 6.6 cm x 8.0 cm x 9.0 cm of Couinaud's segment II and III. There was no evidence of any synchronous tumor. On operative finding, a firm pedunculated mass of segment II, III, and IV was noticed. Wedge resection was performed. The specimen was a well-defined, inhomogeneous white cut surface with central necrosis. Histopathological report confirmed a spindle cell tumor. Immunohistochemistry study was positive for actin, desmin, and caldesmon but negative for CD117, CD34, and S-100. Primary hepatic leiomyosarcoma was diagnosed. Two months after the operation, he developed an obstructive jaundice. CT scan showed recurrent tumor at the surgical bed, portal vein thrombosis, porta hepatis invasion, and metastatic ascites. The patient was in a severe condition due to sepsis and died. The survival period was 5 months from the first diagnosis.

Conclusion: Primary liver leiomyosarcoma is a rare neoplasm. More case series are required for a better understanding of prognosis and treatment outcomes. In this case, the tumor showed very aggressive behavior. The radical surgery and adjuvant therapy might be necessary.

Key words: Primary liver leiomyosarcoma, Immunohistochemistry study

Primary Leiomyosarcoma of the Inferior Vena Cava: A Case Report

Chairat Bunchaliew, Rawisak Chanwat, Thiravud Khuhaprema

Department of Surgical Oncology, National Cancer Institute of Thailand

Introduction: Primary leiomyosarcoma of the inferior vena cava (IVC), a rare and poor prognosis tumor, is usually presented at late stage with surrounding structure involvement causing an unresectable disease or distant metastasis. We here presented a patient who was successfully treated by surgical resection and reconstruction with a vascular prosthesis.

Methods: A 55-year-old lady suffered from progressive abdominal pain with sudden onset of hypertension for 2 months. Her abdominal CT scan revealed a 10 cm x 9 cm x 6 cm mass at right para-caval area which involved right kidney, right renal vessels and infra-renal IVC. MRV was organized to identify collateral circulation in case of left renal vein is needed to be resected and implanted to vascular graft. Other further investigation including chest CT scan, 24-hour urine epinephrine, norepinephrine and metanephrine were normal.

Results: Explore laparotomy and en bloc tumor removal with right nephrectomy and IVC resection was performed in this patient. After tumor was resected, a 20 mm Dacron graft was used for IVC reconstruction. The pathological specimen revealed a 10 cm x 9 cm x 6 cm tumor which was originated from IVC. Post-operative course was uneventful. Patient was discharged on 7th post-operative day. Pathological report revealed a high grade, primary leiomyosarcoma of IVC with free all resection margin. She was not received any anti-coagulant or adjuvant treatment. Now, She is doing well at 6 months after operation.

Conclusions: Curative surgical resection remains the current treatment of choice for primary leiomyosarcoma of the IVC.

Poster Presentation

Isolated Eosinophilic Pancreatitis- A Case Report

***Chuathong A, Hiranyakas A, Kamonmarttayakul K,
Ouawathanamongkol S, Chongchitnant N, Maipang T.***

Bangkok Hospital Phuket, Muang, Phuket

Background: Eosinophilic pancreatitis is a rare pancreatic condition that is diagnosed only by reviewing the pancreatic specimen. This condition typically presented with eosinophilic gastroenteritis that could involve any part of the gastrointestinal tract (particularly the stomach, small intestine and colon) at the time of presentation. Nevertheless, isolated biliary tract involvement had also been reported. We reported and isolated eosinophilic infiltration of the pancreas that was an extremely rare condition.

Case report: A 69 year-old Swiss gentleman presented at the Cancer Center, Bangkok Hospital Phuket in October 2012, with the complaint of an intermittent epigastric pain for 7-8 months. He also lost 4-5 kg during the past 2 months. Physical examination was not remarkable. The whole abdominal Magnetic Resonance Image (MRI) and the Magnetic Resonance Cholangiopancreatography (MRCP) demonstrated moderately enlarged pancreatic head with multiple cystic lesions predominately at pancreatic head and body. The sizes were varied from 1 to 1.4 cm in diameter. Common bile duct was mild dilatation and gradual tapering without evidence of luminal filling defect. Dilatation of main pancreatic duct of 7-8 mm was also noted (Figure A.). Serum CA 19-9 was 104.4 U/mL (0-25). Complete blood count was normal without eosinophilia. He subsequently underwent Endoscopic Retrograde Cholangiopancreatography (ERCP) with biopsy showing negative for malignancy cell. Whipple's operation was carried out with satisfied postoperative recovery.

Discussion: The etiology of the isolated eosinophilic infiltration of the pancreas was unclear. The patient allergic history to variable of foods had been observed that may imply the role of hypersensitive response. We reported a rare case of isolated eosinophilic infiltrated pancreas that the patient presented with symptomatic pancreatic tumor and high level of serum CA 19-9. Preoperative tests were challenged to exclude malignant condition. The combination of preoperative imaging and ERCP were not always helpful in this difficult situation. Careful surgical intervention was indicated for a proper histopathological study.

Conclusion: Isolated eosinophilic infiltration of the pancreas could be mimicking a pancreatic neoplasm. Whipple's operation by the experienced hands may be indicated in this setting.

Laparoscopic Colorectal Surgery in Elderly Patients: Three Year Experience of National Cancer Institute Thailand

Saipan Khunpugdee, Thirawut Khuaprema

National Cancer Institute, Surgical department, Bangkok, Thailand.

Background: We prefer laparoscopic colorectal surgery (LC) for all patients if we can perform because of benefits of minimally invasive surgery. The author studied the outcomes of laparoscopic colorectal surgery performed by a surgeon on 37 consecutive patients with or older than 70 years old during 3-year period.

Material and Methods: February 2010 to January 2013, 202 patients underwent elective laparoscopic colorectal surgery in National Cancer Institute by the same surgeon. Patients aged 70 years or older were identified. Retrospective data was analysis.

Results: LC was performed in 37(18.32%) elderly patients out of 202 patients. Mean age was 75.3 years (range, 70-87 years). 17 (45.9%) out of 37 patients were male. Mean BMI was 22.1(range, 14.7-30.9). Incidence of co-morbidity was 86.5%, almost were cardiovascular diseases (75.7%). Mean intensive care unit stay was 1.9 days (range, 0-10 days). Mean hospital stay was 10.7 days (range, 3-41 days). Indication for surgery was cancer in 36 cases (97.3%). Types of procedure were left side segmental colectomy 20 cases (54.1%), APR and Hartmann procedure 9 cases (24.3%), right colectomy 6 cases (16.2%) and total colectomy 2 cases (5.4%). Conversion to open surgery was found in one case (2.7%) of right colonic cancer due to duodenal wall invasion. As for staging of cancer, we found stage I in 9 cases (25%), stage II in 9 cases (25%), stage III in 14 cases (38.9%), and stage IV in 4 cases (11.1%). Seven (18.9%) cases had complications, which were CHF, Bladder dysfunction, wound infection, gut obstruction, diarrhea and leakage. Reoperation was performed in 3 cases due to leakage for 1 case and gut obstruction for 2 cases. There was no hospital mortality and readmission in this series. Five patients died during follow-up period from cancer in 3 cases and the others died from cardiovascular disease.

Conclusion: Laparoscopic colorectal surgery for elderly patients is feasible and safe.

	N	Minimum	Maximum	Mean	Std. Deviation
Age (year)	37	70	87	75.27	4.221
Body Mass Index	37	14.73	30.85	22.0605	3.41735
ICU Stay (day)	37	0	10	1.92	1.801
Hospital Stay (day)	37	3	41	10.68	6.713
Valid N (listwise)	37				

Early Surgical Outcomes of Minimally Invasive Esophagectomy for Locally Advanced Esophageal Cancer: NCI Experience

S. Khunpugdee, T. Khuaprema

National Cancer Institute, Surgical department, Bangkok, Thailand.

Background: Most of esophageal cancer patients in Thailand came with progressive weight loss from obstructive advanced cancer and carried very poor prognosis and poor quality of life. Palliative esophagectomy for these advanced cancer patients which aimed for restore oral diet and quality of life and oncologic control is remaining controversial. Esophageal stent installation may be the method of choice but the expensiveness, the problem of food impact or patency, the stent migration and without oncologic control are the main problems.

Objective: MIE or Minimally invasive esophagectomy hopes to result in better surgical outcome for these patients. We present early experience of palliative MIE in advanced obstructive esophageal cancer patients.

Materials and Method: From October 2012 to February 2013, 4 patients (age range, 50-65 years) with thoracic esophageal cancers (BMI 15-18) had investigated by endoscopy biopsy and CT scan. Patients with esophageal cancer less than 25 cm from incisor were excluded from surgery. All without pulmonary-liver metastases, celiac node metastases, aortic-atrium-tracheal-bronchus invasion, and severe systemic comorbidity were included for MIE. Thoracoscopic Esophagectomy in prone position, laparoscopic gastric conduit and cervical anastomosis were performed in 1 case. Intrathoracic anastomosis by hand suture was performed in 1 case. FEEA (What is it?) was performed in 2 cases.

Results: There was no 30-day mortality. One patient needed re-intubation for 3 days from abdominal distention. One case had permanent hoarseness from RLN injury. One case had high output chylothorax needed re-thoracoscopic thoracic duct clipping. Anastomotic stricture needed balloon dilation in 1 case. All were discharged within 14 days and 2 cases were readmitted from severe back pain and dysphagia from anastomotic stricture. Pathological reports were T4 (with greatest diameter of 12.5 cm, 12 cm, 3.5 cm and 3 cm each case) with R1 (micro positive radial margins), node metastases N0/7, 2/26, 0/10 and 4/7.

Conclusion: Palliative MIE for obstructive advanced esophageal cancer is feasible and safe procedure with acceptable morbidity and no mortality. We prefer intrathoracic anastomosis to avoid RLN injury. Intrathoracic anastomoses as FEEA by multiple endoGIA linear staplers are simpler and avoid anastomotic stricture. Proximal and distal free margins were possible even in less than 5 cm margin transection. But for radial margins, it was hard to get R0 free margin, only grossly free margins, R1, we got in locally advanced esophageal cancer. We performed only limited node dissection for these cases because of our limited experience now. Minimal invasive surgery was the main factor for good result in these high risk patients.

Thoracoscopic Selective LowThoracic Duct Clipping in Chylothorax following MIE for Cancer: National Cancer Institute(NCI) experience

S. Khunpugdee, T. Khuaprama

National Cancer Institute, Surgical Oncology, Bangkok, Thailand

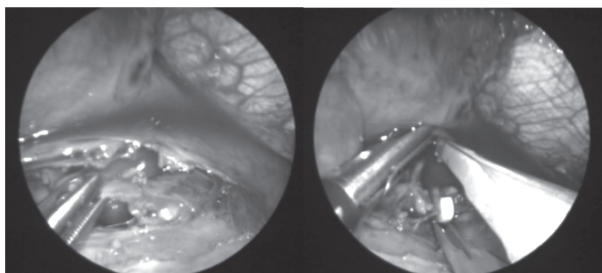
Background: High-output thoracic duct fistula with daily drainage over 2,000ml leads to nutritional and immunological deterioration, especially in cancerous patient with esophagectomy. In literature, the thoracic duct ligation can carry out just above the right hemidiaphragm by a mass ligature technique encircling all tissue between the azygos vein and aorta. The successful ligation will achieve immediate cessation of drainage. Identification of the fistula site is avoided by this technique

Objective: We report the minimal invasive surgical intervention for thoracic duct injury following minimal invasive esophagectomy for locally advanced midthoracic esophageal cancer.

Material and method: A 52-year-old male with BMI 14.6 presented with obstructing midthoracic esophageal cancer of T4N1M0 by endoscopic examination and chest computer tomography. The patient underwent minimal invasive esophagectomy (MIE) and R1 resection achieved because cancer invaded left bronchus anteriorly and tissue posteriorly. High-output thoracic duct fistula began at postoperative day 2 and continued more than 2,000 ml of drainage per day. Re-operation at day 5 after esophagectomy was performed by thoracoscopic approach. Low thoracic duct was clipped at the level just above right hemidiaphragm.

Result: Operative time for thoracoscopic selective low thoracic duct clipping was about 70 min. The high output right pleural drainage decreased abruptly to 100-200 ml per day and chest tube was removed 3 day after operation. The patient was sent for esophagography and started oral liquid diet at day 7 and discharged day 11 after esophagectomy.

Conclusion: Thoracoscopic selective low thoracic duct clipping is feasible and effective surgical intervention procedure for the management of thoracic duct injury. When urgent surgical intervention perform, difficulty in identifying and isolating structure can avoid from less pleural adhesences.



Oncologic Outcome of Laparoscopic Gastrectomy for Gastric Cancer: Experience in National Cancer Institute

S. Khunpugdee, T. Khuaprema

National Cancer Institute, Surgical department, Bangkok, Thailand.

Background: Laparoscopic radical gastrectomy for gastric cancer is becoming well-known procedure for early gastric cancer in minimally invasive era. In Thailand, almost gastrectomies were performed in advanced cancers as stage II or III.

Objective: We present surgical and oncological outcomes of 11 patients underwent laparoscopic gastrectomy after 3 years experience.

Materials and Methods: October 2010 to July 2012, 11 Gastric cancer patients underwent laparoscopic radical gastrectomy. 8 of 11 patients had no distant metastases. Another 3 patients, more advanced cancers but resectable confirmed by laparoscopic staging, composed of an ovarian metastasis -post TAH-BSO (What is it?) in 52-year-old patient, a limited carcinomatosis in 71-year-old patient and a liver segment 3 invaded gastric cancer in 32-year-old patient. Follow up to April 2013, 10 patients had follow up to date or died, one case had loss follow up after one time of postoperative visit. The data was retrospectively collected and analyzed.

Results: All 11 patients (5 male 6 female) with mean age 58.91 years (range, 32 - 83 years), mean BMI 18.99 (15.47 - 20.80), underwent total laparoscopic total gastrectomy (TLTG) 7 cases, Total laparoscopic distal gastrectomy (TLDG) 3 cases and laparoscopic assisted distal gastrectomy (LADG) 1 case. Stages of cancer at operation were stage I, 1 case (9.1%); stage II, 3 cases (27.4%); stage III, 5 cases (45.5%), and stage IV, 2 cases (18.2%). Early complication occurred only 1 patient (9.1%), in 83-year-old patient with stage IIIB post LADG. It was gastrojejunostomy ileus and resolved after temporary stent placement. Ten of 11 cases were discharged within 2 weeks without any complication. To April 2013, only 4 of 11 patients survived, with follow-up period of 9 (47-year-old female, stage IIB), 12 (71-year-old male, stage IA), 25 (55-year-old female, stage IIB), and 26 (48-year-old female, Stage IIIA) months. Four of 11 patients died from cancer cause at 3 (71-year-old female, stage IV), 9 (32-year-old female, stage IV), 15 (52-year-old male, stage IIIB), and 24 (83-year-old male, stage IIIB) months PO (What is it?). Two of 11 cases died from non-cancer at 4 (70-year-old male, stage IIIB) and 21 (67-year-old male, stage IIB) months postoperatively and loss follow up 1 case.

Conclusion: Laparoscopic radical gastrectomy for gastric cancer patients in our series had acceptable surgical and oncological outcome with no mortality and only 1 morbidity. 4 patients who survive are less advanced disease of stage I, stage II and stage IIIA.

Palliative Laparoscopic Ileocolic Bypass for Advanced Right Colonic Cancer: National Cancer Institute (NCI) Experience

S. Khunpugdee, T. Khuaprama

National Cancer Institute, Surgical Oncology, Bangkok, Thailand

Background: Many palliative treatments are recommended in obstructive advanced stage colorectal cancer patients with severely altered general health and with diffuse non-resectable hepatic metastasis. Endoscopic placement of the self-expandable plastic stent is the new intervention for colonic cancer complicated with obstruction in the preparation of the radical surgery or palliative treatment for non-resectable cancer. Laparotomy exploration and resection may provide good symptomatic results for patient with obstruction or bleeding from the primary tumour but carried significant morbidity and mortality.

Objective: We present 2 cases of complicated right colonic cancer with diffuse hepatic metastases treated by laparoscopic exploration and ileotransverse colon anastomosis. We present the advantage of laparoscopic exploration to identify and resolve the hidden complication that may be missed if the placement of self-expandable plastic stent was performed.

Material and Method: A 57-year-old male (BMI 23.56) and a 38-year-old female (BMI 26.3) were referred to NCI. Both patients had abdominal pain from obstructive advanced right colonic cancer with diffuse hepatic metastases. No ascites present in both cases. Both of them underwent laparoscopic exploration and ileotransverse colon anastomosis.

Result: The advanced and nonresectable natures of the tumour were confirmed at laparoscopy. The female patient also found abscess formation between colonic mass and abdominal wall from concealed minute leakage. The abscess was drained. The postoperative courses were uneventful. The patients' symptoms were improved in combination with oral diet. Then, they were sent for palliative chemotherapy.

Conclusion: Laparoscopic bypass surgery is safe and effective procedure even in advanced right colonic cancer patients with severely altered general health. However, laparoscopic approach may be difficult in setting of bowel dilatation, same as endoscopic interventions also difficult and high risk too. Because of the resection of primary colon cancer in these patients carried a significant operative morbidity and mortality. Laparoscopic bypass should be considered for palliative surgical intervention for patients with limited functional reserve like these. Another benefit is the chance to explore, detect and resolve the complication such as abscess too.

Traumatic Occlusion of Right External Iliac Artery After Blunt Abdominal Injury

Jaroen Cheewinmethasiri

Cardiovascular and Thoracic unit, Department of Surgery, Lampang Hospital, Lampang, Thailand

Background and objective: Blunt vascular trauma is rare as compared with penetrating vascular trauma. The incidence of iliac artery injury has been reported as low as 0.4 percent of total arterial trauma. We reported an interesting case presented with abdominal pain and right leg pain with distal pulse deficit after blunt abdominal injury.

Materials and Methods: A 75-year-old man presented with abdominal and right leg pain after blunt abdominal injury. Physical examination revealed generalized abdominal tenderness and absence of the right femoral and distal pulses. FAST showed small amount of fluid collection at hepatorenal recess and cul de sac. CT angiography showed occlusion of Rt. external iliac artery. He was transferred to operating room rapidly for revascularization and laparotomy. We decided to do the femorofemoral bypass with an 8-mm reinforced-ring PTFE graft first because of avoiding contamination in peritoneum. Then, laparotomy was performed; mesenteric injury was found and mesenteric repaired was made.

Results: After the operation was finished, all of right lower extremity pulses could be palpated. The patient was fully recovery and discharged after 1 week. The CT angiography of lower extremities at 2 months after discharge showed patency of PTFE graft.

Conclusion: Extra-anatomical bypass may be an alternative way in case of external iliac artery thrombosis associated with fecal contamination in peritoneal cavity.

Wound Dressing with TLC-NOSF Technology in Chronic Wound: Case report

Jaroen Cheewinmethasiri

Cardiovascular and Thoracic unit, Department of Surgery, Lampang Hospital, Lampang, Thailand

Background: Chronic wound is a wound that does not heal in an orderly set of stages and in a predictable amount of time the way most wounds do. Matrix metallo-proteinases (MMPs) are involved in the wound's chronicity. Excessive production of MMPs coupled with reduced expression of the tissue inhibition of MMPs, induce degradation of the extracellular matrix and inactivation of growth factor. The wound is maintained in an uncontrolled inflammatory state. Urgostart is a dressing that incorporate a MMP inhibitor, the Nano-Oligosaccharide Factor (NOSF) into lipidocolloid matrix dressing that provide wound healing in chronic wound

Objective: To demonstrate the benefit of Urgostart in chronic wound

Materials and methods: A 60-year-old man presented with chronic wound at his right foot after right big toe amputation from diabetic foot infection in 13 months ago. His underlying diseases were diabetes mellitus, dyslipidemia, and diabetic retinopathy. He had visited our hospital for wound dressing (wet dressing)for 13 months but the wound had not been healed. After no sign of infection was confirmed, we applied Urgostart to his wound and changed every 3-4 days depended on exudate from the wound. The beginning size of the wound was 8.2 x 5.1 cm.

Results: The wound was healed within 7 weeks after using Urgostart.

Conclusion: Urgostart can improve quality of life for patients with chronic wound due to less frequent dressing changes and accelerate wound healing. Moreover, Urgostart can save labour cost and time-consuming. In conclusion, NOSF and lipidocolloid matrix dressing (Urgostart) may promote the healing process of non-infected chronic wound.

Extremely Large Gastric GIST: A Case Report

**Moungthard H¹, Chanwat R¹, Panchan V¹, Bunchaliew C¹,
Thesawadwong T², Khuhaprema T¹**

¹Department of surgical oncology, National cancer institute, Thailand

²Department of pathology, National cancer institute, Thailand

Introduction: Gastrointestinal stromal tumors (GISTs) are mesenchymal tumor which most common arising from stomach. Tumor size can be varies from a few millimeters to > 30 cm. Usually, tumor size larger than 10 cm harbored malignant potential and associated with distant metastasis. We here reported an unusual case of extremely large, non-metastatic gastric GIST which successfully managed by an en bloc resection.

Methods: A 55-year-old man suffered from progressive enlarging abdominal mass for 20 years. MRI of the chest and abdomen revealed a 40 cm X 34 cm X 28 cm cystic mass in abdomen which suspected originate from stomach without lymph node enlargement or distant metastasis. His laboratories reported anemia, hyponatremia and hypoalbuminemia. En bloc resection was planned thus total parenteral nutrition and oral supplement diet was given for 2 weeks for improving nutritional status before operation.

Results: Explore laparotomy, tumor removal, partial gastric resection with distal pancreatectomy was performed. Operative time was 630 minutes and blood loss was 3000 ml. Pathological report revealed high grade gastric GIST, tumor containing necrotic tissue with blood clot and free resection margin. Post-operative course was complicated by pneumonia and respiratory distress. This required prolonged endotracheal intubation and then tracheostomy on 14th postoperative day. Length of ICU stay was 30 days and hospital stay was 60 days. He received no any adjuvant treatment. Now, he is doing well at 3 months after operation.

Conclusions: Surgical resection is a mainstay treatment for localized GISTs especially in case of extremely large tumor.

D-dimer in Patients with Strangulated Intestinal Obstruction

Satit Srimontayamas, Waigoon Stapanavatr

Department of surgery, Faculty of medicine, Vajira hospital, University of Bangkok metropolis.

Background: The strangulated intestinal obstruction is a serious condition that has unfavorable outcome. Recently, there is no accurate test and reliable marker to detect it. The purpose of this study is to assess the role of serum D-dimer in the diagnosis of strangulated intestinal obstruction.

Method: A prospective study of 73 patients with intestinal obstruction was conducted from June 2009 to January 2012. Blood samples were taken on admission for D-dimer measurement. The diagnosis of intestinal strangulation was based on operative finding.

Results: Seventy three patients were diagnosed the intestinal obstruction. The small intestinal obstruction from adhesion band was the most common cause that was presented in 50 patients (68%), the other causes, such as colonic obstruction from tumor and volvulus were presented in 8 patients (10.9%) and hernia was presented in 15 patients (20.5%). Eleven patients (15.1%) were diagnosed strangulated intestinal obstruction which was complicated from small bowel obstruction in 8 patients (72.7%), large intestinal obstruction in 2 patients (18.2%) and hernia in 1 patient (9.1%). Intestinal resection was performed in all patients with strangulated intestinal obstruction. In this study, 8 from 11 patients (72.7%) with strangulated intestine had high level of D-dimer, while 25 from 62 patients (40.3%) with non-strangulated intestine had. The mean D-dimer level was 0.75 mg/l in patients with strangulated intestine and 0.47 mg/dl in patients with non-strangulated intestine. The high level of D-dimer (level > 0.3 mg/l) was frequently found in the cases of strangulation rather than in the cases of non-strangulation ($p=0.04$). The mean D-dimer level was higher in the patients with strangulated intestine, but it was not reach statistic significance ($p=0.068$).

Conclusion: The high level of serum D-dimer may be useful in diagnosis of the strangulation of the intestine in patients with intestinal obstruction.

Outcome of Normal Saline Flushing for a Totally Implantable Central Venous Access Device

Kamonrut Pibul*, Kanyarat Katanyu, Prapapan Chotikanon**
Somboon Opasyul****

*Department of Surgery, Faculty of Medicine Vajira Hospital, University of Bangkok Metropolis, Thailand

**Department of Radiology, Faculty of Medicine Vajira Hospital, University of Bangkok Metropolis, Thailand

Objective: To study the outcome of flushing a totally implanted central venous access device (port) with normal saline without heparin.

Materials and methods: This was a retrospective descriptive study. Data were collected from medical records of the patients who had port flushing with only normal saline at Faculty of Medicine Vajira Hospital from January 2009 to April 2012.

Results: A total of 35 patients were included. Mean age was 50.3 ± 7.1 years. Most were female (30 patients or 85.7%) and most had breast cancer (28 patients or 80.0%). Types of port were Celsite ST201® in 29 patients (82.9%) and Celsite Implantofix® in 6 patients (17.1%). All ports were flushed with 20 ml of normal saline. The flushing was done once every 4-18 weeks (median 12 weeks). With a median follow up of 96 weeks (36-156 weeks), none had port occlusion which needed port removal or re-implantation. Nevertheless, there were 2 patients (5.7%) whose blood could not be aspirated through the device but only fluid injection was possible. The problem in these 2 patients was solved by an injection of 5 ml of 500 units/ml heparin which was left in the port. A follow up at 4-week in both patients demonstrated a completely patent port serving for blood aspiration and fluid injection.

Conclusion: Normal saline flushing was one of the effective flushing techniques for the port.

Keywords: totally implantable central venous access device, port, normal saline flushing, flushing technique.

Vacuum Dressing for Serum Oozing Wound: Applied Technique from Traumatic Temporary Abdominal Wound Closure

***Suphakarn Techapongsatorn, Sunantha Tipaya-udom,
Siwarak Warodomrangsimun, Wisit Kasetsermwiriya,
Sopon Lerdsirisopon, Satit Srimontayamas, Amarit Tansawet***

Department of Surgery, Faculty of Medicine Vajira Hospital, Navamindradhiraj University

Objective: This study presents the outcome of vacuum dressing in open serum oozing wound.

Materials and Methods: Thirty patients who had an open wound with serum oozing required wet dressing once daily. Vacuum dressing technique was applied for wound care and the dressing was changed every other day. Step by Step for Vacuum dressing was as follows:

- Prepared wound base
- Covered the wound base with gauze
- Placed a 12 F nasogastric tube over the gauze
- Applied the Opsite to cover the wound area
- Started the vacuum dressing

Result: All patients were satisfied with this technique (mean VAS = 9.4). No patients needed to change the dressing before the plan. No patients developed surgical site infections.

Conclusion: Vacuum dressing technique can be applied for serum oozing wound by using general nursing equipment with an acceptable result.

Skip Segment Hirschsprung's Disease Presented with Meconium Peritonitis: Report of a Rare Case and Its Management

Patchareeporn Tanming, Vinai Tantiyasawasdikul, Suchat Areemit

Pediatric Surgery Unit, Department of Surgery, Srinagarind Hospital, KhonKaen University, KhonKaen, 40002, Thailand.

Meconium peritonitis and skip segment Hirschsprung's Disease (SSHD) is a rare condition. A male newborn, 39 weeks gestational age with the weight of 3,150 grams, presented with abdominal distension after birth. Plain film of the abdomen revealed a large amount of pneumoperitoneum and multiple intra-abdominal calcifications. After his condition had been stabilized, the patient underwent exploratory laparotomy.

During the laparotomy, meconium pseudocyst and ileal perforation were identified. Loop ileostomy was performed at the perforation site. Serial muscular biopsies at ileum and appendix, as well as ascending, hepatic, transverse, splenic and sigmoid colon was done. The pathological report revealed aganglionic segments at hepatic to splenic flexure.

Six weeks afterward, the definite surgery was considered, but was eventually discarded due to the concern of bowel movement in the aganglionic segment. Instead, Santulli enterostomy at the ascending colon was performed. Postoperatively, the patient had passed stool regularly without need for laxative or rectal irrigation. Two months after enterostomy, the stroma spontaneously closed. At the age of five months, the patient was growing well and was able to tolerate breast milk without any problems.

Key words: Meconium peritonitis, skip segment Hirschsprung's Disease, SSHD

Email address :ptanming@gmail.com, Telephone number : +6689-711-0177

The First Successful Simultaneous Pancreas-kidney Transplantation at King Chulalongkorn Memorial Hospital: A Case Report

Jade Suphapol¹, Bunthoon Nonthasoot¹, Boonchoo Sirichindakul¹, Wipusit Taesombat¹, Yingyos Avihingsanon², Natavudh Townamchai², Kamol Panumatrassamee¹, Ruenreong Leelanukrom³, Laddawan Vajragupta⁴, Sarat Sunthornyothin², Supanit Nivatvongs¹

¹Department of Surgery, ²Department of Medicine, ³Department of Anesthesiology, ⁴Department of Radiology, Faculty of Medicine, Chulalongkorn University, Bangkok 10330, Thailand

Background: This report described the first successful simultaneous pancreas-kidney transplantation (SPK) at King Chulalongkorn Memorial Hospital. A 45-year-old male patient who suffered from diabetic retinopathy and end staged renal disease (ESRD) requiring hemodialysis due to type I diabetes was offered for SPK.

Methods The operation was performed on November 12, 2012. The graft was obtained from 15-year-old man cadaveric brain-death donor. The donor had group B blood which was identical to the recipient. T cell-cross match was negative but B cell IgM was weakly positive. HLA typing also was done. Regarding our immunosuppression protocol, we used thymoglobulin, IL-2R (simulect) and methylprednisolone for induction and tacrolimus, MMF and prednisolone for maintenance. Cytomegalovirus prophylaxis and anticoagulant to prevent vascular anastomosis thrombosis were also applied.

The operation was performed via a midline incision. The kidney transplantation was carried out first on the left iliac fossa. The ureteric anastomosis was withheld until the pancreatic transplantation was completed on the right iliac fossa to minimize ischemic time of pancreatic graft. Porto-systemic anastomosis and enteric drainage was performed for pancreatic transplantation. Total ischemic time for the kidney was 9 hr 49 min and 11 hr 36 min for the pancreas. Total operative time was around 8 hr.

Results: Postoperatively, his blood sugar has been normal without the need of insulin injection. His serum C-peptide level was also normal (7.4, normal range 0.9-7.1) on the first postoperative day. Three months after the operation, the HbA1C level returned to normal (5.8 mg %). He remained dialysis free with adequate urine output but a high normal serum creatinine (Cr 1.4 mg/dl), which might be explained by relatively small transplanted kidney size. Until now, the patient's condition remains well without the need of insulin and dialysis and he has no surgical complications.

Conclusion: In case of diabetes type I and ESRD, SPK should be considered as the first line of treatment to cure both conditions whenever possible.

Keywords: simultaneous pancreas-kidney transplantation

Acute Mesenteric Ischemia in A HIV-Positive Patient: A Case Report

Noppawat Samankatiwat*, Chanin Klinjongkol*, Bussaba Pukderat**

*Department of Surgery, Ratchaburi Hospital, Ratchaburi, Thailand

**Department of Radiology, Ratchaburi Hospital, Ratchaburi, Thailand

Background: A mesenteric ischemia is a relatively rare condition but has high mortality rate. Successful treatment requires early diagnosis and surgical intervention. We reported a case of acute mesenteric ischemia in a HIV-positive woman diagnosed with MDCT and successfully treated with emergency surgery.

Case Report: A 46-year-old woman, who had a history of HIV positive and diabetes, presented with symptoms of low grade fever, nausea, vomiting and abdominal pain for 2 days. The physical examination revealed body temperature 39.6 oC, generalized abdominal tenderness and decreased bowel sound. The patient had marked leukocytosis, high serum potassium (6.22 mmol/l) and elevated serum amylase (863 u/l). The abdominal X-ray showed generalized dilatation of small bowel. The computed tomography (MDCT) scan was found to have an intraluminal thrombus in branches of the superior mesenteric artery and dilated segment of small bowel 3.2 cm in diameter with thickening wall of small bowel 4-5 mm thickness with intramural air bubbles. Emergent exploratory laparotomy was performed. Arteriotomy of superior mesenteric artery was done. Thrombus was found in the proximal portion of the SMA just distal to the origin of the middle colic artery. Thrombectomy was successfully performed. The patient was found to have 3 feet gangrenous segment of the small bowel. Segmental resection of necrotic bowel and end to end anastomosis were done. The operative time was 3 hours and 15 minutes. There were no intraoperative complications. Length of hospital stay was 40 days. Long term anticoagulant was continued. No recurrent disease was detected during 5 month follow-up.

Conclusion: Acute mesenteric ischemia is an emergency condition which requires prompt diagnosis and appropriate surgical treatment. This report illustrates this rare condition in a HIV-positive patient which received successful diagnosis and management.

Specialty: General surgery

Presentation: Poster presentation (no competition)

Audio-visual Presentation

Laparoscopic Roux-EN-Y Gastric Bypass: A Stepwise Tips and Techniques

***Ajjana Techagumpuch, Pakkavuth Chanswangphuvana,
Soravith Vijitpornkul, Chadin Tharavej, Suppa-ut Pungpapong,
Patpong Navichareern, Suthep Udomsawaengsup***

Department of Surgery, King Chulalongkorn Memorial University Hospital

Background: Morbid obesity has become increasing concern problem in Thailand and the number of patients rapidly increase over times. Laparoscopic roux-en-y gastric bypass (LRYGB) is the gold standard treatment, however, the procedure is not widely performed due to difficult technique.

Objective: This video demonstrated tips and techniques for the procedure stepwise, and pointed out important steps to make it easier.

Methods: After first LRYGB in King Chulalongkorn Memorial Hospital, we developed and continuously improved the procedure which can divided into 4 principle steps

- 1) Positioning and port insertion
- 2) Pouch creation
- 3) Jejunojejunostomy anastamosis
- 4) Gastrojejunostomy anastamosis

Tips and techniques of each step were aggregated and demonstrated in the video presentation.

Results: LRYGB were performed in 116 patients which mean ages was 34.6 years, mean BMI was 44.3 kg/m², mean operative time was 178 minutes, and average excess weight loss 1 year after surgery was 66.5% ,with complication rate was 1.76% comparable to international report.

Conclusion: The key of procedure is performing the procedure step by step. This video presentation will provide a better understanding of each step, therefore help to improve and develop individual technique.

Glissonean Pedicle Approach for Liver Surgery

Chairat Bunchaliew, Rawisak Chanwat, Thiravud Khuhaprema

Department of surgical oncology, National cancer institute, Thailand

Introduction: Glissonean pedicle approach is one of many methods for performed anatomical liver resection. This technique can applied for many type of liver resection which helped shorten operative time and created bloodless surgery.

Methods: Glissonean pedicles are structure including hepatic artery, portal vein and bile duct that ensheathing by Glisson's capsule within the liver. This pedicle can be categorized as primary, secondary and tertiary level that consisted on right and left side. Usually, primary and secondary pedicles on both sides can be encircled, controlled and transected extrahepatically.

Results: We presented a video demonstration of liver anatomy, plate systems and extrahepatic glissonean pedicles which detailed step to perform Glissonean pedicle approach. Cholecystectomy was done and cystic plate was ligated then hilar plate was taken down from liver. Bifurcation between right and left pedicle was identified and both pedicles were encircled. Bifurcation between right anterior and right posterior pedicle was dissected followed by both secondary pedicles were taped. Each pedicle was controlled and demarcation line was observed before proceed to resection step.

Conclusions: Glissonean approach is a surgical techniques that can be safely performed in selected patient with liver cancer.

Video Presentation “Laparoscopic Splenic Preserving Distal Pancreatectomy”

Chaiyaporn Suwitchakul

Fellowship in Minimally Invasive Surgery, Department of Surgery, Rajavithi Hospital.

A 65-year-old Thai female patient presented with convulsion and unconscious from hyperinsulinism and hypoglycemia. Diagnosis is insulinoma at body and tail of pancreas. Laparoscopic splenic preserving distal pancreatectomy was achieved with a good result.

Video Presentation “ Peroral Endoscopic Myotomy (POEM) for Achalasia in Thailand”

Chaiyaporn Suwitchakul

Fellowship in Minimally Invasive Surgery, Department of Surgery, Rajavithi Hospital.

POEM is a novel therapeutic technique for Achalasia. Five POEMs were performed by 2 endoscopists in Laparoscopic-endoscopic center, Department of Surgery, Rajavithi Hospital. This video presents the procedure in stepwise manner. Short term outcome is very good. However, long term outcome is awaiting.

Laparoscopic Training Box Improves Residents Skill Performance

Taweesak Tongtawee, Somboon Subwongjaroen

Department of Surgery, Rajavithi Hospital, Bangkok 10400, Thailand

Background: In the future, laparoscopic surgery will be a standard treatment of many diseases.

Since laparoscopic skill of surgeon is not parallel to laparoscopic tools, we want to design laparoscopic training box for improving resident skill performance.

Materials and methods: The Microsoft life cam is a program that is particularly designed for this box. We use standard laparoscopic tools that are used in a real surgery. 6 residents and 6 staffs of the department of surgery were enrolled as operators in this study.

We have 3 stations for laparoscopic training box programs.

1. The 2-handed transferring rope coordination procedure
2. The 2-handed stretching procedure
3. The sewing procedure

Result: The result shows that laparoscopic training box can improve laparoscopic skill in all stations and reduce duration time in all stations. We hope laparoscopic performance can decrease complication caused by surgeon factor.

Correspondence to: Dr Taweesak Tongtawee, Department of surgery, Rajavithi Hospital, Bangkok 10400, Thailand.

E-mail:Thaveesak-123@hotmail.com

Laparoscopic Gastrectomy with Lymph Node Dissection for Advance Gastric Cancer: Early Experience in Vajira Hospital

Wisit Kasetsermwiriya, AtmaritTansawet, Sophon Lerdsirisophon, Suphakarn Techapongsathorn

Vajira Minimally Invasive Surgical Unit, Department of Surgery, Faculty of medicine Vajira hospital, Navamindradhiraj University, Bangkok, Thailand.

Background: Currently, laparoscopic gastrectomy (LDG) for gastric cancer was performed mainly in early gastric cancer (T1) however; the application of this technique for treatment of advance gastric cancer has been reported increasingly. Here we present our technique to perform laparoscopic distal gastrectomy.

Aims: To report our early experience of laparoscopic gastrectomy for advance gastric cancer.

Methods: History and operative record of patients who underwent laparoscopic gastrectomy at Vajira hospital from August 2012 to May 2013 were reviewed. The pictures were captured from operative video.

Result: There were 5 patients who underwent laparoscopic gastrectomy, 3 distal gastrectomies and 2 total gastrectomies. There was no conversion. Mean lymph node harvested was 32 LNs. Every patient underwent lymph node dissection following the Japanese Gastric Cancer Guideline 2010. Here we present the detail of laparoscopic distal gastrectomy.

Conclusions: LDG technique is possible treatment option for advance gastric cancer and the number of dissected lymph node was comparable with the open technique, however the long term oncological outcome and further RCT are needed to compare with the open surgery.

Endoscopic Thyroidectomy via Anterior Chest Approach with Recurrent Laryngeal Nerve Preservation (VDO presentation)

Wisit Kasetsermwiriya, Amarit Tansawet, Sophon Lerdsirisophon, Suphakarn Techapongsathorn

Vajira Minimally Invasive Surgical Unit, Department of Surgery, Faculty of medicine Vajira hospital, Navamindradhiraj University, Bangkok, Thailand

Background: Endoscopic thyroidectomy has been performed in Thailand for many years. There are various techniques of procedure; some surgeons routinely identify the recurrent laryngeal nerve while the others omit this step. The purpose of this study is to report our technique and how to preserve the recurrent laryngeal nerve.

Methods: A case was reviewed from in-patient chart and the operative record. The pictures were captured from operative video.

Result: A 32-year-old female presented with 4-cm left thyroid nodule. The FNA was shown benign follicular cell. The patient was undergone endoscopic left lobectomy via anterior chest approach. Our technique to find the nerve is as follows; first, thyroid was free from strap muscles on the lateral side similar to open technique. The inferior pole was meticulous dissected and inferior thyroid artery was cut. At this step recurrent laryngeal nerve was identified at trachea-esophageal groove as in open technique. Then thyroid was cut from inferior pole to superior pole. The patient recovered uneventfully and was discharged on the second postoperative day.

Conclusion: Endoscopic thyroidectomy with recurrent laryngeal nerve identification was feasible and has a good cosmetic result.

Laparoscopic Suprapancreatic Lymph Node Dissection in D2 Distal Gastrectomy for Advance Gastric Cancer

Wisit Kasetsermwiriya, Atmarit Tansawet, Sophon Lerdsirisophon, Suphakarn Techapongsathorn

Vajira Minimally Invasive Surgical Unit, Department of Surgery, Faculty of medicine Vajira hospital, Navamindradhiraj University, Bangkok, Thailand.

Background: Currently, the suprapancreatic lymph node (consists of lymph node (LN) #7, 8a, 9, 11p and 12a) dissection is an important step in laparoscopic distal gastrectomy. The technique is similar to open surgery; here we present our technique to perform lymphadenectomy in laparoscopic fashion.

Aims: To report our technique of lymphadenectomy in laparoscopic gastrectomy for advance gastric cancer.

Methods: First, we dissect LN #12a and 5 along hepatic artery and right gastric artery respectively. After cutting duodenum, the LN #8a, 9 and 11p along the upper border of pancreas were dissected. Then the lymphatic tissue around origin of left gastric artery was dissected. Finally, LN #1 and 3 along the lesser curvature was cleared and reconstruction was performed respectively.

Result: There were 6 patients who underwent laparoscopic gastrectomy, 4 distal gastrectomies and 2 total gastrectomies. There was no conversion. Mean LN harvested was 32 LNs. Every patient underwent LN dissection following the Japanese Gastric Cancer Guideline 2010. Mean operative time was 324 minutes and mean operative blood loss was 220 cc. Every patient recovered uneventfully.

Conclusions: Laparoscopic gastrectomy is a treatment option for advance gastric cancer and the number of dissected LN was comparable to the open technique. Our laparoscopic suprapancreatic pancreatic LN dissection is feasible. However, long-term oncological outcome and further studies are mandatory.

Minimally Invasive Esophagectomy: 3-Hole Approach in Prone Position

Kamthorn Yolsuriyanwong, Siripong Chewathanakornkul

Division of General Surgery, Department of Surgery, Faculty of Medicine, Prince of Songkla University, Songkhla, Thailand

Introduction: Recently, minimally invasive esophagectomy (MIE) has become an optional procedure for esophageal cancer treatment. Many reports on this operation as a standard procedure have indicated better results than the open technique, especially in terms of pulmonary complications; the oncologic results are not inferior to those of the open technique as well. Several MIE techniques have been introduced. One of them is thoracoscopic surgery in the prone position with laparoscopic surgery and cervicotomy with anastomosis (the 3-hole approach). Many reports propose this technique because it allows for good exposure during thoracoscopic surgery as the lung drops with gravity. Thus, lung retraction is not necessary and the trachea is pulled down slightly, which causes the aortopulmonary window to open more and makes the lymph node dissection in this area easier than in the left lateral decubitus position.

Purpose: To present our technique of the 3-hole approach of MIE in the prone position

Methods: We present a case of a mid- to lower-thoracic esophageal cancer; the clinical staging was at least T3N0M0. This case received preoperative chemoradiation therapy with a partial response. There are three main steps in this procedure. The first step, the thoracoscopic surgery in the prone position, consists of operation set-up, port insertion, separation of the azygos vein, mobilization of the entire esophagus, and thoracic lymphadenectomy. The second step, the laparoscopic surgery, comprises operation set-up, port insertion, separation of the greater and lesser omentums, celiac lymph node dissection, ligation and separation of the left gastric vessels, hiatal dissection, testing for adequate gastric mobilization, gastric conduit creation, hiatal defect closure after gastric pull-up, and feeding jejunostomy. The third step, cervicotomy with anastomosis, is composed of neck positioning, incision, cervical esophageal mobilization, esophageal and gastric pull-up, specimen removal, and esophagogastric anastomosis.

Results: The operative time was 390 minutes, blood loss was 200 ml and no intraoperative complication was encountered. The patient could be extubated and start jejunostomy feeding on the first postoperative day. The barium esophagogram on the sixth postoperative day showed the anastomosis had no leakage. Moreover, there were no postoperative complications. The pathological result showed a residual squamous cell carcinoma, 0.4 cm in diameter, free resection margins, and metastatic squamous cell carcinoma in 2 out of 22 lymph nodes.

Conclusions: The 3-hole MIE approach in the prone position for esophageal cancer treatment is feasible, safe and provides good exposure in the thoracoscopic surgery part.

Surgical Dilatation of Arterio-venous Fistula (AVF) Stenotic Lesions

***Burapa Kanchanabat, Wikoorn Stapanavatr, Yutapong Wongmahisorn,
Pong Kanchanasuttiruk, Wuttichai Saengprakai***

Department of Surgery, Faculty of Medicine, Vajira hospital. Bangkok Metropolitan university

As the prevalence of chronic renal disease increases, revision of AVF has become one of the most common surgical service in vascular surgery. The results of endovascular surgery with balloon angioplasty or stent are suboptimal in terms of efficacy and patency rate. In addition, this procedure incurs high cost for the patients and national health resources. This audio-visual presentation demonstrates the utilization of biliary bougie dilator and vascular clamp for the correction of AVF stenotic lesion. Brief summarization of the results are also reported.

VDO Presentation: Techniques Nerve Preservation in Laparoscopic Rectal Cancer Surgery

Suttatip Seumoo, Worrawit wanitsuwan, Siripong Chewatanakornkul

Division of General Surgery, Department of Surgery, Faculty of Medicine, Prince of Songkla University, Songkhla, Thailand

Background&Objectives: The rectal cancer surgery has a risk of nerve injury. The technique named Total mesorectal excision (TME) has been a gold standard for rectal cancer surgery since 1990s by Prof. Heald. In this technique is complete excision of mesorectal tissue within the intact envelope of fascia propria of the rectum. Also, preservation of autonomic nerve is warranted to avoid genitourinary complication and sexual dysfunction. In the present, laparoscopic treatment is more popular and has benefit to identify the autonomic nerve by obviously. We presented a point that during TME technique with emphasis on critical points of nerve damage and the technique that can prevent the autonomic nerves in laparoscopic view.

Methods: A 50-year-old Thai male with active sexual life was diagnosed with well differentiated adenocarcinoma of mid to lower rectum. Laparoscopic low anterior resection was planned. Lithotomy position was used with special precaution on pressure free of peroneal nerve and bony prominent. Port incision was performed which provided a good exposure and easier the technique.

In laparoscopic rectal cancer surgery technique, we start the left-sided colon mobilization from medial to lateral approach, begin from the plane below the superior rectal artery and dissect until to the white line of Toldt. By extending this plane upwardly, the splenic flexure is mobilized in case having tension of the anastomoses. We show the technique nerve preservation following this stepwise TME technique in laparoscopic view.

For the superior hypogastric plexus preservation, the mesocolic dissection began just below superior rectal artery and extended laterally to join the previously dissected plane to the lateral aspect. The correct plane has fascia above the ureter and gonadal vessels group. Step of high ligation of inferior mesenteric artery and inferior mesenteric vein was performed at the same level 2 cms from the aorta. This stepwise could protect the superior hypogastric plexus.

For the hypogastric plexus preservation, we used the technique sharp dissection under direct vision along avascular plane between fascia propria of the rectum and parietal pelvic fascia started at the sacral promontory downwards in the same plane as colonic mobilization. Used instrument to retraction of the rectum anteriorly facilitated the posterior dissection which was carried on till to the pelvic floor.

For the pelvic plexus preservation stepwise, after we can identify and preserve the hypogastric nerves. Then, the dissection extended to laterally on both sides with identification of the pelvic plexus and group of the hypogastric vessels. In this part, used instruction to make a tension plane which can be clearly to see the pelvic plexus and try to dissect to closely at the rectum. Anterior dissection started by transverse division of peritoneal reflexion and went further down in the plane behind the seminal vesicle and anterior to anterior mesorectal fascia which represent the Denonvilliers' fascia still was intact. The precise traction technique of the instrument provided a good exposure in the pelvic cavity. This technique can be safe the pelvic plexus.

And then circumferential dissection ended at the pelvic floor where the mesorectum ended. After the rectal resection, tension-free anastomosis was performed with stapling devices technique in laparoscopic view.

Results: Laparoscopic rectal cancer surgery technique with technique precise nerve preservation was showed. This patient returned to normal without genitourinary complication and sexual dysfunction.

Conclusion: In laparoscopic rectal cancer surgery technique, understanding the technique which correct surgical plane and nerve preservation are a key for good TME in laparoscopic view. This technique will result in low bladder and sexual dysfunction from the autonomic nerve injury during laparoscopic rectal cancer surgery.

Operative Techniques in Multivessel Off-pump Coronary Artery Bypass Graft (OPCABG) at Lampang Hospital

Nuttapon Arayawudhikul

Cardiothoracic and vascular unit, Department of Surgery, Lampang Hospital

Background: Conventional coronary artery bypass graft (CABG) has been a standard of care for treating patients suffering from ischemic heart disease for over 5 decades. Since late 1990s, percutaneous coronary intervention (PCI) has become more and more popular due to its advantages of less invasiveness and complications compared to conventional technique. OPCABG may be considered as an armamentarium to treat patients more effectively.

Objectives: To review the results of OPCABG surgery of Lampang Hospital and share our surgical techniques via audiovisual presentation.

Materials and Methods: Retrospective review from hospital database from April 2011 to June 2013

Results: Between April 26, 2011 and June, 2013, eighty-six cases were treated by using OPCABG technique. Of 291 performed anastomoses, internal mammary artery regarded as an artery of life for bypass were utilized in 90% (LIMA 89.5%, RIMA 17.4%, GEA 3.6%, LRad 13.9%, and SVG 2.5%). Regarding clinical results, there were conversion to on-pump technique 2 cases (2.3%), unplanned IABP insertion 2 cases(2.3%), operative death 0 case (0%), 30-day mortality 1 case (1.1%), CVA 0 case (0%), re-explore for bleeding 1 case (1.1%), sternal wound infection 0 case(0%)

Conclusions: The result of OPCABG is comparable to conventional technique. Since the technique is difficult at the beginning and requires steep learning curve, OPCABG is not popular in Thailand (less than 15%). However, strong consideration and dedication of the surgical team and anesthesiologist are the only way to achieve the goal.

Single Port Laparoscopic Sigmoidectomy

Angkoon Anuwong, Burin Awapittaya, Siripong Sirikurnpiboon

Rajavithi Hospital, Bangkok 10400

Objective: The purpose of this study is to report our experience with 2 techniques of laparoscopic sigmoidectomy in CA sigmoid.

Materials and methods: A 79-year-old Female, presented with history of bowel habit change for 1 year with weight loss of 3kg in 2months.

Sigmoidoscopy : sessile mass at sigmoid colon
occupied 1/2 circumferential of lumen

Pathologic study : High grade dysplasia

CT Whole abdomen with triple contrast showed as follows:

- Infiltrative lesion at distal descending to proximal, sigmoid colon
- No adenopathy was seen
- No sign of metastatic disease

Result: Laparoscopic sigmoidectomy was performed in 2 patients.

Conclusion: This study aims to compare single port to conventional technique in terms of wound size, operative technique and operation time.

Single Access Laparoscopic Rectal Surgery in Glove Technique

Angkoon Anuwong*, Burin Awapittaya, Siripong Sirikurnpiboon

Rajavithi Hospital, Bangkok 10400

A 52-year-old man has been presented with bleeding per rectum. Colonoscopy found circumferential rectal mass 10 cm from anal verge. Biopsy was done and found well differentiated adenocarcinoma of rectum. We decided to perform single access laparoscopic rectal resection in this patients. The 4 centimeters incision was created at left para-umbilicus down to intra-abdomen. A surgical glove was inserted in Alexis wound retractor and used as glove port. We cut the end of 3 glove's fingers and put 5mm ports in. 10 mm port was inserted in one glove's finger. 5mm camera and instruments were inserted and performed operation. The medial to lateral approach was used as in conventional laparoscopic surgery. IMA was ligated using metallic clip. Splenic flexor was mobilized. Rectal dissection with TME technique was performed using monopolar coagulation. Rectal separation was done using endo-stapler. The rectum was removed from abdomen through the same left paraumbilical wound. End to end anastomosis was created using circular stapler. Operation was smoothly done without any complication.

Laparoscopic Gastrectomy with D2 Lymph Node Dissection for Gastric Adenocarcinoma

Saipan Khunpugdee, Hathaiwan Mounthard, Wutthi

Sametchotimaytha, Thiravud Khuhaprema

National Cancer Institute Bangkok, Thailand

Background: Indications for laparoscopic gastrectomy (LG) for early gastric cancer has gained acceptance and spread worldwide over the last decade. However, its role for advanced gastric cancer remains unclear. Recent study from Japan¹, which showed LG have a safe postoperative course and benefit oncologic outcomes, comprised 231 patients who underwent LG from August 2001 to December 2011. Of 231 patients, only 7 patients had locally advanced gastric cancer or stage III, according to UICC. The study from USA², which showed that laparoscopic gastrectomy for gastric cancer is feasible and safe and can be performed in patients with excellent surgical and oncologic outcomes. The study had stage III patients only 7 patients in total 65 patients underwent LG between June 2005 and August 2011. The study about safety of laparoscopic gastrectomy for locally advanced gastric cancer came from Canada³. This study compared 21 patients underwent LG with 182 open gastric resection, both had stage III patients about 52% and suggests that laparoscopic gastrectomy is an oncologically safe procedure for advanced gastric cancer with outcomes similar to those for open resection.

Objectives: Laparoscopic gastrectomy with D2 lymph node dissection for gastric cancer is emerging in NCI Thailand few years as an investigational procedure which offers benefits for patients. We present step by step for D2 lymph node dissection in totally laparoscopic distal gastrectomy for distal gastric cancer patient to show the technical feasibility, oncological efficacy and surgically safe technique.

Materials & Methods: A 39-year-old Female with positive stool occult blood was sent for gastro-colonoscopy and found antral gastric cancer. She underwent laparoscopic distal gastrectomy with D2 lymph node dissection.

Result: She had no perioperative complication. On 1st postoperative day, she began ambulate and all catheters were removed after 24 hour. Oral liquid diet began on 2nd postoperative day and step up next day. Parenteral fluid was unnecessary in 4th PO day.

Conclusion: Laparoscopic gastrectomy is technically feasibility and safe technique for advanced gastric cancer. Benefits of decreased postoperative complications with decreased length of rehabilitation and hospital stay make LG a preferable approach for resectable gastric cancer.

- 1: Nobuhisa Matsuhashi, et al. Oncologic outcomes of laparoscopic gastrectomy: a single-center safety and feasibility study. *SurgEndosc* (2013) 27:1973-1979
- 2: A.K. Arrington, et al. Laparoscopic Gastrectomy for Gastric Adenocarcinoma: A Single Institution's Experience and Oncologic Outcome of 65 Consecutive Patients
- 3: S.J. MacLellan, et al. Laparoscopic gastrectomy for patients with advanced gastric cancer produces oncologic outcomes similar to those for open resection. *SurgEndosc* (21 Feb 2012)

Posterior Approach Ventral Rectopexy, Alternative Approach for Treatment Rectal Prolapse with Pelvic Floor Descent

Narain Santikulanont, Songphol Malakon

Colorectal surgery, chulalongkorn university

Background: Nowadays, laparoscopic ventral rectopexy (LVR) becomes popular for rectal prolapse treatment with pelvic floor descent because of its low recurrent rate (3.66%). However, LVR is limited for surgery under general anesthesia in the high risk patient. The aim of this VDO is to show technique of this procedure in patient treated with surgery under spinal anesthesia.

Objective: To show the technique of Posterior approach ventral rectopexy for rectal prolapse treatment with pelvic floor descent.

Material and Method: A case of 64-year-old Thai women who had rectal prolapse with pelvic floor descent with incontinent symptoms was diagnosed by physical examination. We present “Posterior approach ventral rectopexy”, an alternative approach for treatment of rectal prolapse with pelvic floor descent.

Result: The patient was discharged with no perioperative recurrence and improvement of incontinence symptoms. There was no recurrence on follow-up for three months.

Conclusion: Posterior approach ventral rectopexy is feasible and safe for rectal prolapse treatment.

Colonic Lengthening for Low Rectal Anastomosis

Waranyu Jiramarit, Songphol Malakorn, Jirawat Pattana-arun

Division of Colorectal surgery, department of surgery, Faculty of medicine, Chulalongkorn university, Bangkok, Thailand

Background: Lengthening of the colon for tension-free low rectal anastomosis comprises ligation of the inferior mesenteric vessels and splenic flexor mobilization. The aim of this video is to demonstrate technique and evaluate the length gained after each level of mesenteric vessel ligation with or without splenic flexor mobilization.

Objectives: This video shows tips and technique for lengthening the colon for low rectal anastomosis.

Methods: The video shows each mobilization technique, that is, low ligation of the inferior mesenteric artery (IMA), high ligation of IMA, high ligation of inferior mesenteric vein (IMV) and mobilization of splenic flexor. The length of colon was measured after each step.

Results: The distance of the rectosigmoid junction and sigmoidodescending junction to the pubic symphysis was measured after each mobilization technique. The elongation of the colon after left side mobilization was 0, 3 cm gained, after low ligation of IMA was 19, 4 cm gained, after high ligation of IMA was 23.5, 4 cm gained, after high ligation of IMV was 26, 4 cm gained, after splenic flexor mobilization was 42, 19 gained

Conclusion: The left side mobilization, low ligation of inferior mesenteric vessels, high ligation of IMA and IMV, splenic flexor mobilization are the effective technique for lengthen the colon and result in good blood supply

Emergency Hemorrhoidectomy in Prolapse Circumferential Thrombosed Hemorrhoid

Chanchai Suwannakij, Songphol Malakon

Colorectal Division, King Chulalongkorn Memorial Hospital, Bangkok, Thailand

Background: Prolapse circumferential thrombosed hemorrhoid can cause severe disabling pain, bleeding or even infection. There are two different ways to manage this condition : conservative treatment or emergency hemorrhoidectomy

Our study shows no difference in complication such as post operative bleeding and wound dehiscence between emergency and elective hemorrhoidectomy. In addition, emergency group has advantages than conservative group such as lower pain score, shorter hospital stay, only one admission (30-40% of conservative group will re-admit for hemorrhoidectomy)

Objective: This video shows our tips and techniques of emergency hemorrhoidectomy in prolapse circumferential thrombosed hemorrhoid

Method: The patient was in prone Jackknife position. Local perianal anesthesia with 0.5%xylocaine with adrenaline 40 ml was gradually injected at 3, 6, 9 and 12 o'clock, 10 ml each. Digital massage was done at the hemorrhoidal tissue to decrease edema then the actual size of the hemorrhoidal tissue that have to excise will be clearly seen. Shaftless Fansler's proctoscope, 3.2 cm diameter, was inserted. Hemorrhoidal tissue was excised with metzenbaum scissors, started perianally till just above hemorrhoidal plexus. Every wound was completely dried before approximation with 4-0 Vicryl Rapide in continuous fasion

The two advantages of this technique are : 1) The internal sphincter is safe from iatrogenic injury because the larger size proctoscope can stretch the sphincter from redundant hemorrhoidal cushion, let the dissection plane always superficial to it. ; 2) To provide good approximation, only the appropriate amount of hemorrhoidal tissue would be removed through this limited working channel, which can prevent dehiscence and stricture finally.

Results: From June 1st 1998 to May 31st 2003, there were fifty-eight cases of acute prolapsed thrombosed hemorrhoid who underwent emergency hemorrhoidectomy. At two weeks, the patients had neither bleeding nor wound infection, but one case of thrombosis (1.72%) and seven minor perianal dehiscence (12.07%). At four weeks, no bleeding or infection were found. Compare with elective hemorrhoidectomy group, there was no statistic difference in complication between the two groups

Conclusion: Emergency hemorrhoidectomy show good result in treatment of prolapsed circumferential thrombosed hemorrhoid

Single Glove Port Laparoscopic Hartmann's Reversal Via Colostomy Wound : The Real Advantage of Single Port in Colorectal Surgery

Songphol Malakorn, MD.

Colorectal division, Department of surgery Chulalongkorn University Bangkok, Thailand

Background: Hartmann's reversal is a very challenge procedure with wide range of difficulty. Most of the times these group of patients have had multiple previous surgeries or previous serious surgical complications and hostile abdomen. In these situations the Hartmann's reversal procedure is even more challenge. Recently, the single port laparoscopic surgery has became one of the surgical options in colorectal surgery. In our experience using single glove port for laparoscopic Hartmann's reversal has many advantages such as avoiding the laparotomy through the complicate previous surgical wound in hostile abdomen, thus minimize the rate of internal organ injury and wound complication. Moreover, using glove port is very cost effective without compromising the degree of freedom of the laparoscopic instruments.

Objective: This video shows the tips and technique of single glove port laparoscopic Hartmann's reversal via colostomy wound.

Methods: 12 patients with previous Hartmann's procedure were performed the single glove port laparoscopic Hartmann's reversal via colostomy wound. First step, the end colostomy was dissected apart from the abdominal wall, the bowel lumen was closed by continuous suture then put the colon back into the abdominal cavity. The single glove port was inserted into the colostomy wound. The laparoscopic lysis adhesion and splenic flexure takedown was done. 150 cc. of normal saline solution was instilled into the anus to facilitate the identification of the distal stump. Then the anastomosis was done by hand-sawn or circular staple depend on the length of the distal stump. The abdominal wall was closed layer by layer. The skin was closed by purse string suture technique.

Results: Ten patients were accomplished by this procedure. One patient have to had one additional 5 mm. port and one patient was converted to laparotomy due to severe adhesion in pelvic cavity. The internal organ injury and wound complication rate were 0%

Conclusion: Single glove port laparoscopic Hartmann's reversal via colostomy wound is feasible with many advantages in selected patients.

The Modified Sugarbaker Technique: Novel Technique in Laparoscopic Parastomal Hernia Repair

***Pakkavuth Chanswangphuvana, Soravith Vijitpornkul,
Ajjana Techagumpuch, Suppa-ut Pungpapong, Chadin Tharavej,
Patpong Navicharern, Suthep Udomsawaengsup***

Department of Surgery, King Chulalongkorn Memorial Hospital, Bangkok, Thailand

Introduction: Parastomal hernia is a common surgical complication following stomal formation, representing a challenging problem to surgeons. At least three approaches for parastomal hernia repair have been described: fascial suture repair, relocation of stoma and local repair with mesh. As the field of laparoscopic surgery advances, different laparoscopic techniques for parastomal hernia repair have been developed. Fascial suture repair only open techniques have been described with benefit in improving abdominal wall physiology. The Sugarbaker technique has been reported to have low recurrence with both open and laparoscopic technique. We propose the modified Sugarbaker technique, a novel technique as another option for parastomal hernia repair. This technique includes laparoscopic intraperitoneal on-lay mesh and fascial suture repair.

Objective: To evaluate the safety of this technique.

Methods: The modified Sugarbaker technique was performed from November 2012 to June 2013 in King Chulalongkorn Memorial Hospital. Fascial suture laparoscopic repair is done with the use of Crochet hook needle. The data were collected and reported.

Results: Our patients, after repaired by the modified Sugarbaker technique, had controllable pain and no postoperative complication. They also had early discharge from hospital. Short-term follow-up with patients showed no evidence of recurrence.

Conclusion: Laparoscopic repair with the modified Sugarbaker technique is safe and technically feasible.

The Karydakis Operation, How I Do It?

ChinavonChivaratanond, JirawatPattana-arun

Department of Surgery, King Chulalongkorn Memorial Hospital, Bangkok, Thailand

Introduction: Complex pilonidal sinus is a rare disease of Thai population but still can be found in patients with hirsute and obese group. Karydakis operation is the treatment of choice of recurrent complex pilonidal sinus with the best outcome (high success rate with low complication and recurrent rate). Due to the limited number of cases, some surgeons may not be familiar with this operation. This video presentation showed the details and technical tips of Karydakis operation in the form of Doctor Jirawat Pattana-arun's practice which has already been updated and modified to be simple and practical.

Objective: To show the Karydakis operative technique in the VDO presentation format.

Methods: A case of Thai male, 30-year-old presented with recurrent complex pilonidal sinus. This video showed the modified Karydakis operation which excising all of sinus tract together with skin flap reconstruction. To make the off-midline wound together with decreasing of skin tension, we divided skin flap into 2 layers for reconstruction that can make the skin closure easier. After the operation, the patient was followed up at 2 weeks, 1,3 and 6 months.

Results: After 2 weeks, the wound was healed without complication. And at 6-month follow-up, there was no recurrence.

Conclusion: From the past to present, Karydakis operation is used as the treatment of choice for recurrent complex pilonidal sinus. Most textbooks inform only the principle and a rough detail of the operation. Karydakis operation technique is still being interpreted and developed in order to improve the method and get the better result.