

Abstracts of the 35th Annual Scientific Meeting of the Royal College of Surgeons of Thailand, 25-28 July 2010, Ambassador City Jontien Hotel, Jomtien, Pattaya, Chonburi, Thailand (Part 1)

BREAST SURGERY

RETRO-MAMMARY ENDOSCOPIC APPROACH FOR REMOVAL OF BENIGN BREAST LUMP

Youwanush Kongdan, Chairat Supsamutchai, Yodying Wasutit, Kampol Ratchaworapong, Phatarachate Klaiklern, Monchai Leesombatpaiboon, Prasakit Chirappapha

Department of Surgery, Faculty of Medicine Ramathibodi Hospital, Mahidol University, Bangkok, Thailand

Background: Benign breast lump proven by triple assessment should be removed if the size is larger than 2 centimeters. Removal of tumor in some location may result in poor cosmetic outcome from surgical scar and loss of skin integrity. The tumor located in deeper area requires a wider incision for good exposure. In the past, endoscopic surgery has been used in breast surgery to remove benign mass with good cosmetic outcome.

Methods: The patients who were diagnosed fibroadenoma were selected to undergo endoscopic removal via retro-mammary route. Data of operation were recorded at the time of surgery. Complications and outcomes were recorded at the time of follow up. The cosmetic result was evaluation by patients and another surgeon in the Breast Unit.

Results: Endoscopic removal of benign breast lump has excellent cosmetic result, minimal or no pain. There was no immediate complication such as infection, bleeding, wound dehiscence or seroma. Loss of sensation at inner aspect of forearm was observed in some patients. All of patients were satisfied.

Conclusions: Endoscopic removal of benign breast lump provided excellent aesthetic results without complication but more time consuming.

ACASEREPORT:INTRAOPERATIVERADIOOTHERAPY FOR BREAST CANCER RECURRENCE FOLLOWING BREAST CONSERVING THERAPY

Youwanush Kongdan, Phatarachate Klaiklern, Chairat Supsamutchai, Kampol Ratchaworapong, Monchai Leesombatpaiboon, Prasakit Chirappapha

Department of Surgery, Faculty of Medicine Ramathibodi Hospital, Mahidol University, Bangkok, Thailand

Recurrence of breast cancer following breast conserving therapy (BCT) is one of the common problem seen in clinical practice. Re-irradiation therapy is under limitation by tissue tolerance dose of radiation. Intra-operative radiotherapy (IORT) is an option since re-radiation is volume limited and side effect is acceptable. A case of 54 years old Thai female had BCT for 3 years. In that BCT, the cancer pathology was invasive and in situ ductal carcinoma measuring 2.1 cm in diameter. The invasive component was moderately differentiated. All resected margins were free of tumor. The nearest margin was <1 mm at supero-lateral margin. The sentinel lymph node showed no evidence of metastatic carcinoma. The biologic markers were ER (+), PgR (-), HER2/neu (-), P53 (+) and Ki-67 (+) in 15% of tumor cell. Radiation therapy in total dose of 50 Gy. plus boost tumor bed 12 Gy/4F was given after completion of adjuvant chemotherapy. Endocrine therapy with tamoxifen 20 mg. OD was prescribed. On the 3rd year, of regular 6 month follow up, tumor recurrence was found at right parasternal region with invasion to pectoralis muscle. There was no distant organ metastasis. Mastectomy plus resection of underlying Pectoralis muscle was done. IORT with 12.5 Gy at tumor bed was given. Pathological report revealed invasive ductal carcinoma

grade 2, size 2 cm, with free margins, and presence of lymphovascular invasion, ER +ve 85%, PgR +ve 1% HER2/neu (+) 2+, FISH -ve and Ki-67 were positive in 40% of tumor nuclei. Aromatase inhibitor was given for the next 5 years.

SCREENING BREAST CANCER WITH DIGITAL MAMMOGRAM AND ULTRASOUND IN PHYATHAI 2 HOSPITAL

Monchai Leesombatpaiboon^{1,2}, Youwanush Kongdan^{1,2}, Kampol Ratchaworapong², Prakasit Chirappapha², Phhatarachate Klaiklern²

¹Breast Care Center, Phyathai 2 Hospital, Bangkok, Thailand

²Department of Surgery, Faculty of Medicine Ramathibodi Hospital, Mahidol University, Bangkok, Thailand

Background: Breast cancer is the most common cancer in Thai woman especially in Bangkok. Early detection can decrease breast cancer mortality. Several large studies show that breast cancer screening with mammogram reduces the number of death from breast cancer for woman ages 40 to 69 especially for those over age 50. Screening with digital mammogram plus ultrasonography are widely used in Thailand to detect an early stage cancer.

Patient and Methods: This study is retrospective descriptive study. All of average risk women who have screening for breast cancer at Breast care center, Phyathai 2 hospital during January 2009 - December 2009 were reviewed. The symptomatic breast patients were excluded.

Results: Records of 3,840 screening women were reviewed. The most frequent age groups were 40-49 years old and 50-59 years old respectively (44.8%, 22%). There were 92 patients (2.6%) for mammogram BIRADS 4 and 5 (86 and 6 patients) and only half of this group followed the recommendation for tissue diagnostic procedure. For BIRADS 5, 57% were in 50-59 years old and 43% were in 40-49 years old. For BIRADS 4, mostly also were in 40-49 years old and 50-59 years old respectively (29%, 17%). Breast cancer diagnosis proven by core needle biopsy, accounted for 0.18% of screening woman. All of them were in stage I. Most of them were in 50-59 years old (57%). For imaging BIRADS 4 and 5, were divided into 3 groups: detected by mammogram only 33%, by ultrasound only 33% and by mammogram and ultrasound 34%.

Conclusion: Screening digital mammogram plus ultrasonography is likely to benefit in the age 40 years old upward, particularly for those over age 50. However, only half of patient who received biopsy is a limitation of this study. In Thai women, adding ultrasound to screening mammogram can increased detection rate of about 33%.

EVALUATION OF TUMOR CELLS IN AFFERENT LYMPHATIC TRACT OF SENTINEL LYMPH NODE IN BREAST CANCER PATIENTS

Kampol Ratchaworapong¹, Youwanuch Kongdan¹, Sansanee Wongwaisayawan², Prakasit Chirappapha¹, Panuwat Lertsithichai¹, Ronnarat Suwikapakornkul¹, Yodying Wasutit¹

¹Department of Surgery, ²Department of Pathology, Faculty of Medicine Ramathibodi Hospital, Bangkok, Thailand

Background: Micro- or macro-metastasis in sentinel lymph node (SLN) biopsy is an indication for axillary lymph node dissection in breast cancer patients. The technique disregards whether there are tumor cells in the afferent lymphatic tracts of sentinel nodes or not. The presence of tumor cells in the afferent tract of a negative SLN may imply that axillary management is needed.

Objective: To identify tumor cells in the afferent lymphatic tract of SLNs in breast cancer patients.

Materials & Methods: We performed a prospective study of 100 breast cancer patients who underwent SLN biopsy in the Breast and Endocrine Unit at Ramathibodi hospital between June 2009 and January 2010. The afferent lymphatic tracts of SLNs and the SLNs were identified by isosulfan blue dye and/or radioisotopes and were submitted for pathological study.

Results: Three patients had bilateral breast cancer. Overall, 103 SLNs and their afferent lymphatic tracts were examined. The mean age of patients was 52.4 yrs (range, 24-78 yrs). The average number of SLNs was 2.3 (range, 1-7). Positive SLNs were seen in 24 patients (24%). Most patients had stage I breast cancer (67%). The main histologic type was invasive ductal carcinoma (78.6%). Three patients with positive SLN were found to have tumor cells (Isolated tumor cells) in the afferent tract tissue. There were no tumor cells in the afferent tracts of negative SLNs.

Conclusion: Most of positive-SLN patients and all negative-SLN patients had no tumor cells in the afferent tracts of SLNs. Examination of sentinel nodes is probably sufficient for evaluating axillary metastasis. The presence of tumor cells in the afferent lymphatic tract or soft tissues may suggest that the breast cancer is more aggressive.

PROGNOSTIC FACTORS DETERMINING PATIENT WITH TRIPLE-NEGATIVE BREAST CANCER IN SONGKLANAGARIND HOSPITAL

Pongtrip Unprasert, Puttisak Puttawibul, Rassamee Sangthong
Prince of Songkla University

Background: Triple-negative breast cancer (estrogen

receptor-negative, progesterone receptor-negative, and HER2-negative) is a high risk breast cancer due to their aggressive behavior and high recurrence nature.

Objective: To determine the clinical features and prognostic factors of triple-negative breast cancer in Songklanagarind Hospital.

Materials and Methods: We retrospectively study patients with triple-negative breast cancer between 1st September 2006 to 31st August 2009. Then characterize this subgroup of breast cancer and determine prognostic factors that can predict the recurrence of this aggressive behavior tumor.

Results: Eighty (80) patients had triple negative phenotype. The majority characteristics of these tumors were found in younger women who came with breast mass

which are mostly detected by physical examination. Most tumors were of grade 3, invasive intraductal carcinoma. However, only the lymphovascular invasion has shown statistic significance in cases with recurrence. Other parameters including age, histological grade, tumor size, invasion ductal component or other factors included in the current study were not significant.

Conclusions: This study concluded that assessment of characteristic of these tumors, histological study in addition to the established pathologic variables, mainly lymphovascular invasion status can be used to predict high-risk of recurrence at the time of primary surgery and can provide valuable information on treatment options in patients with triple-negative breast cancer.

CARDIOVASCULAR & THORACIC DISEASES

SUCCESSFUL TRANSLOCATION OF ABERRANT RIGHT SUBCLAVIAN ARTERY IN CHILDHOOD BY SUPRACLAVICULAR APPROACH: REPORT OF AN UNCOMMON CASE

Piya Samankatiwa, Schwannuch Reungsri

Division of Cardiothoracic Surgery, Department of Surgery, Faculty of Medicine Ramathibodi Hospital, Mahidol University, Bangkok, Thailand

Background: Dysphagia lusoria caused by an aberrant right subclavian artery is uncommon although the abnormal origin of the vessel is the commonest anomaly of the aortic arch. The mechanism of difficulty in swallowing is the abnormal origin and course of the right subclavian artery that loops around the posterior aspect of the oesophagus and compresses the oesophagus against the trachea. As a result of insidious onset and bizarre behavior, patients with this condition usually present late in adulthood. This unusual cause of deglutition disorder is therefore deliberately managed by surgery. However, surgical approach is different between adult and children. The childhood patient should be managed via a thoracotomy incision while in the adult via the supraclavicular one. We report our experience in managing this disorder in a 6-year-old patient against general recommendation, through the supraclavicular approach instead of the thoracotomy. We also depict the surgical technique used in this patient.

Methods: A 6-year-old girl was referred to our institution due to a deglutition problem for 2 years. The patient had worse symptoms with solid food and gained weight poorly. She experienced several medical treatments

but none of them were successful. An oesophagography was performed and demonstrated a posterior indentation on the thoracic oesophagus at the level of the aortic arch. Furthermore, a computerized tomography of the chest revealed an abnormal origin of the right subclavian artery from the distal aortic arch. The patient was diagnosed with “aberrant right subclavian artery”. The supraclavicular approach was selected and the abnormal right subclavian was successfully divided at its origin. Postoperatively, the symptom was relieved immediately.

Conclusion: Although it is widely advised that surgery should be performed via the thoracotomy incision for children, we considered that it can be managed successfully and safely using the supraclavicular approach. Moreover, this approach can alleviate adverse effects of thoracotomy.

MITRAL VALVE REPAIR FOR RHEUMATIC MITRAL REGURGITATION: MID-TERM RESULTS

Somchai Waikittipong

Department of Surgery, Yala Hospital, Yala, Thailand

Background: Mitral valve repair is considered to be the procedure of choice for mitral regurgitation whenever feasible. But for rheumatic patients, the long term results are not as good as non-rheumatic patients.

Objectives: To evaluate the mid-term results of mitral valve repair for rheumatic mitral regurgitation.

Patients and Methods: Between January 2003 and December 2009, 56 patients with rheumatic mitral

regurgitation underwent mitral valve repair. There were 12 males and 44 females. Ages ranged from 10 to 51 years (mean 20 ± 10). 39.3% were in Functional Class 3 or 4. 19.6% have atrial fibrillation. 78.6% have mitral regurgitation grade 3 or 4 by echocardiographic examination. The mechanism of mitral regurgitation according to Carpentier's classification were as follow: type one 6, type two 16, type three B 21, and type two-three B 13. The pathology of mitral regurgitation were as follow: Posterior mitral leaflet restriction 36, elongated chordae 33, ruptured chordae 4, and commissural fusion 4. The numbers of lesions per patient ranged from 1 to 5 (mean 2.3 ± 0.7). The reparative techniques performed were as follows: resection of secondary chordae of posterior mitral leaflet 34, chordal shortening 4, chordal transfer 5, chordal replacement 9, commissurotomy 4, commissuroplasty 3, leaflet placcation 11, and leaflet resection 1. All patients received ring insertion. The numbers of reparative techniques performed per patient ranged from 1 to 5 (mean 2.2 ± 0.9)

Results: There was no hospital mortality or serious complication. Post-operative echocardiogram showed no mitral regurgitation in 43 patients, and MR grade one in 13 patients. Follow-up was complete for all patients, ranging from 3 to 87 months (mean 40 ± 23). There were late death in 3 patients, giving that survival rate at 4 years was 90.9%. There were 3 re-operations, giving that freedom from reoperation at 2 years was 93.7%. There were 8 patients with MR grade two or three, giving that freedom from progression of MR at 2 years was 78.3%.

Conclusion: Mid-term results of mitral valve repair for rheumatic mitral regurgitation was encouraging but long-term results still have to be determined.

NORMAL SIZE OF THE THORACIC AORTA IN THAI POPULATION

Samrit Attasiriluk¹, Worawong Slisatkorn¹,
Thanongchai Siriapisith², Pansak Laksanabunsong²

¹Division of Cardiothoracic Surgery, Department of Surgery; ²Department of Radiology, Faculty of Medicine, Siriraj Hospital, Mahidol University, Bangkok, Thailand.

Objective: To study average diameters of normal thoracic aorta in Thai population.

Methods: Eight levels of aortic diameters were collected from 100 adult patients who underwent a thoracic helical CT scan for various non-aortic diseases. Two perpendicular diameters were measured. Mean, minimal, maximal and standard deviation (SD) of all data were analyzed.

Results: There were 51 males, and 49 females. Mean

age was 57.7 years (range 18-92). Average aortic diameter (mean \pm SD) was 28.55 ± 5.16 mm at aortic annulus, 34.63 ± 4.74 mm at aortic sinus, 33.62 ± 5.07 mm at ascending aorta, 32.43 ± 4.62 mm at proximal to innominate artery level, 30.68 ± 4.27 mm at left common carotid taking off level, 28.77 ± 3.94 mm at left subclavian taking off level, 27.59 ± 4.02 mm at descending aorta just distal to left subclavian artery level, and 23.28 ± 3.65 mm at diaphragmatic level. Male aortic diameters are larger than female's. Aortic diameters increased with age in all levels.

Conclusion: Average thoracic aortic diameters in Thai population were proposed. Sex, age and various aortic levels determine size of the thoracic aorta.

SURGERY FOR ACUTE CORONARY SYNDROME: FACTORS INFLUENCING OUTCOME

Permyos Ruengsakulrach¹, Kitipan V Arom¹,
Prachueb Sirivongrungron¹, Damras Tresukosol²,
Kriengkrai Hengrussamee³

¹Bangkok Heart Hospital, Bangkok 10320, Thailand

²Siriraj Hospital, Mahidol University, Bangkok 10700, Thailand

³Chest Disease Institute, Nonthaburi 11000, Thailand

Background: Acute coronary syndromes (ACS), ranging from unstable angina and acute myocardial infarction (AMI) without ST-segment elevation (NSTEMI) up to evolving acute myocardial infarction (AMI) with persistent ST-segment elevation (STEMI), offer a challenge from the standpoint of diagnosis, treatment, and prognosis, because the clinical manifestations vary considerably. Treatment of ACS has undergone great evolution since introduction of percutaneous coronary intervention (PCI). The objective was therefore to assess the outcome of patients with acute coronary syndrome undergoing surgical revascularization with coronary artery bypass grafting (CABG).

Materials and Methods: From 2007 to 2009, two thousand and nine patients were enrolled in the Thai Registry in Acute Coronary Syndrome (TRACS). Sixty two patients underwent CABG. There were 14 unstable angina, 29 NSTEMI and 19 STEMI. Both elective (52 patients) and emergency (10 patients) operations were included. The mean age was 65.33 ± 11.46 years with 45 males (72.6%). Forty patients (64.5%) had diabetes and 44 patients (71%) had hypertension. The most common location of MI was lateral wall. Nine patients (14.5%) presented with cardiogenic shock. One patient (1.6%) was post cardiac arrest and 23 patients (37.1%) had preoperative heart failure. Seven patients (11.3%) had previous PCI. The preoperative CPK-MB and troponin T/I levels were 1.3-

176.2 ng/ml and 0.01-8.73/0.20-43.19 ng/ml respectively. The preoperative left ventricular ejection fraction was $46.10 \pm 16.07\%$.

Results: The time between the onset of acute coronary syndrome and CABG was within 24 hours in 5 patients (8.1%), 1 to 3 days in 9 patients (14.5%), 4 to 7 days in 15 patients (24.2%), and 8 to 14 days in 33 patients (53.2%). Eight (12.9%) was failed PCI and 5 (8.1%) had thrombolytic before CABG. Overall in-hospital mortality was 6.45% (4/62). Morbidity was found in 58% (36/62) including congestive heart failure 51.6% (32/62) and bleeding complication 6.5% (4/62). There was a significant association between mortality and patient with age ≥ 75 years ($P < 0.002$). However age, gender, shock, congestive heart failure, diabetes, hypertension, left ventricular ejection fraction, failed PCI and time between the onset of acute coronary syndrome and CABG did not influence death outcome and postoperative congestive heart failure by multivariate logistic regression analysis.

Conclusion: CABG in acute coronary syndrome can be performed with acceptable risk by incorporating adequate management strategies. Care should be taken for CABG in ACS in elderly patients.

REVERSED REMODELING OF THE LEFT VENTRICLE AFTER DIRECT INTRAMYOCARDIAL ANGIOGENIC CELL PRECURSORS INJECTION IN PATIENT WITH MYOCARDIAL INFARCTION

Permyos Ruengsakulrach, Kitipan V. Arom, Lertlak Chaothawee
Bangkok Heart Hospital, Bangkok, Thailand

Objectives: To investigate the effects of intramyocardial angiogenic cell precursors (ACPs) injection on left ventricular (LV) size and function in patients with prior myocardial infarction.

Methods: Twenty five consecutive patients with previous myocardial infarction who had completed follow up were studied. Mean age was 59.0 ± 12.6 years, 24 were male and 17 were in the NYHA Class III and IV. Seventy six percent had left ventricular ejection fraction (LVEF) less than 40%. Ten had ACPs injection alone and 15 had combined CABG plus ACPs injection. The ACPs were isolated and cultured from the patient's own blood. The number of cells prior to injection was 41.4 ± 43.3 million cells. Cells were injected into non-viable myocardium and hypokinetic segments via microthoracotomy, or median sternotomy with CABG. All were examined by cardiac magnetic resonance imaging (CMR) with gadolinium contrast in preoperative and postoperative periods, assessing LV dimensions and function. The interval of follow-up was

11.6 ± 1.2 months.

Results: Decreases in LV end-diastolic and LV end-systolic volume were found (31.2 ± 62.5 ml, $P = 0.026$ and 31.0 ± 52.4 ml, $P = 0.01$, respectively), whereas infarction volume decreased (10.3 ± 22.7 , $P = 0.046$). No significant changes were seen regarding LVEF, stroke volume, cardiac output and LV mass index (Table 1).

Table 1 Preoperative and Postoperative CMR Parameters

CMR parameters	Preop	Postop	P Value
Infarction Volume (%)	35.6 ± 28.6	25.3 ± 21.1	0.046
End-Diastolic Volume (ml)	248.8 ± 76.6	217.6 ± 77.3	0.026
End-Systolic Volume (ml)	183.4 ± 84.3	152.5 ± 78.2	0.010
Ejection Fraction (%)	29.0 ± 16.5	33.3 ± 16.4	0.064
Stroke Volume (ml)	64.5 ± 27.0	65.1 ± 26.4	0.894
Cardiac Output (L/min)	4.6 ± 1.7	4.3 ± 1.7	0.545
LV mass (g)	158.4 ± 42.2	162.8 ± 37.8	0.472

Conclusions: Intramyocardial ACPs injection could prevent remodeling effects on the LV in prior myocardial infarction patients. Infarction volume, end-diastolic and end-systolic LV volume were significantly reduced. The LVEF was improved but not statistically significant. Further investigation of this novel use of intramyocardial ACPs injection is warranted.

AORTIC VALVE-SPARING OPERATION FOR AORTIC ROOT ANEURYSM: SIRIRAJ EXPERIENCE

Worawong Slisathorn, Wanchai Wongkornrat, Somchai Sriyoschati, Pansak Laksanabunsong

Division of Cardiothoracic Surgery, Department of Surgery, Faculty of Medicine Siriraj Hospital, Mahidol University, Bangkok, Thailand.

Background: Aortic valve-sparing operation offers an opportunity to save the native normal valve for patients who require surgery for aortic root aneurysm. This avoids life-long anticoagulant after aortic root replacement with a composite graft-mechanical valve conduit. The objective of this study is to examine results of aortic valve-sparing operation by reimplantation technique in aortic root aneurysm.

Methods: From July 2007 to May 2010, 13 aortic root aneurysm patients were operated with aortic valve-sparing operation by reimplantation technique. Perioperative data and postoperative echocardiography studies were reviewed and analyzed.

Results: There were 8 males and 5 females. Their mean age was 48.8 years (range 35-71 years). Three patients were diagnosed Marfan syndrome and other three were in clinically suspicious Marfan. All patients had preoperative aortic regurgitation (AR) (2 mild, 2 moderate and 9 severe AR). Three patients were in New York Heart Association functional class I, 5 in class II and 5 in class III.

Four patients had aortic cusp repair, 3 patients had arch replacement, 2 patients had coronary artery bypass and one had mitral valve repair. Mean cardiopulmonary bypass time was 235 minutes (207- 329 minutes) and mean aortic clamp time was 205.7 minutes (145-251 minutes). Six patients were operated under hypothermia with circulatory arrest. Mean hospital stay was 10.2 days (7-17 days) and mean ICU stay was 35 hours (10-78 hours). No hospital mortality, stroke, and reoperative bleeding was found. Intraoperative transesophageal echocardiography showed mild AR or less in 11 patients and mild to moderate AR in 2 patients. Mean follow up time was 14.6 months. Eleven patients were in NYHA functional class I and 2 were in functional class II. Postoperative transthoracic echocardiography revealed mild AR or less in 9 patients and moderate AR in 4 patients.

Conclusions: Aortic valve-sparing with reimplantation technique for aortic root aneurysm showed a good short-term outcome in both Marfan and non-Marfan patients without early and late mortality.

MANAGEMENT OF MEDIASTINAL TERATOMA IN A NEONATE WITH ACUTE RESPIRATORY FAILURE

Jarun Sayasathid¹, Naraporn Somboonna²,
Siraphop Thapmaogkol¹, Yuthapong Buddharadsa¹,
Kanchapan Sukonphan³

¹Cardiac Center, Naresuan University Hospital, Phitsanulok 65000, Thailand; ²Department of Microbiology, Faculty of Science, Chulalongkorn University, Bangkok 10330, Thailand; ³Department of Obstetrics and Gynecology, Buddhachinaraj Hospital, Phitsanulok 65000, Thailand

Background: While teratomas account for the leading cause of germ cell tumors, the mediastinal teratomas represent one of the infrequent types of congenital germ cell tumors. Neonates with large mediastinal teratomas generally show severe respiratory distress, and the immediate surgical treatment is needed to alleviate their problems.

Objectives: To describe clinical symptoms, diagnostic procedures, treatment option, and outcomes after the treatment for a neonate with a large mediastinal teratoma.

Methods: This is a case report of a 2-day-old female infant presenting with acute respiratory failure and diagnosed as mediastinal teratoma followed with surgical treatment. The removed tissues were pathologically examined.

Results: The girl suffered an acute respiratory failure since day two after birth. The chest radiography, echocardiography and chest computerized tomography results specified a considerable size of mediastinal teratoma. Median sternotomy was performed on the third day of

infant life to confiscate the tumor without rupture of capsule. Pathological diagnosis was germ cell tumor. Clinical follow-ups reported no complication.

Conclusion: Immediate detection and proper treatment of a large mediastinal teratoma in neonate was exceedingly important to reduce morbidity and mortality of the infant. The successful management of such a case was presented.

VIDEO-ASSISTED THORACOSCOPIC THYMECTOMY VS TRANSSTERNAL THYMECTOMY FOR MYASTHENIA GRAVIS: SURGICAL OUTCOME

Wittawas Phetphaisit, Pranya Sakiyalak,
Punnarerk Thongcharoen, Thaworn Subtaweesin,
Pansak Laksanabunsong

Department of Surgery, Faculty of Medicine Siriraj Hospital, Mahidol University, Bangkok, Thailand

Background: Thymectomy is recommended as an option to increase the probability of symptomatic improvement in myasthenia gravis. The thoracoscopic approach to thymectomy improves cosmetic result with shorter recovery period. We compared outcomes of the transsternal thymectomy and VATS thymectomy.

Methods: Between January 2004 and January 2008, 59 thymectomies were performed for myasthenia gravis; 28 by VATS and 31 by transsternal approach. Preoperative classification and postoperative disease status were compared between the groups.

Results: Mean age was 36.6 (VATS) versus 40.0 years (transsternal) ($p = 0.342$). The proportion of male/female was 2/26 versus 5/26 ($p = 0.311$) and preoperative duration of myasthenia gravis was 15.9 versus 17.4 months ($p = 0.76$), respectively. Mean of clinical follow up was 15.1 versus 25.4 months ($p = 0.003$). In VATS group, no patient required conversion to transsternal approach. No patient needed postoperative ventilation in both approach groups. Mean length of stay was 3.8 versus 5.2 days ($p = 0.043$). There were no significant difference in pre and postoperative medication for control of myasthenia gravis (MG). Thymomas were found in 7.1% of VATS versus 16.1% of transsternal patients ($p = 0.72$). No myasthenia gravis related deaths occurred with 61% of the VATS and 71% of the transsternal patients ($p = 0.57$) were either in complete remission or no medication requirements, asymptomatic, decreased medication requirements, improvement in symptoms.

Conclusions: VATS thymectomy is an effective treatment in myasthenia gravis patients with decrease hospital stay and equivalent clinical outcomes obtained by either approach.

THORACOABDOMINAL AORTIC ANEURYSM EXCLUSION

*Somchai Sriyoschati, Teeravit Phanchaipetch,
Worawong Slisatkorn, Wanchai Wongkornrat*

Division of Cardiothoracic Surgery, Department of Surgery, Faculty of Medicine Siriraj Hospital, Mahidol University, Bangkok, Thailand.

Background: Descending thoracic aortic interruption just above the diaphragm with descending thoracic aorta to left femoral artery bypass is an alternative procedure which acts like the treatment of type I endoleak and at the same time can decrease the systemic blood pressure by lowering systemic vascular resistance.

Methods: We performed this procedure in a 60 years old man with threatened rupture of chronic thrombosis of type IV thoracoabdominal aortic aneurysm. He had history of type IV thoracoabdominal aortic thrombosis for 14 years with malignant hypertension since then. He had Bentall operation and CABG performed for 9 years. CTA before surgery revealed 9.8 ± 7.2 cm. thoracoabdominal thrombosis with leakage of contrast from the native proximal luminal flow and multiple collateral vessels at anterior abdominal wall.

Results: He recovered uneventfully with follow up CTA revealed thrombosis of the threatened rupture aneurysm and much improvement of hypertension.

Conclusions: Aortic inflow interruption with descending thoracic aorta to femoral artery bypass is an alternative treatment for a high surgical risk patient with impending rupture of thrombotic chronic type IV thoracoabdominal aortic aneurysm. However, long-term outcomes of this procedure need to be monitored.

SUCCESSFUL REMOVAL OF INTRAMURAL RIGHT VENTRICULAR TUMOUR USING A SIMPLE EXCISION METHOD: REPORT OF AN UNCOMMON CASE

Piya Samankatiwat, Wichaya Withurawanit

Division of Cardiothoracic Surgery, Department of Surgery, Faculty of Medicine Ramathibodi Hospital, Mahidol University, Bangkok, Thailand

Cardiac tumor is a relatively uncommon condition. The most common cardiac tumor is myxoma which is usually originated in the right atrium. On the other hand, intraventricular cardiac neoplasm is relatively rare. Therefore, there have been only small case reports regarding this type of cardiac tumor. An intramural tumor is even less common. As a result, there has been no standard approach to the removal of the tumor. We report an experience on successful removal of a large intramural ventricular tumor in a 6-year-old child using a simple technique under

cardiopulmonary bypass support. A 6-year-old girl was referred to Ramathibodi Hospital with incidentally detected heart murmur when she had caught a cold. Previously, she was otherwise normal. There was right ventricular heave and systolic ejection murmur at the left parasternal border detected on physical examination. Echocardiography and computerized axial topography of the heart revealed a large mass in the right ventricle causing obstruction to the right ventricular outflow tract (RVOTO). The patient underwent an operation for removing the tumor. The operation was performed under cardiopulmonary bypass support and cardioplegic arrest. The tumor was huge and it was protruded on the anterior surface of the right ventricle and encroached on the right ventricular chamber leading to RVOTO. It was exterminated by simple limited resection technique, in order to preserve the right ventricular function. The patient was well and rapidly recovered. On postoperative echocardiography, there was no residual tumor nor right ventricular outflow tract obstruction. During preparing this abstract, the pathological result has not been finalized. Summarily, our report shows that limited resection is beneficial in terms of preservation of ventricular mass and function in selected cases of large intramural ventricular tumor.

PULMONARY ROOT REPLACEMENT FOR PULMONARY REGURGITATION AFTER COMPLETE REPAIR OF TETRALOGY OF FALLOT

Piya Samankatiwat

Division of Cardiothoracic Surgery, Department of Surgery, Faculty of Medicine Ramathibodi Hospital, Mahidol University, Bangkok, Thailand

Pulmonary regurgitation is the most frequent leading cause of late reoperation after complete repair of tetralogy of Fallot (TOF). This condition is accounted for 10 to 15 per cent of TOF patients undergoing previous complete repair. It is also associated with ventricular dysrhythmia, which subsequently a significant cause of sudden death. The commonly used technique is to replace the pulmonary valve with a pulmonary valve homograft or other conduit, for example stentless porcine xenograft. However, many centers recently have advocated the use of root replacement technique with a pulmonary-homograft-valve conduit. At Ramathibodi Hospital, we have recently started applying this technique to reconstruction the severely regurgitate pulmonary valve for 3 years. Fifteen cases of TOF patient after a previous complete repair have undergone pulmonary root replacement using a pulmonary homograft valve conduit. This video presentation is an example of utilization of this approach.

WARFARIN CLINIC FOR HEART VALVE SURGERY : MULTIDISCIPLINARY TO ACHIEVE OPTIMAL PT-INR

*Suthep Taksinachanekij, Jintawee Chaichun,
Wilaiwan Nuchsri, Supaporn Noimay, Wannapa Hinwisat,
Parada Suttipongpracha*

Queen Sirikit Heart Center of The Northeast, Khon Kaen University,
Khon Kaen, Thailand.

Background: Queen Sirikit Heart Center of the Northeast. Khon Kaen University has established the Warfarin Clinic for heart valve surgery patients in June 2009. The aims are optimal patients care, in the form of multidisciplinary approach to reduce the risk of complications of warfarin therapy and closely monitored with the plan for networks transferring.

Objectives: The purpose of this study was to evaluate the success of the clinic management by (1) Investigating the PT-INR adjust dose value of the patients who underwent valve surgery with anticoagulant warfarin before establishment of the clinic compared with after establishment, (2) The satisfaction of patients who receive the service, and (3) The satisfaction if they were transferred to nearby provincial/local hospitals.

Methods: 1. Setting service team consisting of surgeon, nurse, pharmacist, medical technologist, physical therapist and nutritionist. 2. Taking information and treatment according to care map and clinical practice guideline. 3. Evaluating the performance efficacy by considering the patient satisfaction and frequency of drug monitoring for suitable INR level. 4. Planning for future network development from service evaluation and deployment.

Statistical analysis: Odds ratio is statistically significant at the 5% level ($P < 0.05$).

Results: 1. Adjust the dosage to patients receiving the desired PT-INR level was changed from 65 percent to 30 percent after establishment of the clinic ($p < 0.05$). 2. Patients who receive the new service showed satisfaction over traditional systems over 95 percent. 3. Most patients are reluctant to monitor PT-INR treatment after surgery at the provincial/local hospitals.

Conclusions: 1. Multidisciplinary team for warfarin clinic provided the patients with good information and dosing the INR level were more standardized. 2. Referral system and post operative care should be improved for increasing the patients trust in community hospitals.

COLORECTAL AND ANAL SURGERY

ASSOCIATION BETWEEN PRE-OPERATIVE LYMPH NODE METASTASIS OF COLORECTAL CANCER PATIENTS BY FDG PET/CT SCAN AND FINAL HISTOPATHOLOGY

*Chuathong A¹, Rajchadara S², Banpapong C³,
Ouawathanamongkol S¹, Maipang T¹*

¹Surgical Oncology Unit, ²Nuclear Radiology Unit, Wattanosoth Hospital, Bangkok, Thailand; ³Research Unit, Bangkok Hospital Medical Center, Bangkok, Thailand

Introduction: The latest technology in using positron emission tomography/ computed tomography (PET/CT) is becoming a widely held standard, especially when utilized for surveillance and pre-operative staging in this era. The purpose of this research is to study the association between the diagnostic value of PET/CT scan (maximum standardized uptake value-SUV) for pre-operative lymph nodes status as compared to the result of the final histopathology report.

Patients and Methods: This retrospective study gathered the information from patient medical records at the Bangkok Hospital Medical Center. The patients were

examined for colorectal cancer from May 2007 to November 2009 and received the pre-operative PET/CT scan before having the oncologic colorectal surgery during the time mentioned above. The subjects in this study numbered 30 patients as in Table 1.

Table 1 Demographic data of colorectal cancer patients

Factors	Sample Size = 30	
Sex	Male (20)	Female (10)
Age	46-83 years (mean = 63)	43-99 years (mean = 64.3)
Site of primary tumor		
- Ascending colon	Male (3)	Female (0)
- Transverse colon	Male (2)	Female (0)
- Descending colon	Male (4)	Female (2)
- Sigmoid colon	Male (4)	Female (5)
- Rectum	Male (7)	Female (3)

Interpretation of PET/CT scan The interpretation of PET/CT scan was reviewed by one nuclear medicine professional without knowledge of the details of each patient, including the diagnosis of previous PET/CT scans. The report will be interpreted from the SUV of lymph nodes.

Results: Results demonstrated that the PET/CT scan correctly identified 24 out of 30 patients on the pre-

operative lymphadenopathies. Moreover, 14 out of 24 patients (58.3%) showed metastatic lymphadenopathies from final histopathology (Fig. 1). The remaining 2 out of 6 patients (33.3%) have metastatic lymphadenopathies from final histopathology, but PET/CT did not detect it (Fig. 2, Fig. 3).

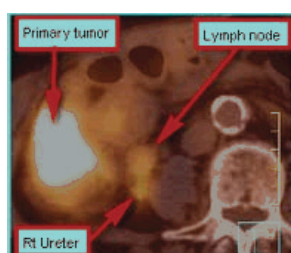


Figure 1 True positive PET-CT

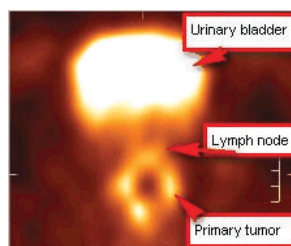


Figure 2 False negative PET

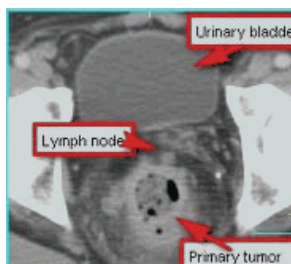


Figure 3 False negative CT

Mean on the SUV in malignant lymphadenopathies (1.18 ± 0.69) together with benign lymphadenopathies (0.59 ± 0.54) in primary colorectal cancer patient has the significant differentiation ($p = 0.014$) which is shown in Table 2.

Table 2 Histopathological diagnosis of detected lymph nodes compared with SUV

	Histopathological diagnosis of detected lymph nodes		P value*
	Malignant LN (n = 16)	Benign LN (n = 14)	
Range SUV	0-2.4	0-1.8	0.014
Mean \pm SD	1.18 ± 0.69	0.59 ± 0.54	

*Data was analyzed by student's t-test ($p < 0.05$)

Conclusion: There is an association between pre-

operative diagnosis of suspicious malignant lymphadenopathies by PET/CT scan and final histo-pathological lymphadenopathies. PET/CT scan will benefit from further examination of its predictive role pre-operatively towards diagnosis of lymph node metastasis in colorectal cancer patients. The constraint of this retrospective study is the confirmation of the location of lymph nodes that were found on the PET/CT scan that matched the lymph node results to the final histopathology report. There is a trend to have more high level of SUV (High uptake FDG) in malignant rather than benign lymph nodes using pre-operative PET/CT scan in colorectal cancer patients. According to this small samples size, the cut-off point of significant SUV could not be exactly calculated. This report will be the case for the further study in the future.

BENEFIT FROM A GENETIC TEST IN DESCENDANTS OF FAMILIAL ADENOMATOUS POLYPOSIS SYNDROME: REPORT OF A FAMILY IN SOUTHERN THAILAND

Worawit Wanitsuwat, Teeranut Boonpipatanapong, Samornmas Kanngern, Walawee Chaiyapan, Podchanaporn Graidist, Surasak Sangkhatthath

Tumor Biology Research Unit, Department of Surgery, Department of Pathology and Department of Biomedical Science, Faculty of Medicine, Prince of Songkla University, Hat Yai, Songkhla, Thailand

Background: Colorectal cancer (CRC) is one of the leading causes of cancer death worldwide and ranks as the third most common cancer in Thailand. According to the Thai cancer registry, 8,000 new cases of CRC are expected each year and the incidence is increasing. Although the etiology of CRC is multifactorial, it was estimated that about 5% of CRCs are an inherited condition. The most widely known CRC associated hereditary syndrome is familial adenomatous polyposis (FAP), a cancer predisposing syndrome that inadvertently leads to development of CRC. Although it is recommended that a patient with FAP should be screened for APC mutations, such genetic testing is not common in low income countries, especially in rural areas where resources for sophisticated tests are limited. The cost of an APC test, at around 285-1,650 USD, is not covered by national health insurance in Thailand. Even in developed countries, a unit cost this high remains an important barrier for a genetic study.

Objective: We present the case of a FAP family in southern Thailand which had clear benefit from the test, in hope that cases such as this will help persuade policy makers that this test, although expensive, is worth the cost.

Materials & Methods: From an economic point of

view, to invest in preventive care is basically more cost-effective than therapy, especially when any preventive measure is given to the patients at risk. FAP is a single-gene condition that invariably has an autosomal dominant mode of inheritance with complete penetrance. For this reason, identification of family members who have inherited the FAP genetic pathology theoretically provides an early exclusion of unaffected cases and allows those with mutations to enroll into more intensive work-ups and prophylactic surgery.

Results: First degree family members including siblings and their children were invited for counseling and genetic testing under informed consent. Except for case which had died of colorectal cancer prior to the study, all related members at the same generation as the index case and their children participated the genetic test. The study found the same APC mutation in two male children and two daughters of the index patient. Colonoscopies have been performed on the 4 cases with positive mutations. The study revealed multiple sessile polyps along the entire length of the colon in all cases. Biopsies homogeneously showed tubular adenoma in all the patients. A prophylactic total colectomy and a straight ileoanal anastomosis was performed on the children with polyposis. The surgical specimen from each patient showed sparse colonic polyposis, attenuating at the rectosigmoid region. The number of polyps in each case was not more than 300 lesions. We have shown a clear economic benefit from the genetic test. With the current standard of mutation study, including a combination of nucleotide sequencing and deletion test, APC mutations can be identified in 85-95% of FAP patients. Taking this technical limitation into account, cost needed per a positive yield will exceed the actual test cost. The cost can be balanced against the cost of not doing unnecessary screening endoscopies. In addition, family members who have negative results can be relieved from psychological stress caused by the cancer risk. To understand the full benefit of a high cost genetic test such as the APC test, a health care provider needs to view the big picture of the whole family. The more at-risk members a family has, the more cost-effective the test scores. The APC genotyping in our index case revealed a deletion mutation at codon 1249 which leads to a premature stop. Although the mutation at the same codon has been reported by Miyoshi et al., the details of the nucleotide alteration were not alike. Positive beta-catenin nuclear accumulation could be interpreted as indicating that Wnt-signaling was activated in our patient, which was an evidence that supports a disease-causing role of the mutation. The sparse number of polyps in our four patients undergoing colectomy at their varying ages confirmed a previous observation that

codon 1249 is a boundary in the gene that distinguishes APC mutations that are correlated with attenuated polyposis from the profuse type.

Conclusions: In summary, we presented the case of a family with FAP that had benefit from APC genotyping. The test was able to identify cases that would benefit from early surgical intervention. The model encourages the implementation of such genetic tests to standard care.

ONCOLOGIC AND PERIOPERATIVE OUTCOMES OF LAPAROSCOPIC ASSISTED VS HAND-ASSISTED VS OPEN RESECTIONS FOR RECTAL CANCER: A CASE MATCH STUDY

Pornthep Prathanvanich¹, Pattana-arun J²,
Sahakitrungruang C², Atithansakul P², Arun Rojanasakul²

¹Taksin Hospital, Bangkok, Thailand

²King Chulalongkorn Memorial Hospital, Bangkok, Thailand

Purpose: Advances in surgical techniques and improvements in laparoscopic instruments have enabled most colorectal procedures to be performed by using the laparoscopic approach. Laparoscopic surgery of colon cancer has been accepted to be oncologically adequate compared with open resection. However, the situation in rectal cancer remains unclear because anatomy and complex surgical procedures. There have been only a few reports compared Laparoscopic assisted vs Hand-Assisted (HALS) vs Open resections for rectal cancer.

This study is designed to analyze oncologic and perioperative outcomes of selected patients matched by staging who undergo these three accesses of surgery.

Methods: A total of 114 patients with rectal cancer who underwent surgery by the same surgical team (2006-2008) are prospectively studied. They are selected for the same staging in which 38 patients are chosen into each group. One-way ANOVA, Pearson's chi-square and Fisher's Exact test are used to compare differences in demographics and perioperative parameters.

Results: All groups are comparable regarding age, gender, tumor localization, and complications. Each group is comprised of 2 upper, 6 middle, 30 low rectal cancer cases with 5 in stage 0, 3 in stage I, 13 in stage IIA, 3 in stage IIIA, 9 in stage IIIB, 4 in stage IIIC, and 1 in stage IV. No mortality occurs in any group. Mean operative times are not significantly different between open and HALS group (276 min/open vs 263 min/HALS, $p = 0.546$). But difference are found when compared these two groups with laparoscopic surgery (344 min/lap, $p = 0.002$ and 0.000 respectively). No significant difference are found in first bowel movement between minimal invasive surgery (2.5

day/lap vs 1.9 day/ HALS , $p = 0.128$), but difference with open group (3.5 day/ open , $p = 0.02$ and 0.00 respectively). The mean tumor size is 4.5 cm/open, 3.6 cm/lap, and 4.2 cm/HALS. The mean tumor-free margin is 1.6 cm/open, 1.8 cm/lap, and 2.3 cm/HALS group. And the mean number of harvested lymph nodes is 19.4 /open, 17.5 /lap, and 17.6 /HALS group. No wound recurrence is observed.

Conclusions: Minimal invasive surgery is equivalent to conventional surgery in the treatment of rectal cancer but having the advantages of faster recovery. Especially in patients with low rectal cancer, minimally invasive surgery with exact preparation of the total mesorectal excision seems to be favorable compared with open access surgery.

SHORT-TERM OUTCOMES AND ONCOLOGIC CLEARANCE OF SIDE-TO-END ANASTOMOSIS AFTER LOW ANTERIOR RESECTION IN RECTAL CANCER PATIENTS

Romyen Jitmongngan, Woramin Riansuwan, Cherdasak Iramaneerat, Wiroon Boonnuch, Darin Lohsiriwat, Narong Lert-akyamanee

Colorectal Surgery Unit, Division of General Surgery, Department of Surgery, Faculty of Medicine Siriraj Hospital, Mahidol University, Bangkok, Thailand

Background: Colorectal cancer is one of the most common cancers in Thailand. Low anterior resection (LAR) is the procedure of choice to achieve oncologic resection and sphincter saving for rectal cancer patients. Many methods to restore of bowel continuity were described including side-to-end anastomosis (SEA) after LAR. Although outcomes of SEA after LAR were acceptable, most studies reported only small number of cases and studies of Thai patients are limited. We therefore performed this study to determine short-term outcomes and oncologic clearance of side-to-end anastomosis after low anterior resection in rectal cancer patient.

Methods: A retrospective patient charts review was performed. All patients with pathologically confirmed adenocarcinoma of rectum who underwent LAR with SEA in Colorectal Surgery Unit, Department of Surgery, Faculty of Medicine Siriraj Hospital between July 2007 and April 2010 were included. Demographic, perioperative data and postoperative short-term outcomes were analyzed.

Results: There were 113 patients with a mean age of 59 years; 57 (50.4%) males and 56 (49.6%) females. Six percent of patients underwent preoperative neoadjuvant chemoradiation. Average tumor location was 6.7 cm above anal verge; 31 (27.4%) above, 37 (32.7%) at, and 45 (39.8%) below the peritoneal reflection. Pathologically,

most specimens were T3 tumor (67.3%) and half of patients had positive lymph nodes (Table 1). Median number of harvested lymph node was 18 nodes and the resected surgical margin was 6.1% microscopically positive. Postoperative overall complication rate was 38.9%. Anastomosis leakage rate was 7.1% and there was one death (Table 2). Median time to regular diet resumption was 110 hours and median hospital stay was 11 days.

Conclusions: Short-term outcomes and oncologic clearance of low anterior resection with side-to-end anastomosis is comparable to reported outcomes in other studies. Studies of long-term oncologic and functional outcomes are ongoing.

Table 1 Pathology and resected surgical margin

	N	%
T stage		
T1	6	5.3
T2	25	22.1
T3	76	67.3
T4	6	5.3
N stage		
N0	53	46.9
N1	23	20.4
N2	37	32.7
Resected surgical margin		
All free	106	93.8
Positive circumferential margin	5	4.4
Positive distal margin	2	1.7

Table 2 Postoperative complications and 30 day-mortality

Complication	N	%
Overall	44	38.9
Superficial surgical site infection	15	13.3
Urinary retention	11	9.7
Anastomosis Leakage	8	7.1
Intraabdominal collection	6	5.3
Postoperative ileus	5	4.4
30 day-mortality	1	0.9

PELVIC EXENTERATION: COMPLEX TECHNIQUES OF LATERAL WALL AND BONE INVOLVEMENT: HOW TO DO IT

Michael J. Solomon

Department of Colorectal Surgery & Surgical Outcome Research Centre (SOuRCe) University of Sydney, Australia

A clear resection margin (R0 stage) is predictive of survival for patients with local recurrence. Achieving an R0 stage is technically more difficult due to the proximity of the recurrence to the bony pelvis. This paper describes in detail the methods for detailed pre-operative assessment of the resectability of recurrent using MRI scans and the meticulous planning and multi-disciplined surgical approach to exenteration surgery. Better imaging techniques available today, a multidisciplinary surgical approach and improved surgical technique have changed the definition of resectability. Patients previously considered unresectable due to ischium or ileum bone involvement are now considered resectable by functional preserving composite resection of the pelvis, that is, resection of an anatomical bony component of the pelvis. Magnetic resonance imaging (MRI) of the pelvis allows accurate and individual assessment of the tumor and planning of the surgical approach particularly with assessment of the lateral pelvic side wall and bone involvement. A lateral dissection technique will be described anatomically and operatively.

The technique that enables one to get lateral from the level of the internal iliac vessels and into a fresh tissue plane will be described pictorially and in detail. This allows exposure and resection of involved ischium and ileum, piriformis and obturator muscles, from the femoral nerve to obturator nerves to the lumbosacral trunk and sacral trunks down the origin of the sciatic nerve at the greater sciatic notch. At this level exposure and resection can include, via access from the pelvis alone in supine or combined with a prone completion, the ischial spine, sacrospinous and sacrotuberous ligaments and the sacral vertebra up to and occasionally partially involving S1. This multidisciplinary approach and careful and thorough preoperative radiological assessment as well as the complexity of this procedure can involve any combination of procedures. Extensive preoperative assessment and operative planning can be predictive of the number of specialties and type of resection that may be required and hopefully determine the probability of a clear resection margin (R0 is the holy grail of exenteration surgery).

PELVIC EXENTERATION FOR ADVANCED PRIMARY AND RECURRENT RECTAL CANCER: SURVIVAL, SURGICAL OUTCOMES AND QUALITY OF LIFE

Michael J. Solomon

Department of Colorectal Surgery & Surgical Outcome Research Centre (SOuRCe) University of Sydney, Australia

Despite its first description in 1948, pelvic exenteration for locally advanced primary or recurrent rectal cancer still remains a surgical challenge associated with a high mortality and significant morbidity. As a result, the role of pelvic exenteration still remains somewhat contentious even though promising evidence shows a marked improvement in survival amongst those who undergo such radical surgery. Our experience over the past decade with this procedure has demonstrated a 36%-46% 5 year survival rate for those who undergo pelvic exenteration for recurrent rectal cancer. While the evidence shows a marked improvement in survival compared to those treated non-operatively, its role remains debatable for lateral pelvic side wall recurrence and bone involvement (LR). We have previously demonstrated that the ability to achieve a clear resection margin (R0 stage) is predictive of survival. However, for patients with local recurrence achieving an R0 stage is technically more difficult due to the proximity of the recurrence to the boney pelvis. For this reason, some believe that extensive radical resection for LR may not translate into a worthwhile survival gain, and, that the subsequent quality of life during this period will be extremely poor. However, our data combined with

other encouraging survival data has prompted the development and adoption of a more radical lateral approach to lateral pelvic involvement. This paper describes the international results as well as techniques developed to particularly address extensive lateral pelvic side wall or sacral involvement by locally advanced or recurrent pelvic cancer, in order to achieve a clear resection margin, which should translate into improve survival in these patients. The effect on quality of life of pelvic exenterations will be discussed. Better imaging techniques available today, a multidisciplinary surgical approach and improved surgical technique have changed the definition of resectability. Patients previously considered unresectable due to ischium or ileum bone involvement are now considered resectable by functional preserving composite resection of the pelvis, that is, resection of an anatomical boney component of the pelvis. Computed Tomography combined with Positron Emission Tomography (CT-PET scan) has arguably allowed better assessment of metastatic disease from what appears to be local recurrence alone. Magnetic resonance imaging (MRI) of the pelvis allows accurate and individual assessment of the tumor and planning of the surgical approach particularly with assessment of the lateral pelvic side wall and bone involvement. Importantly this lateral dissection technique described, achieved clear margins (R0 stage) in 53% of patients who would otherwise have been considered unresectable. Moreover, 71% of these patients remained disease free at the site of surgical resection with an average disease free interval of 30 months. Despite the complexity and magnitude of this technique, in our experience it is feasible and safe as indicated by a 0% perioperative mortality rate in over 200 exenterations till 2010. Careful preoperative planning with extensive radiological assessment and a multidisciplinary approach is paramount prior to proceeding to surgery if one wishes to achieve a clear (R0) resection. The benefit of this technique is that it enables one to get lateral from the level of the internal iliac vessels and into a fresh tissue plane. This allows exposure and resection of involved ischium and ileum, piriformis and obturator muscles, and the lumbosacral trunk and sciatic nerves in order to achieve that clear margin. In conclusion we cannot stress enough the importance of a multidisciplinary approach and careful and thorough preoperative radiological assessment if an R0 margin of resection is to be achieved. The complexity of this procedure can involve any combination of procedures as demonstrated in this series of patients. Extensive preoperative assessment and operative planning can be predictive of the number of specialties and type of resection that may be required. Quality of life is comparable to quality of life after primary rectal cancer resections.

INDIGO CARMINE USE FOR DYE BASED MAGNIFY CHROMOENDOSCOPY, FEASIBILITY AND SAFETY IN COLONIC POLYP DIFFERENTIATION

Supakij Khomvilai, Jirawat Pattana-arun, Chuchee Sahakitrungruang, Kasaya Tantiphlachiva, Puttarat Atittharnsakul, Arun Rojanasakul

Colorectal division, Department of Surgery, Chulalongkorn University, Bangkok, Thailand

Colonic polyp has a chance to become a cancer following the adenoma-carcinoma pathway. That is the reason why we have to cut all of the adenomatous polyps from the colon whenever we found, but all of the colonic polyps do not always been adenoma. Polypectomy of hyperplastic polyp wastes time and equipments without any benefit from polyp removal. Magnify chromoendoscopy can help to differentiate neoplastic from non-neoplastic polyp by using the pit pattern which was described by Professor Kudo in 1994. This procedure has to use the dye, indigo carmine, which is not available in Thailand. We start to produce indigo carmine in corporate with the Queen Saovabha Memorial Institute, Thai Red Cross Society since January 2009. There were 10 patients with the colonic polyps included in the study of feasibility and safety of the indigo carmine. All of the patients did not have any allergic reaction or gastrointestinal symptoms. We report the feasibility and safety of indigo carmine for dye based magnify chromoendoscopy in our institute.

COLON CANCER WITH SKULL METASTASIS: A CASE REPORT

Montian Marutkarakul, Noppawat Samankatiwat

Department of Surgery, Ratchaburi Hospital, Ratchaburi, Thailand

Background: The most common site of distant metastasis of colon cancer is the liver followed by lung. Skull metastasis from colon cancer is a rare condition. We report a case of carcinoma of the cecum with liver and skull metastasis.

Case Report: A 79-year-old man, who had a past history of hypertension and coronary arterial disease, presented with a history of abdominal discomfort for 2 weeks. Physical examination revealed an abdominal mass about 5 cm in diameter at the right lower quadrant and hepatomegaly. In addition, a scalp nodule about 3 cm in diameter was found at the right parietal area. The ultrasonography and CT scan of the abdomen showed multiple liver metastases. Barium enema showed a polypoid intraluminal mass about 6×3 cm at the medial aspect of the caecum with obstruction. Osteolytic lesion at the right

parietal bone was found on the plain skull radiography. The patient underwent right hemicolectomy and excision of the scalp nodule. Multiple liver metastases were found at operation. Operative time was 1 hours 35 minutes. Estimated blood loss was about 150 ml. There was no intraoperative complication. Pathological finding revealed moderately differentiated adenocarcinoma of the cecum with transmural invasion to pericolic fat and metastasis to 5 of 11 regional lymph nodes. Pathological diagnosis of the tissue at the scalp was metastatic carcinoma. CT scan of the brain performed at 2 weeks postoperatively showed no evidence of brain metastasis. The patient expired at 2 months after operation from cancer cachexia and liver metastasis.

Conclusion: A nodule at the scalp in a patient with colon cancer could be a metastatic lesion. The colon cancer patient with a skull metastasis was treated by excision and diagnosis was confirmed by histopathology.

TREATMENT OF RECTOVAGINAL FISTULA: A 5 YEARS EXPERIENCE

Atittharnsakul P, Rojanasakul A, Pattanaarun J, Tantiphlachiva K, Sahakitrungruang C

Colorectal Division, Department of Surgery, Chulalongkorn University, Bangkok, Thailand

Purpose: Several procedures have been described for the management of rectovaginal fistula. Surgical techniques range from local tissue repair to extensive surgery base on the specific etiology, type of fistula, patients' physical status and anatomical defect. We present our 5 years experience in (operated for) rectovaginal fistula repair.

Methods: A retrospective review was performed. Data collection included patients' demographic data, etiology, location, size, operative procedure, morbidity and length of the hospital stay.

Results: From 2001-2005, 34 consecutive patients surgically treated for rectovaginal fistula were evaluated. The etiology included obstetrical injury (7), radiation (8), radiation with recurrent gynecological cancer (8), rectal cancer with preoperative chemoradiation (4), ovarian cancer (1), post low anterior resection (4) and unknown etiology (2). Surgical procedures performed in this study included endorectal flap for 7, endovaginal flap for 4 and one of these patients included gracilis muscle flap, sphincteroplasty for 2, low anterior resection with coloanal anastomosis with protective ileostomy for 5, abdominoperineal resection for 2, transsacral repair for 2, direct repair for 1, tumor resection for 1 and colostomy alone

for 10. There were 9 post operative complications; 3 patients developed wound infection, 2 hematomas, 1 wound dehiscence which was treated conservatively. Three patients developed recurrence of rectovaginal fistula.

Conclusion: Operative repairs for rectovaginal fistula

provide good results in selected patients. The etiology, prior radiation therapy, type of fistula, associated anatomical defect and patients physical status should be extensively evaluated for the selection of the surgical procedure.

HEPATOBIILIARY AND PANCREATIC SURGERY

LAPAROSCOPIC PANCREATIC SURGERY IN OUR INSTITUTION

Yoshiharu Nakamura

Department of Surgery, Nippon Medical School, Japan

Laparoscopic pancreatic resection began to be reported in the first half of the 1990s, with subsequent reports focusing primarily on the safety and usefulness of laparoscopic distal pancreatectomy (Lap-DP) and laparoscopic enucleation (Lap-EN) for benign and low-malignancy lesions of the pancreatic body and tail (such as chronic pancreatitis, neuro-endocrine tumor, mucinous cystic neoplasm, and intraductal papillary mucinous neoplasm). Recently we have also begun to see retrospective case-control studies comparing these techniques to open surgery, with Lap-DP showing advantages not only in terms of esthetics related to the surgical wound, but also with regard to reduced intraoperative bleeding, postoperative recovery time, and days of postoperative hospitalization. Prospective randomized controlled trials are still needed for confirmation, but it appears likely that this technique will become a standard surgical procedure for the treatment of diseases of the pancreatic body and tail. In contrast, laparoscopic pancreatoduodenectomy (Lap-PD) remains controversial in the minds of many pancreatic surgeons. This is primarily due to the difficulty of laparoscopic reconstruction following resection. However, there have recently been a number of single-center reports of the use of this procedure in at least 20 patients per center, showing that Lap-PD is associated with considerable reduction in intraoperative bleeding. Our own experience has been similar. In carefully selected patients, we find Lap-PD to be a useful surgical procedure. Since the approval of laparoscopic pancreatic resection in January 2004 by the Ethics Committee of Nippon Medical School, the use of this procedure has been introduced in our department, and to date we have conducted a total of more than 60 procedures for Lap-DP, Lap-EN, and Lap-PD. We would like to show the techniques that we use in these procedures, and will demonstrate those clinical outcomes.

BINDING PANCREATICOJEJUNOSTOMY AND BINDING PANCREATICOGASTROSTOMY

Shu You Peng

Objective: To prevent the development of pancreatic fistulae, we designed a special technique called Binding pancreaticojejunostomy.

Methods and Result: Binding pancreaticojejunostomy means binding 3 cm of the serosa-muscular sheath of the jejunum to the intussuscepted pancreatic stump. In brief, this procedure is performed as follows: first, the cut end of the pancreatic remnant is isolated for a distance of 3 cm. Three cm of the distal cut end of the jejunum is everted. The exposed jejunal mucosa is destroyed either by electric coagulation, or by 10 percent carbolic acid followed by rinsing immediately with 75% alcohol and normal saline. The pancreatic stump and the everted jejunum are brought together and sutured with silk, intermittently or continuously. Care is taken to suture the mucosa only, and avoid penetrating the serosa and muscular layer of the jejunum. The everted jejunum is then turned down to its normal position to wrap over the pancreatic stump and is sutured to the pancreas with few stitches for fixation. Lastly, 1cm from the cut end of the jejunum, a catgut tie is looped around the entire circumference of the anastomosis. A bundle of vessels is spared for maintaining blood supply to the jejunal cut end distal to the binding ligature. To simplify, the suture of the mucosa of the jejunum to the cut end of pancreas can be omitted. Only the binding ligature can act as the essential role to prevent leakage. BPJ has been used in China for more than 5,000 cases, the leak rate being 0-0.5%. However, when the pancreas stump is too large it would be difficult to be inserted into jejunal lumen. To solve this problem Binding Pancreatico Gastrostomy (BPG) has been designed and used clinically. Five steps are included: (1) Isolation of pancreatic stump for 2 cm. (2) Pre-place a purse-suture at the posterior gastric wall around the area where an incision will be made and the pancreatic stump will be inserted into. (3) An incision is made at the anterior gastric wall. (4) Pre-place purse-suture at the

mucosal layer around the hole on the posterior gastric wall where the pancreatic stump will be pulled into gastric lumen. 5. Binding anastomosis. The pancreas remnant is pulled into the gastric lumen through the posterior gastric wall. Thereafter, the outer purse-string is tied (outer binding) and then the inner purse-string is tied (inner binding) BPG is thus firmly and easily established. BPG has been used for more than one hundred cases. Amylase in abdominal drain are within normal range except one case where amylase level was higher than normal for 2 wk. Presumably It was due to the injury of the pancreas beyond the anastomosis. No anastomotic leakage occurred.

Conclusion: In Whipple operation, binding pancreaticojejunostomy is a safe, simple and effective technique which avoids the primary complication of anastomotic leakage. Pancreaticogastrostomy is good for accommodating a large pancreas stump. Binding technique is very helpful in minimizing the leak rate of pancreaticogastrostomy.

LAPAROSCOPIC ASSISTED WHIPPLE OPERATION

Suchayes Pumchandh

Chulalongkorn Hospital, Bangkok, Thailand

Introduction: Whipple operation is the standard procedure for treatment of pancreatic surgery. In the past, minimally invasive surgery was used for staging and evaluation of resectability by diagnostic laparoscopy. We would like to introduce an alternative option which is laparoscopic assisted Whipple operation. The advantages of this procedure are simple technique and instrument.

Materials and Methods: Data collected by retrospective review from 2007 to 2009 include 15 cases each of laparoscopic Whipple operation and open Whipple operation. The data collected are blood loss, operative time, postoperative stay, conversion rate, pathologic outcome, number of lymph nodes, and complications. The statistic analysis employs Mann-Whitney test.

Result: Mean age was 62.04 years (41-82 years). Mean operative time was 295 minutes in laparoscopic and 275 minutes in open. Blood loss was 550 ml in laparoscopic and 650 ml in open. No statistical significance between open and laparoscopic assisted surgery, except post operative stay and blood transfusion. Postoperative stay was 10.36 days in laparoscopic assisted and 18.64 days in open ($p < 0.007$). Blood transfusion was 267.8 ml in laparoscopic assisted and 714.3 ml in open ($p < 0.03$). One case in laparoscopic assisted was converted to open due to bleeding, one other case required reoperation due to delay bleeding. But both of patients are safe. Complications were leakage (3 patients) and wound infection (3 patients), and Limb

obstruction (1 patient). No mortality in laparoscopic assisted surgery. All specimens revealed free margin and adequate LN in malignancy case.

Conclusion: Our results confirm the feasibility of laparoscopic assisted Whipple operation, and demonstrate the promising outcomes of this procedure in selected patient. There was no difference between open and laparoscopic assisted approach regarding complication and resectability.

ENDOSCOPIC-ASSISTED LIVER HANGING MANEUVER: A SAFER APPROACH

Rawisak Chanwat^{1,2}, Piti Rujanavej¹

¹Surgical Oncology Unit, National Cancer Institute, Bangkok 10400,

²Department of Surgery, Yala Regional Hospital, Yala 95000, Thailand

Objective: To establish a safer and technically easier retrohepatic dissection for the liver hanging maneuver with the assistance of endoscope.

Methods: During the dissection of the cranial and caudal parts of the liver, the space between the right and middle hepatic veins and the anterior surface of the infrahepatic IVC are carefully exposed. A flexible choledoscope was gently moved through the retrohepatic tunnel from the caudal to the cranial end instead of blind dissection, and then tape can be passed around the liver to elevate it away from the anterior surface of the IVC.

Results: This procedure has been employed in six right hepatectomies for a huge hepatocellular carcinoma. In all cases, the taping was easily accomplished without any problems.

Conclusions: The most important step during the liver hanging maneuver is to develop the avascular space without any complication. This modification of Belghiti's liver hanging maneuver allows direct vision along the plane between the liver and the IVC, thus avoiding injury to the retrohepatic veins or IVC.

IDENTIFICATION OF THE NOVEL BIOMARKERS TO CLINICALLY DISTINGUISH CHOLANGIOCARCINOMA FROM BENIGN BILIARY TRACT DISEASES

Kawin Leelawat, Siriluck Narong, Jerasak Wannaprasert

Department of Surgery, Rajavithi Hospital, Bangkok, 10400, Thailand

Background: Cholangiocarcinoma (CCA) is one of the most aggressive malignant tumors and is associated with local invasiveness and a high rate of metastasis. Most cholangiocarcinoma patients present with symptoms of biliary tract obstruction. However, many cases of benign

biliary tract diseases also present with similar clinical symptoms.

Objectives: This study was designed to identify the serum markers that can discriminate cholangiocarcinoma from benign biliary tract disease patients.

Methods: This study was performed according to a prospective-specimen collection, retrospective-blinded-evaluation (PRoBE) design. A total of 50 cholangiocarcinoma and 50 benign biliary tract disease cases were randomly selected from a cohort of consecutive cases of biliary tract diseases. Their sera were measured for the levels of MMP7, MMP9, NGAL, E-Cadherin, and the widely used serum cholangiocarcinoma marker, carbohydrate antigen 19-9 (CA19-9). To detect circulating tumor cells (CTCs), mRNA was isolated from their peripheral blood mononuclear cells (PBMC) and the expression of hTERT and cytokeratin-19 (CK-19) mRNA was identified by Real-time RT-PCR.

Results: The serum levels of MMP9 and E-cadherin and the quantity of CTCs were not significantly different between cholangiocarcinoma and benign biliary tract diseases patients. However, the serum MMP7, NGAL and CA19-9 levels were significantly elevated in cholangiocarcinoma patients (MMP7: $p < 0.001$, NGAL: $p < 0.001$, and CA19-9: $p < 0.001$). The area under the curve (AUC) of a receiver operating characteristic (ROC) curve analysis for the diagnosis of cholangiocarcinoma of MMP7, NGAL and CA19-9 was 0.86 (95% CI 0.782-0.936), 0.79 (95% CI 0.701-0.880) and 0.81 (95% CI 0.722-0.899) respectively. In a multivariable model that included CA19-9 (cut-off value = 100 ng/ml), MMP7 (cut-off value = 5.5 ng/ml) and NGAL (cut-off = 100 ng/ml), CA19-9 and MMP7 were shown to be independent predictors for cholangiocarcinoma.

Conclusion: The diagnostic accuracy of serum MMP7 and CA19-9 makes them good candidates for use as biomarkers to discriminate cholangiocarcinoma patients from benign biliary tract disease patients.

LAPAROSCOPIC-ASSISTED PANCREATICODUODENECTOMY

Amarit Tansawat, Patpong Navichareern

Chula Minimally Invasive Surgery Center, Department of Surgery, Faculty of Medicine, Chulalongkorn University, Bangkok, Thailand

Background: Pancreaticoduodenectomy is the gold standard for periampullary cancer treatment but in selected cases this procedure can be performed by laparoscopic-assisted technique.

Objective: To demonstrate laparoscopic-assisted pancreaticoduodenectomy.

Materials & Methods: A 60 years old female patient diagnosed to have CA ampulla of Vater underwent laparoscopic-assisted pancreaticoduodenectomy. The procedure consisted of laparoscopic phase and open phase. The mobilization of pancreatic head and its transection were performed in laparoscopic phase, while anastomosis was performed in open phase. Specimen was removed via mini-laparotomy wound.

Results: The patients recovered well and returned home in 1 week.

Conclusion: Laparoscopic-assisted pancreaticoduodenectomy can be the choice of treatment in selected cases of periampullary cancer.

AN NOVEL THERMOSENSITIVE AMPHIPHILIC BLOCK COPOLYMER USED AS DOXORUBICIN CARRIERS FOR THE TREATMENT OF CHOLANGIOCARCINOMA

Li Songgang, Wan Ziwei, Tan Qinggang, Quan Zhiwei

Department of General Surgery, Xinhua Hospital, Shanghai Jiao Tong University, School of Medicine, Shanghai, PR China

Purpose of Study: Cholangiocarcinoma is a devastating malignancy that is difficult to diagnose, and is associated with a high mortality. The incidence of cholangiocarcinoma has increased worldwide. Surgical resection is the only chance for cure, but fewer than 30% of cholangiocarcinomas are potentially resectable at the time of diagnosis. Palliative therapies for unresectable cholangiocarcinoma such as stent, radiotherapy, and chemotherapy are disappointing. Cholangiocarcinoma is highly resistant to various antitumor drugs. To improve the therapeutic effectiveness of antitumor drugs, such as doxorubicin, we developed an amphiphilic block copolymer poly (N-isopropylacrylamide-co-N-hydroxymethyl acrylamide)-block polycaprolactone (P-(NIPAAm-co-NHMAAm)-b-PCL) to be used as doxorubicin carriers with properties of thermosensitivity and controlled drug release to achieve better antitumor effect for cholangiocarcinoma.

Methods: Using benzoperoxide as polymerization initiator and tetrahydrofuran as solvent, P-(NIPAAm-co-NHMAAm) was synthesized from NIPAAm and NHMAAm in the reaction system. P-(NIPAAm-co-NHMAAm) can initiate the polymerization of caprolactone (CL) and the thermosensitive amphiphilic copolymer, P-(NIPAAm-co-NHMAAm)-b-PCL was obtained. The composition and structure of the copolymers were characterized by infrared and NMR spectroscopy. The lower critical solution temperature (LCST) was tested by UV spectrophotometer. Then antitumor drug, doxorubicin was cross-linked to the copolymer and temporal control of the drug release

efficiency was examined by high efficiency liquid chromatography (HPLC) at different temperatures. The cytotoxic effects of doxorubicin loaded copolymer micelles was measured by 3-(4,5-Dimethylthiazol-2-yl)-2,5-diphenyl Tetrazolium Bromide (MTT) assay. The ultrastructures of cells were observed under TEM and apoptosis was evaluated with Hoechst 33258 staining. Finally, the anti-tumor activity of doxorubicin loaded copolymer micelles was tested in nude mice bearing cholangiocarcinoma, and tumor histopathology of mice was evaluated by hematoxylin and eosin staining.

Results: P-(NIPAAm-co-NHMAAm)-b-PCL showed good thermosensitivity and controlled drug release as expected. The LCST was about 38 °C. The doxorubicin-loaded copolymers showed slow drug release at 25 °C and

fast drug release at 38 °C. The doxorubicin-loaded copolymer micelles exhibited better tumor killing effects in cholangiocarcinoma cells in vitro and apoptotic morphological changes were observed by fluorescence microscope with Hoechst 33258 staining. In vivo experiment, the doxorubicin-loaded micelles group had significant effect on inhibiting the tumor growth when compared with model group ($p < 0.05$), and the inhibitory rate was 21.49%.

Conclusions: Amphiphilic block copolymer, P-(NIPAAm-co-NHMAAm)-b-PCL, showed good properties in thermosensitivity and controlled drug release. Doxorubicin-loaded copolymers could effectively kill tumor cells in vitro and inhibit tumor growth in vivo, which was realized by apoptosis.

MINIMAL INVASIVE SURGERY

EARLY EXPERIENCE OF LAPAROSCOPIC FEEDING JEJUNOSTOMY

Poochong Timratana, Suchart Chantawibul

Division of General Surgery, Department of Surgery, Rajavithi Hospital, College of Medicine, Rangsit University, Bangkok, Thailand

Background: In comparison to open technique, laparoscopic feeding jejunostomy may provide less postoperative pain, less intraabdominal adhesion, improve in immune function, early return of bowel function and short hospital stay. We report early experience of laparoscopic feeding jejunostomy for nutrition support in locally advanced esophageal cancer patients scheduled for preoperative chemoradiation, locally advanced stomach cancer patients planned for preoperative chemotherapy, pharyngeal cancer patients awaiting total laryngectomy and gastric pull-up, and corrosive esophageal stricture patients awaiting colonic bypass.

Methods: The 8 patients (2 patients of esophageal cancer, 2 patients of stomach cancer, 2 patients of pharyngeal cancer and 2 patients of corrosive esophageal stricture) that never had abdominal operation, were offered for laparoscopic feeding jejunostomy under general anesthesia. The three ports technique (5 mm at subumbilicus and left upper quadrant, 10 mm at right upper quadrant, and we finally changed port incision at left upper quadrant to be the site of jejunostomy tube) and 14 French siliconized balloon catheter were used.

Results: Laparoscopic feeding jejunostomy was performed in 8 patients. There were no intraoperative complications, and average operative time was about 88.8

min. Early enteral feeding was started in the next day after surgery and no early postoperative complication was found.

Conclusions: Laparoscopic feeding jejunostomy is safe and less postoperative pain. This operation needs some skill in laparoscopic suturing technique.

LAPAROSCOPIC INCISIONAL HERNIA REPAIR (IPOM)

Amarit Tansawet, Suthep Udomsawaengsup

Chula Minimally Invasive Surgery Center, Department of Surgery, Faculty of Medicine, Chulalongkorn University, Bangkok, Thailand

Background: Incisional hernia is the protrusion of intra-abdominal organs through the defect of abdominal muscular layers which follow the many kinds of surgical wound complication. Nowadays, the concept of tension-free repair produced by mesh reinforcement is accepted as a gold standard in treatment of groin hernia, also in ventral or incisional hernia. This procedure can be performed by laparoscopic technique.

Objective: To demonstrate laparoscopic technique for abdominal incisional hernia repair.

Materials & Methods: 72 years old female who underwent low anterior resection 2 years ago has reducible hernia from her previous ostomy wound. Laparoscopic adhesiolysis was performed and hernia defect was covered with composite mesh placed intraperitoneally.

Results: The patient recovered uneventfully.

Conclusion: Incisional hernia repair can be performed safely by laparoscopic technique.

LAPAROSCOPIC INTRAGASTRIC SUBMUCOSAL RESECTION

Amarit Tansawet, Chadin Tharavej

Chula minimally invasive surgery center, Department of Surgery, Faculty of Medicine, Chulalongkorn University, Bangkok, Thailand

Background: Stomach is the upper gastrointestinal organ which can be approached by endoscopy but some therapeutic procedure needed special equipments and experienced endoscopist. While small early neoplasm of stomach can be removed by endoscopic submucosal resection, we would like to propose the alternative technique which used only basic laparoscopic instruments.

Objective: To demonstrate the laparoscopic intragastric submucosal resection.

Materials & Methods: Presenting with upper GI bleeding, 52 years old male with a diagnosis of gastric carcinoid tumor by EUS+FNA underwent submucosal tumor resection. The procedure started by endoscopic submucosal saline injection around tumor. By guidance from endoscopy, trocars were inserted directly into stomach then submucosal resection was performed by cautery.

Results: No postoperative complication.

Conclusion: The laparoscopic intragastric resection is the alternative procedure for early gastric neoplasm which can be safely performed and needed no special equipments.

LAPAROSCOPIC ROUX-EN-Y GASTRIC BYPASS

Amarit Tansawet, Suthep Udomsawaengsup

Chula Minimally Invasive Surgery Center, Department of Surgery, Faculty of Medicine, Chulalongkorn University, Bangkok, Thailand

Background: Morbid obesity and its co-morbidities are the one of health care concern. While the bariatric surgery is the most durable way for control excess weight, not all health care center in Thailand can provide these type of surgery.

Objective: To demonstrate the surgical technique of Laparoscopic Roux-en-Y Gastric Bypass (LRYGB)

Materials & Methods: Female, 30, with BMI 47.6 kg/m² was underwent LRYGB. The operation has 3 major steps, 1. Gastric pouch creation, 2. Roux-en-Y creation and 3. Gastric pouch-jejunum limb anastomosis. The procedure was performed with meticulous technique.

Result: Patient recovered well without complication.

Conclusion: LRYGB is the gold standard operation for morbidly obese patients. The meticulous technique can reduce the operative complication and improve the results of surgery.

LAPAROSCOPIC PARAESOPHAGEAL HERNIA REPAIR

Amarit Tansawet, Suthep Udomsawaengsup

Chula Minimally Invasive Surgery Center, Department of Surgery, Faculty of Medicine, Chulalongkorn University, Bangkok, Thailand

Background: Paraesophageal hernia (PEH) is a rare disease but can cause severe adverse events. It usually occurs in elderly patients who invasive procedure should be avoided. However, less invasive reparation can be performed by laparoscopic method.

Objective: To demonstrate laparoscopic technique for paraesophageal hernia reparation.

Materials & Methods: 78 years old female diagnosed to have PEH underwent PEH reparation by laparoscopic technique. The procedure involves 3 steps: 1. Hernia sac excision and crural dissection, 2. Crural repair with mesh reinforcement, and 3. Fundoplication which was meticulously performed.

Results: Patients was uneventfully recovered. No recurrence was detected during follow up.

Conclusion: Laparoscopic reparation of PEH is safe and results in good outcome if performed with meticulous technique.

LAPAROSCOPIC SPLENECTOMY IN B-THALASSEMIA MAJOR PATIENT

Pornthep Prathanvanich

Taksin Hospital, Bangkok, Thailand

Background: Splenectomy is indicated in patients with thalassemia major when they develop hypersplenism with subsequent need for increased transfusions. Extreme splenomegaly is considered a restrictive factor for laparoscopic splenectomy in these patients.

Method: Technique of laparoscopic splenectomy for massive splenomegaly:

1. Dissection of the inferior aspect of the spleen
2. Dissection of short gastric vessels (for clear exposure of splenic hilum)
3. Control splenic artery and vein respectively
4. Dissection of the lateral and retroperitoneal attachments
5. Removing the spleen

This patient was a Thai male, 18 years old with B-thalassemia major disease. He had hypersplenism and massive splenomegaly (spleen was palpable at the umbilicus level). He received blood transfusion frequently (around 2 units / 2 weeks). After counseling, the patient agreed to laparoscopic surgery and he also recognized the percentage of conversion rate and complication. He had already

received polysaccharidic antipneumococcal immunization before surgery for 1 month.

Perioperative Outcomes: The surgical time was 210 minutes. The estimated amount of blood loss was 50 ml. Pain score (VAS) at 1st and 2nd postoperative day were 5 and 2 respectively. He requested 25 mg of Pethidine only one time at the night of operative day. Hospital stay was 3 days. After follow up for 2 months, he never required blood transfusion and hematocrit remained stable.

Conclusion: From our limited initial experience, it seems that laparoscopic splenectomy in the difficult setting of thalassemia major patients is feasible and as safe as the open approach. But extreme care is required in order to avoid hemorrhagic complication.

TAPP REPAIR FEMORAL HERNIA

Suchayes Pumchandh

Chulalongkorn Hospital, Bangkok, Thailand

Male 62 years old with underlying hypertension.

CC: Reducible right inguinal mass for 3 months

PI: 2 years ago, he underwent open femoral herniorrhaphy. 3 months ago, he felt dull pain on his right groin area and protruded mass. Mass is reducible. No clinical signs and symptoms of obstruction and strangulation.

PH: No history of drug allergy, no smoking

Physical examination

Vital signs are stable

Abdomen is soft, not tender, no distention. Surgical scar at right groin area

Reducible mass 5 cm. at right groin area, no sign of inflammation

Impression

Recurrent femoral hernia at right groin

Plan of treatment

Herniorrhaphy by laparoscopic TAPP (transabdominal preperitoneal approach)

GERD : LAPAROSCOPIC NISSEN FUNDOPLICATION

Suchayes Pumchandh

Chulalongkorn Hospital, Bangkok, Thailand

A Thai male 30 years, no underlying disease.

CC: Heart burn for 1 year

PI: He felt burning pain in the chest for one year and more pronounce after large meal. He felt early fullness after the meal. He went to other hospital and the physician suspected GERD, and he took some medicine (PPI). His

symptoms partially improved, but still disturbed him.

Physical examination

Not remarkable.

Investigation

Gastroscopy: normal findings (no hiatal hernia ,no ulcer, no mass)

Manometry: normal esophageal contraction, no pressurized esophagus, 24-hr pH monitoring- positive 8%

Impression

Gastroesophageal reflux disease

Plan of treatment

The patient do not want to take medication and prefer to have surgery.

Surgery: laparoscopic Nissen fundoplication.

VENTRAL HERNIA: LAPAROSCOPIC INTRAPERITONEAL ONLY MESH REPAIR

Suchayes Pumchandh

Chulalongkorn Hospital, Bangkok, Thailand

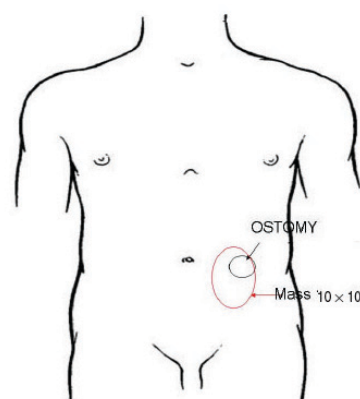
A 65 years old Thai female underlying hypertension

CC: Protruded mass at abdominal wall for 1 year

PI: 3 years ago, she underwent abdominoperineal resection for carcinoma of rectum.

About a year ago, she noticed a progressive enlarged lump at the inferior aspect of the end colostomy. The colostomy is functioning.

Physical examination



Investigation

CT abdomen-no recurrent tumor

Colonoscopy- normal mucosa, no tumor or polyp

Impression

Parastomal hernia

Plan of treatment

Repair parastomal hernia by laparoscopic approach (lap. IPOM)

DIAGNOSTIC LAPAROSCOPY AND TRANSABDOMINAL PREPERITONEAL REPAIR FEMORAL HERNIA (TAPP)

Suriya Punchai, Suthep Udomsawaengsup

Chula Minimally Invasive Surgery Center, Department of Surgery, Faculty of Medicine, Chulalongkorn University, Bangkok, Thailand

Background: Diagnostic laparoscopy is a procedure performed for examination of the abdominal cavity and pelvis for diagnostic purposes. Emergent laparoscopy can help to rule out an operable cause of acute abdominal pain or peritonitis but in cases of gut obstruction it is a relative contraindication because of difficulty in access and possible bowel injury. In complete small bowel obstruction, patient can be selected for diagnostic laparoscopy and laparoscopic treatment.

Objective: To demonstrate diagnostic laparoscopy in patient with complete small bowel obstruction due to obstructed femoral hernia and Trans Abdominal Pre Peritoneal repair (TAPP).

Materials & Methods: 81 years old female who had underlying Alzheimer's disease, previous laparoscopic cholecystectomy and mitral valve replacement presented with vomiting, abdominal distension and obstipation. Physical examination and X-ray revealed obvious complete small bowel obstruction but the cause of obstruction was unknown. We performed the diagnostic laparoscopy and found obstructed femoral hernia causing complete small obstruction then Transabdominal preperitoneal repair (TAPP) with mesh was done.

Result: The patient recovered uneventfully.

Conclusion: The diagnostic laparoscopy is safe in selected complete small bowel obstruction patient and obstructed femoral hernia may be the cause of obstruction which can be repaired by laparoscopic technique.

LAPAROSCOPIC PARAESOPHAGEAL HERNIA REPAIR

Poochong Timratana, Suchart Chantawibul

Division of General Surgery, Department of Surgery, Rajavithi Hospital, College of Medicine, Rangsit University, Bangkok, Thailand

Methods: A 84-year-old women presented with symptoms of dysphagia, substernal discomfort and postprandial fullness for one year. The chest film demonstrated a retrocardiac air-fluid level. CT scan revealed sliding of the stomach in mediastinum. Upper endoscopy showed sliding of the stomach and the gastroesophageal junction into the chest without erosive esophagitis, ulcer or tumor. The diagnosis of paraesophageal hernia type III was made. The patient underwent laparoscopic paraesophageal hernia

repair with PTFE mesh and Toupet fundoplication. The operation went well without immediate complication. Postoperative contrast study revealed no leakage, contrast easily passed into the stomach and the position of fundoplication remained in the abdomen. Liquid diet was allowed on the second postoperative day. No dysphagia or reflux symptoms were found after the operation.

LAPAROSCOPIC TUBE FEEDING JEJUNOSTOMY

Poochong Timratana, Suchart Chantawibul

Division of General Surgery, Department of Surgery, Rajavithi Hospital, College of Medicine, Rangsit University, Bangkok, Thailand

Methods: A 60-year-old man was diagnosed with a laryngeal cancer causing dysphagia and 10 kilogram weight loss within 3 months. The cancer obstructed the esophageal opening and was unable to pass the endoscope. Total laryngectomy and gastric pull-up were scheduled in a few weeks but the patient was in poor nutritional status and needed improvement before the major operation. He underwent laparoscopic tube feeding jejunostomy. Three ports technique (5 mm at subumbilicus and left upper quadrant, 10 mm at right upper quadrant, and converting port incision at left upper quadrant to be the site of jejunostomy tube) and 14 French siliconized balloon catheter were used. The operative went well without immediate complication. Early enteral feeding was started on the next day after surgery and no early postoperative complication was found. The patient was discharged on postoperative day 3.

LAPAROSCOPIC ROUX-EN-Y GASTRIC BYPASS (TRANSGASTRIC CIRCULAR STAPLER)

Poochong Timratana, Suchart Chantawibul

Division of General Surgery, Department of Surgery, Rajavithi Hospital, College of Medicine, Rangsit University, Bangkok, Thailand

Methods: A 25-year-old woman presented with right upper quadrant abdominal pain. The ultrasonography showed a gallstone. The patient was 159 cm tall and weighed 141.6 kg, with a body-mass index of 56. Physical examination revealed no abnormalities aside from her excess weight. The diagnosis of symptomatic gallstone and morbid obesity was made. No other co-morbid condition was found. The patient underwent laparoscopic Roux-en-Y gastric bypass with transgastric circular stapler technique and cholecystectomy. The operation went well without immediate complication. Water soluble contrast study done on the 3rd postoperative day demonstrated no leakage.

Liquid diet was given for two weeks and advanced to soft diet. The patient's weight had decreased 13.6 kg in 3 weeks (BMI from 56 to 50).

MINIMALLY INVASIVE ESOPHAGECTOMY IN A PRONE POSITION

Araya Khaimook¹, Jumpot Borkird²

¹Hatyai Hospital, Songkla, ²Dr. Chamlong's Surgical Clinic, Hatyai, Songkla

This video demonstrates a total esophagectomy for the cancer of middle esophagus at Hatyai Hospital. The surgeon starts the right thoracoscopy with the patient in a prone position. With this position, the surgeon could get better exposure because lung was kept away by the gravity.

Method:

Thoracoscopic esophageal mobilization: The patient is intubated with a double-lumen tube and placed in a prone position, with the surgeon and cameraman standing on the right of the patient. We used 10 mm 0 angle lens and 2 five mm port for dissection.

Laparoscopic gastric mobilization: The patient is placed in a supine position. The surgeon remains on the same place (left of patient). Four or five abdominal ports are used. Then the anastomosis was performed at the neck via a left neck incision.

Summary: Minimal invasive esophagectomy can be done in a patient in a prone position to facilitate esophageal dissection.

SINGLE INCISION LAPAROSCOPIC CHOLECYSTECTOMY BY USING ONLY CONVENTIONAL PORTS AND INSTRUMENTS

Warin Wachirapunyanukul, Songphol Malakorn

Surgical Department, Police General Hospital, Bangkok, Thailand

Background: Now a day Laparoscopic Cholecystectomy is the standard treatment of cholecystitis and symptomatic gallstone. In this last decade, the development in surgical technique is very rapid and useful, especially single incision and single port technique. Mostly we use a very expensive commercial single port which the space between each instrument is not appropriate, causing limitation of movement to the surgeons. Because of those reasons, it is not suitable for use all throughout our country.

Purpose: To show one of our Single Incision Laparoscopic Cholecystectomy technique by using only conventional ports and instruments, that has no limitation of movement and could be simply applied elsewhere in the country

Methods: Skin was incised by curvi-linear subumbilical incision, then extending downward in midline for about 1.5 cm. as a Yshape. Anterior abdominal wall was opened layer by layer with open technique. A plastic bag was inserted into peritoneum cavity along with two conventional 5 mm. instrument ports, one to each end of the subumbilical incision. The camera port was inserted to the lower end of the Yshape incision. Anterior abdominal fascial sheath was sealed, and pneumoperitoneum was created. Cholecystectomy was performed as usual. The abdominal wall was closed in layers with the skin incision closed in either U or V fashion.

Results: Single Incision Laparoscopic Cholecystectomy by using only conventional ports and instruments was done in 27 patients. Three patients were converted to double incisions LC due to marked adhesions. One patient was converted to open LC due to subacute infection and marked adhesion.

Conclusions: By this technique Single Incision Laparoscopic Cholecystectomy could be performed by using only conventional ports and instruments with less limitation of operators' hand movement and with comparable outcome.

REPAIR TRACHEAL INJURY IN THORACOSCOPIC ESOPHAGECTOMY

Jumpot Borkird¹, Araya Khaimook²

¹Dr. Chamlong's Surgical Clinic, Hatyai, Songkla, ²Hatyai Hospital, Songkla

Tracheal injury in esophagectomy is one of fatal complications. We presented video session of repair of tracheal injury by the thoracoscopic approach in a case of carcinoma of mid thoracic esophagus treated by thoracoscopic assisted esophagectomy in a prone position.

Method: This video presented 2 sites of injuries to left main bronchus and findings of air leakage during thoracoscopic assist esophagectomy. The esophagus was firstly divided to obtain good exposure for suture repair of trachea.

Summary: The video explained the surgical approach and technique.

LAPAROSCOPIC PANCREATODUODENECTOMY

Jumpot Borkird¹, Araya Khaimook², Sakda Alapach²

¹Dr. Chamlong's Surgical Clinic, Hatyai, Songkla, ²Hatyai Hospital, Songkla

Laparoscopic surgery is now becoming a worldwide useful treatment of many abdominal operations. For some complex operations this approach remains controversy

regarding benefit over the conventional operations. Pancreaticoduodenectomy is one example of controversies between conventional and minimal invasive procedures (robotic and laparoscopic procedures).

Laparoscopic pancreaticoduodenectomy has been done successfully at the Hatyai Hospital since December 23, 2009. In the early period the operation consumed long operative time, but outcome was acceptable. After the learning curve, we expected shorter operative time. We presented the operative procedure in this video presentation.

Method: This video demonstrated the techniques of laparoscopic pancreaticoduodenectomy. This operation was done in a patient with periampullary carcinoma. In this video the steps in surgical procedure were shown.

Operative steps

1. Freeing distal stomach and duodenum.
2. Dissecting inferior border of pancreas.
3. Dissecting superior border of pancreas.
4. Dissecting second and third part duodenum.
5. Freeing and dividing duodenojejunal junction.
6. Removal of duodenum and head of pancreas.
7. Pancreaticogastrostomy anastomosis.
8. Choledochojejunostomy anastomosis.

Summary: The video explained and demonstrated surgical approach and the steps of operation.

LAPAROSCOPIC SURGERY FOR ADULT INTUSSUSCEPTION

Muyphuag B, Akkaranurakkul P

HRH Princess Maha Chakri Sirinthorn Medical Center, Department of Surgery, Faculty of Medicine, Srinakharinwirot University, Bangkok, Thailand

Background: Adult intussusception is rare. It accounts for 0.003%-0.02% of all adult hospital admissions. In contrast to childhood intussusception, adult intussusception has a demonstrable cause in more than 90% of cases (benign and malignant tumors are most frequent). Presenting symptoms are highly variable. The most common presenting symptoms are colicky abdominal pain, nausea and vomiting. Diagnosis is based on radiologic or surgical findings. Computerized tomography results are pathognomonic and can diagnose intussusception in 72%. Adult intussusception requires surgical intervention because of structural anomalies. Recently, minimally invasive techniques have been applied to the treatment of bowel obstructions, specifically to the diagnosis and treatment of adult intussusception. With advances in laparoscopic surgical techniques, the experienced surgeon can

successfully manage this condition.

Case presentation: A 27-year-old man presented with bouts of abdominal pain with vomiting. Three months before admission, he had colicky pain in the lower abdomen and abdominal mass periodically. Physical examination showed mass (size about 10 cm) at right lower abdomen, firm to hard consistency, with tenderness. A computed tomographic scan of the abdomen showed a thickened segment of bowel with an eccentrically placed crescent-like fatty area. The patient underwent a laparoscopic surgery. The intussusception including the affected loop was resected with an intracorporeal side-to-side anastomosis. There were no postoperative complications and the patient was discharged 7 days later.

Conclusion: Adult intussusception is rare and has a demonstrable cause in more than 90% of cases. Presenting symptoms are variable. Diagnosis is based on radiologic or surgical findings. Computerized tomography results are pathognomonic. This appears either as a round target mass or as a long sausage-shaped mass. Adult intussusception requires surgical intervention. Laparoscopic surgery is now widely used, and its application in this disease is recommended.

LAPAROSCOPIC PLACEMENT OF PERITONEAL DIALYSIS CATHETER WITH ABDOMINAL WALL FIXATION TECHNIQUE UNDER LOCAL ANESTHESIA: INITIAL EXPERIENCE FROM SRINAKARINWIROT UNIVERSITY

Thawatthai Tullavardhana, Prinya Akranurakkul, Withoon Ungkitphaiboon

Department of Surgery, Faculty of Medicine, Srinakharinwirot University, Bangkok, Thailand

Purpose of Study: Peritoneal dialysis is used for renal replacement therapy in end stage renal disease patients. The common problems of peritoneal catheter placement are malfunction and migration of catheter. Moreover, adhesion from previous surgery may lead to difficulty in catheter placement and placement failure. The authors report initial experience in laparoscopic placement of peritoneal dialysis catheter in our institute to resolve the problems.

Method: This procedure was performed under local anesthesia. Nitrous oxide was used for creation of pneumoperitoneum to gain pressure of 8-10 mmHg because it does not induce pain during insufflations and reduced postoperative pain. A peritoneal dialysis catheter is inserted through umbilical port and placement in pouch of Douglas under direct vision from laparoscope. The catheter is fixed

to abdominal wall with prolene 3-0 to prevent catheter migration.

Results: Postoperative radiologic study showed that the catheter was located in proper position. Peritoneal dialysis was started immediately after operation. The patient was discharged from hospital in first postoperative day. No postoperative complication occurred during 2 months of follow-up period.

Conclusion: Laparoscopic placement of peritoneal dialysis catheter with abdominal wall fixation is an effective technique. It can prevent catheter migration and malfunctions and give a chance of peritoneal dialysis in the patient with previous abdominal surgery. This procedure is safe to perform under local anesthesia in combination with Nitrous oxide insufflations for creation of pneumoperitoneum.

THE RESULTS OF ENDOSCOPIC TREATMENT OF BILIARY TRACT COMPLICATIONS OCCURRED AFTER HPB SURGERY. A SINGLE ENDOSCOPIC CENTER EXPERIENCES

Thawatchai Akaraviputh, Nutnicha Suksamannpan, Atthaporn Tragransaga, Wiroom Boonnuch

Minimally Invasive Surgery Center, Department of Surgery, Faculty of Medicine Siriraj Hospital, Mahidol University, Bangkok, Thailand.

Introduction: Although biliary tract complications occurred after hepatopancreaticobiliary (HPB) surgery is an uncommon situation, it may constitute a serious and difficult management problem. Surgical management is associated with high morbidity and mortality. Endoscopic treatment has become the treatment of choice. The study aims to demonstrate the results of endoscopic management in these patients.

Methods: Thirty-two patients with biliary tract complications occurred after HPB surgery (Cholecystectomy 17 cases, Hepatectomy 11 cases, Liver transplantation 4 cases). All patients underwent endoscopic management (Endoscopic retrograde cholangiopancreatography: ERCP) at Siriraj GI Endoscopy Center, Faculty of Medicine Siriraj Hospital, Bangkok, Thailand during 2003 to 2005.

Results: There were 13 males. Mean age was 48.9 yr. (range: 14-71 yr.). Twelve patients with bile leaks occurred in cystic duct (2 patients), common bile duct (4 patients) and intrahepatic duct (6 patients). Of these patients, 20 had bile duct stricture. All patients received diagnostic or therapeutic ERCP procedures. There were 9 patients who endoscopic treatment could not be applied and finally they underwent biliary-enteric anastomosis. There was no mortality in this study.

Conclusion: Endoscopic treatment is safe and effective in the management of biliary tract complications occurred after HPB surgery.

LAPAROSCOPIC SINGLE PORT INTRAPERITONEAL ONLAY MESH (IPOM) IN BILATERAL INGUINAL HERNIA REPAIR USING BIORESORBABLE COMPOSITE MESH

Thanapongsathorn W

HRH Princess Maha Chakri Sirindhorn Medical Center, Department of Surgery, Faculty of Medicine, Srinakharinwirot University, Bangkok, Thailand.

Introduction: Tension free hernia repair using mesh graft is popularized worldwide. Bioresorbable composite mesh is renovated for prevention of bowel adhesion to mesh. Currently, Intraperitoneal Onlay Mesh (IPOM) technique using bioresorbable composite mesh for incisional hernia repair has been increasing in number. But, for inguinal hernia repair is ongoing studied.

Technique: Laparoscopic single port IPOM is done by a 10 mm trocar at umbilicus with one 10 mm hand instrument that has 5 mm optical lens and 5 mm channel for grasper or hernia tacker™.

1. Insert 10 mm trocar at umbilicus using semi-open technique.
2. Identify intraperitoneal anatomical landmark of inguinal hernia :- Triangular of Doom or Square of Doom, Symphysis pubis, Cooper ligament, Iliopubic tract, Anterior superior iliac spine.
3. Placement each hernia opening with an 8 × 15 cm pre-tied bioresorbable composite mesh on three potential area of hernia. (indirect, direct and femoral hernia)
4. Pass Endoclose™ needle through abdominal wall into peritoneal cavity under direct vision, grasp and pull out both end of pre-tied suture in same needle wound, tie the knot and place in subcutaneous space. So, the upper half of mesh is fixed to posterior abdominal wall.
5. Fix the lower half of mesh using hernia tacker™ at Symphysis pubis (medial side), Cooper ligament (lower side), Iliopubic tract (internal ring), Anterior superior iliac spine (lateral side).
6. Remove trocar and make closure of skin.

Case report: A 58 years old Thai man was operated by laparoscopic single port IPOM for bilateral indirect inguinal hernia repair using Parietex™ composite mesh. Operative time was 40 minutes. No immediate complication. No recurrence was found at 4 months follow up.

Conclusion: Laparoscopic single port IPOM is a feasible operation and is much easier to perform and of

more benefit in term of time saving, cosmetic wound, early discharge and early return to work. But bioresorbable composite mesh is much more expensive. The long term follow up have to be studied for complications and recurrence rate.

ENDOSCOPIC MANAGEMENT OF GASTRO-JEJUNOSTOMY OBSTRUCTION BY LARGE GASTRIC BEZOAR

Sunthorn Treesaranuwattana, Taweesak Deekajorn, Choosak Khemtai

St. Mary Hospital, Nakhon Ratchasima, Thailand.

Background: Gastric bezoar commonly occurs in the patients who have impairment of gastric motility following gastric surgery. It may cause gastric outlet obstruction. Method of treatment includes surgical removal, endoscopic removal or fragmentation and dissolution.

Objective: To present the simple endoscopic procedure for treatment of large phytobezoar.

Materials & Methods: A 62-year-old man with history of Billroth II gastrectomy developed severe intermittent abdominal pain which was aggravated by meal and relieved after vomiting. Gastroscopy showed a large and hard phytobezoar in gastric remnant which precluded endoscopic removal or fragmentation. One hundred milliliters of normal saline solution were infused through nasogastric tube every two hours for two days. The repeated gastroscopy revealed that the bezoar was softened that the injection catheter could be deeply punctured into the bezoar, and the disruption occurred following vigorous irrigation through catheter. Forceful impaction by catheter tip could also produce such disruption. Large fragmentations were crushed by mechanical lithotripter and polypectomy snare. All small fragmentations were left in the stomach and efferent jejunal loop. Second look gastroscopy in the next two days showed that there were one third of fragmentations remained in the gastric remnant. They were moved into jejunum by retrieval forceps and lithotripter. Thirty milliliters of emulsified

liquid paraffin and lactulose were infused into jejunum and the clump of fragmentations.

Results: Large amount of small fragmentations were found in his stools in the next morning and the abdominal pain was completely disappeared.

Conclusions: This presented procedure can be the successful treatment for large and hard phytobezoar with simple endoscopic accessories which are generally available in endoscopic unit.

LAPAROSCOPIC PRIMARY REPAIR OF IATROGENIC COLONIC PERFORATION: SURGICAL TECHNIQUE

Thawatchai Tullavardhana, Prinya Akranurakkul, Withoon Ungkitphaiboon

Department of Surgery, Faculty of Medicine, Srinakharinwirot University, Bangkok, Thailand

Purpose of Study: To demonstrate minimally invasive surgical technique for management of iatrogenic colonic perforation.

Case Description: The 50-year-old man underwent elective diagnostic colonoscopy for chronic diarrhea. Colonic perforation was occurring by excessive advancement of colonoscope passing through sigmoid colon. A 1.5-cm tear was found at anti-mesenteric border of sigmoid colon by colonoscopy and patient developed massive abdominal distension. Laparoscopic repair of colonic perforation by intracorporeal simple suture technique was performed immediately.

Result: Operative time was about 45 minutes. The patient was able to start oral diet on first postoperative day and was discharged from hospital on fourth postoperative day without any surgical complication.

Conclusion: Laparoscopic repair by intracorporeal simple suture technique is safe and effective treatment option for the patient with iatrogenic colonic perforation. This surgical procedure brings out the best outcome when performed immediately after colonic perforation is detected.