

# *Breast Biopsy: Accuracy of Core Needle Biopsy Compared with Excisional or Incisional Biopsy: A Prospective Study*

Prakob Luechakietisak, MD<sup>1</sup>  
Pimpattana Rungkaew, MD<sup>2</sup>

<sup>1</sup>Department of Surgery, <sup>2</sup>Department of Pathology, Suratthani Hospital, Suratthani, Thailand

---

## **Abstract**

**Objective:** To determine the accuracy and complications of manual core needle breast biopsy compared with excisional or incisional biopsy.

**Materials and Methods:** Between October 2004-September 2005, core needle breast biopsy was performed in 92 women with suspicious malignancy of the breasts on physical examination. The mean age was 53.9 years (range 38-73 years). Mean tumor size was 3.1 cm (range 1.8-8.2 cm). Pathological findings of core needle biopsy were compared with excisional or incisional biopsy and procedural complications and treatment were noted.

**Results:** Ninety-two core needle biopsies were performed over the period. The histopathologic findings of core needle specimens correlated with those of excisional or incisional biopsy in 85 patients (92.4%). Invasive ductal carcinoma was diagnosed in 79 patients, benign lesion in 6 patients (4 fibroadenoma and 2 fibrocystic disease), with accuracy rate of 92%, sensitivity of 92%, specificity of 100% and over all false-negative rate of 7.6% (7 in 92 patients).

**Conclusions:** In this study, core needle breast biopsy yielded an accuracy rate of 92% compared with excisional or incisional biopsy. There may be a slight higher risk of bleeding which may be related to the lack of breast compression during the procedure.

---

## **INTRODUCTION**

The diagnosis and treatment of breast cancer have undergone a shift during the last 30 years. The trend has been toward earlier diagnosis, less invasive diagnostic procedures and definitive operations. In recent years, the effects of earlier diagnosis have finally led to an overall decreased mortality from breast cancer. Traditionally, a patient would undergo excisional or

incisional biopsy of a breast mass under general anesthesia. If a cancer is found on frozen section, the surgeon would proceed with mastectomy and axillary dissection. However, in recent years carcinoma in situ is often diagnosed and women with early breast cancer are candidates for wide excision and radiation therapy rather than mastectomy. Routine axillary dissection is being replaced by sentinel lymph node biopsy and selective axillary dissection.

The development of biopsy is to make a diagnosis in an awake patient. If the diagnosis is accurate, then the patient can have definitive surgical treatment as an outpatient. If sentinel node biopsy techniques are used in combination with selective axillary dissection, surgery can often be performed with local anesthesia and intravenous sedation. Early stereotactic techniques were problematic. Smaller gauge needles would often undersample the lesions in question and lead to false-negative results. Also, meticulous techniques were required to accurately sample a mammographic abnormality. Core Needle breast biopsy has become an integral part of the work-up for patients with suspicious breast lesions. To our knowledge, the accuracy and complications of core needle breast biopsy have not been addressed specifically in the literature. The objectives of our study were to determine the diagnostic accuracy, sensitivity and specificity of core needle biopsy compared with excisional or incisional biopsy and to identify possible complications of the procedure.

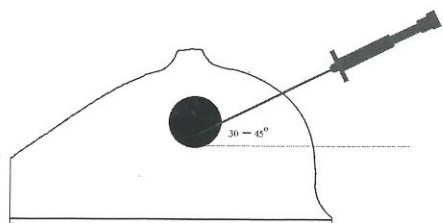
### MATERIALS AND METHODS

From October 2004-September 2005, 92 patients with clinical suggestions of breast carcinoma on physical examination were prospectively studied in the outpatient department, Suratthani Hospital. After sterile technique, local anesthesia was obtained using 1% lidocaine injected into the skin and superficial tissues and within the deeper breast tissues. In the first step, the assistant hold up the breast lesion, core needle biopsy with tangential angle of  $30^{\circ}$ - $45^{\circ}$  was performed. Three to five pieces of specimen were obtained. After that, an excisional or incisional biopsy was then performed. For each lesion, core needle biopsy specimens and excisional or incisional biopsy specimens were submitted for histopathologic

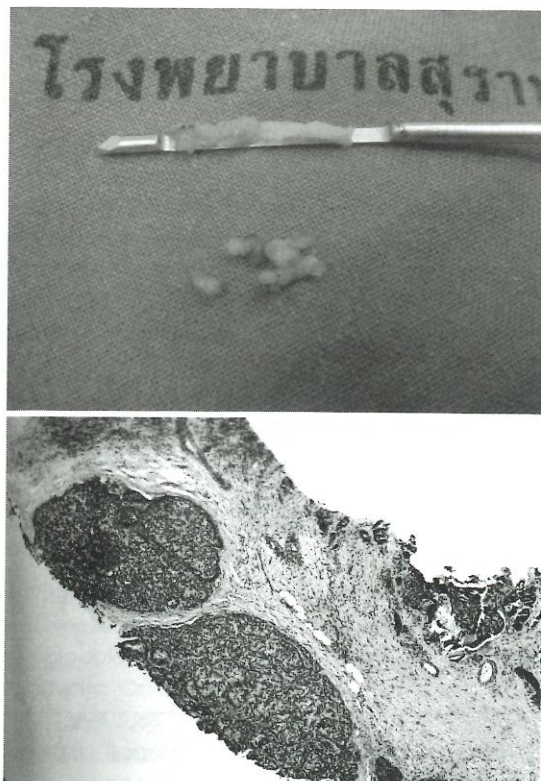
evaluation (Figure 1, 2). The overall accuracy, sensitivity, specificity, positive and negative predictive value were evaluated.

### RESULTS

Ninety-two patients with adequate tissue samples for histopathologic evaluation were included in this study. The mean age was 53.9 years (range 38-73 years) and mean tumor size was 3.1 cm in diameter (range 1.8-8.2 cm). Tumors were mainly in T2 (2-5 cm) which were found in 72 patients (78.26%) and advanced stages (T3, T4) were found in 18 patients (19.56%) (Table 1). Eighty-five patients (92.4%) were correctly diagnosed by core needle biopsy compared with excisional or incisional biopsy. In 79 patients, invasive ductal carcinomas were correctly diagnosed both by core needle and excisional or incisional biopsy. Benign lesions were correctly proved in 6 patients by both techniques (4 patients with fibroadenoma, 2 with fibrocystic disease). Seven of 92 patients (7.6%) were negative for malignancy by core needle biopsy but positive for malignancy by excisional or incisional biopsy (Table 2).



**Figure 1** Direction of core needle biopsy



**Figure 2** Gross and pathological finding of core needle biopsy



## DISCUSSION

A suspicious breast lesion detected on imaging or physical examination needs pathological examination and confirmation before treatments. There are three main types of diagnostic procedures, ie. fine needle aspiration biopsy cytology (FNA), core needle biopsy (CNB) and surgical open biopsy. Each method has both advantages and limitations. Surgical open biopsy often is the most preferable and reliable as it offers a larger specimen for examination, however, it is the most invasive procedure. FNA and CNB are less invasive and may be better cosmetically but the accuracy of diagnostic procedures must be carefully considered before any surgical decisions. The diagnostic accuracy of CNB has been actively verified and several reports were published in the 1990s. These reports were from multiple institutions over the last decade and have

shown good concordance between CNB and surgical biopsy in the diagnosis of carcinoma, ranging from 91-100%.<sup>1-10</sup>

The accuracy of CNB has been confirmed by a large series more recently. Radiologist Investigators of the Fifth Radiologic Diagnostic Oncology Group showed that image-guided core needle biopsy for nonpalpable breast lesions provides high diagnostic accuracy in a large number of cases (N = 2,403).<sup>11</sup> The sensitivity, specificity and accuracy of CNB were 0.91, 1.00 and 0.98, respectively. Another long-term, multi-institutional, prospective study estimated that sensitivity, specificity and accuracy of CNB were 91%-92%, 98%-100% and 96%-97%, respectively (N = 1003).<sup>12</sup> The COBRA (Core Biopsy after Radiological Localization) study group also showed high diagnostic accuracy (N = 973) of large-core needle biopsy for nonpalpable breast disease.<sup>13</sup> The sensitivity and specificity of CNB in this trial were 0.97 and 0.99. In our series, core needle biopsy predict the presence or absence of carcinoma in 85 of 92 cases with an accuracy rate of 92% (95%CI = 0.84-0.97); with discordant results seen in 7 of 92 cases (7.6% false-negative), sensitivity of 92% (95%CI = 0.83-0.96), specificity of 100% (95%CI = 0.52-0.98), positive predictive value of 100% (95%CI = 0.94-1.00), negative predictive value of 46% (95%CI = 0.20-0.74). Most breast cancers contained invasive ductal carcinoma. It was not surprising that core needle biopsy technique may miss an area of invasive

**Table 1** Characteristic of Tumor

Characteristic of Patients	Total (N = 92)
Age (mean)	38-73 (53.9) yrs
Tumor size (mean)	1.8-8.2 (3.1) cm
T1 (<2 cm.)	2
T2 (2-5cm.)	72
T3 (>5 cm.)	10
T4*	8

\*Any T with skin lesion

**Table 2** Histopathologic findings: Core needle biopsy versus excisional or incisional biopsy

Core Biopsy Finding	Excisional or incisional biopsy findings	Total (N = 92)
Invasive ductal carcinoma	Invasive ductal carcinoma	79
Fibroadenoma	Fibroadenoma	4
Fibrocystic disease	Fibrocystic disease	2
Nonspecific benign abnormality	Invasive ductal carcinoma	3
Atypical hyperplasia	Invasive ductal carcinoma	3
Fibroadenoma	Invasive ductal carcinoma	1

**Table 3** Final diagnosis compared with core biopsy finding

Core Biopsy Finding (N = 92)	Final Diagnosis (N = 92)		Total
	Malignant	Benign	
Malignant	79	0	79
Benign	7	6	13
<b>Total</b>	<b>86</b>	<b>6</b>	<b>92</b>



carcinoma, particularly in small lesions. Our study confirms that areas of invasive carcinoma were missed at core needle biopsy in 7 cases where invasive ductal carcinoma was identified at surgical excision. These findings were consistent with report by Jackman, et al<sup>14</sup> who found invasive ductal carcinoma at surgical excision in 8 of 43 lesions in which core needle biopsy yielded ductal carcinoma in situ. Obtaining a larger number of core needle specimens in such cases would increase the chance of finding areas of invasive carcinoma.

There are several factors which may influence diagnostic accuracy. First, the gauge of the needle reflects the total amount of tissue obtained. Among different-gauge needles (14-, 16- and 18-gauge needles) 14-gauge needle provided the most accurate diagnosis both sensitivity and specificity.<sup>15</sup> Second, the number of core biopsy samples taken is also important, the sensitivity for detection of malignancy will increase if multiple core samples are taken (six or more).<sup>8,16</sup> Liberman, et al<sup>17</sup> retrospectively reviewed the number of core needle biopsy in 145 lesions and found that the accuracy of the diagnosis increased by obtaining sequential specimens, as follows: accuracy of the first specimen was 70%, second specimen 81%, third specimen 89%, fourth specimen 91% and fifth specimen 94% and with the addition of a sixth core biopsy in some cases resulted in 97% accuracy. Third, experience of the operator may be another factor.<sup>8</sup> Fourth, the pathological diagnostic agreement was extremely high, except for borderline lesions which could not be resolved even with open biopsies.<sup>18,19</sup> Complications related to the procedure including bleeding and hematoma post biopsy treated by manual compression for not more than 10 minutes, vasovagal response which was not serious and minor complications including bruise and pain were commonly reported in 33%-69% of patients.<sup>14</sup> In this study no serious complications from core needle biopsy were found.

### CONCLUSIONS

Current goal in the diagnosis of breast carcinoma is to establish a definitive diagnosis in the most efficient and cost-effectiveness way. Core needle biopsy is an excellent technique for palpable breast lesion. Core needle biopsy has a high accuracy rate and high

sensitivity and specificity in obtaining a histological diagnosis of breast lesions. We would recommend that this modality be used in patients with palpable breast lesion suspected of malignancy and that it can be performed on outpatient with less and often minor complications.

### REFERENCES

1. Parker SH, Lovin JD, Jobe WE, Burke BJ, Hopper KD, Yakes WF. Nonpalpable breast lesions. Stereotactic automated large-core biopsies. *Radiology* 1991;180:403-7.
2. Dronkers DJ. Stereotaxic core biopsy of breast lesions. *Radiology* 1992;183:631-4.
3. Elvecrog EL, Lechner MC, Nelson MT. Nonpalpable breast lesions. Correlation of stereotaxic large-core needle biopsy and surgical biopsy results. *Radiology* 1993;188:453-5.
4. Parker SH, Burbank F, Jackman RJ, et al. Percutaneous large-core breast biopsy. A multi-institutional study. *Radiology* 1994;193:359-64.
5. Liberman L, Dershaw DD, Rosen PP, et al. Stereotaxic core biopsy of breast carcinoma. Accuracy at predicting invasion. *Radiology* 1995;194:379-81.
6. Meyer JE, Christian RL, Lester SC, et al. Evaluation of nonpalpable solid breast masses with stereotaxic large-needle core biopsy using a dedicated unit. *Am J Roentgenol* 1996;167:179-82.
7. Nguyen M, McCombs MM, Ghandehari S, et al. An update on core needle biopsy for radiologically detected breast lesions. *Cancer* 1996;78:2340-5.
8. Brenner RJ, Fajardo L, Fisher PR, et al. Percutaneous core biopsy of the breast. Effect of operator experience and number of samples on diagnostic accuracy. *Am J Roentgenol* 1996; 166:341-6.
9. Seoudi H, Mortier J, Basile R, Curletti E. Stereotactic core needle biopsy of nonpalpable breast lesions. Initial experience with a promising technique. *Arch Surg* 1998; 133:366-72.
10. Jackman RJ, Nowels KW, Rodriguez-Soto J, Marzoni FA Jr, Finkelstein SI, Shepard MJ. Stereotactic, automated, large-core needle biopsy of nonpalpable breast lesions: False-negative and histologic underestimation rates after long-term follow-up. *Radiology* 1999; 210:799-805.
11. Fajardo LL, Pisano ED, Caudry DJ, et al. Radiologist Investigators of the Radiologic Diagnostic Oncology Group V: Stereotactic and sonographic large-core biopsy of nonpalpable breast lesions. Results of the Radiologic Diagnostic Oncology Group V study. *Acad Radio* 2004;11:293-3084.
12. Brenner BJ, Bassett LW, Fajardo LL, et al. Stereotactic core-needle breast biopsy: A multi-institutional prospective trial. *Radiology* 2001;218:866-72.

13. Verkooijen HM. Core biopsy after Radiological Localisation (COBRA) Study Group: Diagnostic accuracy of stereotactic large-core needle biopsy for nonpalpable breast disease. Results of a multicenter prospective study with 95% surgical confirmation. *Int J Cancer* 2002;99:853-9.
14. Jackman RJ, Nowels KW, Shepard MJ, Finkelstein SI, Marzoni FA Jr. Stereotaxic large-core needle biopsy of 450 nonpalpable breast lesions with surgical correlation in lesion with cancer or atypical hyperplasia. *Radiology* 1994;193:91-5.
15. Nath ME, Robinson TM, Tobon H, Chough DM, Sumkin JH. Automated large-core needle biopsy of surgically removed breast lesions: comparison of samples obtained with 14-, 16, and 18-gauge needles. *Radiology* 1995;197:739-42.
16. Rich PM, Michell MJ, Humphreys S, Howes GP, Nunnerley HB. Stereotactic 14G core biopsy of nonpalpable breast cancer. What is the relationship between the number of core samples taken and the sensitivity for detection of malignancy? *Clin Radiol* 1999;54:384-9.
17. Liberman L, Dershaw DD, Rosen PP, Abramson AF, Deutch BM, Hann LE. Stereotaxic 14-gauge breast biopsy: how many core biopsy specimens are needed. *Radiology* 1994;192:793-5.
18. Collins LC, Connolly JL, Page DL, et al. Diagnostic agreement in the evaluation of image-guided breast core needle biopsies. Results from a randomized clinical trial. *Am J Surg Pathol* 2004;28:126-31.
19. Verkooijen HM, Peterse JL, Schipper MEI, et al. The COBRA Study Group: Interobserver variability between general and expert pathologists during the histopathological assessment of large-core needle and open biopsies of non-palpable breast lesions. *Eur J Cancer* 2003;2187-91.