

Corrosive Injury Induced Gastric Outlet Obstruction in Children: A Case Report

Wannisa Poocharoen, MD

Department of Surgery, Uttaradit Hospital, Uttaradit, Thailand

Abstract

Accidental corrosive ingestion in children is one of the common problems in childhood trauma worldwide. Gastric outlet obstruction is rare, but it is a well-known complication of corrosive acid ingestion. It mostly occurs at the pylorus and antrum due to the pooling of the corrosive agent. However, most reports were in adult patients in which various treatment modalities were used with various outcomes. This report presents a successful experience with a 2-year-old boy with gastric outlet obstruction after an accidental corrosive ingestion. His symptoms developed 7 days after the ingestion. Modified Billroth I was performed at 6 weeks post injury. He was discharged 7 days after surgery with an uneventful post operative course. At present he is asymptomatic and thriving well.

INTRODUCTION

Accidental corrosive ingestion in children is one of the common problems in childhood trauma worldwide. Gastric outlet obstruction is rare, however it is a well-known complication of corrosive acid ingestion. The obstruction mostly occurs at the pylorus and antrum due to the pooling of the corrosive agent and the reflex pyloric spasm of the stomach after the ingestion.¹⁻⁵ However, most reports were in adults where various treatment modalities were used with various outcomes.⁶⁻¹⁰ With lack of experience in children, gastric outlet obstruction is still a challenging problem. This report presents a successful treatment in a 2-year-old boy with gastric outlet obstruction after an accidental corrosive ingestion.

CASE REPORT

A 2-year-old boy was admitted to the pediatric ICU with hematemesis and mild dyspnea a few hours after an accidental ingestion of an unidentified volume of car battery fluid. On physical examination, mild tenderness was noted in the epigastrium. Chest film revealed mild aspiration pneumonia. Endoscopic examination was not done due to lack of equipment. Therefore, he was treated with intravenous (IV) antibiotics, H2-blockers, supplemental oxygen and IV fluids. He was under close observation for early complications especially perforations. He was discharged 4 days later. A week later he was re-admitted with complaints of non-bilious vomiting and dyspepsia. His esophagogram was normal but a near

complete obstruction at the pylorus was observed during the barium studies. Conservative treatment was started with nasogastric decompression, IV antibiotics, steroids, H₂-blockers and total parenteral nutrition given via a central venous catheter. His parents refused a feeding jejunostomy for the patient. He developed a serious gram negative septicemia and was transferred to the pediatric ICU for 2 weeks. He then gradually recovered and gained weight. The second barium study, three weeks after the previous one, revealed an abrupt cut off at the pylorus. (Figure 1, 2A and 2B) He was diagnosed with complete gastric outlet obstruction secondary to corrosive ingestion.

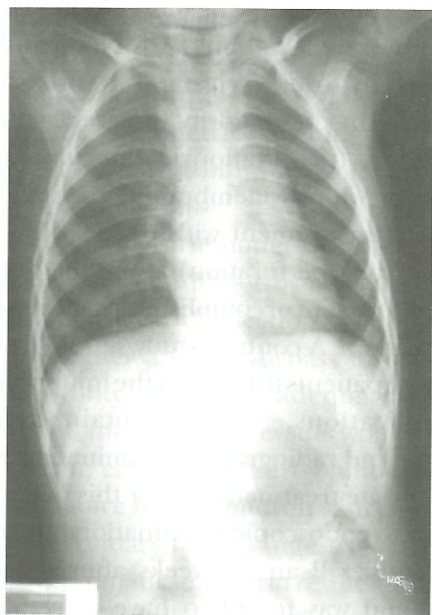


Figure 1 Chest film including upper abdomen shows marked dilatation of the stomach

Six weeks after the accident, he underwent an exploratory laparotomy. The pylorus and the distal part of the antrum were found to become fibrosed, contracted and rigid. The proximal part of the stomach was dilated. Modified Billroth 1 operation (antropyloroplasty with gastroduodenostomy) was performed with truncal vagotomy. Linear stapling device 7.5 mm (GIA, Johnson & Johnson) was used for resection and the staple line was closed with non-absorbable suture material. The gastroduodenostomy anastomosis was performed on the posterior wall of the stomach side to side, double layers (Figure 3A and 3B). The operative time was 3.5 hours with 100 ml of blood loss during surgery. No blood transfusion was required. A nasoduodenal tube was placed for 5 days after that an oral feeding was started.

The patient was discharged 7 days after surgery with an uneventful postoperative course. The pathologic report revealed a complete obstruction of the lumen with areas of necrosis and chronic inflammation in the mucosa and submucosal layer, and also dense fibrosis of the muscular layer. At one-year follow-up, he was asymptomatic and thriving well.

DISCUSSION

Accidental corrosive ingestion in children is one of the common problems in childhood trauma worldwide. More than 100,000 cases in children per year were reported in the USA¹¹ and thousands developed morbidity or mortality. The incidence is still underreported in Thailand. Children under the age of 5 years are most likely to unintentionally ingest

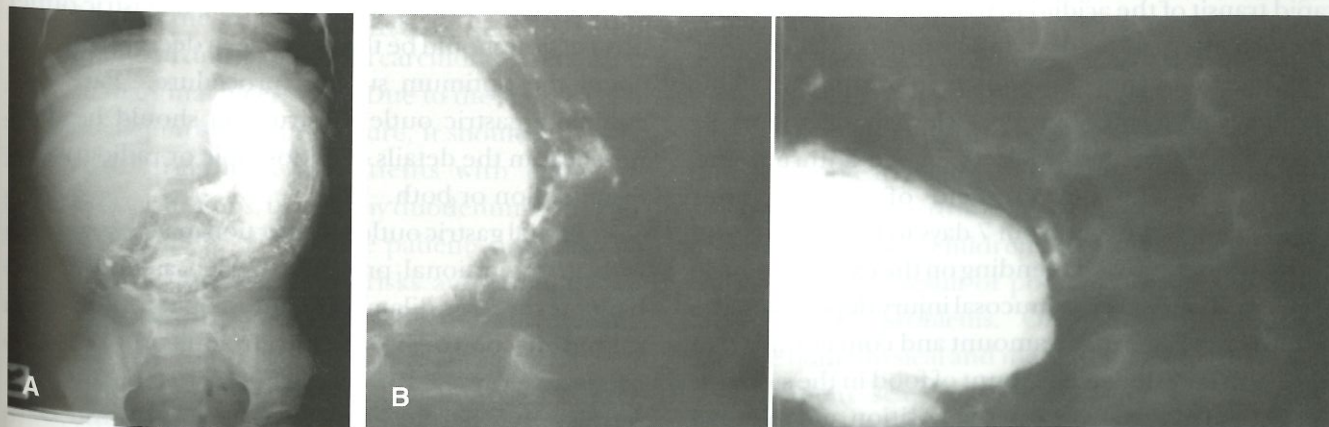


Figure 2 A Upper GI study shows marked dilatation of the stomach with abrupt change in caliber at the prepyloric region.
B Upper GI study shows scanty amount of barium in the duodenum.

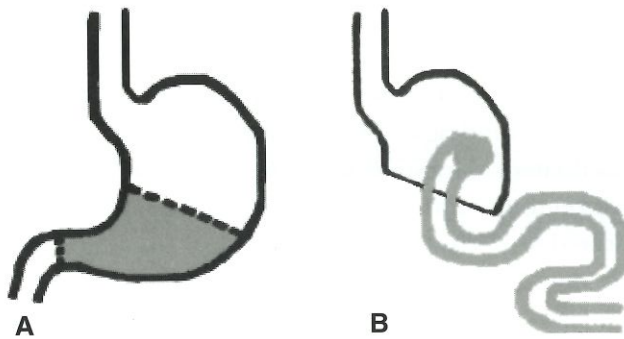


Figure 3 A Outline of the resected area
B Modified Billroth 1 operation

these toxic agents.^{2,4,12} They are prone to this incidence due to their unawareness of danger and their nature of curiosity. Most of the ingested agents are alkali and only about 20% are acidic agents.^{1,4,12} According to Nuutinin et al,¹³ the acidic agents cause burn injuries more often than alkali which more often develop into scars which is a result of coagulation necrosis of the tissue in contact. Severity may vary from no injury to a fatal outcome. One of the most important complications of corrosive acid injuries is gastric outlet obstruction.

Gastric outlet obstruction without esophageal involvement is rare but it is a well-known complication of corrosive acid ingestion, despite the more recent reports of gastric injury caused by alkali corrosives.^{2,5,8} There is a tendency of acids to lick the esophagus and bite the pyloric antrum.¹⁴ The esophagus is spared because of the relative resistance of the squamous epithelium to acid and shorter contact time due to rapid transit of the acidic corrosive agent. Once in the stomach, the acid tends to follow the natural curve of the lesser curvature to pool in the antrum. This pooling is aggravated by reflex pylorospasm, therefore the gastric burns mostly occur in the antrum and pylorus.^{5,15} The development of gastric outlet obstruction may occur from 7 days to 6 years after the corrosive ingestion,⁶ depending on the extent of gastric damage. The degree of mucosal injury depends on the nature of the agent, the amount and concentration of the agent ingested, the amount of food in the stomach at the time of ingestion and the position and mode of ingestion.^{3,5} Symptoms include non-bilious vomiting, post-prandial fullness followed by early satiety and

weight loss.⁶ In this patient, symptoms started 7 days after the corrosive ingestion.

Various treatment modalities have been used to manage corrosive injury-induced gastric outlet obstruction with various outcomes, but most were reports in adult patients.⁶⁻¹⁰ The initial management after the corrosive ingestion is similar. Antibiotics, H₂-blockers are routinely administered but the use of steroid is controversial in some reports.^{2,16} This patient was not given steroid at the first admission due to the vulnerability to infection and UGI bleeding.

The following step should be the assessment of the degree and extent of injury. Endoscopic examination within 48 hours after the corrosive ingestion has been recommended in most studies in patients without known perforation.^{1-10,17,18} Nevertheless, early endoscopy by inexperienced hands could be hazardous.¹⁶ In the majority of cases, patients with grade 2 injury (penetration to the submucosa with ulceration or whitish membranes) or grade 3 injury (transmural involvement with deep injury, necrotic mucosa or frank perforation) are at the greatest risk for the development of complications such as strictures or perforation.¹⁸ A contrast study should be obtained later in these patients to confirm the injury and identify the complications. Details obtained from the endoscopic and radiographic examination will guide the appropriate treatment. As for this patient, he was not subject to endoscopic examination but underwent contrast studies 2 and 5 weeks after the corrosive ingestion and was found to have a near complete pyloric obstruction. Due to lack of experience in children, when gastric outlet obstruction occurs after corrosive acid ingestion, the choice of treatment modality is controversial. The degree of gastric outlet obstruction should be the key issue in decision making about the optimum surgical procedure. Partial or complete gastric outlet obstruction should be diagnosed from the details of endoscopic or radiographic examination or both.

Partial gastric outlet obstruction may be managed with many optional procedures such as endoscopic balloon catheter dilatation, endoscopic intralesional steroid injection or pyloroplasty. In adults, the outcome of endoscopic balloon catheter dilatation and intralesional steroid injection were impressive. The results of combined intralesional steroid injection and balloon dilatation through endoscopy were also

effective.^{7,9,10}

There are not many reports on the treatment of gastric outlet obstruction induced by corrosive injury in children. Erdogan et al. reported a case of pyloric obstruction successfully managed by balloon dilatation.⁴ Pyloroplasty is a safe, simple and fast operative procedure to manage partial gastric outlet obstruction. It is one of the common surgical procedures of choice in many reports of children with corrosive injury-induced partial gastric outlet obstruction.^{2,5} However, there are reports of on-going fibrosis that compromises the gastric outflow resulting in a recurrent gastric outlet obstruction that must be treated again with surgery.^{3,19,20} The long-term sequelae of leaving the fibrotic gastric remaining is still unknown. There are reports of mucosal metaplasia with carcinoma in adults.^{16,19,20} Therefore, these patients must be cautioned for the long-term risks and should have regular follow-up and surveillance endoscopic examination.

For complete gastric outlet obstruction, 2 procedures that are commonly performed include gastroenterostomy and gastric resection. The important question is whether a simple bypass surgery such as gastrojejunostomy would be adequate or partial gastrectomy of the obstructive site would be more suitable. Özcan, et al¹ used gastrojejunostomy as the treatment of choice for all children with gastric outlet obstruction secondary to acid ingestion. This series provided asymptomatic long-term results in all patients (4.8-18.7 years). Chaudhary, et al.²¹ reported that 32% of patients with gastric outlet obstruction underwent gastrojejunostomy without stomal ulcer afterwards. However, gastroenterostomy procedures without resection of the non-viable gastric tissue are not recommended due to the risk of carcinoma, metaplasia and late marginal ulcers.^{5,19,20} Due to the simplicity of the gastrojejunostomy procedure, it should be a safe alternative treatment in patients with extensive perigastric adhesions, unhealthy duodenum and poor general condition.^{17,21,22} These patients must also be cautioned for the long-term risks and should have regular follow-up and surveillance endoscopic examination.

Distal gastric resection such as Billroth I (antropylorctomy with gastroduodenostomy) is a classic treatment for corrosive injury induced gastric outlet obstruction. It is recommended for severely injured

mucosa with complete pyloric obstruction. Billroth I procedure is a major operation and many surgeons have doubts about risk and benefit, especially in children. Billroth I procedure removes the devitalized and fibrotic tissue of the stomach which has the potential for malignant transformation. Therefore, it is a surgical procedure of choice in both adult and children. According to Kaushik, et al.⁶ gastric resection to remove the scarred stomach is preferred and Billroth I was favored with good results. Ciftci et al,⁵ Tekant et al,³ and Erdogan et al.⁴ preferred Billroth I procedure in children with gastric outlet obstruction and their results were uneventful.

In this patient, Billroth I was chosen according to the radiographic and intra-operative findings. The side-to-side gastroduodenal anastomosis was performed. With the concern of anastomotic leakage, it was modified from the original end to end technique. Linear stapling device was used to facilitate the operation. The operative time was shorter and blood loss was reduced. At 1-year follow-up visit, he was asymptomatic and thriving well. Therefore, with meticulous modern surgical techniques, safe anesthesia and good pediatric intensive care, excellent results would be obtained in children with corrosive injury-induced gastric outlet obstruction.

CONCLUSION

Corrosive injury induced gastric outlet obstruction should be managed surgically. The type of surgery depends on the endoscopic and radiological evaluation and findings on laparotomy. Billroth I procedure is recommended for severely injured mucosa with complete pyloric obstruction. With a meticulous approach, Billroth procedure can be performed safely with excellent results. Routine follow-up should be advised in order to assure the normal gastrointestinal function and early detection of late complications.

Accidental corrosive ingestion is still one of the tragic incidences in children especially in developing countries, as the result of poor education and other socioeconomic problems. Other than the potential damage both physical and mental to the child, it leaves a permanent scar in the hearts of the parents. Therefore, no treatment in any modality is better than prevention. Public awareness promoted by both government and private sectors is the key to this issue.

REFERENCES

- Özcan C, Ergün O, Sen T, Mutafo O. Gastric outlet obstruction secondary to acid ingestion in children. *J Pediatr Surg* 2004;39:1651-3.
- Dogan Y, Erkan T, Çokugras FC, Kutlu T. Caustic gastroesophageal lesions in childhood: An analysis of 473 cases. *Clin Pediatr* 2006;45:435-8.
- Tekant G, Eroglu E, Erdogan E, et al. Corrosive injury-induced gastric outlet obstruction: A changing spectrum of agents and treatment. *J Pediatr Surg* 2001;36:1004-7.
- Erdogan E, Eroglu E, Tekant G, et al. Management of esophagogastric corrosive injuries in children. *Eur J Pediatr Surg* 2003;13:289-93.
- Ciftci AO, Senocak ME, Büyükpamukçu N, Hıçsönmez A. Gastric outlet obstruction due to corrosive ingestion: incidence and outcome. *Pediatr Surg Int* 1999;15:88-91.
- Kaushik R, Singh R, Sharma R, Attri AK, Bawa AS. Corrosive-induced gastric outlet obstruction. *Yonsei Med J* 2003;44:991-4.
- Kochhar R, Sethy PK, Nagi B, Wig JD. Endoscopic balloon dilatation of benign gastric outlet obstruction. *J Gastroenterol Hepatol* 2004;19:418-22.
- Agarwal S, Sikora SS, Kumar A, Saxena R, Kapoor VK. Surgical management of corrosive strictures of stomach. *Indian J Gastroenterol* 2004;23:178-80.
- Solt J, Bajor J, Szabó M, Horváth OP. Long-term results of balloon catheter dilatation for benign gastric outlet stenosis. *Endoscopy* 2003;35:490-5.
- Kochhar R, Sriram PV, Ray JD, Kumar S, Nagi B, Singh K. Intralesional steroid injections for corrosive induced pyloric stenosis. *Endoscopy* 1998;30:734-6.
- Litovitz TL, Schmitz BF, Bailey KM. Annual report of the American Association of Poison Control Centers National Data Collection System. *Am J Emerg Med* 1990;8:394-442.
- Huang YC, Ni YH, Lai HS, Chang MH. Corrosive esophagitis in children. *Pediatr Surg Int* 2004;20:207-10.
- Nuutinen M, Uhari M, Karvali T, Kouvalainen K. Consequences of caustic ingestions in children. *Acta Paediatr* 1994;83:1200-5.
- Marks IN, Banks S, Werbeloff L, Farman J, Louw JH. The natural history of corrosive gastritis: Report of five cases. *Am J Dig Dis* 1963;8:509-24.
- Brown RA, Millar AJ, Numanoglu A, Rode H. Y-V advancement antropyloroplasty for corrosive antral strictures. *Pediatr Surg Int* 2002;18:252-4.
- Keh SM, Onyekwelu N, McManus K, McGuigan J. Corrosive injury to upper gastrointestinal tract: Still a major dilemma. *World J Gastroenterol* 2006;12:5223-8.
- Tseng YL, Wu MH, Lin MY, Lai WW. Early surgical correction for isolated gastric stricture following acid corrosion injury. *Dig Surg* 2002;19:276-80.
- Kay M, Wyllie R. Caustic ingestions and the role of endoscopy (Editorials). *J Pediatr Gastroenterol Nutr* 2001;32:8-10.
- McAuley CE, Steed DL, Webster MW. Late sequelae of gastric acid injury. *Am J Surg* 1985;149:412-5.
- Kennedy SC, Bavaki AE. Corrosive damage to stomach stimulating carcinoma. *Br Med J* 1967;4:93-4.
- Chaudhary A, Puri AS, Dhar P, et al. Elective surgery for corrosive-induced gastric injury. *World J Surg* 1996;20:703-6.
- Hsu CP, Chen CY, Hsu NY, Hsia JY. Surgical treatment and its long-term result for caustic-induced prepyloric obstruction. *Eur J Surg* 1997;163:275-9.