

The Power Setting of Endovenous Microwave Ablation for the Treatment of Varicose Vein: In Vitro Study

Pruittipong Khantiworapong, MD
Somboon Subwongchareon, MD
Pasu Sukheepot, MD
Nipon Praditphol, MD

Division of General Surgery, Department of Surgery, Rajavithi Hospital, Bangkok, Thailand

Abstract

Introduction: Traditional treatment of greater saphenous vein (GSV) reflux has been surgical removal of the GSV. Ablation of the vein by endovenous laser therapy (EVLT) and radiofrequency endovenous ablation (VNUS Medical Technologies) are newer techniques which are less invasive and with lower complication rates. Microwave ablation is a sub-type of radiofrequency which has the same characteristic as radiofrequency ablation. This study aimed at finding the appropriate power setting of microwave ablation applied for the treatment of varicose vein that has no further damage to other surrounding tissue.

Material and Methods: Two patients with symptoms of varicose vein were enrolled in this study. Greater saphenous vein (GSV) stripping was performed and the veins were used for this study. Six segments of 10 cm long of greater saphenous veins were inserted into the subcutaneous layer which adhered to muscle layer of swine model via the probe. The swine meat was divided into 6 groups. Heparinized blood was filled into the lumen of greater saphenous vein of each group. Microwave generator (MICROTAZE OT -110M) with catheter was used in this study. The cut pieces were labeled as C (control), S (sham), 40, 50, 60 and 70. No additional procedure was performed in group C. Endoluminal microwave catheter was applied with power generator at 0, 40, 50, 60 and 70 Watts in group S, 40, 50, 60 and 70 respectively. Endoluminal microwave catheter was pulled back at 0.5 cm per 10 seconds. The swine meat in each group was sent for pathological examination and was each sectioned into 10 pieces.

Results: Normal venous walls were found in C and S group. In 40 Watt group, the burning depth to tunica adventitia was found in 5 of 10 pieces. In 50 Watt group, the burning depth to tunica adventitia was found in 9 of 10 pieces with 20% circumferential extra luminal tissue damage (mean distance 897 ± 942.98 micron). In 60 Watt group, the burning depth to tunica adventitia was found in all 10 pieces with 75% circumferential extraluminal tissue damage (mean distance 843 ± 343.65 micron). In 70 Watt group, the burning depth to tunica adventitia was found in all 10 pieces with 51% circumferential extraluminal tissue damage (mean distance 1207 ± 953.79 micron).

Discussion: The appropriate power setting of endovenous microwave ablation for the treatment of varicose vein should be in the range of 50-60 Watts which gives best result by causing venous tissue damage of all layer with minimal extraluminal tissue damage.

Correspondence address : Pruittipong Khantiworapong, MD, Division of General Surgery, Department of Surgery, Rajavithi Hospital, Bangkok 10400, Thailand. E-mail: prkh1@hotmail.com

INTRODUCTION

Venous insufficiency from superficial reflux through varicose veins is a serious problem and is usually progressive if left untreated. Traditional treatment of greater saphenous vein (GSV) reflux has been surgical removal of the GSV. Although surgical ligation and stripping of the GSV has been the most widely accepted treatment, it is associated with significant morbidity and a prolonged recovery period. Ablation of the vein by endovenous laser therapy (EVLT)¹⁻⁸ and radiofrequency endovenous ablation⁹⁻¹¹ (VNUS Medical Technologies) are newer techniques which are less invasive with lower complication rates. These procedures are well tolerated by patients and give good cosmetic results.¹²⁻¹⁶

Radiofrequency endovenous ablation (VNUS Medical Technologies) works by thermal destruction of venous tissues. Electrical energy passes through the tissues in the form of high-frequency alternating current and is converted into heat which causes irreversible localized tissue damage. Radiofrequency energy is delivered through a special catheter with deployable electrodes at the tip; the electrodes touch the vein walls and deliver energy directly into the tissues without coagulating blood. During the procedure, the temperature within the vessel wall is limited to 85 °C to avoid thermal injury to the surrounding tissues.

Microwave ablation is a sub-type of radiofrequency ablation which has the same characteristic as radiofrequency ablation. Microwave ablation is commonly used for hemostasis and coagulation and is now widely used in the treatment of liver tumors.¹⁷

This study aimed to find out the appropriate power setting of microwave ablation which gives the best results in the treatment of varicose vein and causes no further damage to other surrounding tissue.

MATERIAL AND METHODS

The study was performed at Rajavithi Hospital from January to March 2006. Two patients were treated for varicose vein by greater saphenous vein (GSV) stripping. After stripping, the specimens of greater saphenous vein (GSV), about 30 cm in length each, were used in this study.

Pieces of greater saphenous vein were inserted via a probe into the subcutaneous layer of a swine model (10 cm long) which adhered to the muscle layer.

Heparinized blood was filled into the lumen of greater saphenous vein of all groups.

Microwave generator (MICROTAZE OT-110M, surgical equipment which uses the dielectric heating energy that occurs in the tissue after focusing and radiating microwave of 2,450 Hz to generate output power of 10-110 Watts) and catheter were used in this study (Figure 1 and 2).

The swine meat was divided into 6 groups; C (control), S (sham), 40, 50, 60 and 70 Watts. No additional procedure was done in group C. Endoluminal microwave catheter was applied with power generator at 0, 40, 50, 60 and 70 Watt in group S, 40, 50, 60 and 70, respectively. Endoluminal microwave catheter was pulled back at the interval of 0.5 cm per 10 seconds.

Each labeled swine meat was sent for pathological examination and was sectioned into 10 pieces. Pathological report would include layer of greater saphenous vein with coagulation necrosis, percentage of extraluminal damage area (along circumference) and maximum distance of extraluminal burn.



Figure 1 The microwave power generator (MICROTAZE OT-110M)

Statistical analysis

All collected data was analyzed with SPSS program and expressed as mean \pm SD and percentage.

RESULTS

Normal venous walls were found in C and S group. In 40 Watt group, the burning depth to tunica

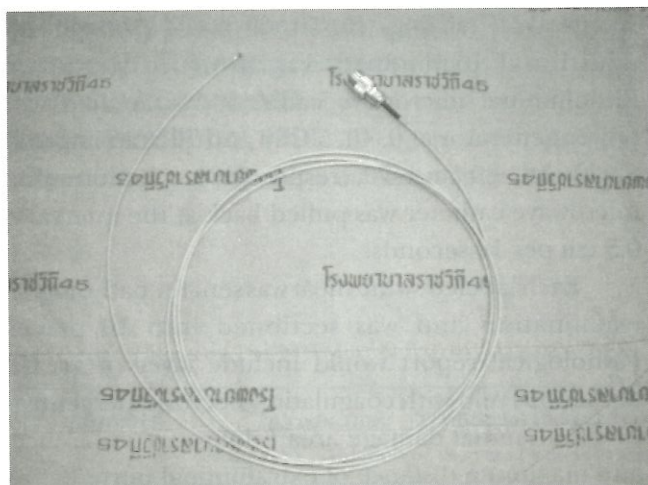


Figure 2 The microwave catheter

adventitia was found in 5 of 10 pieces with 5% extraluminal tissue damage (mean distance 105 ± 245.45 micron). In 50 Watt group, the burning depth to tunica adventitia was found in 9 of 10 pieces with 20% extraluminal tissue damage (mean distance 897 ± 942.98 micron). In 60 Watt group, the burning depth to tunica adventitia was found in all 10 pieces with 75% extraluminal tissue damage (mean distance 843 ± 343.65 micron). In 70 Watt group, the burning depth to tunica adventitia was found in all 10 pieces with 51% extraluminal tissue damage (mean distance 1207 ± 953.79 micron) (Table 1 and 2, Figure 3-7).

DISCUSSION

Minimally invasive technique for the treatment of varicose vein has many advantages for patients with GSV reflux, such as the better cosmetic results, the reduction of postoperative pain and less hospital stay. The outcome in 2-year follow-up is equal. Nowadays, endovenous laser therapy (ELVT) and radiofrequency endovenous ablation play an important role in the treatment of varicose vein.^{12,10}

Table 1 Showing number of specimens with intraluminal burn depth and extraluminal burn in 6 groups. (n = 10 in each group)

Group (n = 10)	Intraluminal burning depth			Extraluminal Burn*
	Tunica intima	Tunica media	Tunica adventitia	
Control	0	0	0	0
Sham	0	0	0	0
40 watts	10	5	5	2
50 watts	10	1	9	6
60 watts	10	10	10	10
70 watts	10	10	10	9

*extraluminal burn = burning of tissue outside tunica adventitial layer of venous wall

Table 2 Showing mean of circumferential extraluminal tissue damage (percentage of circumference) and extraluminal burn distance (micron)

Group	Mean	Extraluminal tissue damage* (percentage along circumference)	Extraluminal burn distance (micron)
Control		0	0
Sham		0	0
40 watts (n = 2)		5 ± 10.54 (25)	105 ± 245.45 (300-750)
50 watts (n = 6)		20 ± 19.72 (25-50)	897 ± 942.98 (550-2425)
60 watts (n = 10)		75 ± 28.16 (25-100)	843 ± 343.65 (250-1375)
70 watts (n = 9)		51 ± 33.91 (25-100)	1207 ± 953.79 (575-3125)

*Percentage of extraluminal tissue burn compared with venous circumferential line

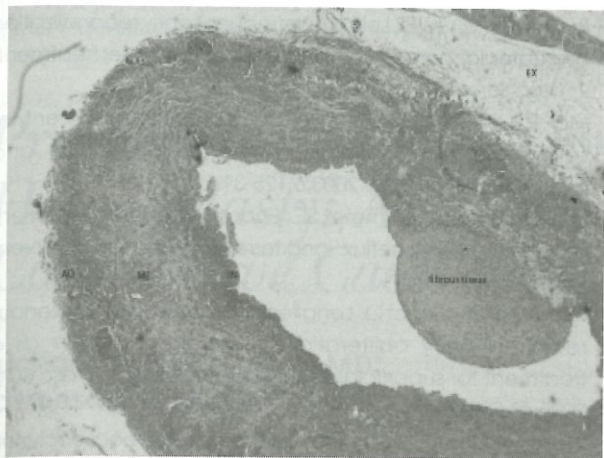


Figure 3 Showing varicose vein with no tissue damage. (IN = tunica intima, ME = tunica media, AD = tunica adventitia, Fibrous tissue = fibrous tissue commonly found in varicose vein, EX = extraluminal tissue)




Figure 5 Showing damage of tunica media with pyknotic nuclei characteristic (nucleus of cell in tunica media layer stained blue color representing cell death)

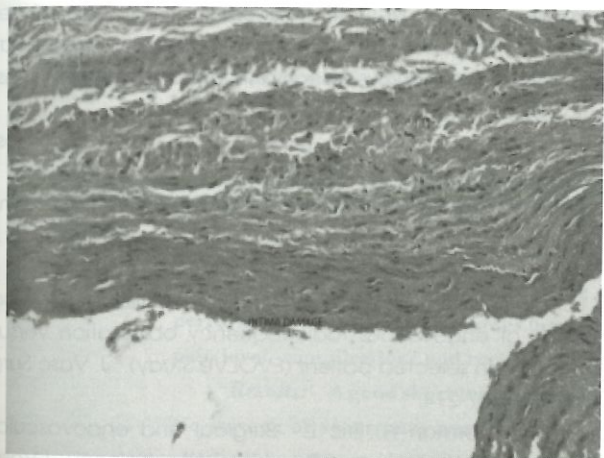


Figure 4 Showing damage of tunica intima (loss of endothelial cell and reposition with RBC)

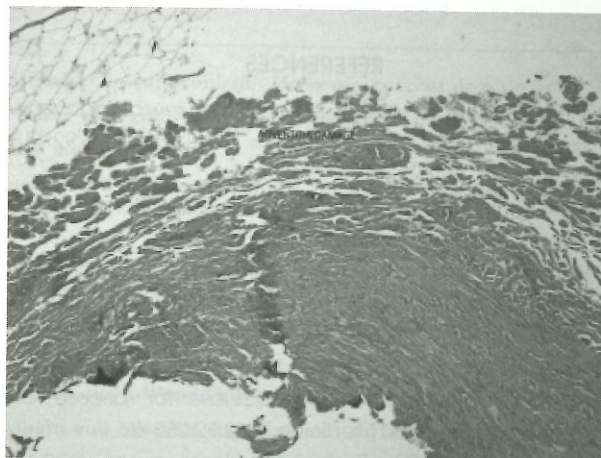


Figure 6 Showing coagulation necrosis and loss of continuity of tunica adventitia tissue

Endovenous microwave ablation is a newer technique adapted from microwave ablation which is commonly used in surgery with low cost compared with other two procedures. Catheters used in this study adapted from microwave coagulation probe for the treatment of UGI bleeding.¹⁷

From the results of this study, the appropriate setting of microwave endovenous ablation is between 50-60 Watts. This setting gives the best results in burning all 3 layers of varicose vein (tunica intima, media and adventitia) and causing total shrinkage of varicose vein. This 50-60 Watt setting will also make extraluminal tissue burn but the mean distance of burn from the outer surface of vein is just only 0.8 mm.

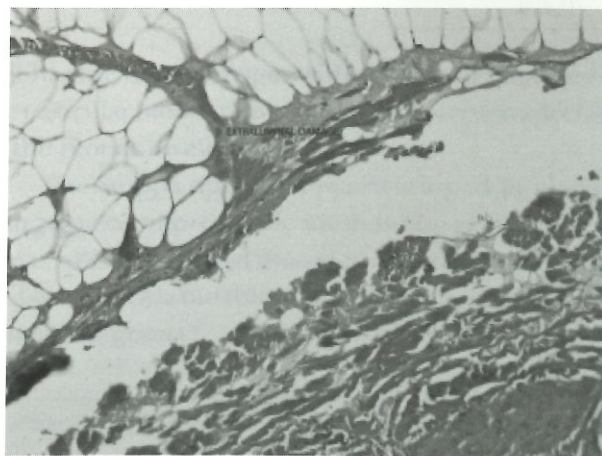


Figure 7 Showing extraluminal tissue damage (coagulation necrosis of muscle cell around venous wall)

The percentage of extraluminal burn compared with circumferential line is low in 70 Watt setting compared with 60 Watt setting but the severity is higher. Some specimens of 70 Watt setting showed complete disruption of venous wall which did not occur in 60 Watt setting.

From this study, the endovenous microwave ablation may be used safely in human with appropriate setting.

At Rajavithi hospital, based on this study and with the informed consent, endovenous microwave ablation has been used to treat GSV reflux in 5 patients. There have been no immediate postoperative complications and no recurrences of disease in the 3-month follow-up.

REFERENCES

1. Mundy L, Merlin TL, Hiller JE. Systematic review of endovenous laser treatment for varicose veins. *Brit J Surg* 2005;92:1189-94.
2. Min RJ, Khilnani NM. Endovenous laser ablation of varicose vein. *J Cardiovasc Surg* 2005;46:395-405.
3. Proebstle TM, Moeler T, Gul D, Herdemann S. Endovenous treatment of Great Saphenous Vein using a 1,320 nm Nd:YAG laser cause fewer side effect than using 940 nm Nd:YAG laser. *Dermatol Surg* 2005;31:1678-84.
4. Chang CJ, Chua JJ. Endovenous laser for varicose veins. *Laser in Surgery and Medicine* 2002;32:257-62.
5. Navarro L, Min RJ. Endovenous laser, a new minimally invasive method of treatment of varicose veins - preliminary observations using a 810 nm diode laser. *Dermatol Surg* 2001;27:117-122.
6. Proebstle TM, Gul D, Lehr HA. Infrequent early recanalization of greater saphenous vein after endovenous laser treatment. *J Vasc Surg* 2003;38:511-6.
7. Min RJ, Khilnani NM. Endovenous laser treatment of saphenous vein reflux. *Technique in Vascular and Interventional Surgery* 2003;6:125-31.
8. Min RJ, Khilnani N, Zimmet SE. Endovenous laser treatment of saphenous vein reflux: long term results. *J Vasc Intervent Radiol* 2003;14:991-9.
9. Merchant RF, Pichot O. Long term outcomes of endovenous radiofrequency obliteration of saphenous reflux as a treatment for superficial venous insufficiency. *J Vasc Surg* 2005;42:502-9.
10. Weiss RA. Controlled radiofrequency endovenous occlusion using a unique radiofrequency catheter under duplex guidance to eliminate saphenous varicose vein reflux. A 2-year follow-up. *Dermatol Surg* 2002;28:38-42.
11. Wagner WH, Levin PM, Cossman DV, Cohen JL. Early experience with radiofrequency ablation of greater saphenous vein. *Ann Vasc Surg* 2004;18:42-7.
12. Paggioni A, Kalra M, Carno M, Mozes G. Endovenous laser therapy and radiofrequency ablation of the great saphenous vein: analysis of early efficacy and complications. *J Vasc Surg* 2005;42:488-93.
13. Morrison N. Saphenous ablation: what are the choices, Laser or RF. *Sem Vasc Surg* 2005;18:15-8.
14. Perrin M. Endoluminal treatment of lower limb varicose veins by endovenous laser and radiofrequency techniques. *J Phleb* 2005;19:170-8.
15. Lurie F, Creton D, Ekof B, Pichot O. Prospective randomized study of endovenous radiofrequency obliteration versus stripping in selected patient (EVOLVE Study). *J Vasc Surg* 2003;38:207-214.
16. John J, Norman H, Eric L. Surgical and endovascular treatment of lower extremities venous insufficiency. *J Vasc Intervent Radiol* 2002;13:563-58.
17. Simon CJ, Dupuy DE, Mayo-Smith W. Microwave ablation: principles and applications. *J Radiograph*. 2005;25:69-83.