

# *An Aesthetic Technique for Complete Removal of a Sebaceous Cyst through a Small Elliptical Incision*

**Arthi Kruavit, MD**

Division of Plastic and Maxillofacial Surgery, Department of Surgery, Ramathibodi Hospital, Faculty of Medicine, Mahidol University, Bangkok 10400, Thailand.

---

**Abstract:**

**Objective:** An aesthetic technique is described for one-stage complete removal of a sebaceous cyst through a 1-2 × 3-4 mm elliptical incision around the punctum of the cyst and parallel to the skin crease.

**Methods:** The procedure is performed under local anaesthesia with the use of vasoconstrictive effect of the epinephrine and hydrodissection of the anaesthetic solution. One or two interrupted stitches are usually required for wound closure with everted wound margins.

**Results:** The postoperative results were uneventful with no recurrence. The aesthetic results were found to be very satisfactory and no patients required scar revisions.

**Conclusion:** This technique is simple and easy and it is highly recommended to all doctors.

---

## **INTRODUCTION**

When a sebaceous cyst which is a very common surgical condition is diagnosed, its complete removal demands aesthetically inconspicuous scar especially when the cyst is located on the face or any area of the body of a patient with scar conscious. A number of techniques had been reported for removal of sebaceous cysts to leave minimal surgical scars. Patton<sup>1</sup> in 1963 described the use of a trephine before subsequent excision. Vivakananthan<sup>2</sup> in 1972 advised an oval or a circular skin incision no more than 2-3 mm in diameter around the punctum and the contents of the cyst were removed by suction and squeezing. The wound was closed with one or two buried catgut sutures without drainage. O'Keeffe<sup>3</sup> in 1972 and Richards<sup>4</sup> in 1985

used skin punches for trephining sebaceous cysts and left the wounds unsutured to allow drainage of the contents of the cysts. The wounds were closed within 2 weeks and some patients later required scar revisions. Moore and Greer<sup>5</sup> in 1975 employed mini-incisions combined with 5% phenol solution; great care was taken to avoid phenol damage to the skin. Avakoff<sup>6</sup> in 1989 wrote a letter to the editor describing micro-incision for removing sebaceous cysts. However, the incision was about  $\frac{1}{4}$  inch (7 mm) long and the wound was not closed. Neither of those techniques mentioned the advantages of hydrodissection effect of adequate amount of local anesthetic solution containing epinephrine all around the cyst wall.

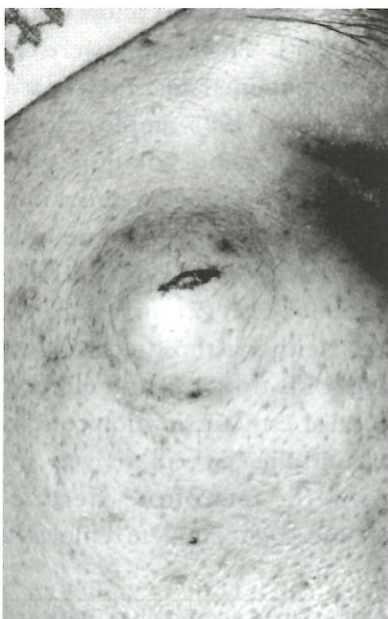An aesthetic technique described below demonstrates one-stage complete removal of sebaceous

cysts through small elliptical incisions under local anaesthesia with the use of hydrodissection and vasoconstrictive effect of the anaesthetic solution.

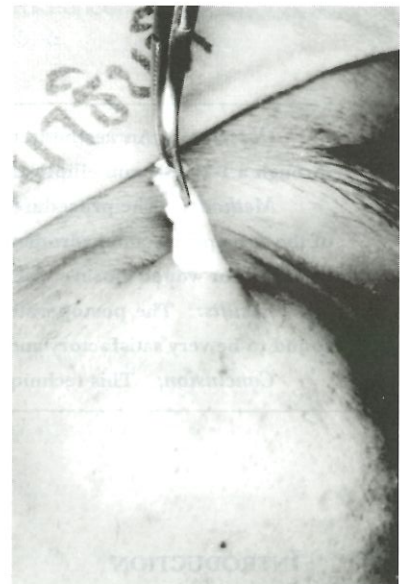
### OPERATIVE TECHNIQUE

Under aseptic and antiseptic techniques, a small elliptical incision of 1-2 mm wide and 3-4 mm long is marked with gentian violet or methylene blue around the punctum of a noninfected sebaceous cyst, no matter what size the cyst is (Figure 1). The long axis of the ellipse is always parallel to the skin crease. Local infiltration with 5-20 cc of 1% lidocaine (xylocaine) with 1:200,000 epinephrine (adrenaline) is adequately employed on the convex skin surface, around and deep to the cyst to produce a field block and hydrodissection. When the skin over the cyst becomes blanching due to vasoconstrictive effect of the epinephrine, an elliptical incision is made on the marked area and deep through the top wall of the cyst. The punctum is removed together with a small piece of the skin ellipse. The small opening of the cyst is again punctured and minimally dilated deep to its content with a small arterial forceps. With light pinching pressure of the thumb and index finger applied around the cyst, the sebum within the cyst wall is thus squeezed

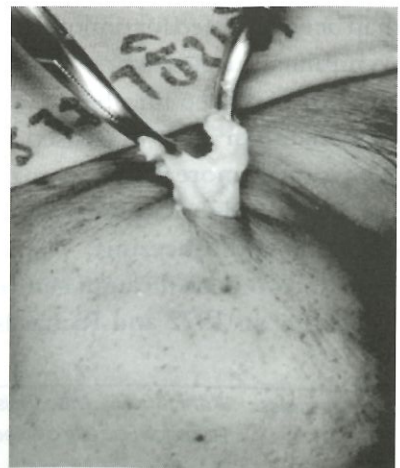out as much as possible at various angles. The top margin of the cyst wall around the opening of the cyst is exposed as a whitish tissue and is clamped with an arterial forceps. An iris scissors is used to carefully dissect the uppermost cyst wall free from the surrounding subcutaneous tissue in the correct plane. The arterial forceps holding the cyst wall is gently pulled out (Figure 2). Another arterial forceps takes turn, little by little, to pull out more cyst wall until it is completely removed without any active bleeding (Figure 3). However, hemostasis, if necessary, can be



**Figure 1** An elliptical incision of 1-2 mm wide and 3-4 mm long is marked around the punctum and its long axis is parallel to the skin crease.

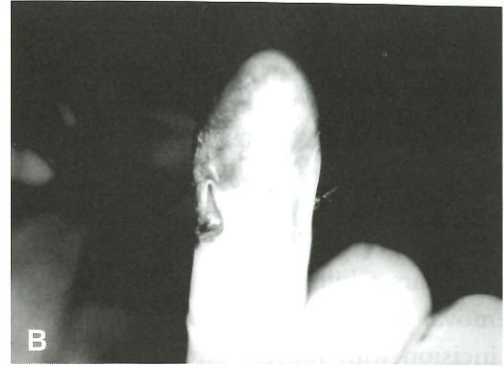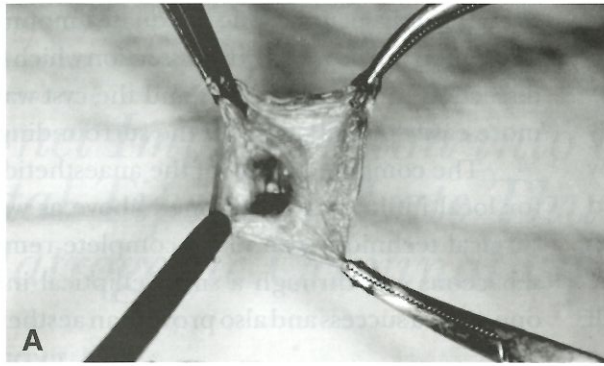


**Figure 2** Demonstrating the blanching over the sebaceous cyst due to vasoconstrictive effect of the epinephrine. One arterial forceps holding the cyst wall is gently pulled out.

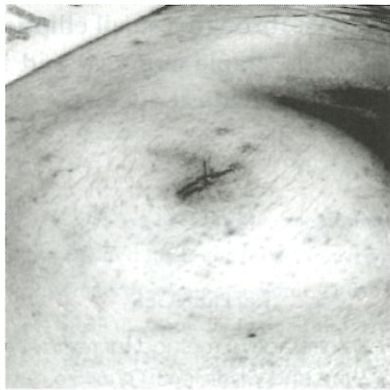


**Figure 3** Two arterial forceps are pulling the cyst wall out.





**Figures 4 A, B** Demonstrating complete removal of the cyst wall.

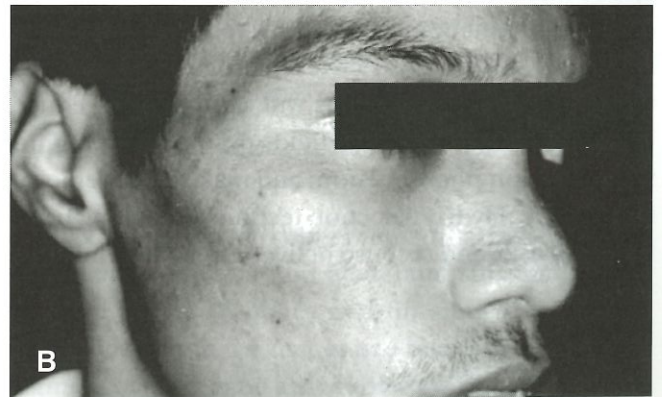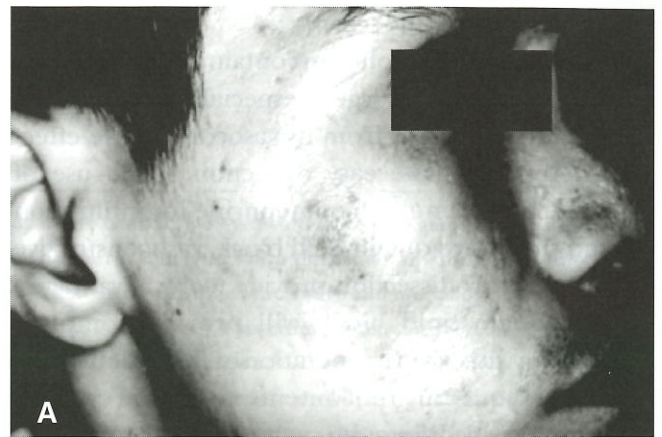


**Figure 5** Immediately after surgery with one stitch closure.

obtained only by temporary light pressure dressing. No electric cautery is used. Following complete removal of the cyst wall, a sac of the cyst wall can be demonstrated (Figures 4A, B). The redundant skin which is stretched, like the anterior abdominal wall of a pregnant woman or an expanded tissue, will shrink and later contract. The wound is loosely closed for access of any drainage with one or two stitches of 6/0 monofilament suture material just to keep the wound margins everted. No stitch is often required for a cyst smaller than one centimetre in diameter. Compressive dressing (not pressure dressing) is applied to the wound. No postoperative antibiotic is employed. Stitches are removed within 7 days. It should be noted that removal of a sebaceous cyst at the back is sometimes more difficult with this technique because of thick skin and thus extended incision is required to finish the procedure.

## RESULTS

During 1987-2006, the author had been using this



**Figures 6 A** 1 month after the operation,  
**B** 8 months after the operation.

one-stage technique to completely remove quite a number of sebaceous cysts of all sizes varying from less than one centimetre to four centimetres in diameter. The postoperative results had been uneventful and no patient developed hematoma, infection or recurrence. The aesthetic results were found to be very satisfactory and no patients required scar revisions (Figures 6 A, B).

## DISCUSSION

Wound healing by secondary intention is always found when an abscess is incised and adequately drained. It will heal, like an unsutured wound, by granulation tissue formation causing wound contraction, and epithelialization. Some develop pitted scars ie. acne scars, while some develop hypertrophic scars. Removal of a sebaceous cyst through a small elliptical incision with loosely direct closure of the wound margins to keep the wound margins everted and to obtain contact inhibition of the epidermis can minimize the development of a pitted scar, a depressed scar or a hypertrophic scar.

The anaesthetic solution containing epinephrine has long been used in surgery, especially facial surgery, to provide hemostasis from its vasoconstrictive effect in order to facilitate easy dissection. The use of adequate lignocaine with epinephrine for infiltration around the cyst to obtain field block, vasoconstrictive effect and hydrodissection provide many advantages. The adequate field block will provide complete anaesthesia with good cooperation of the patient while satisfactory squeezing of contents within the cyst wall can be achieved. When the cyst wall is nearly empty, it can be completely and easily removed through a small incision. The vasoconstrictive effect of the epinephrine which enhances hemostasis will significantly reduce bleeding at the operative field, despite its rebound vasodilatation phenomenon, and make a cyst removal more easily. Hydrodissection technique has long been used in plastic and reconstructive surgery as an adjunct

to surgical dissection. The adequate amount of local infiltration will provide hydrodissection which facilitates dissection in surgical planes and the cyst wall can be more easily pulled out from the surrounding tissues.

The combined effect of the anaesthetic solution for local infiltration mentioned above as well as the surgical technique can make complete removal of a sebaceous cyst through a small elliptical incision in one-stage a success and also provide an aesthetic result.

## CONCLUSION

The aesthetic technique for complete removal of a sebaceous cyst through a small elliptical incision described herein is simple and easy and it is highly recommended to all medical doctors.

## REFERENCES

1. Patton HS. An alternative method for removing sebaceous cysts. *Surg Gyne and Obstr* 1963;117:645-6.
2. Vivakananthan C. Minimal incision for removing sebaceous cysts. *Br J Plast Surg* 1972;25:60-2.
3. O'Keeffe PJ. Trephining sebaceous cysts. *Br J Plast Surg* 1972;25:411-5.
4. Richards MA. Trephining large sebaceous cysts. *Br J Plast Surg* 1985;38:583-5.
5. Moore C and Greer DM, Jr. Sebaceous cyst extraction through mini-incisions. *Br J Plast Surg* 1975;28:307-9.
6. Avakoff JC. Microincision for removing sebaceous cysts (Letter). *Plast Reconstr Surg* 1989;84:173-4.