

## *Giant Fibroadenoma in A Pre-menarchal Girl: A Case Report*

**Surasak Sangkhathat, MD\***

**Somboon Waiprib, MD\***

**Winyou Mitarnund, MD\*\***

**Sakda Patrapinyokul, MD\***

*\*Pediatric Surgery Unit, Department of Surgery and \*\*Department of Pathology, Faculty of Medicine,  
Prince of Songkla University, Songkla, Thailand*

---

### **Abstract**

We reported a case of giant fibroadenoma in a pre-menarchal girl, presenting as a large ulcerated fungating breast mass, protruding out of the overlying skin for 2 years. The clinical appearance and initial biopsy can not be differentiated from cystosarcoma phylloides. A limited simple mastectomy for this benign tumor gave a satisfactory outcome and no recurrence was evident after our two years of follow-up.

---

Although fibroadenoma is the most common breast mass in the adolescent,<sup>1-3</sup> giant or juvenile fibroadenoma accounts for 0.5-2 per cent of all fibroadenomas.<sup>4</sup> This sub-type is characterized by its large size and rapid growth.<sup>5,6</sup> The peak age-incidence is reported at 17-20 years and less than 5 per cent of the cases occur before menarche.<sup>7</sup> Herein, we report a case of giant fibroadenoma in a pre-menarchal girl, presenting as a malignant-looking breast mass.

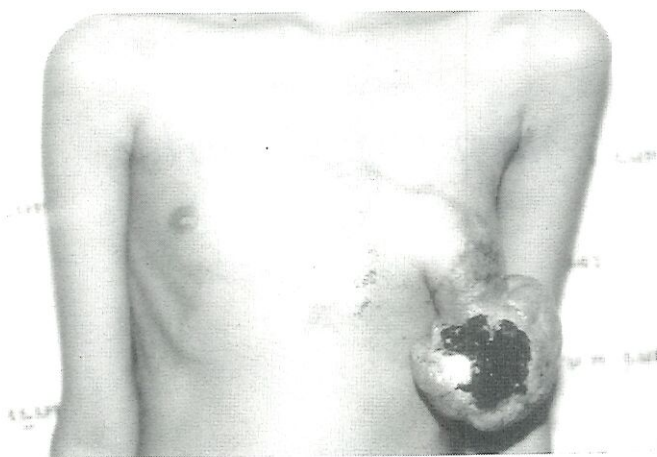
### **CASE REPORT**

A nine-year old Thai-Muslim girl presented in August 2000 with a rapidly enlarging lump in her left breast for 2 years. An incisional biopsy taken at a provincial hospital revealed a malignant phylloides tumor. The patient initially refused to undergo

mastectomy and went to try herbal medicine. The mass continued to grow and protruded through the overlying skin, about 6 months before the patient visited our clinic. Bleeding and foul-smelling discharge from the raw surface was also observed. The patient had lost weight and also had a low-grade fever.

This girl had not reached her menarche when the mass first developed. There was no history of exogenous estrogen used. The patient lived in a rural family and food usually came from a local plantation and their own domestic farm. History of breast mass was positive in her younger sister. The mass was only a small one that resolved spontaneously.

On physical examination, the girl was pale and malnourished. Her body weight was at the tenth percentile by her age whereas height was at the fiftieth. A large pedunculated gray-tan irregular mass was



**Fig. 1** Gross appearance of the breast mass. Note the skin protrusion at the nipple-areola complex and large ulceration on the tumor surface. Venous distension was observed on the surrounding chest skin. The development of the contralateral breast was at Tanner II stage.

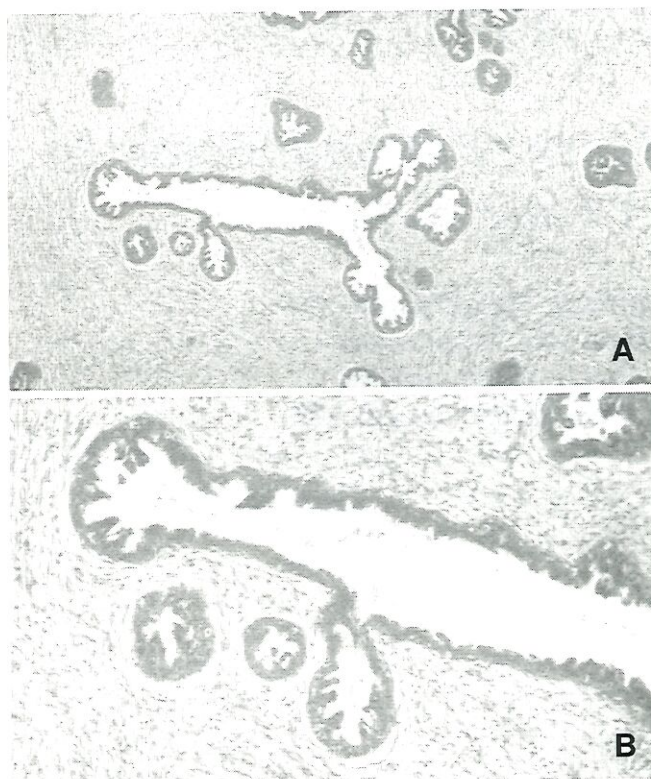
found protruding from her right areola (Figure 1). It measured 10 × 12 × 10 centimeters. The ulcerated tumor was covered by purulent discharge and dried crust was noted on the tumor surface. Superficial venous engorgement was seen on the chest wall skin. General female gender development was in the late Tanner II stage.

Blood examination showed anemia (Hb 7.4 g%) and eosinophilia (absolute eosinophil 912 cells/ml.). Serum chemistry revealed alkaline phosphatemia (207 U/L) and hypoalbuminemia (2.40 g/dl). A bone scan detected a slight increase of radiouptake at the anterior portion of left 4th-6th ribs. A histopathological review of the previous biopsy indicated a possible phylloides tumor because of the hypercellularity of the stroma.

A limited simple mastectomy was done. The left nipple-areola complex was removed together with a small elliptical piece of skin because of its proximity to the tumor stalk. Breast tissue beneath the mass was widely excised. Skin was primarily closed without much tension. The post-operative course was uneventful except for small superficial wound disruption.

Histopathology revealed proliferating ductal tissue lined by a few layers of cuboidal epithelium. The stroma showed slightly increased cellularity. No hyperchromatic nuclei or mitotic figure was found (Figure 2).

The patient did well on follow-up visits for two



**Fig. 2** Histopathology of the tumor, showing (A) increased stromal cellularity (low magnification) and (B) normal glandular epithelium with some papillary projections (high magnification).

years. She began her menstruation 18 months after his operation. Breast augmentation for cosmetic purposes has been planned after the child reaching her full breast development.

## DISCUSSION

Breast mass is not a common problem in the pediatric population. Although primary breast cancer in this group has been reported, it is extremely rare.<sup>8,9</sup> The majority of breast masses in the young arise from congenital malformations or benign neoplasm.<sup>2,3</sup> However, a breast lump is of great concern to the parents and physicians because of potential malignancy.<sup>8</sup>

Fibroadenoma is the most common cause of adolescent breast tumor. This pathology accounts for 64.4 - 71.7 per cent of breast biopsy specimens from patients under twenty years of age.<sup>1-3</sup> A classic fibroadenoma usually presents as an encapsulated, rubbery, non-tender mass that slowly enlarges over

several weeks or months.<sup>5</sup> The tumor is suggested to be estrogen-sensitive, as there is some tendency for it to enlarge toward the end of a menstrual cycle and significant enlargement occurs during pregnancy.<sup>6</sup> Estrogen and progesterone receptors detected in this type of benign tumor indicate that these steroid receptors may play an important part in the proliferation.<sup>7</sup>

A giant or juvenile fibroadenoma is a less common form, characterized by large size and rapid growth.<sup>5</sup> The size is usually 6-9 cm<sup>4,8</sup> (more than 5 cm by definition)<sup>11</sup>, but may be as large as 21 cm.<sup>6</sup> Reports from western countries showed a tendency for this neoplasm to occur in black race.<sup>4,6,8</sup> The peak incidence is in the second to third decade of life with an average age of 26 years.<sup>8,11</sup> Incidence in the pre-menarchal period in one study was less than 5 per cent.<sup>8</sup> The development of fibroadenoma in our patient at the age of nine years is unusual. There was one report of the disease occurring to a girl with androgen-insensitivity syndrome.<sup>12</sup>

The histologic appearance of giant or juvenile fibroadenoma differs from the classic fibroadenoma in the increased stromal cellularity and prominent glandular epithelium.<sup>4,5</sup> Atypical epithelial hyperplasia may also be present,<sup>6,8</sup> explaining why this tumor is often be confused with benign cystosarcoma phylloides. The latter usually shows more stromal cellularity, cellular pleomorphism, hyperchromatic nuclei and mitoses.<sup>6,11</sup> The evidence of skin protrusion and stromal hypercellularity from the previous examination in our case made it difficult to distinguish from phylloides tumor, although this is very rare in this age group. Immunohistochemical study in one case report also revealed positive staining for anti-estrogen receptor antibody in the nuclei of tumor cells.<sup>13</sup>

The current trend in management of a pediatric breast mass has swung to a conservative approach. Surgical therapy is reserved for a fibroadenoma that grows rapidly and/or causes distortion of the normal breast architecture.<sup>5,11</sup> Total excision is the operation of choice for giant fibroadenoma. To distinguish the mass from normal breast tissue is often difficult, necessitating a subcutaneous mastectomy be ultimately performed. Removal of the nipple-areola complex with the tumor in our case was considered because of the uncertainty in diagnosis and the involvement of the tumor with those structures.

Although there is no proven incidental link between fibroadenomas and carcinoma, one case of contralateral intraductal carcinoma and one case of lobular carcinoma in situ were reported in cases of juvenile fibroadenoma with atypical epithelial hyperplasia.<sup>8</sup> Those two cancers occurred at 19 years and 5 years after the excision of the fibroadenomas. Long term follow-up is then suggested, no matter the primary therapy chosen.

In summary, we report a case of giant fibroadenoma presented as a large fungating breast mass with ulceration in its surface. Diagnosis was initially confused with phylloides tumor and surgical excision was successfully performed.

#### ACKNOWLEDGEMENT

*The authors wish to thank Dr. Anupong Nitiruangjaras for the histopathology photographs. Medical record and films review were done with permission from the Research Committee of the Faculty of Medicine, Prince of Songkla University.*

#### REFERENCES

1. Stone AM, Shenker LR, McCarthy K. Adolescent breast mass. *Am J Surg* 1977; 134: 275-7.
2. Ferguson CM, Powell RW. Breast mass in young women. *Arch Surg* 1989; 124: 1338-41.
3. Palmer ML, Tsangaris TN. Breast biopsy in women 30 years old or less. *Am J Surg* 1993; 165: 708-12.
4. Baxi M, Agarwal A, Mishra A, et al. Multiple bilateral giant juvenile fibroadenomas of breast. *Eur J Surg* 2000; 166: 828-30.
5. Greydanus DE, Parks DS, Farrel EG. Breast disorders in children and adolescents. *Pediatr Clin North Am* 1989; 36: 601-39.
6. Davis C, Patel V. Surgical problems in the management of giant fibroadenoma of the breast. *Am J Obstet Gynecol* 1985; 152: 1010-5.
7. Umekita Y, Yoshida H. Immunohistochemical study of hormone receptor and hormone regulated protein expression in phylloides tumour: comparison with fibroadenoma. *Virchows Arch* 1998; 433: 311-4.
8. Mies C, Rosen PP. Juvenile fibroadenoma with atypical epithelial hyperplasia. *Am J Surg Pathol* 1987; 11: 184-90.

9. Seltzer MH, Skiles MS, Diseases of the breast in young women. *Surg Gynecol Obstet* 1980; 150: 360-2.
10. Rogers DA, Lobe TE, Rao BN, et al. Breast malignancy in children. *J Pediatr Surg.* 1994; 29: 48-51.
11. West KW, Rescorla FJ, III LRS, Grosfeld JL. Diagnostic and treatment of breast masses in pediatric population. *J Pediatr Surg* 1995; 30: 182-7.
12. Davis SE, Wallace AM. A 19 year old with complete androgen insensitivity syndrome and juvenile fibroadenoma of the breast. *Breast J* 2001; 7: 430-3.
13. Tochka N, Ogawa Y, Kumon M, et al. Rapid growing fibroadenoma in an adolescent. *Breast Cancer* 1998; 25: 321-4.