

# *Perigraft Seroma and Serous Fluid Leakage following Modified Blalock - Taussig Shunt : A Case Report*

Chareonkiat Rergkliang, MD  
Prasert Vasinanukorn, MD  
Apirak Chetpauphan, MD  
Vorawit Chittitavorn, MD

Division of Cardiovascular and Thoracic Surgery, Prince of Songkhla University,  
Songkhla, Thailand 90110.

---

## **Abstract**

A one year-old boy with tetralogy of Fallot and pulmonary atresia underwent the modified Blalock - Taussig shunt using a 5 mm polytetrafluoroethylene graft (PTFE). Postoperative course was complicated by perigraft seroma and serous fluid leakage. Conservative management with re-insertion of the chest tube failed to resolve the problem. At reoperation, after perigraft seroma removal, the PTFE graft was wrapped by Dacron patch and oxidized regenerated cellulose. This approach resulted in immediate reduction of the serous fluid leakage and eventually stopped on the 3<sup>rd</sup> postoperative day.

At the last follow-up 4 months later, the child appeared well with good function of the shunt.

---

The creation of a systemic to pulmonary shunt with polytetrafluoroethylene (PTFE) graft was first introduced by Gazzaniga in 1976.<sup>1</sup> This procedure has become increasingly popular as a palliation for cyanotic children with reduced pulmonary blood flow.<sup>2</sup> The modified Blalock - Taussig shunt has the advantage of requiring less dissection during operation<sup>2</sup>, pulmonary growth is greater, distortion of pulmonary arteries is less, shunt failure is less often<sup>3,4</sup> and blood flow to the respective arm is not jeopardized because the subclavian artery is not sacrificed.<sup>5</sup>

Substantial serous fluid may leak through the

interstice of PTFE graft and complicate the postoperative course.<sup>6</sup> The objective of this paper is to report the successful management of a patient who developed postoperative perigraft seroma and serous fluid leakage following modified Blalock - Taussig shunt.

## **CASE REPORT**

A one year old boy with congenital cyanotic heart disease was demonstrated to have tetralogy of Fallot with pulmonary atresia. He was admitted to the hospital

in February 2001. Because of increasing cyanosis, he required a palliative operation. The modified Blalock-Taussig shunt with a 5 mm PTFE graft was performed. Following the operation, the child's color improved, oxygen saturation in room air was 80 per cent and a continuous murmur was heard over the right infraclavicular region. The chest tube was removed on the second postoperative day.

However, on the 5<sup>th</sup> postoperative day, the child became dyspnea and the physical examination revealed decreased breath sound in the right chest. The chest x-ray demonstrated large pleural effusion with haziness at the right superior mediastinum (Figure 1). The pleural fluid analysis showed: straw-color; WBC 1,050 cell/cu.mm. (mononuclear cell 60% and PMN 40%); Triglyceride 79 mg/dl; Glucose 95 mg/dl; Total protein 5 gm/dl; and LDH 470 U/L.

The chest tube was re-inserted. The drainage persisted at an average of 150 ml/day for 2 weeks. The MRI study demonstrated collection around the graft

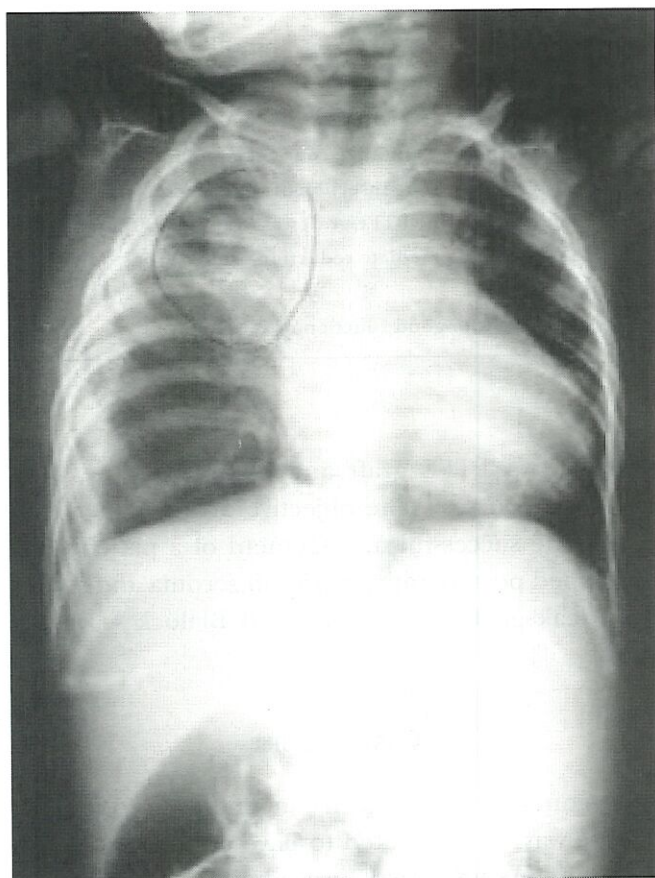


Fig. 1 Chest x-ray demonstrated haziness of right superior mediastinum and right pleural effusion.

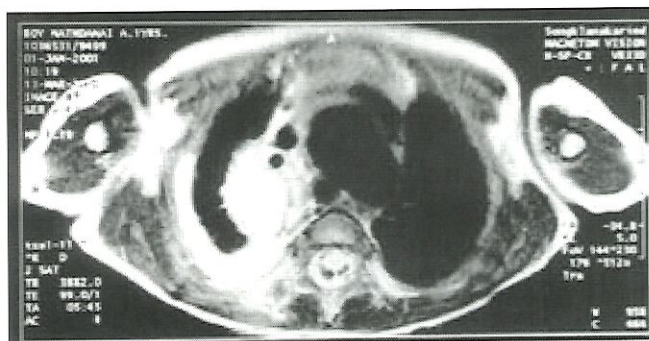


Fig. 2 MRI showed collection around the tubular graft and right pleural effusion.

and moderate amount of pleural effusion (Figure 2). Re-operation was undertaken at 3 weeks after the shunt placement because of perigraft collection and excessive persistent of the drainage.

At reoperation, a semiopaque mass of proteinaceous coagulum was found around the functioning PTFE graft. After total removal of the proteinaceous mass, the graft was found actively leaking clear serous fluid throughout its length. A piece of Dacron patch was trimmed to appropriate size and placed wrapping around the PTFE graft. A piece of oxidized regenerated cellulose was applied around the Dacron patch. The serous fluid leakage became much less active and a chest tube was placed.

The child's subsequent recovery was satisfactory with well functioning shunt. The chest tube drainage gradually decreased and ceased on the 3<sup>rd</sup> postoperative day. The chest tube was removed on the following day.

At the last follow-up 4 months later, the child appeared well with a continuous murmur, good oxygen saturation and a clear chest x-ray film.

## DISCUSSION

Perigraft seroma and serous fluid leakage following a PTFE modified Blalock-Taussig shunt may occurred in 20 per cent after the operation<sup>6</sup>. Serous leakage through the wall of PTFE graft may cause prolonged chest tube drainage or recurrent pleural effusion after the chest tube removal. It may also accumulate around the PTFE graft, producing perigraft seroma.<sup>7</sup>

PTFE graft is hydrophobic and impermeable to whole blood but it may become hydrophilic 48 to 96



hours after implantation which explains why the perigraft seroma and serous fluid leakage occurs late after the operation. The exact mechanism of this complication has not been determined.<sup>6</sup>

LeBlance found the use of silicon sheet wrapping the PTFE graft in children older than one year of age and the size of PTFE graft larger than 5 mm in diameter were the risk factors for perigraft seroma and serous fluid leakage in their report (26 of 138 cases).<sup>6</sup> Berger reported 8 cases of perigraft seroma and mentioned that the use of intravenous heparin after operation was a risk factor associated with symptomatic perigraft seroma.<sup>8</sup>

Van Rijn RR reported 11 cases of perigraft seroma. They were able to demonstrate the perigraft seroma by thoracic sonography in 8 cases and found that CT scan and MRI were equally well in revealing perigraft seroma.<sup>9</sup>

In our patient, the x-rays findings of widening or haziness at the superior mediastinum following modified Blalock - Taussig shunt required further investigation to elucidate the nature of such findings. The possibilities included perigraph hematoma or seroma, pseudoaneurysm, and upper lobe atelectasis. MRI was employed and the findings suggested the presence of a perigraft seroma. Thus the child was re-operated after conservative management had failed.

We reported the method of treating serous fluid leakage from PTFE graft at reoperation by wrapping the PTFE graft with Dacron patch and oxidized regenerated cellulose. It is a simplify method that gives an excellent result in immediate and midterm period.

There are many methods of correction for this complication at the reoperation. Damus replaced the graft with another PTFE graft.<sup>7</sup> Luis Garcia-Guereta successfully managed with topical application of Tissucol Immuno (1 ml contains 75 mg coagulant protein, 300 KIU bovine aprotinin, 500 IU bovine thrombin, and 40 mmol/L calcium chloride) on the surface of the graft.<sup>10</sup> Maitland using the intraluminal "fibrin glue" (10,000 U aprotinin, 1,000 U thrombin and 6.8 mol/ml calcium chloride) after temporarily occluded the graft and aspirated the blood.<sup>11</sup> Ugurlu resolved this complication by wrapping the PTFE graft with parietal pleural flap.<sup>12</sup> Hiramatsu successfully treated with intravenous fibrinogen administration but the patient developed recurrent pleural effusion

following the initial treatment and required another doses of intravenous fibrinogen and additional oral antifibrinolytic agent.<sup>13</sup> LeBlance simply evacuated the seroma from around the graft and resumed the chest tube drainage. Their method resulted in slow resolution over several weeks.<sup>6</sup>

## REFERENCES

1. Gazzaniga AB, Elliot MP, Sperling DR, Dietrick WR, Eisenmajer JI, McRoe DM, et al. Microporous expanded polytetrafluoroethylene arterial prosthesis for construction of aortico-pulmonary shunts. Experimental and clinical results. *Ann Thorac Surg* 1976; 21: 322-7.
2. Ilbawi MN, Grieco J, DeLeon SY, et al. Modified Blalock - Taussig shunt in newborn infants. *J Thorac Cardiovasc Surg* 1984; 88: 770-5.
3. Rebecca L, Ullom MS, Robert M, et al. The Blalock - Taussig shunt in infants: Standard versus modified. *Ann Thorac Surg* 1987; 44: 539-43.
4. Jahangiri M, Lincoln C, Shinebourne EA. Does the modified Blalock - Taussig shunt cause growth of the contralateral pulmonary artery? *Ann Thorac Surg* 1999; 67: 1397-9.
5. Watkins MT, Ricotta JJ, Manning JA, Stewart S. Upper extremity claudication 10 years after a Blalock - Taussig Shunt: Treated with a carotid-to-subclavian graft. *Ann Thorac Surg* 1988; 45: 445-6.
6. LeBlanc J, Albus R, Colonel L, et al. Serous fluid leakage: a complication following the modified Blalock - Taussig shunt. *J Thorac Cardiovasc Surg* 1984; 88: 259-62.
7. Damus PS. Seroma formation after implantation of Gore-Tex vascular grafts in cyanotic children (letter). *J Thorac Cardiovasc Surg* 1984; 88: 310-1.
8. Berger RMF, Raap GB, Hop WJC, Bogers AJJC, Hess J. Heparin as a risk factor for perigraft seroma complicating the modified Blalock - Taussig shunt. *J Thorac Cardiovasc Surg* 1998; 116: 286-93.
9. Van Rijn RR, Berger RMF, Leguin M, Robben SGF. Development of a perigraft seroma around modified Blalock - Taussig shunt: Imaging evaluation. *AJR* 2002; 178: 629-33.

10. Garcia - Guereta L, Burgueros M, Borches D, Gonzalez V, Jimenez J. Cardiac tamponade after a systemic-pulmonary shunt complicated by serous leakage. *Ann Thorac Surg* 1997; 63: 248-50.
11. Maitland A, Williams WG, Coles JG, Freedom RM, Trusler GA. A method of treating serous fluid leak from a polytetrafluoroethylene Blalock - Taussig shunt. *J Thorac Cardiovasc Surg* 1988; 90: 791-3.
12. Ugurlu BS, Sariosmanoglu ON, Metin SK, Hazan E, Oto O. Pleural flap for treating perigraft leak after a modified Blalock - Taussig shunt. *Ann Thorac Surg* 2002; 73: 1638-40.
13. Hiramatsu Y, Atsumi N, Sasaki A and Mitsui T. A successful treatment of serous leakage from polytetrafluoroethylene Blalock - Taussig shunt with intravascular fibrinogen administration. *J Thorac Cardiovasc Surg* 1999; 117: 1230-1231.