

Biliary Stenting in Tight Malignant Biliary Stricture : A Technical Consideration

Sunthorn Treesaranuwaitana, MD

Department of Surgery, St. Mary Hospital, Nakhon Ratchasima, Thailand 30000

Abstract

A simple technique employing a long taper tip catheter to facilitate stent placement in tight biliary malignant stricture, smaller than 5 F, may serve as an alternative procedure to successful placement of biliary stent when conventional dilatation is of no avail. This procedure requires only standard diagnostic duodenoscope, 5 F long taper tip catheter, grasping forceps and 5 F stent set containing the stent, 0.021 inch guide wire and the pusher tube. Subsequently, it also facilitates the consecutive dilatation by balloon or graduated dilator for placement of larger plastic stent or expandable metallic stent.

Key Words : Malignant obstructive jaundice - Cholangiocarcinoma - Therapeutic endoscopy-Biliary stent.

Endoscopic biliary stent, originally described by Sohendra et al in 1980,¹ is now widely accepted for palliative biliary decompression of obstructive jaundice from advanced or non-resectable malignant stricture.²⁻⁴

The success rate of inserting the stent is generally in the range of 70-95 percent depending upon the location and nature of strictures. Greatest success is in the case of periampullary and distal common bile duct (CBD) carcinoma (90-95%), followed by lesions at mid CBD and common hepatic duct (CHD). Hilar cholangiocarcinoma (HCCA) is the most difficult lesion for endoscopic stenting. In Bismuth type III HCCA, the success rate is only about 70 percent.⁵

If tight stricture is encountered at the time of Endoscopic Retrograde Cholangiopancreatography

(ERCP) and a 5 F catheter fails to pass through the lesion, conventional stenting method can not be performed without prior dilatation. But if only 0.021 inch guide wire can pass across the stricture, stenting can be achieved by the technique herein described.

MATERIALS AND METHODS

From January 1998 to December 1999, thirty five cases of obstructive jaundice caused by cholangiocarcinoma (CCA) excluding periampullary, pancreatic and metastatic carcinomas, underwent ERCP and stenting attempts. Six cases of HCCA had tight stricture that only the 0.021 inch guide wire could be passed through the lesion. Stenting with 5 F stent was performed in the following steps.

1. Advancing the guide wire further in until reaching the level of peripheral bile duct (Figure 1).

2. Change the catheter to a 5 F long taper tip catheter (Figure 2).

3. Advance the catheter until it comes to impact against the stricture site, sustain the forceful pushing, then angling up endoscopic tip with left rotation of its shaft, meanwhile assistant pulls back guide wire for 1-2 cm. Repeating this maneuver until the catheter tip gets above the stricture (Figure 3).

4. Remove the catheter, then insert stent and pusher tube in place of the catheter and push in the stent by repeating step 3. If stent moves in, repeat maneuver until stent is in good position (Figure 4). If the stent no longer moves further, remove guide wire and pusher tube, then proceed to step 5.

5. Use grasping forceps to grasp the stent at 1 cm from papilla. The stent should be well orientated to the

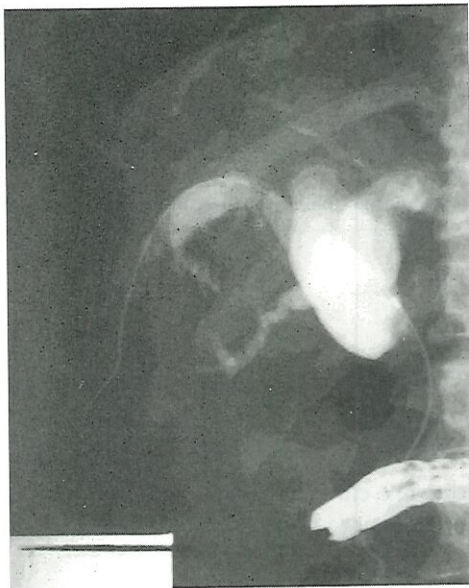


Fig. 1 Endoscopic Retrograde Cholangiopancreatogram showing the tip of guide wire in peripheral bile duct of the right lobe.

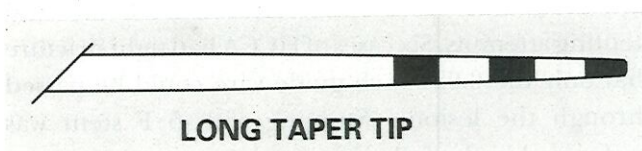


Fig. 2 Distal end of 5 F Long taper tip catheter (GLO Tip Wilson - Cook). Body size 5 F, tip size 4 F.

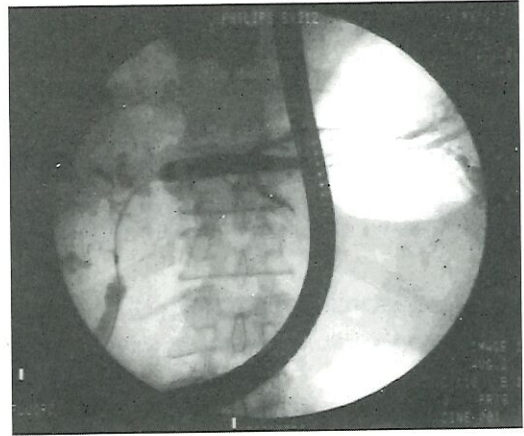


Fig. 3 Initial dilatation with 5 F Long taper tip catheter. Metal mark at tip of catheter was seen inside the stricture.

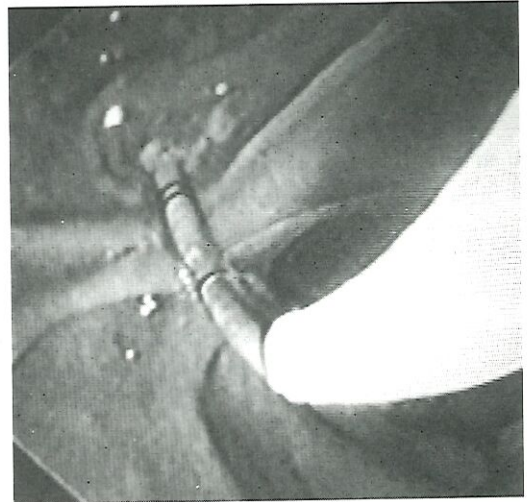


Fig. 4 Pushing the stent by pusher tube.

bile duct axis, then push in the stent by angling up endoscopic tip with a left rotation of its shaft. When stent moves in, repeat the maneuver until the stent has reached a good position (Figure 5).

RESULTS

All six cases of tight stricture were the Bisthmus type III, IV HCCA. Three cases had successful stenting with 5 F stent performed (Figure 6). The other three cases failed due to the long tight stricture (> 3 cm). One of the successful stented patient survived for over 12 months.

Three cases of successful stenting survived 14, 3 and 1 months. First case, 60 year old woman, required

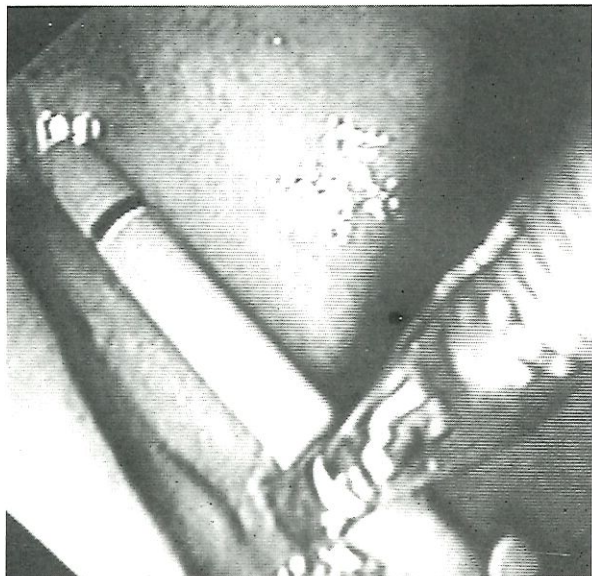


Fig. 5 Pushing the stent by using grasping forceps.

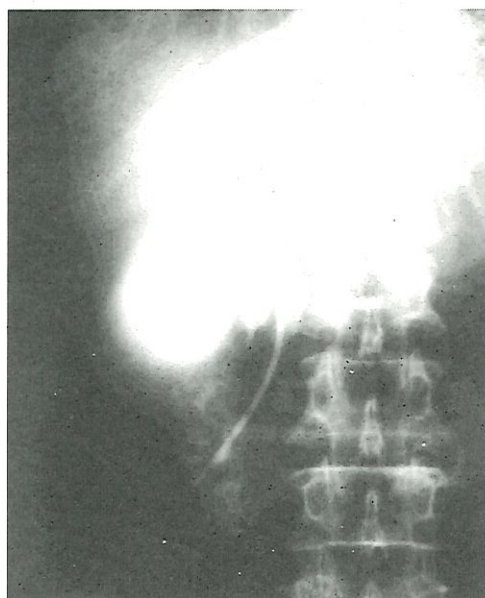


Fig. 6 5 F Stent placement through a long - tight stricture.

four stenting procedure because of occlusion of stent. In the third attempt, double stents were inserted for drainage of both lobes bile duct. Second case, 73 year old man, developed septicemia and death from occlusion. of second stent with delay proper management. The last case, 55 year old man, had deep jaundice for three months with evidence of metastatic carcinoma to liver and lung. Despite successful

placement of stent, only slight decrease of bilirubin level without clinical improvement.

DISCUSSION

Endoscopic management of malignant biliary stricture by biliary stent is a straight forward procedure when ERCP catheter can be passed across the site of stricture. Stenting with large plastic stent or expandable metallic stent is usually successful in these cases. But if even a 5 F catheter fails to pass through the stricture especially in the sclerosing type of HCCA, prior dilatation with balloon or graduated dilator are inaccessible then making biliary stenting impossible.

The technique presented employs a 5 F long taper tip catheter as a two step dilator (4 F at its tip to 5 F at its body). When forceful push in maneuver is attempted, the tip of catheter will dilate the proximal part of stricture which in turn facilitates the body of the catheter to move inward little by little upon repeated pushing during the maneuver until finally the catheter is brought passing across the stricture. Once the initial stent is successfully instituted, placement of larger plastic stent or expandable metallic stent may be achieved subsequently.^{6,7}

CONCLUSION

A simple technique employing a long taper tip catheter to facilitate stent placement in tight biliary stricture, smaller than 5 F, may serve as an alternative procedure to successful placement of biliary stent when conventional dilatation is of no avail. Subsequently, it also facilitates the consecutive dilatation by balloon or graduated dilator for placement of larger plastic stent or expandable metallic stent.

References

1. Sohendra N, Reijnder Frederix. Palliative bile duct drainage. A new endoscopic method of introducing a transpapillary drainage. *Endoscopy* 1980; 12:8-11.
2. Sherman S, Lehman GA. Retrograde cholangiopancreatography, Endoscopic biliary and pancreatic drainage. In: Tadataka Yamata, ed. *Textbook of Gastroenterology*, 3rd ed. Philadelphia: JB Lippincott, 1999; 2718-46.

3. Huibregtse K. Practice of therapeutic endoscopy: Syllabus of Gastrointestinal Endoscopy Workshop. *Siriraj Hosp Gaz* 1996; 48: 53-66.
4. Kozarek RA. Endoscopy in the management of malignant obstructive jaundice. *Gastrointest. Endosc Clin North Am.* 1996; 6:153-76.
5. Liguory CI. Endoscopic Stenting for malignant jaundice. Syllabus of post graduate course in 6th World Congress of Endoscopic Surgery 1998; 102-6.
6. Cotton PB, Williams CB. Therapeutic ERCP. *Practical Gastrointestinal Endoscopy*. 3rd ed. New York: Blackwell Scientific. 1990; 118-56.
7. Desereunx CE, Binmoellera KF. Endoscopic Retrograde Cholangiopancreatography in the next millennium. *Gastrointest Endos Clin North Am* 2000; 10: 117-33.