

# *Needle-Knife Papillotomy : An Adjunct to Therapeutic ERCP*

Sukij Panpimanmas, MD  
Tawee Ratanachu-ek, MD  
Suchart Chantawiboon, MD

*Division of General Surgery, Department of Surgery, Rajavithi Hospital, Bangkok, Thailand 10400.*

---

## **Abstract**

Between January 1998 and September 2000 needle-knife papillotomy (NKP) was attempted in 21 patients after failure of conventional endoscopic biliary cannulation. The indications of ERCP included CBD stones in 9, gallstone with abnormal liver enzymes or suspicious ultrasonographic findings in 5 and jaundice with dilated biliary duct in 7 cases. The success rate of cannulation was 76 per cent (16 in 21 patients) in the first session and 80 percent (4 in 5 patients) when attempted in the second session. Overall success rate was 95 per cent. Complication rate was 9.5 per cent (2 in 21 patients) with mild pancreatitis in two patients. There was no mortality in this study.

In conclusion, NKP is a valuable adjunct to ERCP that allows safe, effective and high success rate for cannulation in cases that conventional access maneuver has failed.

**Key Words :** Needle-knife papillotomy, Precut papillotomy, ERCP.

---

Endoscopic retrograde cholangiopancreatography (ERCP) was first described in 1970<sup>1</sup> and is now commonly performed successfully in over 95 per cent of cases in most centers. Endoscopic sphincterotomy was developed in 1973<sup>2</sup> and became an established procedure with the success rate of 90-95 per cent.<sup>3-5</sup> When conventional diagnostic or therapeutic endoscopic biliary access fails, pre-cut papillotomy (Figure 1) or needle-knife papillotomy (NKP) has been proven to be effective technique to enhance access to the biliary tree.<sup>6</sup> Despite its efficacy, the use of NKP remains controversial because of the required technical skill. At present, no consensus or uniform strategy has been reached in case of the failed cannulation. The endoscopic approach depends on several factors such as indications for ERCP, availability of alternate procedure to endoscopy, and experience of the endoscopist. In addition, questions regarding its safety have been raised among experts about the early reports of NKP of a higher rate of complications

than in the more recent series.<sup>7-9</sup> Many endoscopists do not use this technique for diagnosis but only for therapeutic purposes. The aim of this study is to evaluate the technique of NKP, the success rate of cannulation and its complications.

## **PATIENTS AND METHODS**

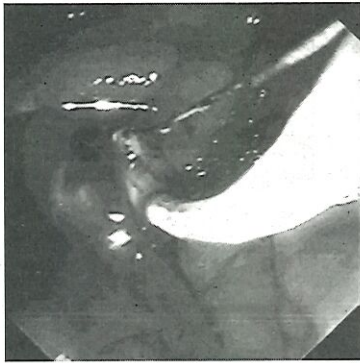
Since 1990 we had performed 2,040 cases of ERCP, 810 cases of sphincterotomy, 602 cases of stones extraction, and 180 cases of endoprosthetic stenting for biliary obstruction in Rajavithi Hospital. The NKP technique commenced in January 1998 in those patients whom cannulation of the ampulla of Vater was unsuccessful by the conventional maneuvers.

In this report, retrospective review was studied in patients receiving NKP during the 3-year period between January 1998 and September 2000. There were 12 men and 9 women (total 21 cases). Their mean age was 58 years (range 30-79). The indications

for ERCP were CBD stones in 9 cases, gallstones with abnormal liver enzymes or presence of gallstones by ultrasonographic findings in 5 cases, and janudice with dilated biliary duct in 7 cases.

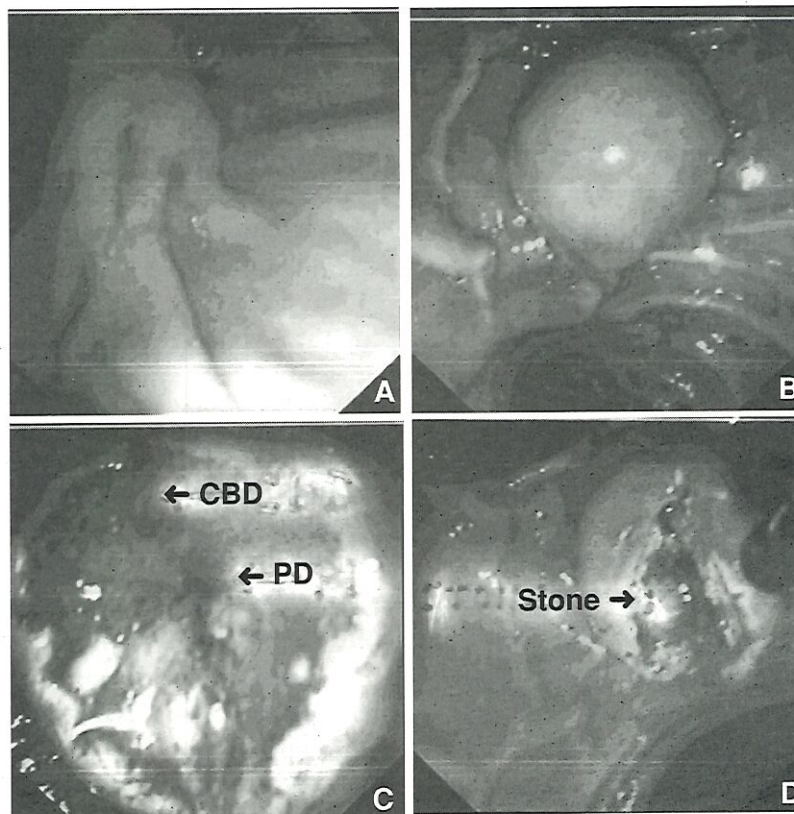
### Endoscopic Technique

ERCP was performed with Olympus-duodenoscopes JF-100 and JF-130. The NKP technique we usually employed was transorifice papillotomy.<sup>10</sup> We



**Fig. 1** Precut papillotomy or needle-knife papillotomy using a standard papillotome.

used suprapapillary fistulosphincterotomy only in cases of bulging ampulla or impacted ampullary stones (Figure 2). Lidocaine spray (10%) application to hypopharynx and Hyoscine-N-butylbromine (Buscopan) for anti-motility were routinely used. Sedation (Medazolam) and analgesics (Pethidine) were given in some cases when indicated. The needle-knife papillotome consists of an outer plastic sheath (5-5.5 F) and an inner solid stainless steel wire that can be projected from the plastic sheath. NKP was performed using either Olympus KD-10G needle knife or Wilson-Cook Zimmon needle knife. The electrocautery unit (Olympus) was set for a blended current at 30 coagulation and 30 cutting on electrocautery. It was applied only when the needle knife was in motion to avoid a deep cut and perforation. The incision was usually made at 11 or 12 o'clock position, starting from the papillary orifice and moving in a cephalad direction. When this was not possible due to a bulging ampulla or impacted stone, the incision was started in the most prominent portion (suprapapillary fistulosphincterotomy). The cut was extended in short, controlled



**Fig. 2** A, B Transorifice needle-knife papillotomy showing opening of common bile duct (CBD) and pancreatic duct (PD). C, D Needle suprapapillary-knife papillotomy showing impacted intraampullary stone.



movement until bile flow or bile duct orifice was visualized. A small catheter was then inserted and contrast media injected to delineate the biliary duct under a C-arm fluoroscopic monitor control. Blind injection of contrast through the NKP site should not be done as this could create submucosal collection or a false tract. Following the above maneuver, if the papillotomy site was still inadequate for therapeutic intervention, a conventional sphincterotomy would be added by using the papillotome cutting over guide-wire technique. NKP was considered successful when free cannulation of the bile duct was achieved. If immediate cannulation was unsuccessful after NKP, further attempt of ERCP and cannulation was delayed for three to seven days to allow swelling to subside and to gain clear anatomical identification. Usually, this delayed attempt would lead to a successful cannulation.

## RESULTS

A total of 21 consecutive NKP were performed following ERCPs. There were 12 men and 9 women with a mean age of 58 years (range 30-79). Nineteen of these patients (90%) were referred cases from other hospitals. The indications for ERCP and therapeutic attempts requiring NKP were shown in Table 1 and the overall success rate in Table 2.

Cannulation was immediately achieved in 16 of 21 patients (76%). Of the 5 patients in whom initial biliary cannulation failed after NKP, 4 patients (80%) had successful cannulation on a second attempt performed during 3-7 days after the first ERCP. The overall success rate of cannulation was 20 from 21 patients (95%). The only case that failed second cannulation was associated with malignant obstruction of distal CBD. In the 20 successful cannulations, 16 cases received further therapeutic interventions.

In the first attempt for CBD stones group, 6 cases had sphincterotomy with stone extraction and one case had temporary biliary plastic stenting because the stones were too large. The other 2 cases required a second attempt for sphincterotomy in one and sphincterotomy with stent in the other because of some residual stones. For first attempt in 5 cases of gallstone with abnormal liver enzymes group, 3 cases were of normal diagnostic visualizations, one case had sphincterotomy and stone extraction for CBD stone. The remaining one in this group required only

**Table 1** Indications for ERCP and therapeutic attempts requiring NKP.

Indication	n	%
CBD stones	9	42.9
Sphincterotomy + stone extraction	(7)	
Sphincterotomy + stone extraction + stenting	(1)	
Stenting	(1)	
Gallstone with abnormal liver enzyme or ultrasound	5	23.8
Diagnostic only	(3)	
Sphincterotomy	(1)	
Sphincterotomy + stone extraction	(1)	
Jaundice with dilate biliary duct	7	33.3
Sphincterotomy	(1)	
Stenting	(5)	
Unsuccessful attempt	(1)	
<b>Total</b>	<b>21</b>	<b>100</b>

(Total ERCP 2,040)

**Table 2** Success rate of cannulation following NKP

Session of NKP	n	%
First attempt	16/21	76
Second attempt	4/5	80
<b>Total</b>	<b>20/21</b>	<b>95</b>

sphincterotomy done in the second attempt for narrowing of the distal CBD of undetermined nature. For the jaundiced group in the first attempt, 3 of 4 cases had successful plastic stenting of strictures caused by cholangiocarcinoma but in the last case only sphincterotomy was required because stricture was located in the distal CBD. For those patients who required second attempt, for CBD stones group, the last 2 cases had underwent sphincterotomy and stones extraction with stenting in one case because of residual stones. For gallstone with abnormal liver enzyme group, this case had underwent only sphincterotomy because of questionable stricture distal CBD. In the second attempt of the jaundice group, only one case had successful biliary stenting for cholangiocarcinoma but another one case had failed the second cannulation attempt because of extremely hard malignant obstruction at distal CBD.

Mild pancreatitis occurred in two patients (9.5%) which subsided within few days of conservative treatment. No massive bleeding, perforation and procedure-related mortality were encountered.



## DISCUSSION

Since the first report of NKP in 1980<sup>12</sup> its application has been considerably popularized in some centers. Possible indications now include not only the impacted intrapapillary stones but also to increase access to the common bile duct or pancreatic duct after the attempt with conventional methods have failed. The use of NKP for diagnostic ERCP was restricted to only the selected cases in most endoscopist's opinions. However, in patient who has positive findings requiring endoscopic intervention, attempting NKP to facilitate therapeutic ERCP by experienced endoscopist may be justified despite the risk of procedure related complication. In our series, 4 patients had diagnostic procedure and 16 patients had therapeutic attempts achieved. We encountered no complication in the diagnostic procedure employing NKP. In our initial period of practice of ERCP (prior to 1996 with nearly 800 cases), the success rate of biliary duct cannulation was only 70 per cent. This has gradually improved by adding several complementary techniques such as special tip cannulas, wire-guiding introduction, precutting papillotomy and NKP. Success rate of biliary duct cannulation in our center since then is more than 90 per cent with lower than 10 percent morbidity and less than one percent mortality. In reviewing literatures of NKP series from various centers, the success rate of biliary duct cannulation reported were 85-96 per cent<sup>6,13-18</sup>, which were comparable to ours experience. Bleeding is the most common complication in most series. The reason may be that pure cutting current was used in most reports in order to avoid pancreatitis. We used blended cutting and coagulating current and have not experienced any bleeding complication. However, there were 2 cases (10%) of mild pancreatitis encountered.

## CONCLUSIONS

NKP is a highly effective precutting procedure for achieving biliary duct cannulation after attempt by conventional maneuver has failed. It is considered to be a safe and helpful adjunct to ERCP, but the endoscopists are required to have considerable experiences in ERCP before attempting to do NKP. It's use should be strictly limited to the case with

positive findings requiring endoscopic intervention and the risk of complication for the therapeutic attempt is justified.

## References

1. Oll. Fiberduodenoscopy and endoscopic pancreatocholangiography. *Gastrointest Endosc* 1970; 17: 69-72
2. Kawai K, Akasaka Y, Murakami K. Endoscopic sphincterotomy of the ampulla of Vater. *Gastrointest Endosc* 1974; 20: 148-51.
3. Cotton PB. Endoscopic management of bile duct stones-apples and oranges. *Gut* 1984; 25: 587-97.
4. Leese T, Neoptolemos JP, Carr-Locke DL. Successes, failures, early complication and their management following endoscopic sphincterotomy result in 394 consecutive patients from a single center. *Br J Surg* 1985; 72: 215-9.
5. Geenen JE, Hogan WJ, Dodds WJ. Endoscopic sphincterotomy in patients with sphincter of Oddi dysfunction. *N Engl J Med* 1989; 320: 82-7.
6. Rollhauser C, Johnson M, Al-Kawas FH. Needle-Knife Papillotomy: A Helpful and Safe Adjunct to ERCP in a Selected Population. *Endoscopy* 1998; 30: 691-6.
7. Cotton PB. Precut papillotomy: a risky technique for experts only. *Gastrointest Endosc* 1989; 35: 578-9.
8. Baillie J. Needle-Knife sphincterotomy. *Gastrointest Endosc* 1990; 36: 645-6.
9. Bruins slot W, Schoeman MN, Disario JA, et al. Needle-Knife sphincterotomy as a precut procedure: a retrospective evaluation of efficacy and complications. *Endoscopy* 1996; 28: 334-9.
10. Dowsett JF, Polydorou AA, Vaira D, et al. Needle knife papillotomy: how safe and how effective? *Gut* 1990; 31: 905-8.
11. O'Connor HJ, Bhutta AS, Redmond PL, et al. Suprapapillary Fistulosphincterotomy at ERCP: A Prospective Study. *Endoscopy* 1997; 29: 266-70.
12. Siegel JH. Precut papillotomy-a method to improve success of ERCP and papillotomy. *Endoscopy* 1980; 12: 130-3.
13. Huibregtse K, Katon RM, Tytgat GNJ. Precut papillotomy via needle-knife papillotomy: a safe and effective technique. *Gastrointest Endosc* 1986; 32: 403-5.
14. Siegel JH, Ben-Zvi J, Pullano W. The needle knife: a valuable tool in diagnostic and therapeutic ERCP. *Gastrointest Endosc* 1989; 35: 499-503.
15. Leung JWC, Banez VP, Chung SCS. Precut (needle-knife) papillotomy for impacted common bile duct stone at the ampulla. *Am J Gastroenterol* 1990; 85: 991-3.
16. Tweedle DEF, Martin DE. Needle-knife papillotomy for endoscopic sphincterotomy and cholangiography. *Gastrointest Endosc* 1991; 37: 518-21.
17. Shakoor T, Geenen JE. Precut papillotomy. *Gastrointest Endosc* 1992; 38: 623-7.
18. Kasmin FE, Cohen D, Batra S, et al. Needle-knife sphincterotomy in a tertiary referral center: efficacy and complications. *Gastrointest Endosc* 1996; 44: 48-53.