

Amputated Penis, A Man's Nightmare

Veerasing Muangman, M.D.

The rapidly changing socio-economic status of Thailand recently has brought about psychological stress among the less fortunate groups of people. The incidence of people affected by psychoneurosis was 500,000 cases in 8 months and the incidence of suicide in the age group of 15-25 was 15:100,000*. Polygamy is not uncommon and machismo is considered as "my pigeon flies high" by some groups of people in Thai society, both the well to do and the laborers. Family conflict is sometimes unavoidable, leading to genital assault and amputation of the penis by the victim's spouse. The epidemiology of amputation of the penis seems high recently, therefore the author feels it is appropriate to study the causes and results of penile amputation in Thailand.

Causes of (wife afflicted) Penile Amputation

Information gathered from the 6 patients at the Ramathibodi Hospital from the period of 1977-1980 whose penes were amputated revealed that all were amputated by their first wives, during the sobering up period following alcohol consumption and after sexual intercourse. The incidents occurred late at night and the patients usually came into the hospital around 1-2 o'clock in the morning. The assault weapons were either shaving razor blades or kitchen knives. The most unfortunate men had the penile distal pieces destroyed or taken away by their wives. The motive behind such crimes was usually "teaching a lesson not to become machismo". And apparently the wives felt so proud about their triumph in performing such a "heroic operation in life time".

The mass media, especially newspapers make an unethical propaganda regarding an amputated penis,

*From the Department of Surgery,
Ramathibodi Hospital,
Mahidol University, Bangkok, Thailand.*

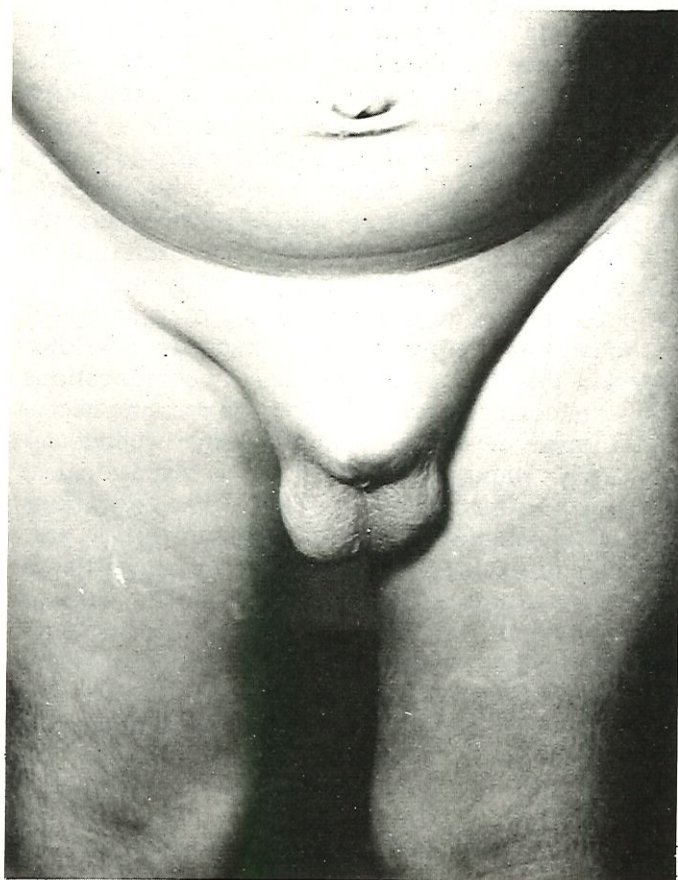


Fig. 1 The appearance of male genitalia after penile amputation by spouse.

*Monograph on the Mahidol University Seminar on Mental Health for the Public, October 6-8, 1980.

calling it "magnificent dragon", "brilliant crocodile", "king of the world". Such headlines on the front page of the papers tend to arouse an unhealthy public attention.

Results of Penile Amputation

Immediately after the penile amputation, there was profused bleeding but soon this stopped spontaneously by the usual clotting mechanism. In the hospital, the surgeons had to perform the meticulous re-anastomosis procedure for the incompletely amputa-

ted penis, sometimes with the aid of microsurgery, or suturing the penile stump and re-fashioning the urethra to prevent bleeding from the stump and the stricture of the urethra. Unfortunately, those men who brought with them the distal penile portions, the re-anastomotic procedure offered the success rate of less than 30%. The less unfortunate men were those who had incomplete penile amputation, or complete amputation with sharp instrument and minimum time loss before surgical procedure. Admittedly surgical skill in anastomosis played an important role in the success of the operation.