

Erratum to: Results of Posteromedial Capsule and Superficial Medial Collateral Ligament Release on Gap and Alignment in Total Knee Arthroplasty for Varus Knee Deformity by Computer-Assisted Surgery Measurement

Chaiyakit P, Onklin I, Ampunpong W. Results of posteromedial capsule and superficial medial collateral ligament release on gap and alignment in total knee arthroplasty for varus knee deformity by computer-assisted surgery measurement. *Vajira Med J* 2022;66(6):389-96.

In the manuscript, the authors notice major faults on their figures which are Figure 4a, 4b and 5 on page 394. The mistakes may lead to misunderstanding. The authors regret the error.

This erratum corrects the following Figures are shown below.

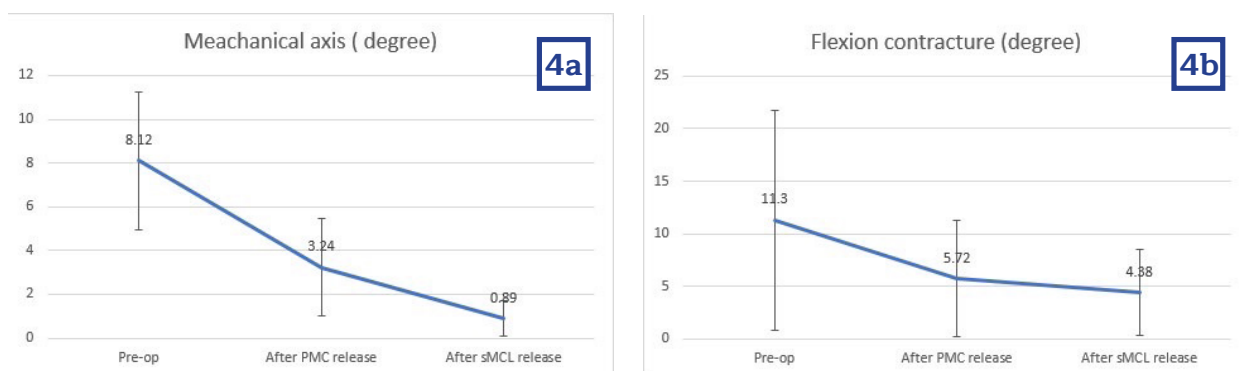


Figure 4a Hip-Knee-Ankle (HKA), Axis-X represents HKA and FC preoperative, after PMC and after sMCL release

Figure 4b Flexion contracture (FC) correction, Axis-Y shows HKA and FC (Degree), Positive HKA angle is defined as varus alignment

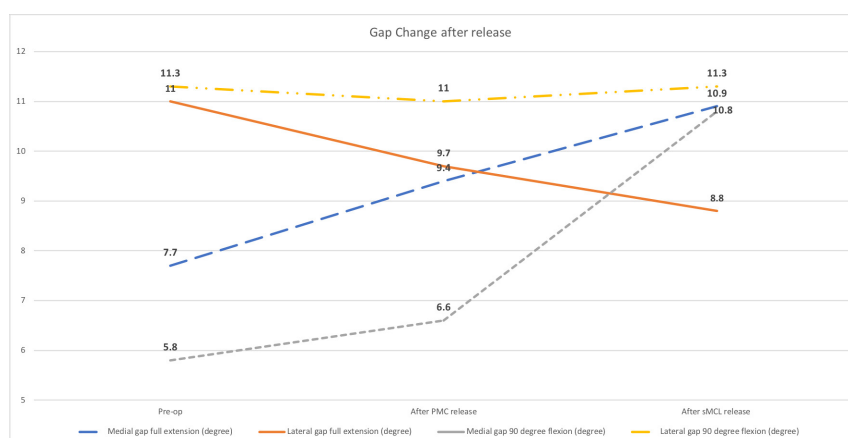


Figure 5 Medial and lateral gaps (mm.) changes at full extension and 90 degree flexion
 Axis-X represents Medial and lateral gaps preoperative, after PMC and after sMCL release
 Axis-Y shows Medial and lateral gaps (mm.)

