

# Endobronchial Ultrasound-guided Transbronchial Needle Aspiration (EBUS-TBNA) Followed by Thoracotomies

Sawang Saenghirunvattana, MD.<sup>1</sup>

Vibul Jotisakulrata, MD.<sup>1</sup>

Chana Buakham, MD.<sup>1</sup>

Surapon Worapongpaiboon, MD., FCAP.<sup>1</sup>

Takahiro Nakajima, MD.<sup>2</sup>

Kazuhiro Yasufuku, MD., PhD, FCCP.<sup>2</sup>

Takehiko Fujisawa, MD.<sup>2</sup>

**OBJECTIVE.** To evaluate sensitivity and specificity of EBUS-TBNA for aspiration biopsy mediastinal lymphadenopathy.

**MATERIALS AND METHODS.** A total of 150 patients were studied: the mediastinal lymph node was range 0.5-5.0 cm. under EBUS-TBNA.

**RESULTS.** The sensitivity was 97%.

**CONCLUSION.** Given the high sensitivity, we conclude EBUS-TBNA may benefit the current diagnosis and staging of cancer.

<sup>1</sup> Samitivej Hospital, Thailand. The Bangkok Hospital Group, Bangkok, Thailand.

<sup>2</sup> Department of Thoracic Surgery, Graduate School of Medicine, Chiba University, Tokyo, Japan.

## Keywords:

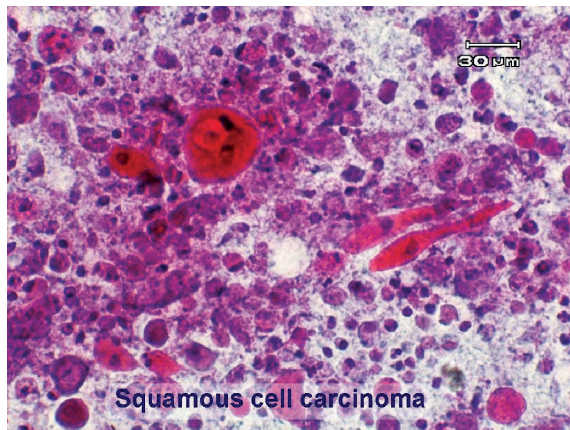
Endobronchial ultrasound, Transbronchial needle aspiration, Lung cancer, Mediastinal lymph node biopsy, Thoracotomy.

We described our technique for performing Endobronchial ultrasound-guided transbronchial needle aspiration (EBUS-TBNA) upon 150 patients with mediastinal lymphadenopathy using a curved linear array ultrasonic bronchoscope that allowed for aspiration biopsy under real-time ultrasound imaging. EBUS-TBNA provided definitive diagnoses for benign diseases such as tuberculosis and accurate staging of lung cancer. The overall sensitivity was 97%. Seven patients with a lung nodule and mediastinal lymphadenopathy were recruited to proof the results of EBUS-TBNA by thoracotomies. There were 4 patients with lung cancer. Four lymph nodes with cancer metastasis were detected via EBUS-TBNA from 5 nodes identified by surgery. Nine lymph nodes with no cancer invasion were confirmed by thoracotomy. The sensitivity was 80% and the specificity was 88.9%.

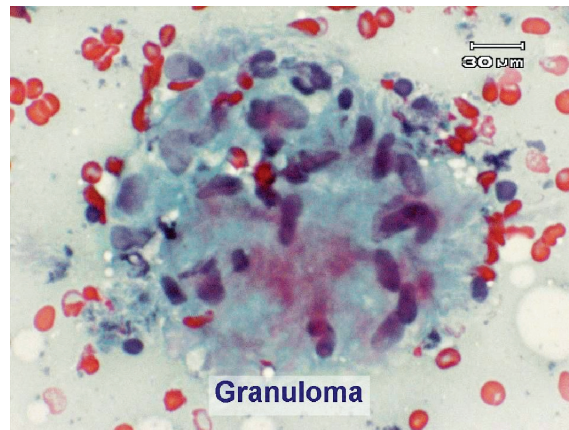
Endobronchial ultrasound guided TBNA (EBUS-TBNA) is a minimally invasive real-time procedure which has been shown to have a high yield for the evaluation of the mediastinum.<sup>1-4</sup> Here we report our experience of EBUS-TBNA for mediastinal lymphadenopathy.

## Materials and Methods

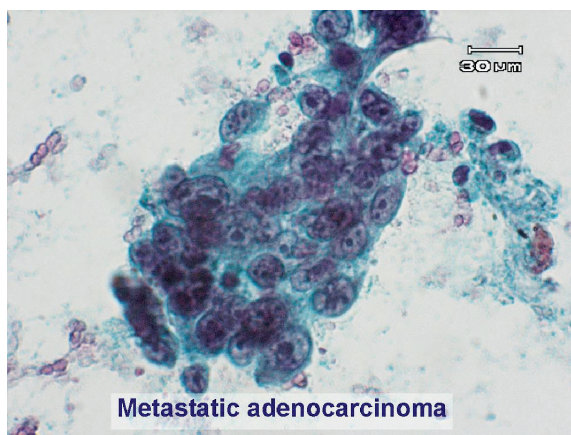
Patients whose computer scan of the chest revealed mediastinal lymphadenopathy were considered to undergo endobronchial ultrasound-guided transbronchial needle aspiration (EBUS-TBNA). Patients with bleeding tendency, active pulmonary tuberculosis, or on respiratory support with positive end expiratory pressure were excluded. Informed consent was obtained in all patients. Six patients with a lung nodule and mediastinal lymphadenopathy were recruited to proof the results of EBUS-TBNA by thoracotomies.



A



B



C

*Figure A-C: revealed pathology of squamous cell carcinoma (A), granuloma (B) and adenocarcinoma (C)*

## Results

Three patients were excluded, one had active tuberculosis, and the other two had bleeding tendency. One hundred and fifty patients underwent EBUS-TBNA. There were 68 females and 82 males. Their ages ranged from 22 to 75 years old. One hundred and nineteen were Thai, twenty-five were Japanese; there was also one patient from each of the following countries: Cambodia, Kenya, Dubai, France, England and Canada.

EBUS-TBNA successfully sampled lymph node tissue from 145 out of 150 patients (97%). The average of the short axis diameter of the mediastinal lymph nodes was 1.2 cm. (range 0.5 cm - 5 cm). There were no complications during any of the procedures.

There were fifty-six cases of tuberculosis, fifty-six cases of adenocarcinomas, ten of squamous cell carcinoma; two of metastatic carcinoma and two were malignant lymphoma. Normal lymphoid tissues were obtained from twenty patients. Four patients were diagnosed with sarcoidosis. Seven patients with a lung nodule and mediastinal lymphadenopathies were recruited to proof the results of EBUS-TBNA by thoracotomies.

There were 4 patients with lung cancer. Four lymph nodes with cancer metastasis were detected via EBUS-TBNA from 5 nodes identified by surgery. Nine lymph nodes with no cancer invasion were confirmed by thoracotomy. The sensitivity was 80% and the specificity was 88.9%.

## Discussion

The sensitivity of EBUS-TBNA was 97% in our current study. This high degree of effectiveness clearly indicates advantages in managing patients with mediastinal lymphadenopathy, in terms of making accurate diagnoses and staging of lung cancer. EBUS-TBNA was very helpful in a patient who developed carcinoma in situ at the carina with a 2-cm. short axis diameter subcarinal node. The subcarinal lymph node was disclosed to be tuberculosis via EBUS-TBNA. Electrocautery technique was employed to destroy the carcinoma in situ completely. The patient's diagnosis of inoperable lung cancer due to carinal involvement and likely to be stage 4, turned out in fact, to be a curable lung cancer with tuberculosis of mediastinal lymph node. Without this definite diagnosis, she may have undergone a chemotherapy program treatment and may have suffered from spreading of tuberculosis.

Three months later, following the anti-tuberculous drugs, the mediastinal node had completely disappeared. EBUS-TBNA has been reported to be useful in the diagnosis of sarcoidosis with the diagnosis yield of 91.8%.<sup>5</sup> In our current series we experienced 4 cases of sarcoidosis. In one patient, who presented with blurred vision due to uveitis, mediastinal lymphadenopathy was present. EBUS-TBNA revealed non-caseous granuloma.

Lymphoma was detected in only two cases. The disease is quite difficult to diagnose: only 50% of the cases could be proved by EBUS-TBNA.

### Conclusion

The sensitivity of our EBUS-TBNA was 97%. The technique offered correct tissue diagnosis and staging of lung cancer. Potentially operable patients with clinically nonmetastatic, non-small cell lung cancer may benefit from pre-surgical EBUS-TBNA biopsies and staging.

### References

1. Yasufuku K, Chajed PN, Sekine Y, et al. Endobronchial ultrasound using a new convex probe : a preliminary study on surgically resected specimens. *Oncol Rep* 2004;11: 293-296
2. Yasufuku K, Chiyo M, Sekine Y, et al. Real-time endobronchial ultrasound-guided transbronchial needle aspiration of mediastinal and hilar lymph nodes. *Chest* 2004;126:122-128
3. Rintoul RC, Skwarski KM, Murchison JT, et al. Endobronchial and endoscopic ultrasound-guided real-time fine-needle aspiration for mediastinal staging. *Eur Respir J* 2005;25:416-421
4. Vilmann P, Krasnik M, Larsen SS. et al. Endoscopic transesophageal and endoscopic-ultrasound guided biopsy : a combined approach in the evaluation of mediastinal lesions. *Endoscopy* 2005;37:833-839
5. Wong M, Yasufuku K, Nakajima T, et al. Endobronchial Ultrasound: new insight for the diagnosis of sarcoidosis. *Eur Respir J* 2007;29:1182-1186