

Melioidosis and Pandemic Influenza

Paithoon Boonma, MD.¹

Secondary bacterial pneumonia complication after influenza viral infection is the major caused of death in pandemic influenza of an out break in 1918 and multiple subsequent epidemic and inter-epidemic periods.¹

The bacteria commonly reported complication after influenza are *Streptococcus pneumoniae*, *Staphylococcus aureus* and *Haemophilus influenzae*.^{2,3} Occasionally other bacterial reports varied to the endemic pathogens. The report 2 cases of probable melioidosis complicated after influenza viral pandemic 2009 are presented.

Case 1

¹ Bangkok Hospital, Bangkok Hospital Group, Bangkok, Thailand.

A 78-year-old man presented with history of relapsed fever after he was treated for influenza A viral infection. About 7 days before this admission, he developed an acute febrile illness with coryza symptoms and body pain. He came to Bangkok Hospital and the screening viral influenza A from nasal secretion was positive. He was treated with Oseltamivir for 5 days. His symptoms was rapidly improved. 2 days prior to admission, he had fever with coughing and progressive right chest pain.

Keywords:
Melioidosis, Pandemic Influenza

The chest x-ray revealed patchy infiltration at right lower lung (Figure 1a). Total White blood cell count (WBC) had increased to 18,800 cell/mm³ with 90% of Polymorphonuclear (PMN). He was treated as bacterial pneumonia complicated after influenza A viral infection with Amoxicillin/Clavulanic acid and Moxifloxacin.

During the first 3 days of hospitalization, fever persisted and chest pain was not improved. The follow up chest x-ray revealed progressive patchy infiltration with right plural effusion (Figure 1b).

Sputum culture grew *E.coli* and *Staphylococcus aureus* which they were all susceptible to the antibiotics therapy.

Because of his clinical deterioration of clinical pneumonia, antibiotic had changed to Imipenem/Cilastatin and Co-trimoxazole. By the time, the results of melioidosis titer showed rising from < 1:80 to 1:320. (Table 1) His clinical was gradually improved with the new antibiotics therapy. Fever gradually subsided and less chest pain. Follow up chest x-ray showed almost clear infiltration and right plural effusion (Figure 1c)

Antibiotics had switched to oral Amoxicillin/Clavulanic acid for another 2 months.

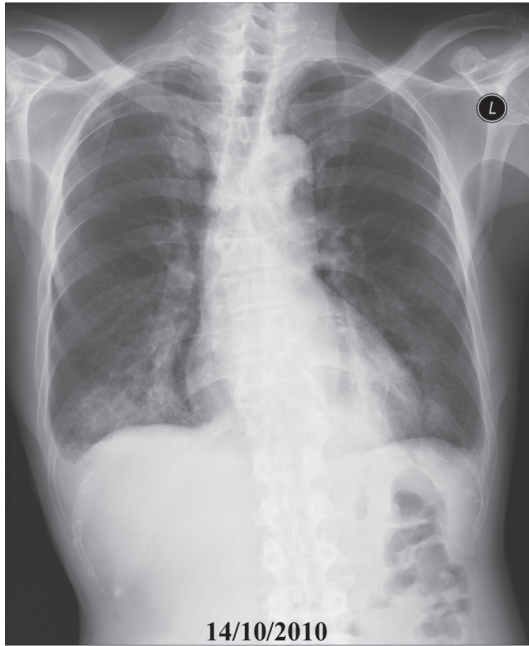


Figure 1a: The chest x-ray shows patchy infiltration at right lower lung.

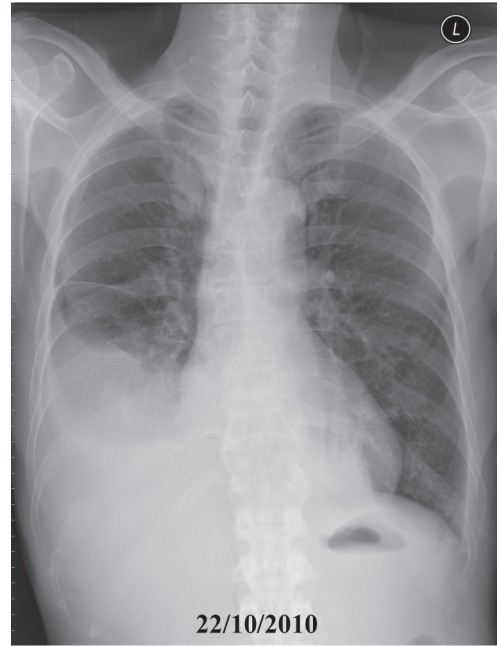


Figure 1b: The chest x-ray shows progressive patchy infiltration with right pleural effusion.

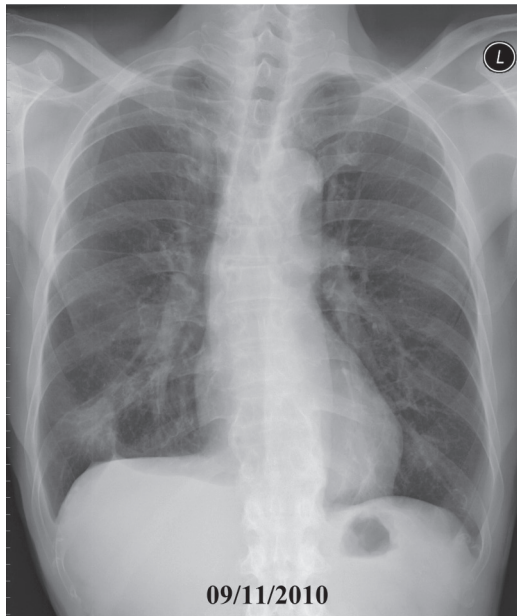


Figure 1c: The chest x-ray shows almost clear infiltration and right pleural effusion.

Table 1: Results of Total WBC, melioidosis titer and C reactive protein (CRP) related to antibiotic(s) therapy.

Date	WBC (cell/mm ³)	Melioidosis titer	CRP	Antibiotic therapy
14/10/2010	18,880	<1:80	-	Amoxicillin/Clavulanic acid + Moxifloxacin
19/10/2010	26,350	<1:80	194.3	Imipenem/Cilastatin, Co-trimoxazole
21/10/2010	15,610	1:320	-	
25/10/2010	9,050	1:80	-	Amoxicillin/Clavulanic acid
05/11/2010	5,330	<1:80	1.75	

Case 2

A 22-year-old obese young man (body weight 110 kg., height 178 cm.) was transferred to Bangkok Hospital for proper management of severe influenza A pneumonia.

About 5 days prior to this admission, he was sick from acute fever, sore throat, malaise and body aching for 2 days. He admitted in a hospital and investigations of nasopharyngeal secretion was positive for influenza A H1N1 2009. Chest x-ray revealed minimal interstitial infiltration at lower lungs. Initially he was treated with Oseltamivir but the fever persisted and clinical deterioration to progressive dyspnea in 2 days. Empirical antibiotics were added with Cefepime and Levofloxacin. The patient transferred to Bangkok hospital and was admitted in an intensive care unit. He was clinically ill with dyspnea and orthopnea. The oxygen saturation at room air was only 85%. He was on BIPAP ventilator with 100% oxygenation.

Septic work up for caused of pneumonia associated with influenza A was done. Chest x-ray revealed progressive diffuse pulmonary infiltration (Figure 2a).

The echocardiogram revealed good Left ventricular contraction (EF = 63%), no left ventricular hypertrophy and normal heart valves. No pericardial effusion. Because the patient had a criteria of high body mass index (31.9 kg/m^2) that would develop severe influenza A complication, antibiotic empirical therapy started immediately with Oseltamivir, Ceftazidime and Dalacin C. Those regimen would coverage most possible pathogens for his pneumonia. The patient had good clinical responded from the treatment that could observed in the first 24 hours. The patient could wean off BIPAP ventilator and transferred to regular ward in 3 days. For results of septic work up, there was no significant pathogen found except the high serology of melioidosis titer = 1:640 and the titer had rising to 1:1280 in a week later (Table2). Oseltamivir prescribed for 10 days. Antibiotic had switch to oral Amoxicillin/Clavulanic acid and Co-trimoxazole on discharged hospitalization day.⁷ The chest x-ray during follow up period showed decrease pulmonary infiltration (Figure 2b) and after treatment about a month, chest x-ray showed completely clear. (Figure 2c)

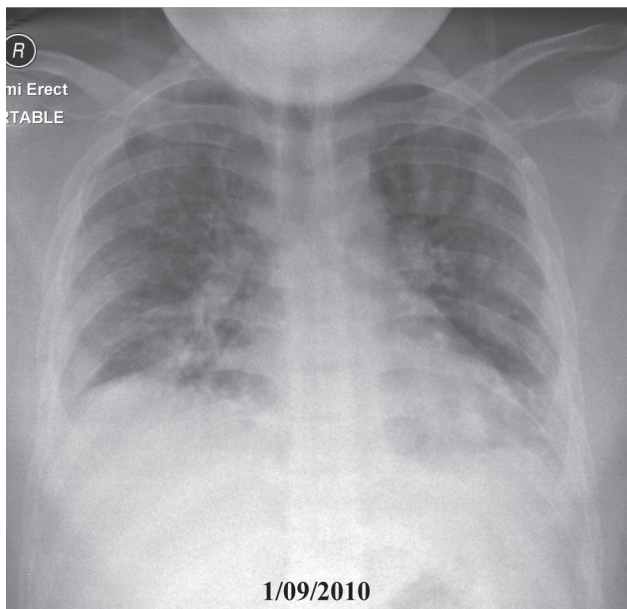


Figure 2a: The chest x-ray reveals progressive diffuse pulmonary infiltration.

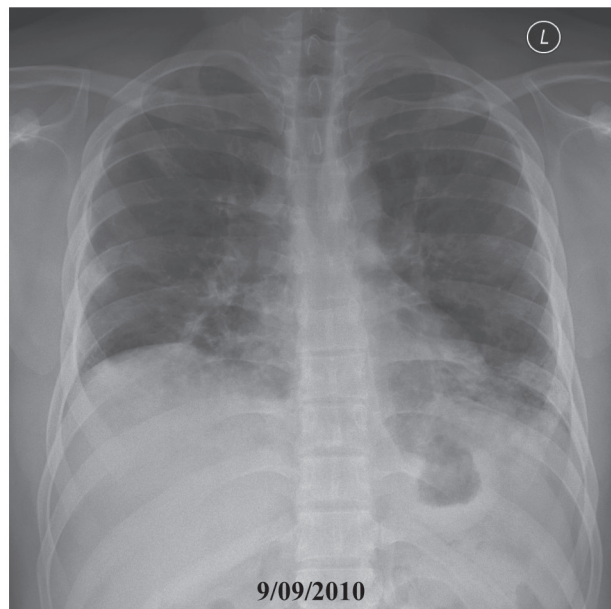


Figure 2b: After Treatment; chest x-ray shows decrease pulmonary infiltration.

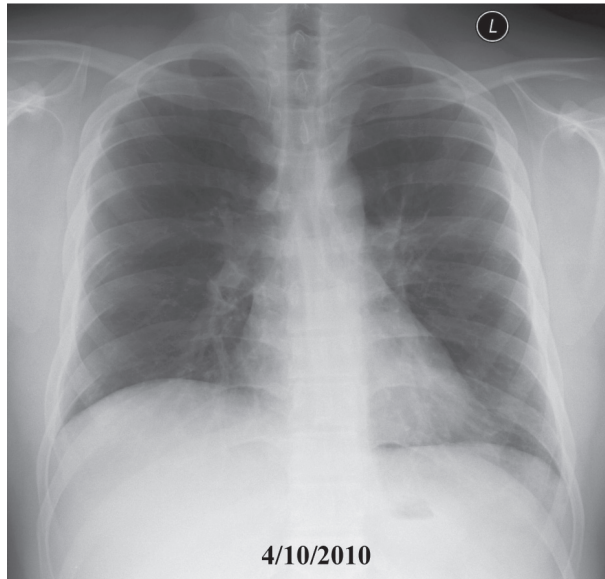


Figure 2-3: After Treatment about 1 month; Chest x-ray shows completely clear.

Table 2: Result of Total WBC, melioidosis titer and C reactive protein (CRP) related to antibiotic(s) therapy.

Date	WBC (cell/mm ³)	Melioidosis titer	CRP	Antibiotic therapy
30/08/2010	4,660	1:640	44.98	Ceftazidime, Dalacin C
03/09/2010	6,840	1:640	-	Imipenem/Cilastatin
09/09/2010	10,520	1:1,280	-	Co-trimoxazole + Amoxicillin/Clavulanic acid
25/10/2010	11,210	1:1,280	24.30	

Discussion

Melioidosis caused by the bacteria *Burkholderia pseudomallei*. The organism presents in soil and surface water in endemic area of South East Asia and Northern Australia. Infection usually follows percutaneous inoculation or inhalation of the causative organism.^{4,5,6}

Clinical presentations varied from asymptomatic, subacute and chronic infection to an acute disseminated septicemia which has high mortality rate up to 80-90%.⁷ Infection can occur long after exposure to endemic area many years later.^{8,9} About 60% had underlying disease e.g. Diabetes mellitus, chronic kidney and chronic liver disease.

Pulmonary infection is the most common site of more than 50% of patients. The disease has high prevalence during many seasons.^{5,6}

Interestingly, melioidosis is rarely reported to be complicated after influenza viral infection particularly

in the endemic area. This might be that influenza viral is rarely tested for inpatient whom admitted with community acquired pneumonia.

Since the pandemic influenza A H1N1 2009 outbreak during 2009-2010, physicians were informed early detection of this viral outbreak and therefore, beware of its complication particularly in high risk patients.

To my knowledge, only one case reported of melioidosis had complicated after influenza A infection.⁸ The disease activation occurred long after exposure to a known endemic area in Vietnam six years ago. This case demonstrates the potential of melioidosis to appear long after departure from endemic area and recrudescence had been reported in association with a variety of stressful event such as thermal injury, after surgery, diabetic ketoacidosis and infection associated e.g. pneumococcal pneumonia, dengue hemorrhagic fever, Mycobacterial disease⁴ and influenza A.⁸

Most antibiotic recommended for treatment community acquired pneumonia¹⁰ do not have broad activity to coverage severe melioidosis. Ceftazidime and Imipenem/Cilastatin have well been on clinical control trials that could decreased mortality rate in severe septicemia melioidosis more than 50 percent.^{11,12,13,14}

2 cases report, demonstration that melioidosis might also be one of the pathogens complication after influenza A infections. Through, the organism could not detection from the clinical specimen, their serologic study, melioidosis titer had rising significantly. They could be diagnosed probably melioidosis.⁷

Therefore melioidosis should be considering particularly cases of pneumonia from endemic area which was not responded to those antibiotics commonly used for community acquired pneumonia.

Conclusion

Report 2 cases of influenza A viral infection and developed pneumonia complication from probable melioidosis. They had good clinical responded to antimelioidosis-antibiotic treatment.

References

1. Morens DM, Taubenberger JK and Fauci AS. Predominant role of Bacterial Pneumonia as a cause of death in pandemic influenza : Implications for Pandemic Influenza Preparedness. *J Infect Dis* 2008;198(7): 962-970
2. Rothber MB, Haessler SD, Brown RB. Complication of Viral Influenza. *J Am J Med* 2008;121:258-264
3. Hageman JC, Uyeki TM, Francis JS, et al. Severe Community acquired Pneumonia Due to Staphylococcus aureus, 2003-04 Influenza Season. *Emerg Infect Dis* 2006;12(6):894-899
4. Cheng AC, Lurie BJ. Melioidosis: Epidemiology, pathophysiology and Management. *Clin Microbial Rev* 2005;18(2):383-416
5. Currie BJ. Melioidosis: an important cause of pneumonia in residents of and travelers returned from endemic regions. *Eur Respir J* 2003;22:542-550
6. Leelarasamee A. Melioidosis in Southeast Asia. *Am J Trop Med Hyg* 1999;60:458-461
7. Punyagupta S. Melioidosis. Review of 686 cases and presentation of a new clinical classification. In Punyagupta S, Sirisonthana T, Stapatayavong B, eds. Melioidosis. Bangkok. *Bangkok Medical Publisher* 1989;217-229
8. Mackowick PA, Smith JW. Septicemic melioidosis. Occurrence following acute influenza six years after exposure in Vietnam. *JAMA* 1978;240:704-766
9. Currie B, Smith VH, Golledge C, et al. Pseudomonas pseudomellis isolates collected over at years from a non-tropical endemic focus show clonality on the basis of ribotyping. *Epidemiology Infect* 1994;113:307-312
10. Shah PB, Giudice JC, Griesback R, et al. The Newer Guidelines for the Management of Community-Acquired Pneumonia. *JAOA* 2004;104(12):521-526
11. Sookpranee, M, Boonma P, Sudaengrat W, et al. Multicenter prospective randomized trial comparing ceftazidime plus co-trimoxazole with chloramphenicol plus doxycycline and co-trimoxazole for treatment of severe aelioidosis. *Antimicrob. Agents Chemother* 1992;36:158-162
12. Thamprajamchit S, Chetchotisakd P, Thinkhamrop B. Cefoperazone/sulbactam + co-trimoxazole vs. ceftazidime + co-trimoxazole in the treatment of severe melioidosis: a randomized, double-blind, controlled study. *J. Med. Assoc Thai* 1998;81:265-271
13. Boonma P, Boonsavat W, Patjanasoontron B, et al. The Efficacy of Imipenem/Cilastatin in the Treatment of Melioidosis : Preliminary Report from Srinagarind Hospital. *J Infect Dis Antimicrob Agents* 1990;7:65-69
14. Simpson A, Suputtamongkol Y. Comparison of imipenem and ceftazidime as therapy for severe melioidosis. *Clin Infect Dis* 1999;19(2):381-387