

## Diagnosis of peripheral lung lesions (PPLs) by endobronchial ultrasonography, with guide sheath transbronchial biopsy



Saenghirunvattana S, MD  
email : ssaenghir@samitivej.co.th

Sawang Saenghirunvattana, MD<sup>1</sup>  
Surapol Israpaibool, MD<sup>1</sup>  
Chana Buakham, MD<sup>1</sup>  
Noriaki Kurimoto, MD<sup>2</sup>

<sup>1</sup> Samitivej Hospital, Bangkok Hospital Group, Bangkok, Thailand.

<sup>2</sup> St. Marianna Hospital, Japan.

### Keywords:

Endobronchial Ultrasonography (EBUS), Guide sheath (GS), Peripheral lung lesions (PPLs)

**OBJECTIVE.** To study the effectiveness of Endobronchial Ultrasonography (EBUS) with Guide Sheath (GS) in detecting peripheral lung lesions.

**MATERIALS AND METHODS.** Between January and March 2011, 8 patients gave their informed consent to EBUS with GS being performed.

**RESULTS.** In 7 patients (87.5%) EBUS detected the PPLs.

**CONCLUSION.** EBUS is a useful and accurate tool for diagnosis of PPL.

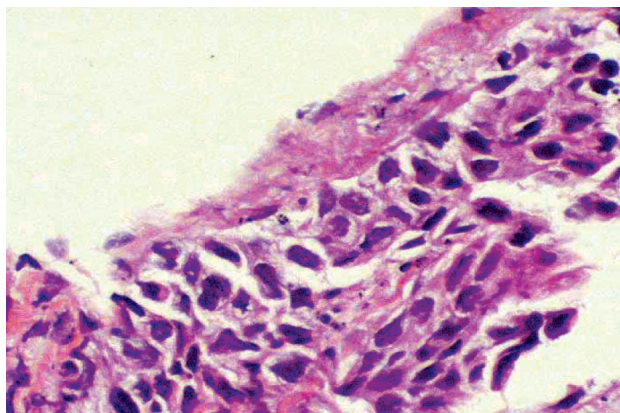
In Thailand, which is an endemic area of tuberculosis, patients may often present with lung nodules which mimic lung cancer. Making diagnosis without requiring patients to undergo major surgery, such as an open thoracotomy has been difficult: the majority of cases are elderly and undernourished, heavy smokers, with poor pulmonary functions; they may also be under financial constraints, especially those from the northeast part of Thailand. Since the 1970's, fiberoptic bronchoscopy under fluoroscopy has become an accepted, diagnostic tool. However, if lesions are > 2 cm, the yields can be as low as 11-42%.<sup>1-5</sup> Whilst there is a higher accuracy rate in diagnoses of PPLs from tissue samples taken via percutaneous needle biopsy or aspiration, (76-97%),<sup>1,6</sup> these techniques are not without hazards for patients; pneumothorax risks may increase, or malignant cells can be spread into the pleural cavity.<sup>7,8</sup> Small calibre ultrasound probes have now been developed which can be introduced into the trachea and bronchus to assess endobronchial lesions. Kurimoto et al., demonstrated use of EBUS to differentiate between benign or malignant tumours.<sup>9</sup> This study intended to study the effectiveness of EBUS with GS in detecting PPLs.

### Materials and Methods

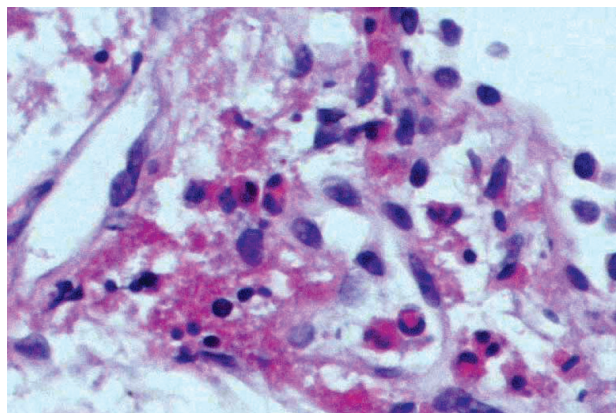
Between January 1, 2011 and March 31, 2011, 8 patients, with PPLs shown by CT to be < 30 mm in mean diameter, were referred for diagnostic bronchoscopy, and were enrolled after giving their informed consent. EBUS was performed. After using EBUS to localise the lesions, biopsy forceps and a bronchial brush were introduced via the GS to conduct the cytologic examination.

### Results

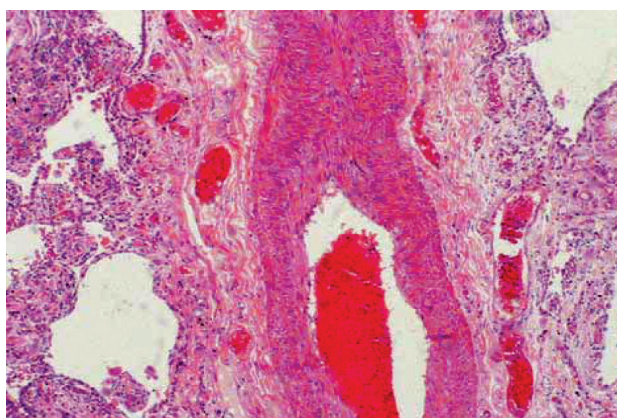
A total of 8 patients, consisting of 7 Thais and one Japanese (4 males) with an average age of  $58.4 \pm 11.3$  years were examined. The mean diameter of the PPLs was  $17.6 \pm 7.5$  mm (9-26.5 mm). Location of the PPLs was the right upper lobe in two patients, the



*Figure 1: Adenocarcinoma of the lung.*



*Figure 2: Increased subepithelium eosinophil.*



*Figure 3: Sequestration, abnormal systemic artery.*

right middle lobe in one patient, the right lower lobe in two patients, the left upper lobe in one patient and the left form lobe in two patients. In 7 patients (87.5 %) EBUS detected the PPLs; these patients accordingly underwent guide sheath-guided transbronchial biopsy (TBB) and bronchial brushing. In 6 cases (75%) diagnosis was made; there were 2 cases of primary lung cancer (Figure 1), one case of eosinophilic pneumonia (Figure 2), and 3 cases of tuberculosis. In the one patient where EBUS could not detect the lesion, surgery appeared to reveal it as sequestration of the lung (Figure 3). The pathology showed there was no connecting airway which is why the ultrasound did not detect the lesion.

We had no complications arising for the patients in this study, such as major bleeding, pneumothorax or infection. Most cases were discharged within 24 hours, with the exception of the sequestration, thoracotomy patient, and the patient with eosinophilic, interstitial pneumonia who needed treatment with intravenous steroids.

#### Discussion

Our small study has shown the usefulness and accuracy of endobronchial ultrasonography in identifying PPLs. It is a promising new diagnostic technique particularly suitable for areas endemic to tuberculosis, such as Thailand.

## References

1. Schreiber G, McCrory DC. Performance characteristics of different modalities of suspected lung cancer: summary of published evidence. *Chest* 2003;123(Supl.1): 115-28.
2. Baaklini WA, Reinoso MA, Gorin AB, et al. Diagnostic yield of fiberoptic bronchoscopy in evaluating solitary pulmonary nodules. *Chest* 2000;117:1049-54.
3. Stringfield JT, Markowitz DJ, Bentz RR, et al. The effect of tumor size and location on diagnosis by fiberoptic bronchoscopy. *Chest* 1977;72:474-6.
4. Gasparini S, Ferretti M, Secchi EB, et al. Integration of transbronchial and percutaneous approach in the diagnosis of peripheral pulmonary nodules or masses: experience with 1,027 consecutive cases. *Chest* 1995; 108:131-7.
5. Naidich DP, Sussman R, Kutcher WL, et al. Solitary pulmonary nodules: CT bronchoscopic correlation. *Chest* 1988;93:595-8.
6. Tsukada H, Satou T, Iwashima A, et al. Diagnostic accuracy of CT-guided automated needle biopsy of lung nodules. *Am J Roentgenol* 2000;175:239-43.
7. Sawabata N, Ohta M, Maeda H. Fine-needle aspiration cytologic technique for lung cancer has a high potential of malignant cell spread through the tract. *Chest* 2000; 118:936-9.
8. Seyfer AE, Walsh DS, Graeber GM, et al. Chest wall implantation of lung cancer after thin-needle aspiration biopsy. *Ann Thorac Surg* 1989;48:284-6.
9. Kurimoto N, Murayama M, Yoshioka S, et al. Analysis of the internal structure of peripheral pulmonary lesions using endobronchial ultrasonography. *Chest* 2002;122: 1887-94.