

Prolonged Fever with Massive Hemoptysis



Boonma P, MD

email : paithoon@bgh.co.th

Paithoon Boonma, MD¹

Suthep Sachthep, MD²

¹ Infectious Clinic, Bangkok Hospital, Bangkok Hospital Group, Bangkok, Thailand.

² Arthritis & Rheumatic Clinic, Bangkok Hospital, Bangkok Hospital Group, Bangkok, Thailand.

Keywords:

Fever, Massive Hemoptysis, Wegener Granulomatosis

Last year in November, a 58-year-old man was referred to our hospital for further diagnosis and treatment. He presented with prolonged fever which further developed into severe haemoptysis and he subsequently died. This patient had a very interesting clinical presentation over the period of his sickness. We believe that reviewing this case will help all clinicians to be more aware of the importance of early recognition and understanding the time variable development of this disease; earlier treatment may result in a better outcome.

The patient was a middle aged man, working as a government officer, who had no known underlying disease. Around one month prior to admission, he had a low grade fever, mild coughing, anorexia, and feelings of general malaise. He sought medical treatment in his local clinic and was given the diagnosis of bronchitis. A week later, his fever still persisted and general symptoms were not improved. He was admitted in another hospital where the radiographic study of chest revealed a patchy infiltration at right lower lobe. A full septic work up was completed, but which resulted in no suggestive diagnosis and he was treated with Ceftriazone.

Intravenous antibiotic was switched to Piperacillin-Tazobactam after the sputum culture grew a few colonies of E.Coli. Even after intravenous antibiotic therapy for a week, his fever persisted. Computer tomography of chest revealed patchy infiltration or a mass like lesion at right lower lobe with minimal bilateral plural effusion. A needle biopsy from the right lower lobe revealed chronic inflammation though testing negative for organisms. The results could not yield any definite diagnosis. Therefore, the patient underwent a bronchoscopy for endobronchial biopsy of the lesion as well as bronchiolar lavage. There were no pathogens detected in clinical specimens; tests included gram stain, modified acid fast stain and acid fast stain. Pathologic study of endobronchial biopsy showed chronic granulomatous inflammation whereas the special stain for mycobacterial was negative.

Because of the prolonged course of fever, lasting more than 20 days, and the abnormal lung lesion showing granulomatous inflammation, the treating physician suspected mycobacterial infection. The patient was thus treated with anti-mycobacterial medications. Unfortunately, the medication had to cease for a week due to the patient's development of hepatitis.

One day prior to the admission of the patient to Bangkok Hospital, he developed dyspnea and hypoxia due to severe hemoptysis. He was transferred to the intensive care unit to stabilize his acute respiratory distress. Imipenem and Amphotericin B were started. The patient was then transferred to our hospital for an open lung biopsy and further

treatment. At Bangkok Hospital the initial physical examination revealed a body temperature of 38.5 °C. Blood pressure was 118/70 mmHg. Heart rate was 110/min, respiratory rate was 20/min. The patient was conscious, on endotracheal intubation with ventilation support. He had pale conjunctiva and no icterus sclera. Auscultation disclosed bilateral rhonchi. Other physical examinations were unremarkable. Chest x-ray (Figure 1) revealed infiltration at right upper lobe and left lower lobe with dense or mass like lesion infiltration at right lower lobe. Complete blood count showed white blood cells of 23,320 cells/cm³, hemoglobin 9.1 gm/dL and hematocrit 27.4%, differential count found polymorphonuclear 92%, lymphocyte 5% and platelet 467,000 cells/mm³. Serum creatinine 0.1 mg/dL, Total protein 5.38 gm/dL, Albumin 1.9 gm/dL, Total bilirubin 0.7 mg/dL, ALT 107 U/L, AST 189 U/L, Prothrombin time was 20.4 sec, Fibrinogen 625 mg/dL, Ferritin 17.128 ng/mL, Erythrocyte sedimentation rate (ESR) 109 mm/hr, C-reactive protein (CRP) 121.29 mg/L.

Sputum examination found bloody secretion and under the microscope, revealed numerous red blood cells with moderate white blood cells. No organism was seen.

Hospital course:

On his first hospitalization day in Bangkok Hospital, the patient had a high grade fever of 39.5°C with obvious massive hemoptysis and chest x-ray showed progressive bilateral pulmonary infiltration (Figure 2). The differential diagnoses for this patient's illness included autoimmune diseases such as vasculitis syndrome. An ENT (Ear-Nose-Throat) specialist was consulted for evaluation and found no evidence of sinusitis. Because the patient's condition was currently too critical for further invasive investigation, such as the planned open lung biopsy, we had started him on a high dose dexamethazone. Lysis of the fever thus ensued within 24 hours (Figure 3). Although we tried to control the massive hemoptysis by blood components replacement, his bleeding still continued. The patient passed away 2 days later from severe hypoxemia. The result of the blood test for c-ANCA/Anti-PR3 was positive of high titer (Table 1). This was the most important evidence for diagnosis, and we concluded that the patient's illness was caused by the autoimmune disease, vasculitis in small-medium-sized blood vessels, better known as Wegener's Granulomatosis.

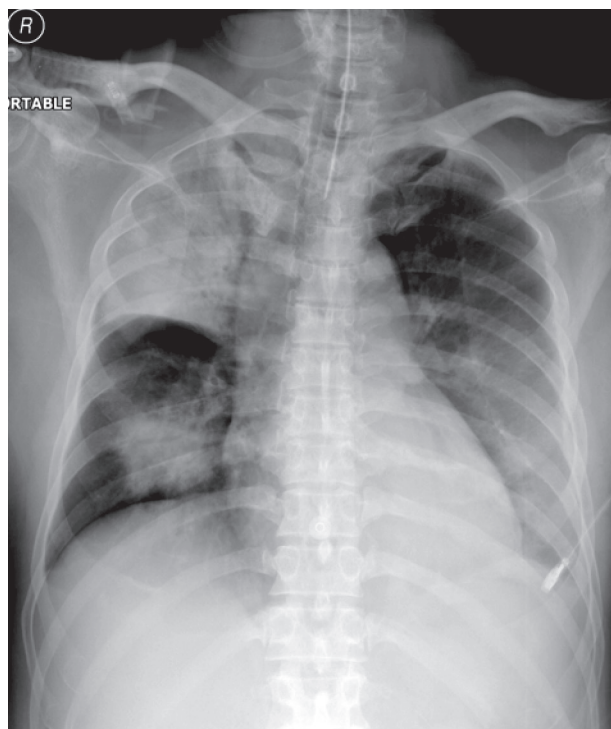


Figure 1: Admission day, chest x-ray showed infiltration at right upper lobe and left lower lobe with dense or mass like lesion infiltration at right lower lobe.

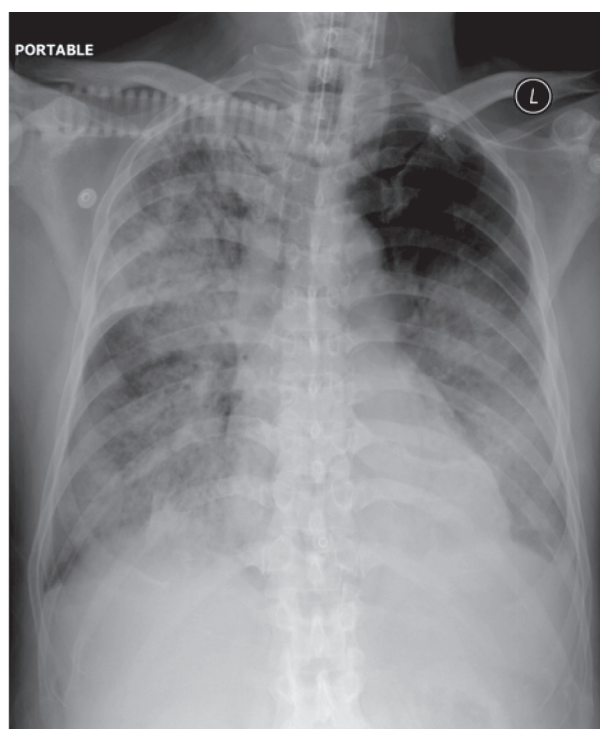


Figure 2: On Day 2, chest x-ray showed progressive pulmonary infiltration at both lungs.

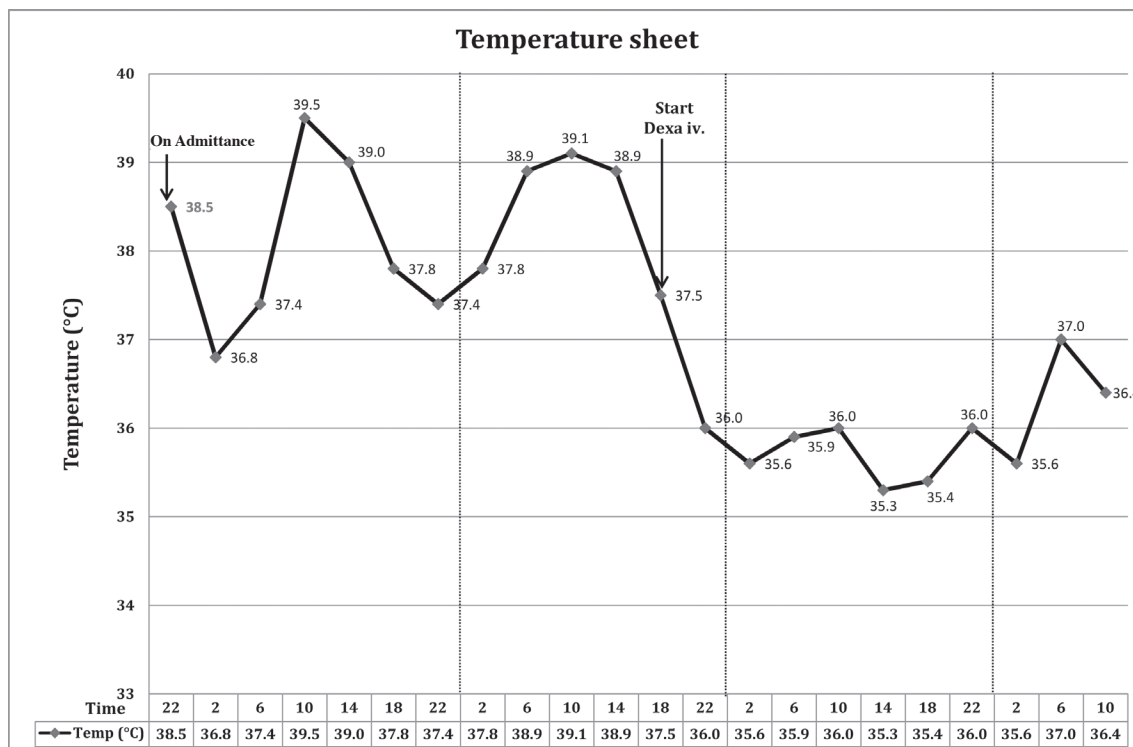


Figure 3: Temperature sheet shows patient's high grade fever during the first 2 days of hospitalization and lysis of fever with demonstration therapy.

Table 1: Result of the Anti-Neutrophil cytoplasmic antibody (ANCA).

Anti Neutrophile Cytoplasmic Antibody (ANCA)	Value (U/mL)	Normal (U/mL)
p-ANCA/MPO, Myeloperoxidase Antibodies	< 2.00	0.00 - 20.0
p-ANCA/MPO, Myeloperoxidase Antibodies	Negative	
c-ANCA/PR3, Proteinase 3 Antibodies	> 200.00 H	0.00 - 20.0
c-ANCA/PR3, Proteinase 3 Antibodies	Positive	

Discussion

This patient presented to our hospital with a history of prolonged fever and right lower lung lesion which had not responded to standard antibiotics. His condition had deteriorated further with the sign of hemoptysis. Taken together, the differential diagnosis needed to be reevaluated and the diagnosis of chest infection with possibility of tuberculosis was unlikely. The second most common differential diagnosis would be an autoimmune disease such as systemic vasculitis. However, the unusual presentation of a malignant tumor could not be ruled out. The treating physician approached the patient step by step from non invasive to invasive investigations. When we had reviewed all investigations, the finding of chronic

granulomatous inflammation from endobronchial biopsy was of interest. Chronic granulomatous lesion in the lung along with prolonged fever would usually lead to the diagnosis of tuberculosis. However, later on, he presented with diffuse alveolar hemorrhage.

Combining all the findings together, the most intriguing diagnosis would be Wegener's Granulomatosis (WG). WG has the hall mark of necrotizing granulomatosis and pauci-immune vasculitis. We did have the ENT specialist review any evidence of chronic sinusitis with the report of negative finding although the negative result could not rule out WG. There was also no clinical finding of

renal disease that would also support a diagnosis of WG. Interestingly enough, one dosage of dexamethasone reduced the patient's fever but no definite diagnosis could be implied by this. When we discovered the c-ANCA positive in high titer in this patient, it more or less confirmed the diagnosis of WG.

Wegener Granulomatosis (WG) was first described in 1936, on the basis of clinical findings and pathological study. Around 20 years later, the pathological triad of necrotizing angiitis, granulomatous inflammation in respiratory tract and kidneys had become the main features for the diagnosis and study of this disease.¹

At present, WG has been grouped into antineutrophil cytoplasmic antibody (ANCA)-associated vasculitides (AAVs) on the basis of autoantibody finding. Clinical presentation of WG is sometimes also classified into limited and severe type.²

Cellular and humoral immune responses are the major pathways in the pathophysiology of WG. Uncontrolled cellular immune responses contribute to granulomatous lesion along with the injury of the tissues via inflammatory cytokines. ANCA is the humoral immune response that mediates pathological process of diseases. The cytoplasmic staining pattern of ANCA or c-ANCA is specific for WG. The auto-antigen for c-ANCA has been identified as serine proteinase 3 (PR3). This antibody has no pathological role in vivo study.³

Patients with WG, if left untreated, suffer a mortality rate over 90%.⁴ The most common cause of death includes systemic infection, respiratory, cardiovascular and renal involvement.⁵ In USA and UK, the prevalence of the disease is around 1-3 cases per 100,000.⁴

The following symptoms are usual findings in patients with WG: constitutional symptoms, fevers, night sweats, fatigue, lethargy, loss of appetite and weight loss. Patients with unconventional presentation of chronic sinusitis will need to be well evaluated for other organs involvement, such as the eye. Saddle nose deformity caused by collapse of nasal support is also common and would lead to the diagnosis of WG.

Common respiratory tract findings in this disease are pulmonary infiltration (71%), cough (34%), haemoptysis (18%), chest discomfort (8%) and dyspnea (7%). Further progression of the disease in certain patients can lead to diffuse alveolar hemorrhage (DAH). Arthralgia or arthritis could be associated symptoms and signs but rarely develops into any permanent joint destruction.

Mononeuritis multiplex and cranial nerve abnormalities due to the vasculitis are not common findings in WG.⁶

Differential diagnoses for WG include: Churg-Strauss Syndrome, cocaine abuse, cryoglobulinemia, glomerulonephritis, Goodpasture syndrome, Hemolytic-uremic syndrome, Infective endocarditis, Langerhans Cell Histiocytosis, leukocytoclastic vasculitis, lung abscess, lung cancer, microscopic polyangiitis, Pneumonia, polyarteritis nodosa, sarcoidosis and systemic lupus erythematosus.

Complete blood count studied in WG often shows a mild normochromic normocytic anemia. Leukocytosis is also common, with a neutrophil predominance. The finding of eosinophilia often indicates other vasculitis syndromes, such as Churg-Strauss syndrome. Increase of inflammatory index as in ESR or CRP is common and may be used as an indicator with which to follow up response of treatment.

At present, there are two types of assays for ANCA: immunofluorescence technique (IF) and enzyme immunoassay technique (ELISA). ELISA provides the target antigen-specific character of ANCA and should be used to confirm IF findings. Autoantibody study by the above two techniques have increased the sensitivity and specificity for the diagnosis of AAV to 95% or above.

Other autoantibodies in WG may be slightly elevated as well e.g., rheumatoid factor or antinuclear antibodies (ANA).⁴ Two phases of treatments need to be carried out in WG, remission induction and remission maintenance, respectively. In 1970, the introduction of cyclophosphamide in WG resulted in 75% of patients expecting complete remission. Combination therapy with oral cyclophosphamide 2 mg/kg/day and prednisolone 1 mg/kg/day has been used in induction of remission in WG. Using pulsed intravenous cyclophosphamide as opposed to giving it orally should result in less cumulative exposure to cyclophosphamide. Subsequently, standard prophylaxes of Pnuemocystis and hemorrhagic cystitis should be implemented.⁷

High doses of glucocorticoids are an important part of remission induction therapy in WG. In the case of rapid progressive glomerulonephritis and/or alveolar hemorrhage or other life threatening conditions, intravenous pulse methylprednisolone should be applied without hesitation. Plasma exchange should be considered in patients with rapidly progressive renal diseases.⁸⁻¹⁰

Azathiopine, methotrexate and leflunomide should be used in remission maintenance. During the treatment, glucocorticoid should be tapered according to the clinical presentation and side effect of prednisolone itself.¹¹

Alternative therapies that are currently under study elsewhere are anti-CD20 immunoglobulin (IgG1) antibody,

intravenous immunoglobulin (IVIG), mycophenolate mofetil, anti-tumor necrosis factor (TNF) antibody, 15-Desoxyspergualin, antithymocyte globulin, anti-CD52 antibody.¹²⁻¹⁶

The remission rate in WG ranges from 30% - 95%. However 50% of patients developed relapses within the first 5 years of treatment. Factors associated with relapse include prednisolone dosage amounts, ANCA status at diagnosis and target organs involvement.¹⁷⁻¹⁹

Poorer survival rates are associated with older age, target organs damage and involvement.

References

- Hoffman GS, Kerr GS, Leavitt RY, et al. Wegener granulomatosis: an analysis of 158 patients. *Ann Intern Med* 1992;116:488-98.
- Kallenberg CGM. Pathogenesis of PR3-ANCA associated vasculitis. *J Autoimmun* 2008;30:29-36.
- Kallenberg CGM, Heeringa P, Stegeman CA. Mechanisms of disease: pathogenesis and treatment of ANCA-associated vasculitis. *Nat Clin Pract Rheumatol* 2006;2:661-70.
- Mukhtyar C, Guillevin L, Cid MC, et al. EULAR recommendations for the management of primary small and medium vessel vasculitis. *Ann Rheum Dis* 2009;68:310-7.
- Phillip R, Luqmani R. Mortality in systemic vasculitis: a systematic review. *Clin Exp Rheumatol* 2008;26:94-104.
- Fauci AS, Haynes BS, Katz P, et al. Wegener's granulomatosis: prospective clinical and therapeutic experience with 85 patients for 21 years. *Ann Intern Med* 1983;98:76-85.
- Frankel SK, Cosgrove GP, Fischer A. Update in the diagnosis and management of pulmonary vasculitis. *Chest* 2006;129:452-65.
- DeGroot K, Harper L, Jayne DRW, et al. Pulse versus daily oral cyclophosphamide for induction of remission in antineutrophil cytoplasmic antibody-associated vasculitis: a randomized trial. *Ann Intern Med* 2009;150:670-80.
- DeGroot K, Rasmussen N, Bacon PA, et al. Randomized trial of cyclophosphamide versus methotrexate for induction of remission in early systemic antineutrophil cytoplasmic antibody-associated vasculitis. *Arthritis Rheum* 2005;52:2461-9.
- Walsh M, Merkel PA, Mahr A, et al. Effects of duration of glucocorticoid therapy on relapse rate in antineutrophil cytoplasmic antibody-associated vasculitis: A meta-analysis. *Arthritis Care Res (Hoboken)* 2010;62:1166-73.
- Sanders JS, Slot MC, Stegeman CA. Maintenance therapy for vasculitis associated with antineutrophil cytoplasmic autoantibodies. *N Engl J Med* 2003;349:2072-3.
- Bosch X, Guilbert A, Espinosa G, et al. Treatment of antineutrophil cytoplasmic antibody associated vasculitis: a systematic review. *JAMA* 2007;298:655-69.
- Martinez V, Cohen P, Pagnoux C, et al. Intravenous immunoglobulins for relapses of systemic vasculitides associated with antineutrophil cytoplasmic autoantibodies: results of a multicenter, prospective, open-label study of twenty-two patients. *Arthritis Rheum* 2008;58:308-71.
- Joy MS, Hogan SL, Jennette JC, et al. A pilot study using mycophenolate mofetil in relapsing or resistant ANCA small vessel vasculitis. *Nephrol Dial Transplant* 2005;20:2725-32.
- Wegener's Granulomatosis Etanercept Trial (WGET) Research Group. Etanercept plus standard therapy for Wegener's Granulomatosis. *N Engl J Med* 2005;352:351-61.
- Walsh M, Chaudhry A, Jayne D. Long-term follow-up of relapsing/refractory anti-neutrophil cytoplasm antibody associated vasculitis treated with the lymphocyte depleting antibody alemtuzumab (CAMPATH-1H). *Ann Rheum Dis* 2008;67:1322-7.
- Mukhtyar C, Flossmann O, Hellmich B, et al. Outcomes from studies of antineutrophil cytoplasm antibody associated vasculitis: a systematic review by the European League Against Rheumatism systemic vasculitis task force. *Ann Rheum Dis* 2008;67:1004-10.
- Hellmich B, Lamprecht P, Gross WL. Advances in the therapy of Wegener's granulomatosis. *Curr Opin Rheumatol* 2006;18:25-32.
- Seo P. Wegener's granulomatosis: managing more than inflammation. *Curr Opin Rheum* 2008;20:10-6.

Conclusion

We reported a patient with unusual clinical manifestations of WG and an isolated lung lesion. The delays and complications in diagnosis unfortunately contributed in clinical deterioration to severe hemoptysis and the eventual death of this patient.