

# A Case of Lung Carcinoid Tumor, Successfully Treated with Bronchoscopic Cryosurgery in Thailand



Saenghirunvattana S, MD

Sawang Saenghirunvattana, MD<sup>1</sup>  
 Chittisak Napairee, MD<sup>1</sup>  
 Panthep Suttinont, MD<sup>1</sup>  
 Chao Saenghirunvattana, MD<sup>2</sup>  
 Maria Christina Gonzales, RN<sup>1</sup>  
 Kritsana Sutthisri, BSc<sup>1</sup>  
 Chitchamai Siangpro, BSc<sup>1</sup>

<sup>1</sup> Bangkok Hospital, Bangkok Hospital Group, Bangkok, Thailand.  
<sup>2</sup> Naresuan University, Phitsanulok, Thailand.

\* Address Correspondence to author:  
 Sawang Saenghirunvattana, MD  
 Bangkok Hospital, Bangkok Hospital Group,  
 2 Soi Soonvijai 7, New Petchburi Rd.,  
 Bangkok 10310, Thailand.  
 e-mail: sawang.sa@bangkokhospital.com

Received: July 23, 2015.  
 Revision received: July 24, 2015.  
 Accepted after revision: July 28, 2015.  
 Bangkok Med J 2015;10:27-33.  
 E-journal: <http://www.bangkokmedjournal.com>

## Abstract

A lung carcinoid tumor is a rare malignant neoplasm. The clinical presentation depends on the characteristics of the tumor, its location and hormones secreted. The most common symptoms are cough, wheezing, chest pain, hemoptysis and dyspnea. Diagnosis can be established through radiographic images, biopsy of the tumor with tissue analysis supplemented by blood tests. In previous years, surgery has been the gold standard in treating carcinoid tumors. However, recently, there have been several studies conducted in the efficacy of the use of bronchoscopic methods such as cryosurgery in completely extracting and treating lung carcinoid tumors without metastases. This case report's objective is to illustrate that cryosurgery should be considered as the new gold standard in treating lung carcinoid tumors.

**Keywords:** cryosurgery, cryotherapy, lung carcinoid tumor, endobronchial tumor, argon plasma coagulation

**L**ung carcinoid tumor is a rare malignant disease made up of neuroendocrine cells. These cells resemble endocrine cells because they both excrete hormone substances and are also like nerve cells due to their release of neurotransmitters.<sup>1</sup> In the lungs, these hormones and substances assist in the regulation of air and blood flow that helps in the growth of other types of lung cells.

Neuroendocrine tumors can develop anywhere in the body. These can form in different organs such as the lungs, appendix, small intestine, rectum and pancreas.<sup>2</sup>

Carcinoid bronchopulmonary tumors constitute a quarter of all carcinoid tumors and 1-2% of all lung cancers.<sup>2,3</sup> About 70% of these tumors are found in the main bronchial airways leading to the lungs, while 10-20% are found in the peripheral areas of the lung.<sup>2</sup> The World Health Organization has classified neuroendocrine pulmonary tumors into 4 types: typical carcinoid (grows slowly and rarely spreads beyond the lungs), atypical carcinoid (grows a little faster and may metastasize but is rarer), large cell neuroendocrine carcinoma and small cell lung cancer.<sup>2,4</sup>

Since this disease develops slowly, approximately 25% of patients with carcinoid lung tumors present no symptoms.<sup>5</sup> For some, the physical manifestations depend on the size of tumor, its location and type of hormones produced. The most common symptoms are cough, wheezing, chest discomfort, blood in sputum and difficulty of breathing.<sup>6</sup>

Diagnosis of this disease can be done through chest x-ray, computed tomography (CT) scans, and tissue analysis through biopsy. Treatment is determined mainly by the size of the tumor, location, depth and most importantly, the patient's overall health status (pulmonary status and presence of metastatic disease). Until recently, the treatment of choice was surgical resection. However, some physicians have presented alternatives using different

interventional techniques such as Nd YAG laser treatments, electrocautery, endobronchial brachytherapy, photodynamic therapy and cryotherapy in the management of carcinoid tumors. These procedures, and in particular cryosurgery is less invasive, versatile, fast and has been shown to be very effective.

The aim of this study is to illustrate the efficacy and safety of cryosurgery in treatment of an isolated carcinoid tumor in the lung through a case report.

## Case Report

A case of a Yemeni, 22-year-old male, a non-smoker, with no known underlying conditions, was diagnosed with a lung carcinoid tumor, left upper lobe. Three weeks prior to consultation, he was admitted to a local hospital in his country because of fever, chronic cough and malaise. He was initially diagnosed with Pneumonia and was treated with antibiotics. He seemed to improve clinically but later developed left upper lobe segment collapse as seen on his chest x-ray. He then underwent a Chest CT scan which revealed left upper lobe collapse with total blockage of the left upper lobar bronchus immediately at the hilar level with suspicious bronchial filling defect. Suspicious left para hilar fullness was seen reflecting possible mass lesion or adenopathy. Prevascular mediastinal lymph node was observed and measured at 17x8 mm diameter (Figure 1). Fiberoptic bronchoscopy showed a large ball-like soft tissue mass obliterating and almost totally closing the left upper lobe bronchus. A biopsy was performed and specimens were extracted for cytology, fluid culture and sensitivity, acid fast bacilli and fungal studies. The histopathology report revealed that the cytomorphological features with the immunohistochemical markers supported the diagnosis of bronchial well differentiated neuroendocrine tumor (carcinoid tumor). He decided to seek a second opinion from Bangkok Hospital.

Upon arrival to Thailand, he was asymptomatic with the following vital signs: temperature: 36.3°C, pulse rate: 73 beats per minute, respiratory rate: 18 cycles beats per minute, Blood pressure: 128/74 mmHg, O<sub>2</sub> saturation: 98%. His test results and radiographic images were reviewed and two options were considered. First, since the patient presents as clinically stable with no signs of hypoxia or bleeding, he is eligible to undergo cryosurgery with argon plasma coagulation to stop bleeding; the second option is lobectomy. The family and patient refused lobectomy and chose to first conduct additional investigations through a 18F-FDG PET/CT scan for further evaluation to help provide more specific information on the primary site as well as any secondary deposit. The 18F-FDG PET/CT scan revealed hypermetabolic focus at the left lingular segment of the left upper lobe. The atelectasis of the left upper lung shows increased

18F-FDG uptake standardized uptake value (SUV of 1.9 (Figure 2). No other hypermetabolic site is observed. Finally, the patient accepted to undergo cryosurgery with argon plasma coagulation.

Prior to the procedure, his lung function was evaluated and revealed a FEF<sub>25-70%</sub> of 75%. Pre-operative protocols were observed and he was prepared for the procedure. Bronchoscopic cryo surgery equipment was put together. The bronchoscope, cryo machine with foot control, suitable size cryoprobes and cooling agent (carbon dioxide) were prepared. Before beginning the procedure, the probe tip was tested directly and made sure that it has no leakage.

## Technical procedure

The patient was placed under general anesthesia. Once breathing has been stabilized, a fiberoptic bronchoscope was inserted through the tube into the left main bronchus then through the left upper lobe bronchus where the tumor was thoroughly examined. Once the tumor is located, the flexible cryo probe is inserted to the working channel and is placed on the surface of the tumor with gentle pressure. The cryo machine is then activated and carbon dioxide is released, controlled through the foot pedal. Once the target tissue was frozen, a short pull to help tear the tissue was done. The freezing and pulling technique was performed 5 times, 20 seconds of freezing each time until the whole tumor was successfully removed. The cryo was maintained until the piece of the tumor was properly thawed in a liquid container for histopathological studies. After the freezing and extraction of tumor, argon plasma coagulation was done to abruptly stop the bleeding. Immediately post procedure, the patient stayed in the recovery room for close monitoring. No post-operative complications were noted. Two days after the cryo surgery, breathing had improved greatly with a lung function test result of FEF<sub>25-70%</sub> of 89% (Table 1). His chest x-ray revealed a partial clear infiltration of the left lung. Histopathology report revealed atypical carcinoid with necrotic foci. A repeat Chest CT scan after 3 months was recommended to evaluate any regrowth of the tumor.

## Discussion

A carcinoid tumor is a rare malignant disease which is frequently managed by surgery especially when it is confined only in one area of the lung. The diagnosis of this tumor is based on the patient's signs and symptoms, radiographic imaging such as chest x-ray and CT scan, confirmed by bronchoscopic procedure and tissue analysis. Imaging of the tumor is very important as this illustrates the location, size, characteristic of the tumor and if there is any nodal involvement.<sup>7,8</sup> The best and most appropriate management is determined once diagnosis through CT scan and tissue analysis has been established.

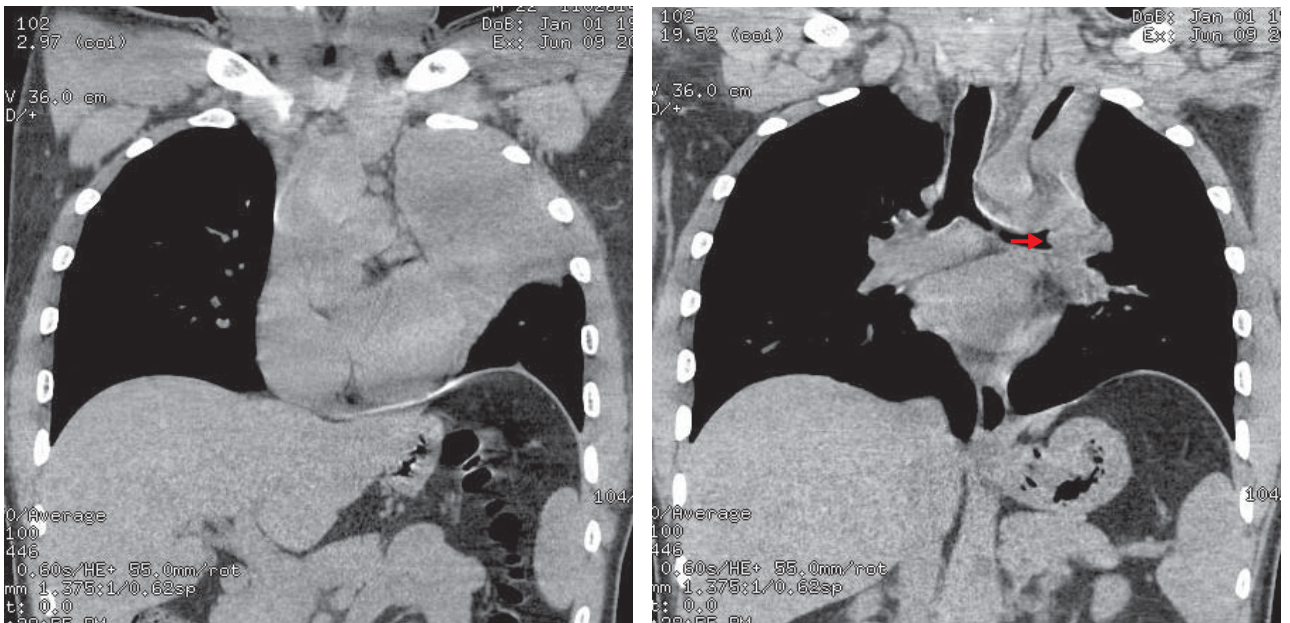


Figure 1: The CT scan image illustrates the carcinoid tumor at the left upper lobe lung (arrow with obstructive atelectasis).

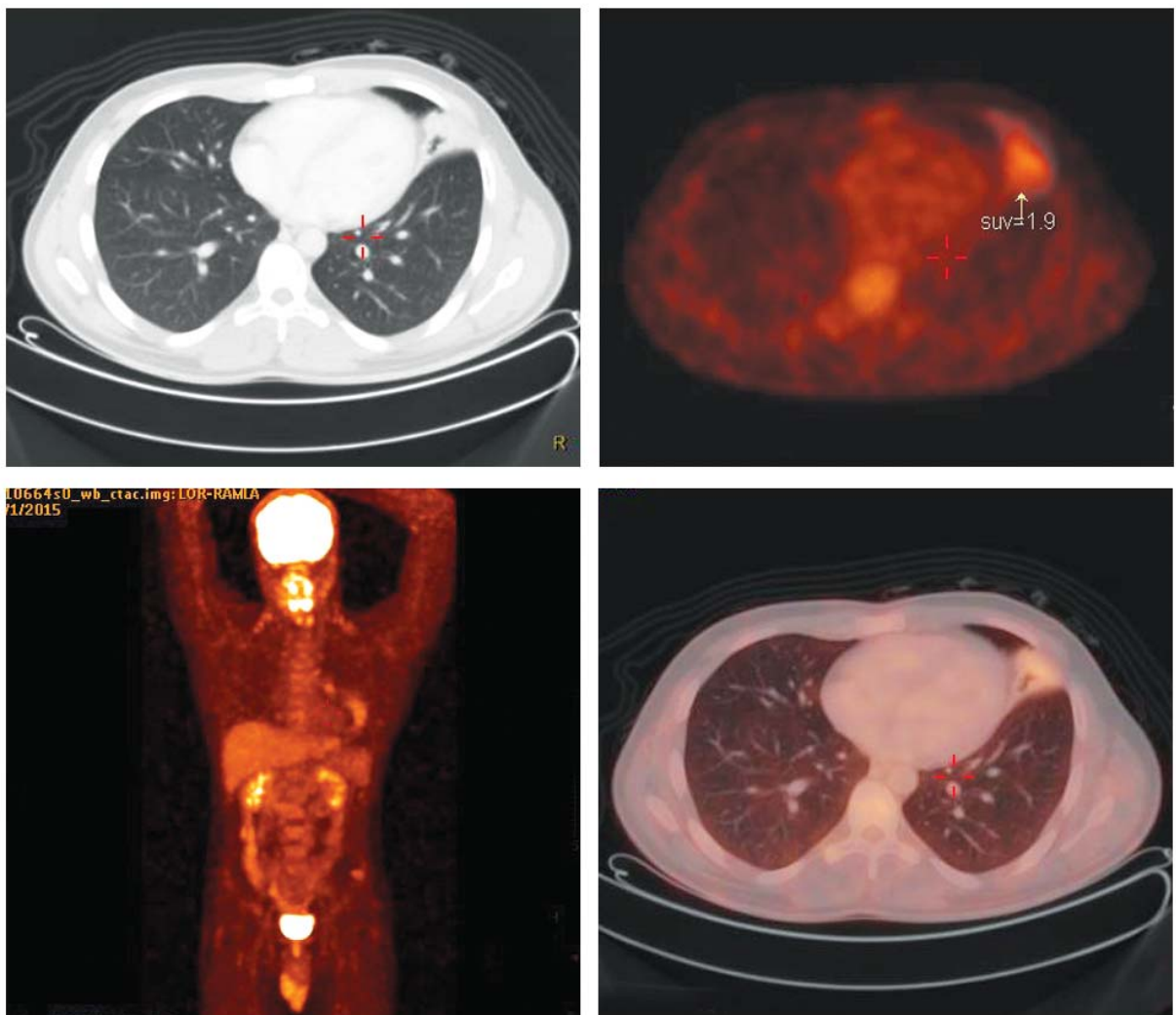
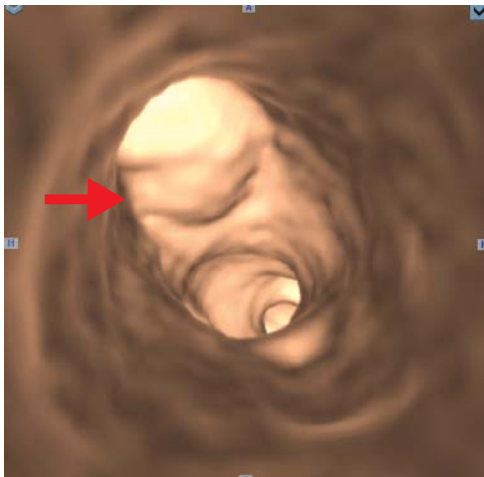


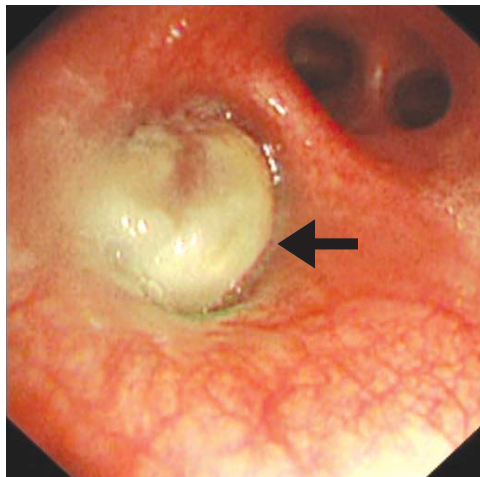
Figure 2: 18F-FDG PET/CT reveals hypermetabolic focus at lingular segment of left upper lobe, the 18F-FDG uptake SUV of 1.9.

**Table 1.** This shows the patient’s lung function test prior and post cryosurgery. The  $FEF_{25-75\%}$  has significantly increased from 75% to 89%.

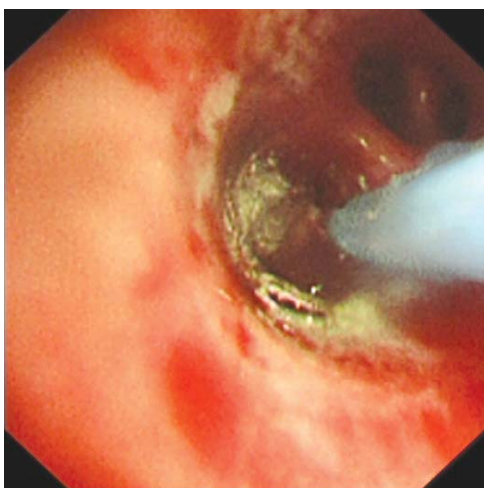
SPIROMETRY	(BTPS)	BEFORE CRYOSURGERY			AFTER CRYOSURGERY		
		PRE-RX			PRE-RX		
		PRED	BEST	%PRED	PRED	BEST	%PRED
FVC	Liters	5.19	4.56	88	5.25	4.68	89
FEV1	Liters	4.38	3.67	84	4.42	3.95	89
FEV1/FVC	%	85	80		85	84	
FEF 25-75%	L/sec	4.79	3.59	75	4.81	4.26	89
IsoFEF 25-75	L/sec	4.79	3.59	75	4.81	4.26	89
FEE 75-85%	L/sec		0.94			1.41	
PEF	L/sec		8.21			8.61	
FET 100%	Sec		6.89			7.23	
FIVC	Liters	5.19	4.31	83	5.25	4.42	84
FEV1	Liters	4.38	3.67	84	4.42	3.95	89
FIV1	Liters		3.95			3.98	
FEF/FIF 50			0.93			0.87	
Vol Extrap	Liters		0.11			0.06	



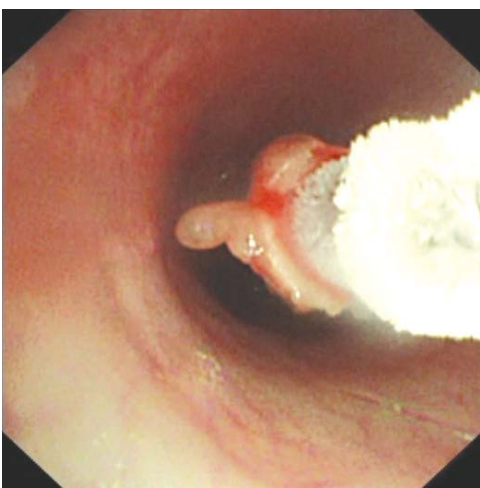
**Figure 2:** The bronchial tumor as viewed through the virtual bronchoscopy.



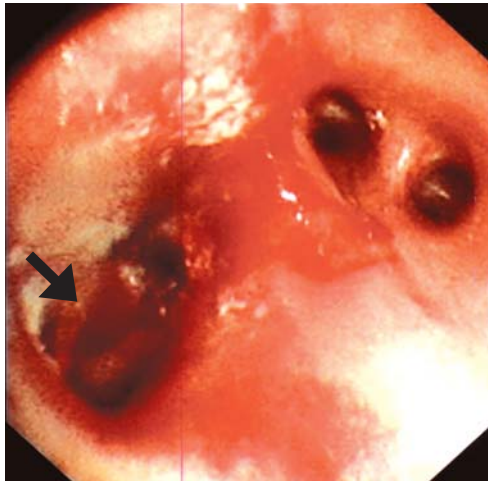
**Figure 3:** The carcinoid tumor as directly viewed from the bronchoscope.



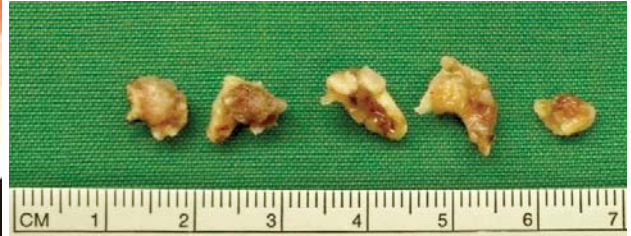
**Figure 4:** The carcinoid tumor when carbon dioxide is applied.



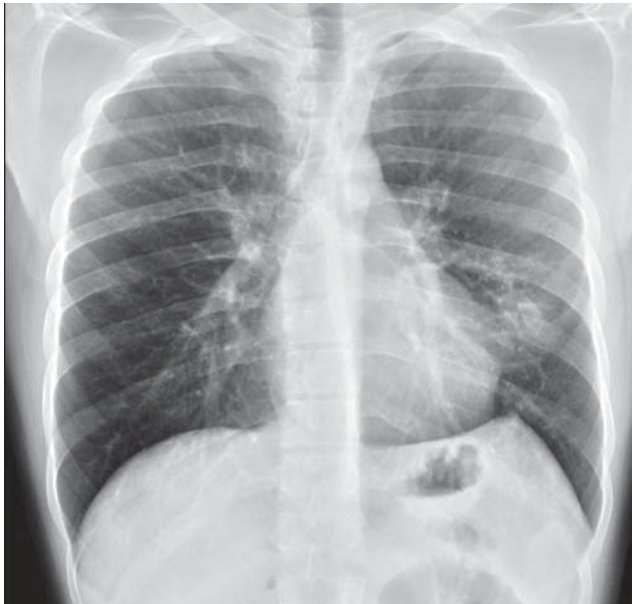**Figure 5:** The frozen carcinoid tumor being pulled out from the bronchus.



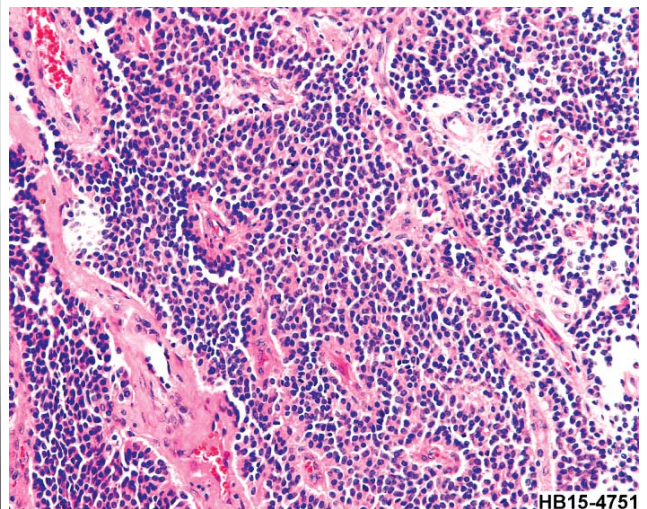
**Figure 6:** The lung parenchyma post cryosurgery with minimal bleeding.



**Figure 7:** The carcinoid tumor extracted by pieces through cryosurgery.



**Figure 8:** The chest x-ray result shows localized patchy infiltration at the lingular segment of the left upper lobe.



**Figure 9:** Tumor cells in organoid and trabecular pattern in hyalinizing stroma with some palisading at periphery. The tumor cells have fine granular tissue chromatin, indistinct nucleoli. The findings are compatible with atypical carcinoid.

For this case, in less than 3 weeks since the onset of symptoms, cryosurgery was decided to be the best treatment option for the carcinoid tumor. The process of diagnosis was efficient and prompt. Once the physicians found the left upper lobe segment collapse in his chest x-ray, this was followed up immediately by chest CT scan and bronchoscopy with biopsy that confirmed a well differentiated neuroendocrine tumor (carcinoid tumor). No metastases were seen on the radiographic images but the size of the tumor was initially a concern as to whether using cryosurgery would be sufficient in extracting the

whole tumor. As mentioned, surgery was offered but the family and patient refused and opted to undergo the less invasive route which is cryosurgery.

According to what we know so far, there is no consensus in treating lung carcinoid tumor. In the past, therapeutic options were focused on surgical resection of the tumor. As this strategy failed to avoid development of recurrence, different techniques such as endoscopic methods have been introduced.<sup>9</sup>

Several published studies encourage the use of less invasive techniques as this is very effective in extracting tumors which improves clinical symptoms and increases the overall survival rates.<sup>10-18</sup> In a study by Seon-Heui Lee et al.<sup>19</sup> endoscopic cryotherapy illustrated approximately 80% efficacy and has greatly improved patient's quality of life. Unlike other endoscopic techniques, cryosurgery is not linked with prolonged complications such as bronchial stenosis, excessive bleeding and avoids collagen damage.<sup>10</sup> The depth of extraction in the bronchial wall is > 3 mm which is enough to treat early stage lung malignancies.<sup>20</sup> It has no risk of electrical accidents, does not require laser training and certification, can be done several times and allows surgical salvage if needed.<sup>9,21</sup>

In a study by Dr. Deygas et al.<sup>9</sup> they illustrated the excellent tolerance to cryotherapy. There were no signs of bleeding, dyspnea, chronic cough, bronchial wall perforation and no severe side effects related to general anesthesia shown by their subjects. As for our experience, argon plasma coagulation was utilized in order to immediately seize the bleeding. Also, no untoward signs and symptoms post procedure were recorded.

In terms of the number cycles and seconds used to freeze the tumor, we were able to completely extract the whole carcinoid tumor with 5 cycles of 20 second freezing time. A number of research studies have been published pertaining to the duration of the application of cryoprobe and how many cycles should be performed in order to maximize satisfactory results. In a research by Dr. Bertolletti et al.<sup>7</sup> 2 methods were used in cryotherapy. One is three cycles of freezing for 20 seconds used in St. Etienne, and the other is 30 seconds in Montreal, then thawing was performed at each site.<sup>10</sup> Meanwhile, in a study by Noppen et al.<sup>22</sup> they performed 3x20 second cycles of -80°C cryotherapy. In a systematic review by Seon-Heui Lee et al.<sup>19</sup> the technique of cryotherapy used by 9 different published studies has a range temperature

of -70°C to -160°C and a varying time of 5 seconds to 3 minutes. Clearly, there is no specific guideline in using cryotherapy. Time and the number of cycles depend on several factors which includes the type of equipment, size and depth of tumor and of course the operator of the cryoprobes.

Among lung cancers, carcinoid tumors have the highest success rates. Typical carcinoid tumor has a 5-year survival rate of 92-100% while atypical tumor has a 61-88% survival rate.<sup>23</sup> This becomes lower to 4-35% if there are metastases to other organs.<sup>24,25</sup> Atypical tumors are rarer than typical tumors but grow faster and have a tendency to metastasize. These tumors are more frequent in males and the average age onset of this disease is 46 years old.<sup>26</sup>

The efficacy of radiotherapy and chemotherapy is still under discussion.<sup>27</sup> In a study by Mitry et al.<sup>28</sup> they found that poorly differentiated neuroendocrine tumors respond to the cytotoxic agents cisplatin and etoposide. However the 2-year survival is significantly low at less than 20%.

A lung carcinoid tumor is an infrequent disease which makes it more challenging to treat. Earlier management was focused on surgery and for some, it is still considered as the gold standard in treating carcinoid tumors. Given the lack of consensus in managing this kind of disease, less invasive strategies such as cryosurgery has been introduced by many interventional pulmonologists, as this procedure is safe, effective and has significantly higher tolerance to surgery. Although there were delayed results reported and multiple endoscopies to be performed to extract the whole tumor,<sup>21</sup> this procedure is definitely more practical, aggressive yet less invasive and more conservative than surgery. In conclusion, physicians and scientists should be able to objectively compare and research more into considering cryosurgery as a first-line therapy for carcinoid tumors without metastases.

## References

1. Cleveland Clinic. Carcinoid Tumors of the Lungs. (Accessed July 10, 2015 at [http://my.clevelandclinic.org/health/diseases\\_conditions/hic\\_carcinoid\\_tumors\\_of\\_the\\_lungs](http://my.clevelandclinic.org/health/diseases_conditions/hic_carcinoid_tumors_of_the_lungs)).
2. Porpodis K, Karanikas M, Zarogoulidis P, et al. A case of typical pulmonary carcinoid tumor treated with bronchoscopic therapy followed by lobectomy. *J Multidiscip Healthc* 2012;5:47-51.
3. Asamura H, Kameya T, Matsuno Y, et al. Neuroendocrine neoplasms of the lung: a prognostic spectrum. *J Clin Oncol* 2006;24:70-6.
4. World Health Organization classification of tumors. Pathology and Genetics. Tumors of the Lung, Pleura and Heart. Lyon, France: IARC. Press; 2004.
5. Ducrocq X, Thomas P, Massard G, et al. Operative risk and prognostic factors of typical bronchial carcinoid tumors. *Ann Thorac Surg* 1998;65:1410-4.
6. McCaughan BC, Martini N, Bains MS. Bronchial carcinoids. Review of 124 cases. *J Thorac Cardiovasc Surg* 1985;89:8-17.
7. Bertolletti L, Elleuch R, Kaczmarek D, et al. Bronchoscopic cryotherapy treatment of isolated endoluminal typical carcinoid tumor. *Chest* 2006;130:1405-11
8. Van Boxem TJ, Golding RP, Venmans BJ, et al. High-resolution CT in patients with intraluminal typical bronchial carcinoid tumors treated with bronchoscopic therapy. *Chest* 2000;117:125-8.

9. Deygas N, Froudarakis M, Ozenne G, et al. Cryotherapy in early superficial bronchogenic carcinoma. *Chest* 2001;120:26-31.
10. Chughtai TS, Morin JE, Sheiner NM, et al. Bronchial carcinoid-twenty years' experience defines a selective surgical approach. *Surgery* 1997;122:801-8.
11. Bolliger CT, Sutedja TG, Strausz J, et al. Therapeutic bronchoscopy with immediate effect: laser, electrocautery, argon plasma coagulation and stents. *Eur Respir J* 2006;27:1258-71.
12. Ernst A, Feller-Kopman D, Becker HD, et al. Central airway obstruction. *Am J Respir Crit Care Med* 2004;169:1278-97.
13. Van Boxem TJ, Venmans BJ, Van Mourik JC, et al. Bronchoscopic treatment of intraluminal typical carcinoid: a pilot study. *J Thorac Cardiovasc Surg* 1998;116:402-6.
14. Cavaliere S, Foccoli P, Toninelli C. Curative bronchoscopic laser therapy for surgically resectable tracheobronchial tumors. *J Bronchol* 2002;9:90-5.
15. Luna D, Hernandez C, Aldama L, et al. Crioterapia endoscopia en 5 carcinoides broquiales intraluminales, tipicos. Presented at V<sup>th</sup> International Meeting on Respiratory Endoscopy. Barcelona, Spain. May 8-10, 1997.
16. Hetzel J, Eberhardt R, Herth FJF, et al. Cryobiopsy increases the diagnostic yield of endobronchial biopsy: a multicenter trial. *Eur Respir J* 2012;39:685-90.
17. Hetzel J, Hetzel M, Hasel C, et al. Old meets modern: the use of traditional cryoprobes in the age of molecular biology. *Respiration* 2008;76:193-7.
18. Hetzel M, Hetzel J, Schumann C, et al. Cryorecanalization: a new approach for the immediate management of acute airway obstruction. *J Thorac Cardiovasc Surg* 2004;127:1427-31.
19. Lee SH, Choi WJ, Sung SW, et al. Endoscopic cryotherapy of lung and bronchial tumors: a systematic review. *Korean J Intern Med* 2011;26:137-44.
20. Vergnon J-M. How I do it: bronchoscopic cryotherapy. *J Bronchol* 1995;2:323-7.
21. Thurer RJ. Cryotherapy in early lung cancer. *Chest* 2001;120:3-5.
22. Noppen M, Meysman M, Van Herreweghe R, et al. Bronchoscopic cryotherapy: preliminary experience. *Acta Clin Belg* 2001;56:73-7.
23. Garcia-Yuste M, Matilla JM, Cueto A, et al. Typical and atypical carcinoid tumours: analysis of the experience of the Spanish Multi-centric Study of Neuroendocrine Tumours of the Lung. *Eur J Cardiothorac Surg* 2007;31:192-7.
24. Tun NT, Oza R. Atypical presentation of carcinoid tumor with unresolved right shoulder pain: a case report. *J Med Case Rep* 2014;8:142.
25. Yao JC, Hassan M, Phan A, et al. One hundred years after "carcinoid": epidemiology of and prognostic factors for neuroendocrine tumors in 35,825 cases in the United States. *J Clin Oncol* 2008;26:3063-72.
26. Valli M, Fabris GA, Dewar A, et al. Atypical carcinoid tumour of the lung: a study of 33 cases with prognostic features. *Histopathology* 1994;24:363-9.
27. Bini A, Brandolini J, Cassanelli N, et al. Typical and atypical pulmonary carcinoids: our institutional experience. *Interact Cardiovasc Thorac Surg* 2008;7:415-8.
28. Mitry E, Baudin E, Ducreux M, et al. Treatment of poorly differentiated neuroendocrine tumours with etoposide and cisplatin. *Br J Cancer* 1999;81:1351-5.