

Interhospital Transport of the ECMO Patients in Bangkok Hospital



Akanitthapichat S, MD

Siriwasan Akanitthapichat, MD¹
Pranya Sakiyalak, MD^{1,2}
Kris Chirasanta, MD³
Sathit Chairatthanawanit, MD³
Sombat Gunyaphan⁴

Abstract

An extracorporeal membrane oxygenator (ECMO) is used to support the heart and lungs in patients with severe cardiogenic shock and respiratory failure. When these cases occur in hospitals that cannot provide ECMO care, the interhospital transport of ECMO is necessary. Since November 2014, Bangkok Hospital has had 3 ECMO cases from Chiangmai, Trad and Pattaya respectively. There were no complications with establishing ECMO during transportation. Two of the patients survived, although they developed deep vein thrombosis after the removal of ECMO. Unfortunately one patient suffered pulmonary hemorrhage and died from circuit thrombosis due to pulmonary hemorrhage.

Keywords: extracorporeal membrane oxygenator, ECMO, transport

Extracorporeal membrane oxygenators (ECMO) provide efficient emergency pulmonary and circulatory support for patients with refractory cardiogenic shock with conventional intensive therapy (Veno-Arterial ECMO, VA) and hypoxic-hypercapnic refractory respiratory failure patients receive advanced ventilation strategies (Veno-Venous ECMO, VV).^{1,2} (Figure 1)

Currently, ECMO use is limited to certain specialized tertiary centers that are both equipped to implement programs and experienced in their management. Hospitals that cannot undertake heart surgery or initiate ECMO find it extremely difficult to treat patients in refractory cardiogenic shock. Transferring patients to centers with better technical resources can be the only alternative but is often considered invariable due to patients' hemodynamic instability. Recent experience confirms that creating mobile heart surgery units-where support devices can be implanted in situ, followed by stabilization and transfer to a specialized center-offers these critical patients a chance of survival.³⁻⁵

The objective of the present case study is to determine the feasibility and safety of an interhospital transfer program for critical patients needing ECMO support at Bangkok Hospital.

Case Report

Since November 2014, Bangkok Hospital has transported 3 patients with ECMO support. The first patient was a 20-year-old female. She was diagnosed with acute viral myocarditis at Chiangmai. After presenting with fever for 7 days, progressive dyspnea developed, and she was admitted to Maharaj Nakorn Chiangmai Hospital, Chiangmai University. The heart failure worsened and an intra-aortic balloon pump (IABP) was inserted to support the heart function. The patient's vital signs were unstable therefore VA-ECMO was established with the right femoral artery and right femoral vein cannulation. IABP was then

¹ Cardiothoracic surgery, Vascular Center, Bangkok Heart Hospital, Bangkok Hospital Group, Bangkok, Thailand.

² Cardiothoracic surgery, Chulalongkorn University, Bangkok, Thailand.

³ Anesthesiology, Operating Room (Cardiac), Bangkok Heart Hospital, Bangkok Hospital Group, Bangkok, Thailand.

⁴ Operating Room (Cardiac), Bangkok Heart Hospital, Bangkok Hospital Group, Bangkok, Thailand.

* Address Correspondence to author:
Siriwasan Akanitthapichat, MD
Thoracic Surgery Bangkok Hospital,
2 Soi Soonvijai 7, New Petchaburi Rd.,
Bangkok 10310, Thailand.
e-mail: siriwasan.ak@bangkokhospital.com

Received: June, 21, 2015.
Revision received: June 30, 2015.
Accepted after revision: July 15, 2015.
Bangkok Med J 2015;10:34-38
E-journal: <http://www.bangkokmedjournal.com>

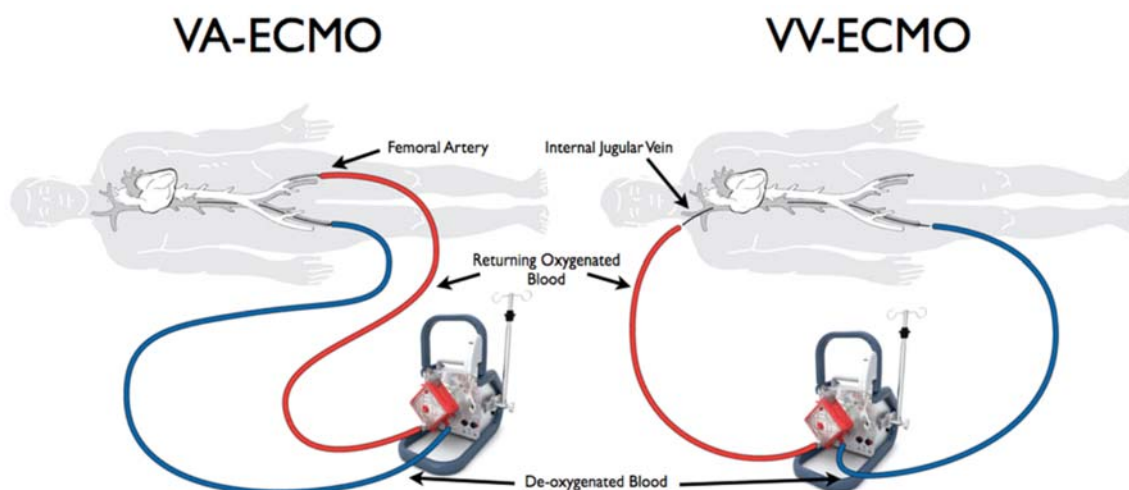


Figure 1: Type of ECMO; (1) Veno-Arterial (VA) ECMO, (2) Veno-Venous (VV) ECMO (Cardiohelp®, Maquet).

removed once vital signs were stable. At this point, Bangkok Hospital was consulted to receive the patient. On the 3rd day with ECMO support, the Bangkok Hospital ECMO transport team, consisting of a surgeon, anesthesiologist, perfusionist and three aviation team members, flew to Chiangmai on a charter flight. By this time, the patient's condition had improved. She was awake and communicated well under a low dose of sedation and low dose of inotropic drugs. Then the ECMO team changed the ECMO machine and circuit from Rotaflow® to Cardiohelp® as it is more compact for transportation, taking about three hours to change and stabilize the patient. The patient was then taken to Chiangmai International Airport by ambulance, which took around 30 minutes, then switched to the jet flying to Don Mueang International Airport, which took around 90 minutes, and finally the patient was transferred to an ambulance to go to Bangkok Heart Hospital (BHT), which took around 40 minutes. There were no catastrophic events during transportation (Figure 2). ECMO was removed after 7 days at BHT, and both the right femoral artery and the right femoral vein were repaired. Two days after ECMO was removed, her right leg was swollen but not tender. Doppler ultrasound confirmed the diagnosis of deep vein thrombosis at the right femoral vein. The patient was advised to take Warfarin for this condition. The patient returned to her country of origin 5 days after ECMO was removed, escorted by a doctor.

The second patient was a 41-year-old male. He had suffered multiple traumas from an accident and was admitted to Bangkok Trad Hospital. Multiple ribs fractures with severe pulmonary contusion and pulmonary hemorrhage progressed to severe respiratory distress syndrome that could not be supported with a high setting ventilator. On the 5th day after the accident, Bangkok Hospital was consulted to receive this case. The Bangkok Hospital ECMO transport team, consisting of a surgeon,

anesthesiologist, perfusionist and a critical care nurse, was assembled. At the referring hospital, non-heparinized VV-ECMO was established at the jugular vein and right femoral vein cannulation and the patient was stabilized for about 3 hours. The patient was taken to BHT by ground ambulance which took around 5 hours. The patient was stable during transportation. On the 3rd day after ECMO insertion, ECMO failed to maintain flow due to a clot in both the inflow and outflow cannula. The ECMO circuit was changed and a left femoral vein cannulation was added. Unfortunately, the patient died after changing the circuit due to prolonged hypoxemia.

The third patient was a 70-year-old male. He was diagnosed with severe triple vessels disease and received an off-pump coronary artery bypass graft at Bangkok Hospital Pattaya. On the 2nd day after the operation, the patient developed high grade fever and hypoxemia. Although the high setting ventilator was adjusted the oxygen saturation remained about 80%. On postoperative day 3, Bangkok Hospital was consulted to receive this case. He was diagnosed sepsis. The Bangkok Hospital ECMO transport team, consisting of a surgeon, anesthesiologist, perfusionist and a critical care nurse, was assembled. At the referring hospital, VV-ECMO was established at the right jugular vein and right femoral vein cannulation. The patient was stabilized for about 3 hours. The patient was then taken to BHT by ground ambulance, which took about 2 hours. He was stable during transportation (Figure 3). On the 3rd day after ECMO insertion, oxygenation returned to acceptable levels, no fever presented, and his white blood cell count decreased so ECMO was removed. One day after removing ECMO, his right leg was swollen with no tenderness. Doppler ultrasound was performed to confirm a clot in the right femoral vein, and right popliteal vein. Heparin and warfarin was used to treat deep venous thrombosis. The patient was transferred back to Bangkok Hospital Pattaya on day 5 after ECMO insertion.

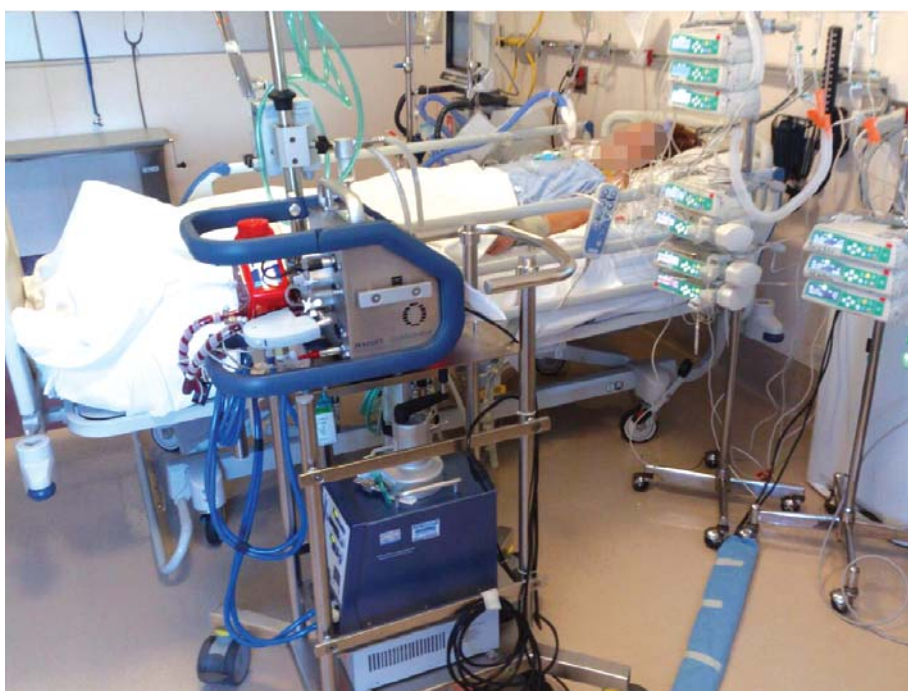


Figure 2: Patient with Transport ECMO (Cardiohelp®, Maquet).

Table : Case Transportation with ECMO.

Characteristic	Diagnosis	Referring Hospital	ECMO type/model	Transportation	Result
1. Female 20 year-old	Acute viral myocarditis	Maharaj Nakorn Chiangmai	VA-ECMO, Cardiohelp®	1. Ground (30 mins) 2. Air (90 mins) 3. Ground (40 mins)	Alive, DVT after ECMO removal
2. Male 41 year-old	Multiple trauma with pulmonary contusion, pulmonary hemorrhage and ARDS	Bangkok Hospital Trad	VV-ECMO (non-heparinized), Cardiohelp®	1. Ground (300 mins)	Dead due to circuit thrombosis
3. Male 70 year-old	TVD S/P OPCAB with severe sepsis	Bangkok Hospital Pattaya	VV-ECMO, Cardiohelp®	1. Ground (120 mins)	Alive, DVT after ECMO removal

Discussion

The transport of three patients from referring hospitals to Bangkok Hospital was done safely, either by establishing or changing ECMO at the referring hospital or during transportation of the patient. Two patients recovered after arriving at Bangkok Hospital. ECMO was removed but they both developed deep vein thrombosis in the leg. One patient had an open cut to insert the cannula followed by an open repair. The Seldinger technique was used for another patient then removed and compressed. Both patients took heparin and warfarin so their leg improved from swelling without catastrophic events. Zangrillo's group⁶ demonstrated that EMCO is still associated with some difficulties in the clinical outcomes. It was found that 10 percent of patients suffered from venous thrombosis faced complications. However, there was no evidence from

this systemic review suggesting whether venous thrombosis occur between using of ECMO or after removal of cannula. In addition to this, there were no guidelines or recommendations for the prevention of venous thrombosis after removal of cannula. Further investigations should be conducted to identify incidences of venous thrombosis after removal of cannula and prevention.

Unfortunately one patient died from cannula thrombosis due to multiple trauma, cerebral hemorrhage and pulmonary hemorrhage which could not be heparinized. Reviewed literatures from 2007-2012 by Pei-Hung's group⁷ reported that 22 multiple injury patients received non-heparinized ECMO and mortality rate is about 18% (4 case). In our case, patient died from prolong hypoxemia after thrombosis of cannulas and circuit. Early detection would help preventing such problems.

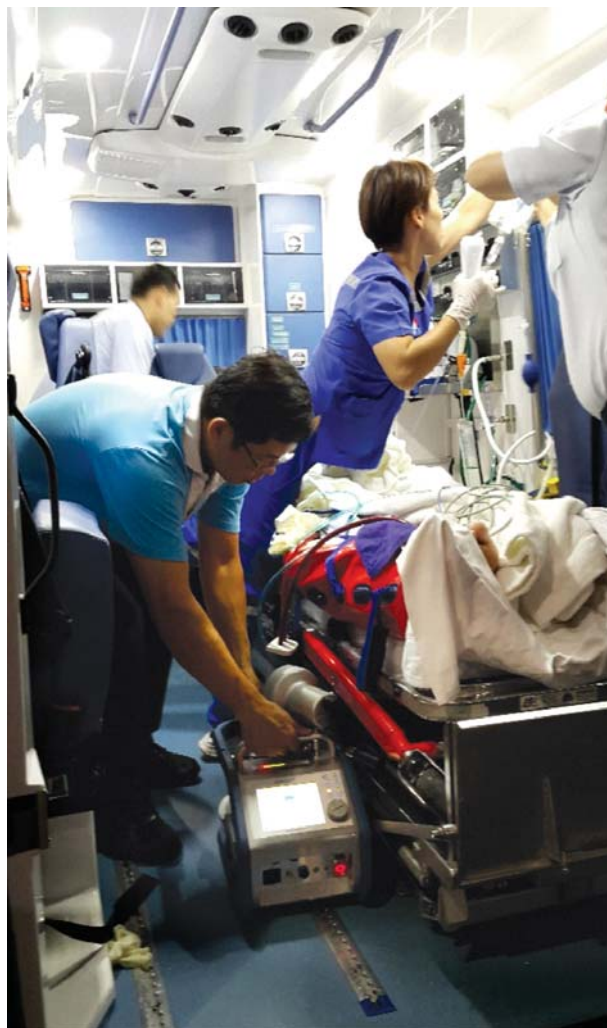
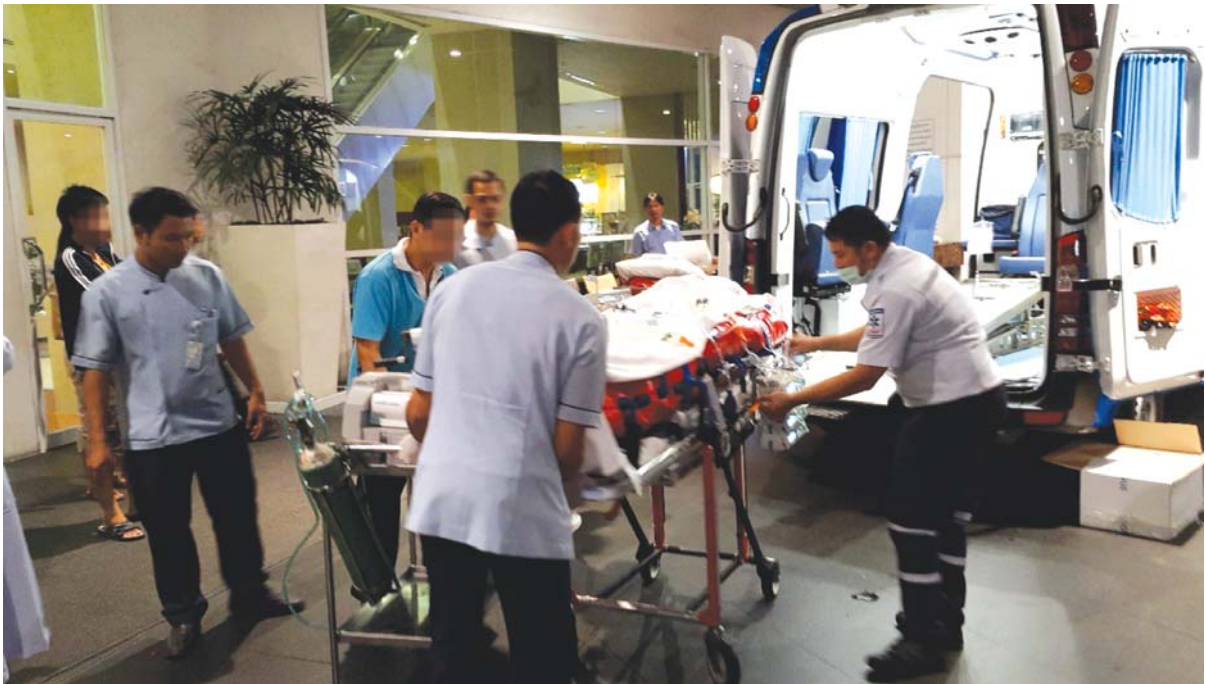
Figure 3: Ground transportation.

Conclusion

Bangkok Hospital team is the first transported ECMO team in Thailand and we perform this procedure with good results as at other ECMO centers.⁸⁻¹⁰ The successful transportation of ECMO patients requires a skilled

Transport Medical Director who is responsible for planning the mission, preparing and assembling the transport team. Furthermore, the ECMO transport team should receive the requisite training.

References

1. Allen S, Holena D, McCunn M, et al. A review of the fundamental principles and evidence base in the use of extracorporeal membrane oxygenation (ECMO) in critically ill adult patients. *J Intens Care Med* 2011;26:13-26.
2. Marasco SF, Lukas G, McDonald M, et al. Review of ECMO (extracorporeal membrane oxygenation) support in critically ill adult patients. *Heart Lung Circ* 2008;17 Suppl 4:41-7.
3. Beurtheret S, Mordant P, Paoletti X, et al. Emergency circulatory support in refractory cardiogenic shock patients in remote institutions: a pilot study (the cardiac-RESCUE program). *Eur Heart J* 2013;34:112-20.
4. Gariboldi V, Grisoli D, Tarmiz A, et al. Mobile extracorporeal membrane oxygenation unit expands cardiac assist surgical programs. *Ann Thorac Surg* 2010;90:1548-52.
5. Haneya A, Philipp A, Foltan M, et al. Extracorporeal circulatory systems in the interhospital transfer of critically ill patients: experience of a single institution. *Ann Saudi Med* 2009;29:110-4.
6. Zangrillo A, Landoni G, Biondi-Zoccai G, Greco M, Greco T, et al. A meta-analysis of complications and mortality of extracorporeal membrane oxygenation. *Crit Care Resusc.* 2013 Sep;15(3):172-8.
7. Pei-Hung W, Wai Hung C, Ying-Cheng C, Yao-Li C, et al. Non-heparinized ECMO serves a rescue method in a multitrauma patient combining pulmonary contusion and nonoperative internal bleeding: a case report and literature review. *World J Emerg Surg.* 2015 Mar 12;10:15.
8. Raspé C, Rückert F, Metz D, et al. Inter-hospital transfer of ECMO-assisted patients with a portable miniaturized ECMO device: 4 years of experience. *Perfusion* 2015; 30:52-9.
9. Desebbe O, Rosamel P, Henaine R, et al. Interhospital transport with extracorporeal life support: results and perspectives after 5 years experience. *Ann Fr Anesth Reanim* 2013;32:225-30.
10. Isgro S, Patroniti N, Bombino M, et al. Extracorporeal membrane oxygenation for interhospital transfer of severe acute respiratory distress syndrome patients: 5-year experience. *Int J Artif Organs* 2011;34:1052-60.