

## A Rare Case of Single, Isolated Liver Metastases from Spermatic Cord Leiomyosarcoma



Sumetchotimaytha W, MD

Wutthi Sumetchotimaytha, MD<sup>1</sup>  
Thiravud Khuhaprema, MD<sup>1</sup>  
Kanoknid Limvipaveanan, MD<sup>2</sup>  
Chairroj Varongchayakul, MD<sup>3</sup>

### Abstract

A 54-year-old man presents with a left scrotal mass with abdominal pain. The investigation 18F-FDG PET/CT reveals hypermetabolic heterogenous enhanced mass at left spermatic cord but non 18F-FDG avid hypodensitic mass at left lobe of the liver is observed. Left orchiectomy with high ligation of the left spermatic cord and left hepatectomy were performed. The pathological finding reveals leiomyosarcoma arising from spermatic cord with liver metastasis. Follow-up at 6 months shows no evidence of recurrence by 18F-FDG PET/CT examination.

**Keywords:** spermatic cord leiomyosarcoma, extratesticular liver metastasis, 18-F-FDG PET/CT findings

Isolated single liver metastasis from spermatic cord leiomyosarcoma is a rare entity without spreading to other organs.<sup>1</sup> Most commonly this occurs by lymphangitic spread. Hematogenous and local invasion along the pathway of the vas deferens<sup>2,3</sup> may be seen.

This report is the first documented case of spermatic cord leiomyosarcoma with isolated single liver metastasis diagnosed and treated at Wattanosoth Hospital. Review of the literature includes extratesticular metastases; diagnosis and treatment are also discussed.

### Case Report

A 54-year-old male has a painless palpable mass at the left inguinal region for a period of 2 years. This mass became larger in size and firm in consistency and it descended to the left scrotum a year ago. The physical examination and all laboratory findings are unremarkable. The 18F-FDG PET/CT revealed hypermetabolic heterogenous enhanced mass with central necrosis at the left spermatic cord (Figure 1) and a non 18F-FDG avid hypodensitic mass at the left lobe liver was observed. (Figure 2). A needle biopsy was performed at the left testis and liver. The histopathological report revealed leiomyosarcomas of the spermatic cord (Figure 3A) and metastatic leiomyosarcoma of the liver (Figure 3B). Spindle cells with long cigar shape nuclei and pink cytoplasm arranged in fascicular pattern by H&E stain 200x magnification were seen. The patient underwent left radical inguinal orchidectomy and left hepatectomy. The macroscopic appearance of the left testis (Figure 4A) and the surgical specimen of left lobe of liver (Figure 4B) show a well circumscribed mass with minimal central necrosis at the spermatic cord and without necrosis at left metastasis.

He recovered after surgery very well. He was discharged after 12 days post-operation in good condition. The 18F-FDG PET/CT examination of the whole body 6 months later showed no evidence of hypermetabolic focus.

<sup>1</sup> Department of Surgical Oncology, Wattanosoth Hospital, Bangkok Hospital Group, Bangkok, Thailand.

<sup>2</sup> Department of Medical Oncology, Wattanosoth Hospital, Bangkok Hospital Group, Bangkok, Thailand.

<sup>3</sup> Department of Urology, Bangkok Hospital, Bangkok Hospital Group, Bangkok, Thailand.

\* Address Correspondence to author:  
Wutthi Sumetchotimaytha, MD  
Surgical oncology department, Wattanosoth Hospital,  
2 Soi Soonvijai 7, New Petchaburi Rd.,  
Bangkok 10310, Thailand.  
e-mail: wutthi.su@bangkokhospital.com

Received: July, 10, 2015.

Revision received: July, 10, 2015.

Accepted after revision: July, 10, 2015.

Bangkok Med J 2015;10:50-54.

E-journal: <http://www.bangkokmedjournal.com>

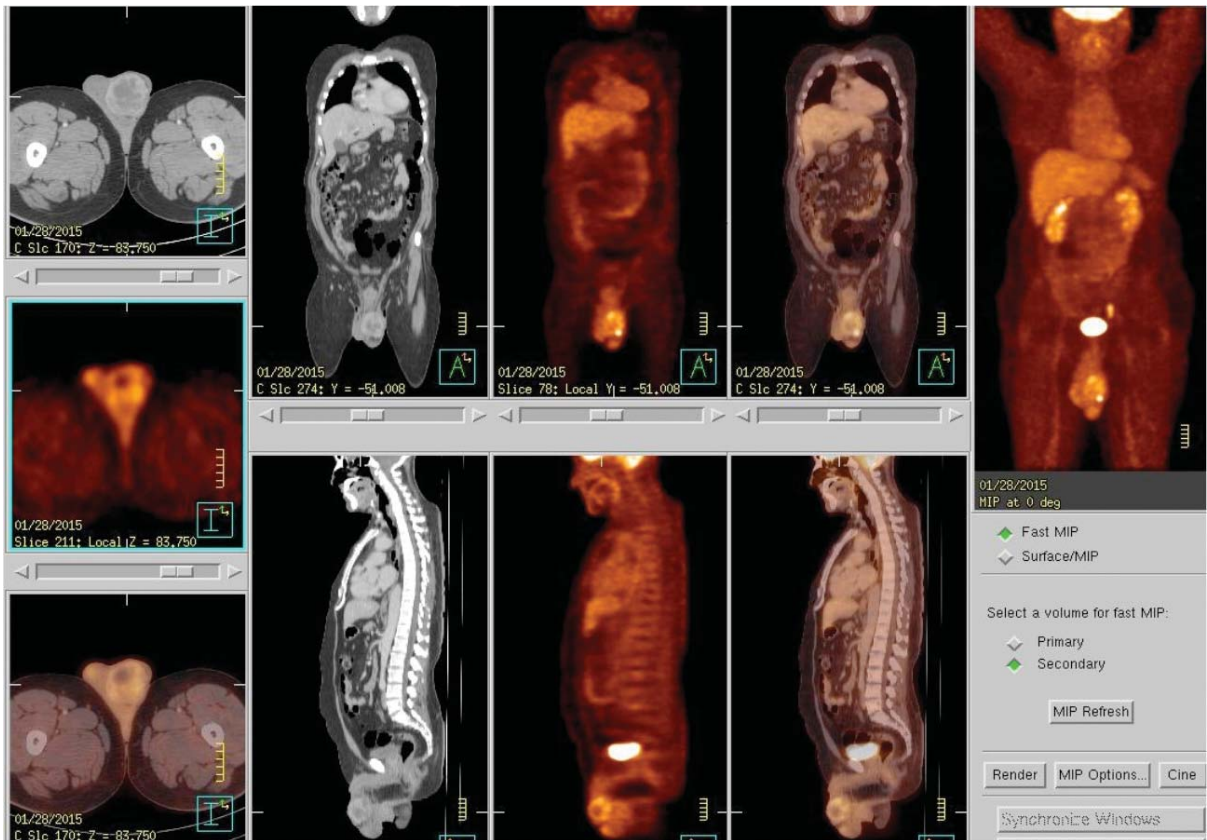


Figure 1: PET/CT scan revealed hypermetabolic heterogeneous enhanced mass at the left spermatic cord.

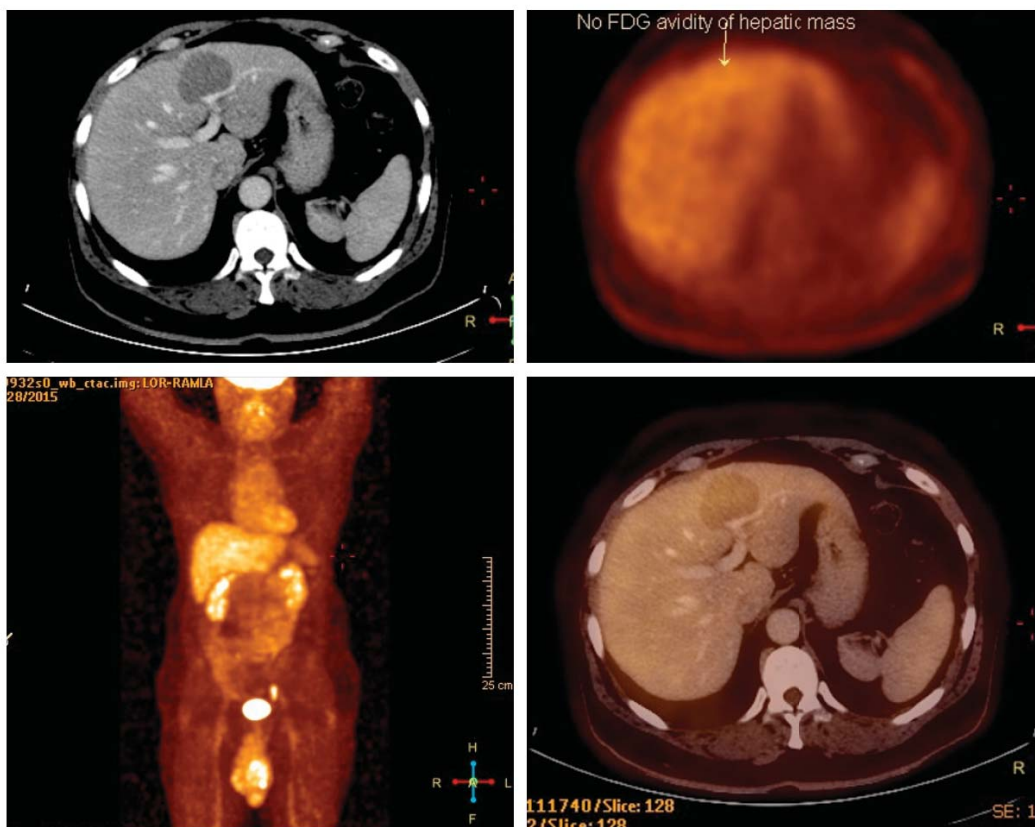
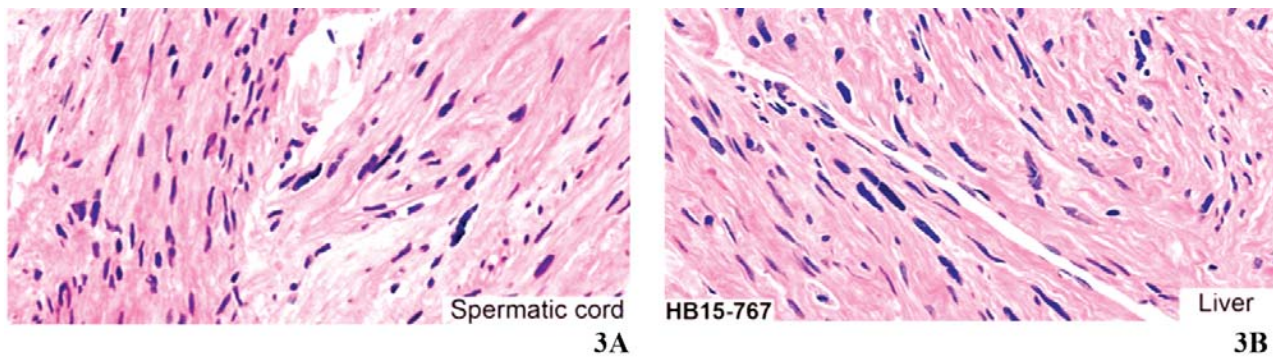
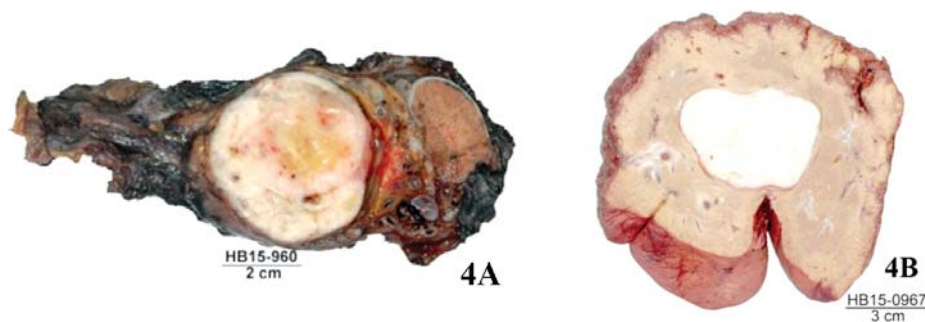


Figure 2: Non FDG avid hypodensitic mass at left lobe of the liver was observed.



**Figure 3A-3B:** Spindle cells with long cigar shape nuclei and pink cytoplasm, arranged in fascicular pattern, hematoxyline and eosin staining at 200x magnification.



**Figure 4A-4B:** Macroscopic appearance of the left testis reveals well circumscribed mass with minimal central necrosis (Figure 4A) at spermatic cord but no central necrosis at liver metastasis is observed (Figure 4B ).

## Discussion

Sarcomas are rare types of cancer that develop in the supporting or connective tissues of the body. This malignant soft tissue tumor can arise from any tissue containing smooth muscle. There are two main types, soft tissue sarcomas and bone sarcomas. Leiomyosarcoma comprise 5% to 10% of soft tissue sarcoma.<sup>4</sup> Leiomyosarcoma of the spermatic cord is rare; about 150 cases have been reported in the literature, and it is mainly diagnosed in the sixth and seventh decade of life. This type of leiomyosarcoma arises from undifferentiated mesenchymal cells of the cremasteric muscle and vas deferens. Leiomyosarcoma of the spermatic cord structures are known to spread by 3 routes: local invasion, lymphatic dissemination, and hematogenous metastasis. Regional lymph nodes are most commonly affected and include the external iliac, common iliac, and hypogastric nodes. The lung is the primary site of hematogenous metastases and is almost always involved in metastatic disease.<sup>5</sup> Clinically, leiomyosarcoma presents as a painless, firm, hard solid and slow growing mass in the cord. Preoperative investigations should include scrotal ultrasound to assess the mass and its relation to the testis, however, histological analysis and immunochemical staining of tissue is required for diagnosis.<sup>6</sup>

Once the diagnosis of leiomyosarcoma has been established by biopsy, clinical staging is necessary. Initial imaging should include plain radiographs of the affected area, computed tomography scan or magnetic resonance imaging of the abdominopelvic and inguinoscrotal regions, specifically looking for the presence of pelvic or retroperitoneal lymphadenopathy, which may be helpful in refining tumor location, as well as delineating the anatomic extent of the tumor. CT scan of the chest is useful to evaluate for the presence of metastatic disease in the lungs.<sup>7,8</sup> The role of 18F-FDG PET/CT-scan has not been established in routine clinical practice for leiomyosarcoma, but has been studied in other soft tissue sarcomas with early promising results. P18F-FDG PET/CT may prove particularly useful in evaluating patients who have undergone surgery in the search for metastatic lesions, or in looking for local disease recurrence.<sup>9</sup> The finding at the primary site shows a hypermetabolic heterogenous enhanced mass in contrast non 18F-FDG and avid hypodensitic mass at the left lobe of the liver. The curative treatment of choice is radical orchiectomy with high cord ligation and wide excision of surrounding soft tissue structures within the inguinal canal.<sup>10,11</sup> In one study, it was suggested that for small grade I and maybe for small grade II tumors, enucleation



might be a good therapy if an adequate follow-up is assured.<sup>12</sup> Adjuvant radiation therapy can lead to improved locoregional control and the recurrence could be reduced to 10-20%.<sup>13</sup> Because of the high propensity of local recurrence following surgery alone there is increasing consensus that all grades and histology should receive adjuvant radiotherapy, however, the use of radiation remains controversial.<sup>14</sup> There is currently no documented controlled studies that specifically address the role of adjuvant chemotherapy in the treatment of spermatic cord leiomyosarcomas. There should be a role for chemotherapy if there is evidence of lymphovascular permeation, distant metastasis or in cases with recurrences. Due to the limited number of cases of this rare malignancy, an ideal treatment protocol has yet to be established with most documented treatments currently describing spermatic cord leiomyosarcoma.<sup>15</sup> Long-term follow up is recommended as locoregional recurrence rates are as high as 50%. Patients should be closely monitored for a minimum period of 36 months.<sup>16</sup> There is no authoritative literature on the treatment in the case of single, isolated liver metastases from spermatic cord leiomyosarcoma to the knowledge of the authors. But in selected patients with isolated liver metastases from visceral and retroperitoneal leiomyosarcomas, complete resection of hepatic metastases results in prolonged survival.

It is extremely uncommon for a spermatic cord leiomyosarcoma and single, isolated metastasis to the liver to be the initial simultaneous presentation. Generally, liver metastases are late events in clinical progression and carry a poor prognosis. In our case, radical inguinal orchiectomy and high ligation of the cord along with left hepatic lobectomy meant no chemotherapy is employed. The histology from the specimen showed clear

margins, therefore, radiotherapy was not recommended. We proposed clinical, biochemical and radiological follow-up every 6 months in the first two years and annually thereafter.

## Conclusion

To our knowledge there are no reported cases of the spermatic cord leiomyosarcoma with single, isolated metastatic to the liver. Currently, we believe that surgery remains the treatment of choice for patients with resectable hepatic metastases from leiomyosarcoma of the cord. Surgical resection of hepatic metastases still holds a chance of cure or of extended survival. Due to the rarity of these tumors and because so little data is available, the decision to operate must be made on a case by case basis. For appropriately selected patients with isolated, limited liver metastases from spermatic cord leiomyosarcoma, there is no consensus as to the optimal selection of surgical candidates; however, the following criteria are recommended:

1. No extrahepatic disease, ascites or retroperitoneal adenopathy.
2. The primary tumor is controlled.
3. The patient is a medically appropriate candidate for hepatic resection.
4. Complete resection appears feasible.

The limited number of cases of this rare disease as well as the inconsistent management strategies utilised requires that further research be performed to formulate an ideal treatment protocol. Ongoing clinical trials may identify agents that may improve the overall and disease-free survival of patients suffering from this disease.

## References

1. Walsh RA, Vaughan., and Wein, A. (2003) Campbell's Urology (8th edition). W.B. Saunders Company
2. Bajaj P, Agarwal K, Niveditha SR, et al. Leiomyosarcoma arising from tunica vaginalis testis: a case report. *Indian J Pathol Microbiol* 2001;44:145-6.
3. Cánovas Ivorra JA, Sastre Albiach JM, Escrivà Escrivà C, et al. Spermatic cord leiomyosarcoma. Case report and bibliographic review. *Arch Esp Urol* 2009;62:70-3.
4. Rodriguez D, Barrisford GW, Sanchez A, et al. Primary spermatic cord tumors: disease characteristics, prognostic factors, and treatment outcomes. *Urol Oncol* 2014;32:52:19-25.
5. Watanabe J, Soma T, Kawa G, et al. Leiomyosarcoma of the spermatic cord. *Int J Urol* 1999;6:536-8.
6. Celik O, Unlu G. A rare case: paratesticular leiomyosarcoma. *Asian J Androl* 2013;15:843-4.
7. Enoch S, Wharton SM, Murray DS. Management of leiomyosarcomas of the spermatic cord: the role of reconstructive surgery. *World J Surg Oncol* 2005;31:23.
8. Kyratzi I, Lolis E, Antypa E, et al. Imaging features of a huge spermatic cord leiomyosarcoma: Review of the literature. *World J Radiol* 2011;3:114-9.
9. Mapulanga V, Mudenda V, Banda L. Case Report on Primary Intratesticular Leiomyosarcoma of the Spermatic Cord. *Med J Zambia* 2009;36:191-3.
10. Patil V, Verma A, Pattar RS, et al. Paratesticular leiomyosarcoma: a case report. *JNMA J Nepal Med Assoc* 2013;52:521-3.
11. Galosi AB, Scarpelli M, Mazzucchelli R, et al. Adult primary paratesticular mesenchymal tumors with emphasis on a case presentation and discussion of spermatic cord leiomyosarcoma. *Diagn Pathol* 2014;9:90.

12. Dangle P, Basavaraj DR, Bhattarai S, et al. Leiomyosarcoma of the spermatic cord: case report and literature review. *Can Urol Assoc J* 2007;1:55-8.
13. Tran LM, Mark R, Meier R, et al. Sarcoma of the head and neck. *Cancer* 1992;70:169-77.
14. de Bolla AR, Arkell DG. Leiomyosarcoma of the spermatic cord. *Postgrad Med J* 1983;59:470-1.
15. Soipi S, Vucic M, Ulamec M, et al. Leiomyosarcoma of the spermatic cord with scalp metastasis: case report and literature review. *Coll Antropol* 2014;38:763-6.
16. Mohammadi Torbati P, Zham H. Epithelioid type of paratesticular leiomyosarcoma: a case report and literature review. *Urol J* 2004;1:215-7.