

Practical Points in Diagnosis of Acute Appendicitis by CT Image and/or Pelvic Ultrasonic Scan: A Case Report



Suchato C, MD

Chirochana Suchato, MD¹

Abstract

Acute appendicitis is one of the most common causes of abdominal pain. CT image and/or pelvic ultrasonic scan are excellent resources to assist in diagnosis. The common locations to examine are retrocecal, pelvic and retroileum. The size of a normal appendix is less than 6 mm in diameter and the wall is less than 2 mm thick. The associated findings are periappendiceal edema with or without fluid collection and/or calcified fecalith in the lumen. In pregnancy and pediatric groups, ultrasound should be performed. The differential diagnosis is diverticulitis.

Keywords: locations of appendix, acute appendicitis

Acute appendicitis is one of the most common causes of acute abdominal pain. Some cases present as classical right lower quadrant pain and tenderness. Serum blood test findings include elevation of white blood cells (WBC), neutrophil and C-reactive protein test. However other cases may present with other more unusual symptoms and in these situations a computed tomography (CT) image and/or pelvic ultrasonic scan is recommended to provide additional support to the diagnosis.

The normal appendix diameter size is not more than 6 mm, and the mural wall is 2 mm thick. The common locations are retrocecal, pelvic and retroileum, and other locations are subcecal, preileal, and extraperitoneal (in 5% of reported cases). The other associated findings are periappendiceal edema with or without fluid collection. Fecalith in situ is most likely reported in the diagnosis. This case report gives details of three cases of acute appendicitis with differing presentations.

Case # 1: Pelvic Appendicitis

A 9-year-old male presented with the chief complaint of fever, abdominal pain for 3 days, vomiting for 8 hours and one bout of diarrhea prior to admission. Physical examination (PE) revealed lower abdominal pain and decreased bowel sounds. Total WBC $55.96 \times 10^3/\text{mm}^3$ (normal range $4.5\text{-}13.0 \times 10^3/\text{mm}^3$), neutrophil is 87.2% (normal range 46.5-75.0%). CT image without contrast enhancement and oblique reconstruction at right lower abdomen reveals an enlarged appendix 2 cm in diameter with an edematous mural wall with periappendiceal edema (Figure 1A). A single, small fecalith is seen at the root of the appendix. The tip of the appendix points to the pelvic cavity. Pelvic ultrasonic scan reveals an enlarged appendix 2 cm in diameter with thickening mural wall (Figure 1B). Pathological diagnosis is acute necrotizing appendicitis, ruptured (Figure 1C).

¹ Imaging Center, Bangkok Hospital, Bangkok Hospital Group, Bangkok, Thailand.

* Address Correspondence to author:
Chirochana Suchato, MD
Imaging Center, Bangkok Hospital
2 Soi Soonvijai 7, New Petchaburi Rd.,
Bangkok 10310, Thailand.
e-mail: chirochana@bangkokhospital.co.th

Received: January 8, 2016
Revision received: January 10, 2016
Accepted after revision: January 20, 2016
Bangkok Med J 2016;11:47-51.
E-journal: <http://www.bangkokmedjournal.com>

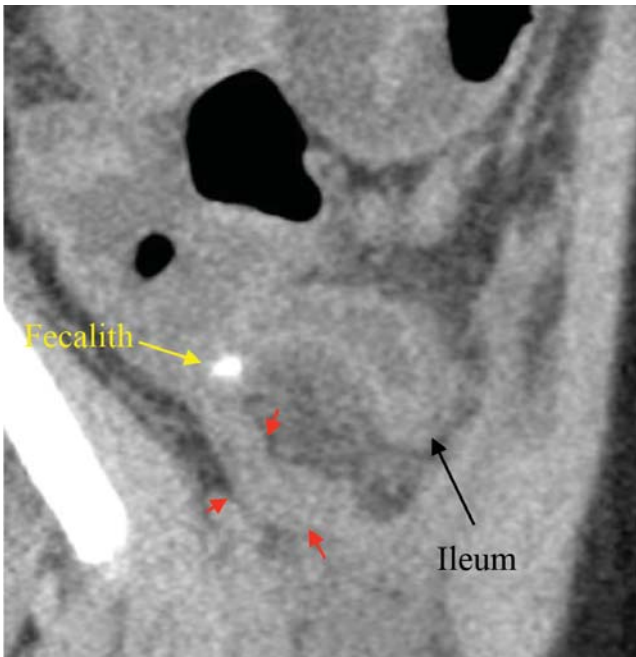


Figure 1A: CT image reveals markedly enlarged appendix with thickening wall (see red arrows).

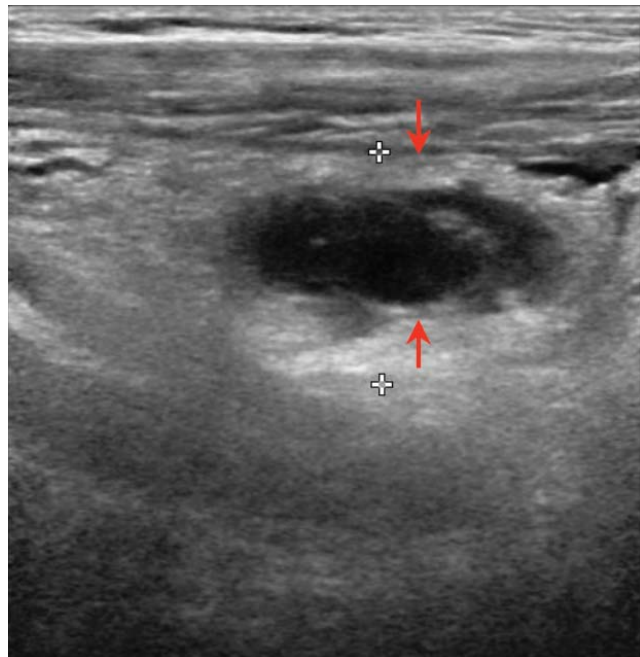


Figure 1B: ultrasonic scan finding reveals enlarged appendix with thickening wall (see arrows).

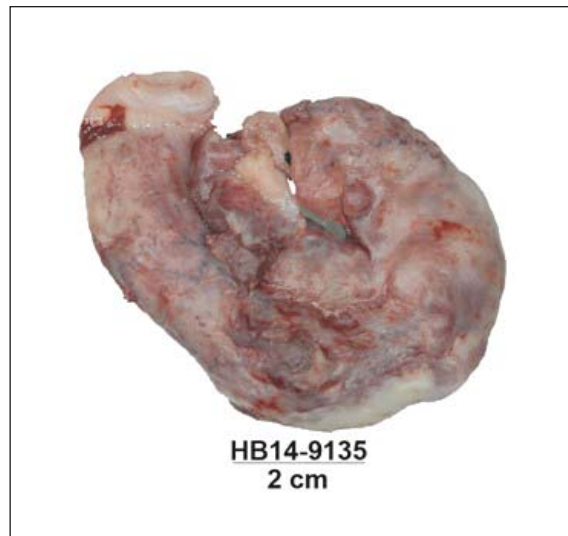

Figure 1C: Gross specimen of appendix.

Case # 2: Retrocecal Appendicitis

A 41-year-old male presented with the chief complaint of abdominal pain with diarrhea for 2 days and one day of fever and persistent abdominal pain. (PE) reveals marked tenderness at the right lower quadrant (RLQ), otherwise findings are unremarkable. Total WBC is $11.22 \times 10^3/\text{mm}^3$ (normal range $4.0\text{-}10.0 \times 10^3/\text{mm}^3$), neutrophil is 86% (normal range 46.5-75.0%).

CT image without contrast enhancement on the sagittal section reveals swelling of the appendix with a thickening mural wall containing a fecalith, located at the retrocecal region (Figure 2A). There is periappendiceal edema surrounding the body of the appendix. Pathological diagnosis is acute suppurative appendicitis with severe serositis, with presence of a fecalith (Figure 2B).

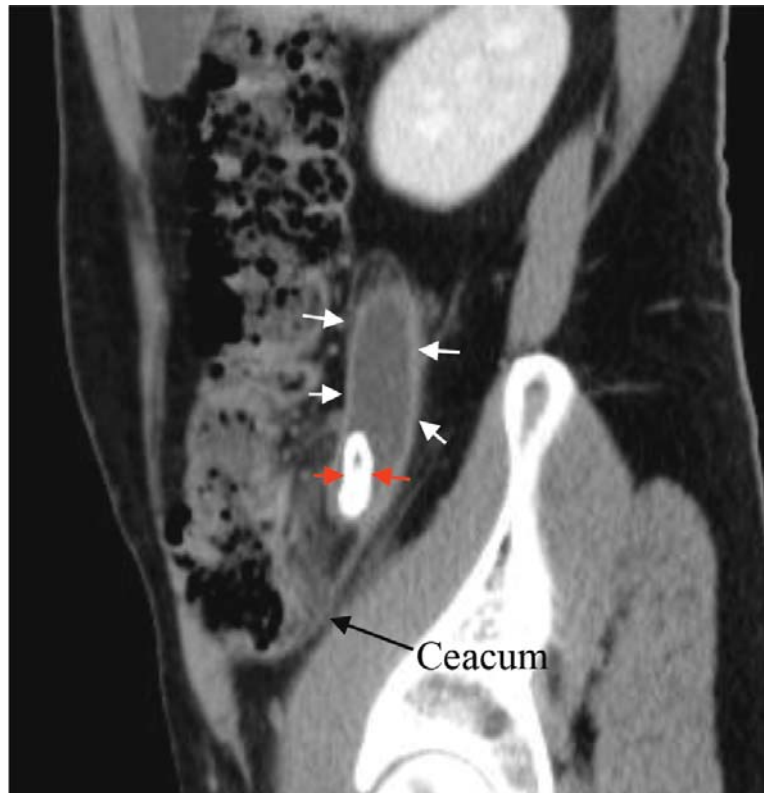


Figure 2A: CT image reveals enlarged appendix (see white arrows) containing calcified fecalith (see red arrows).

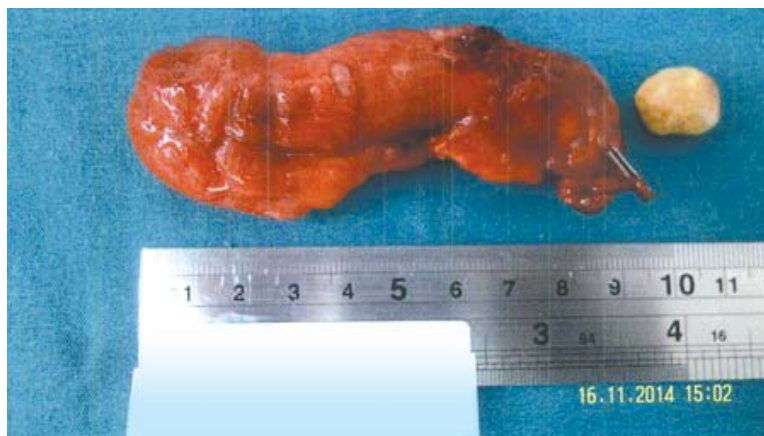

Figure 2B: Gross specimen of appendix with fecalith.

Case # 3: Retroileal Appendicitis

A 22-year-old female presented with the chief complaint of acute colicky abdominal pain, no fever or diarrhea is observed. PE tenderness at epigastrium and mid abdomen otherwise findings appear unremarkable. Total WBC $9.1 \times 10^3/\text{mm}^3$ (normal range $4.0\text{-}10.0 \times 10^3/\text{mm}^3$), neutrophil is 76.43 (normal range 46.5-75.0%). CT image reveals an enlarged appendix behind the terminal ileum (Figure 3A).

Pelvic ultrasonic scan reveals enlarged appendix with a thickening mural wall and minimal free fluid near the tip of the appendix, the terminal ileum lies anteriorly (Figure 3B). Pathological diagnosis show acute suppurative appendicitis with periappendicitis (Figure 3C).

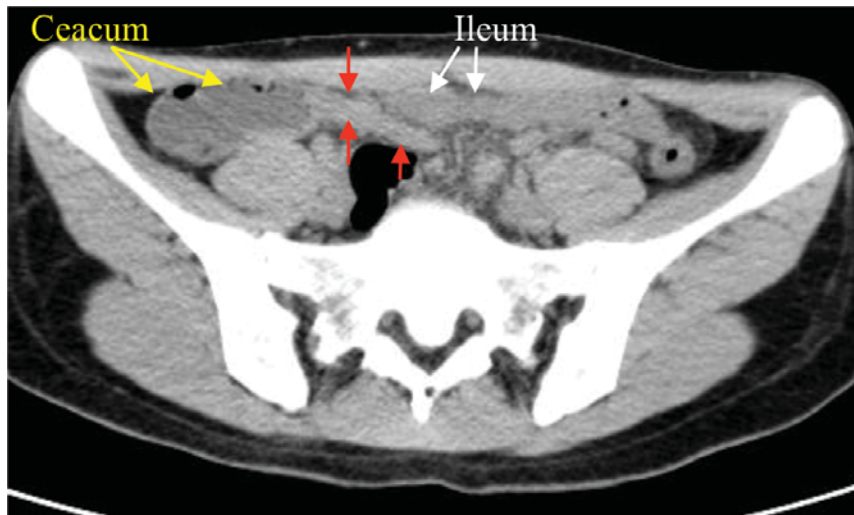


Figure 3A: CT image reveals enlarged appendix behind terminal ileum (see red arrows).

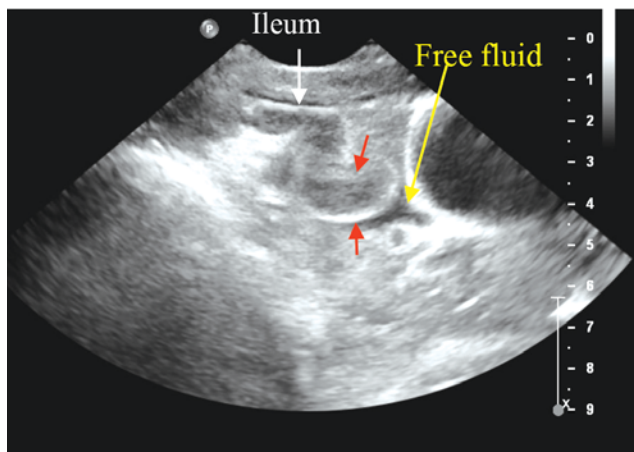


Figure 3B: Ultrasonic scan reveals enlarge appendix with a thickened mural wall (see red arrows)

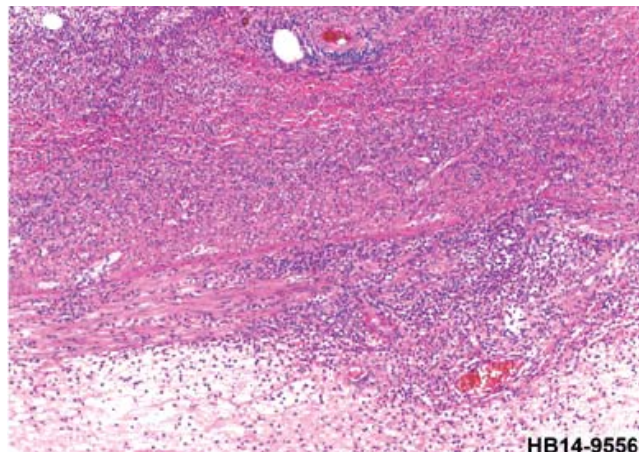


Figure 3C: Microscopic scan shows acute suppurative appendicitis with periappendicitis

Discussion

These three cases of acute appendicitis are presented with CT image findings, and in some cases diagnosis was obtained in combination with a pelvic ultrasonic scan to show the common locations of appendicitis to include the pelvic, retrocecal and retroileal regions. It is important to know the precise appendiceal location for surgical planning. The use of CT image and ultrasound are excellent in diagnosis with high sensitivity and specificity. The appendix can be found by tracing the tubular structure that arises from the tip of the caecum. There are some evidence-based issues about the optimization of using image modalities in this condition. A recent meta-analysis³ reveals CT examination in adult patients has high sensitivity and specificity for acute appendicitis and is superior to ultrasound with graded compression. But in the pediatric group, graded compression ultrasound is highly sensitive and specific in detecting acute appendicitis.

In equivocal cases, ultrasound followed by CT examination has a higher sensitivity but lower specificity than ultrasound alone because of increased false positives.

References

1. Jaffar A. Position of the appendix. Filmed at University of Sharjah, College of Medicine, United Arab Emirates, February 2013. (Accessed at August 10, 2015 at <https://www.youtube.com/watch?v=gEH-9CXIb5g>).
2. Dähnert W. Radiology Review Manual/Wolfgang Dähnert 6th edition. Lippincott William & Wilkins, 2007:804.
3. Blackmore C.C. et al, Imaging in acute abdominal pain: evidence-based Imaging. Springer, 2006:457-74.

In case of suspected pregnancy, ultrasonic scan should be the first diagnostic tool employed, and in some cases, it may be complicated to detect an enlarged appendix. On an ultrasonic scan we have to strictly identify each element, especially the caecum and ileum. The other possibility is colonic diverticulitis. The CT image plays an important role here mainly at the caecum and ascending colon. In diverticulitis, opaque density at the colonic wall may be depicted and is associated with evidence of pericolic edematous changes.

Conclusion

CT image and /or pelvic ultrasonic scan should examine the appendiceal locations and size of appendix with clinical correlation as well as laboratory findings in the diagnosis of acute appendicitis. Samples are presented with imaging and gross specimen/microscopic scans.

Ultrasonic scan is the first priority in case of pregnancy, and the identification of the caecum and ileum are an important consideration. The other possibility to investigate is colonic diverticulitis with shown the depiction of opaque density at the colonic wall and evidence of pericolic edematous changes may also be observed.