

Valentine's Day

Chomsuda Mongkolpanya, RT¹

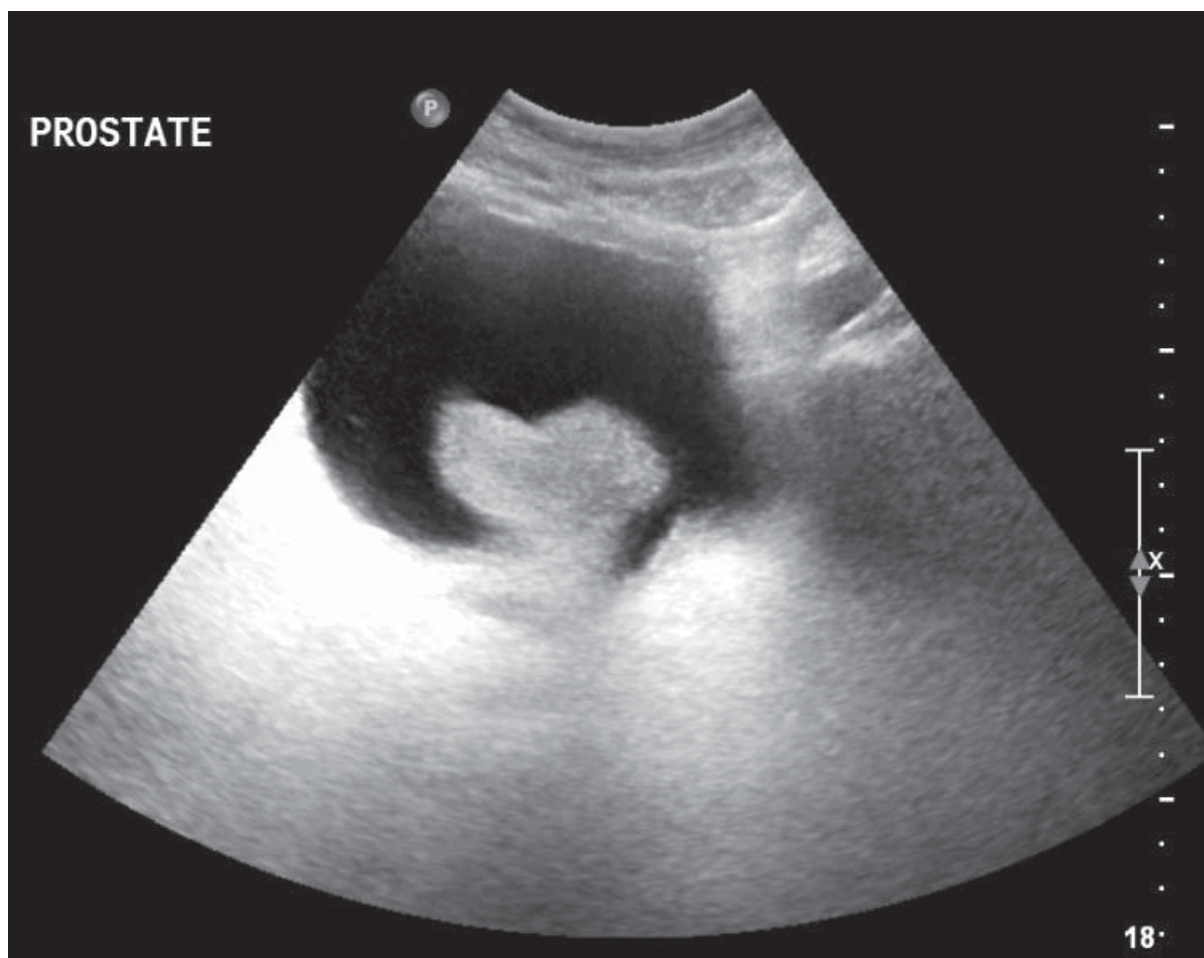
¹ Imaging Center, Bangkok Hospital Hua Hin, Bangkok Hospital Group, Prachuap Khiri Khan, Thailand.

Keywords: valentine's day, enlarged prostate gland

Received: January 18, 2016, Revision received: January 18, 2016, Accepted after revision: January 19, 2016.

Bangkok Med J 2016;11:81.

E-journal: <http://www.bangkokmedjournal.com>



A 66 year old male presenting with acute urinary retention and hematuria. Pelvic ultrasonic scan reveals markedly enlarged prostate gland mainly medial lobe projecting through the bladder neck simulating the image as “**Heart Configuration**”.