

## Foreign Body in Female Genital Tract

Usanee Chatchotikawong, MD<sup>1</sup>, Supatsareeya Banthao, RT<sup>2</sup>

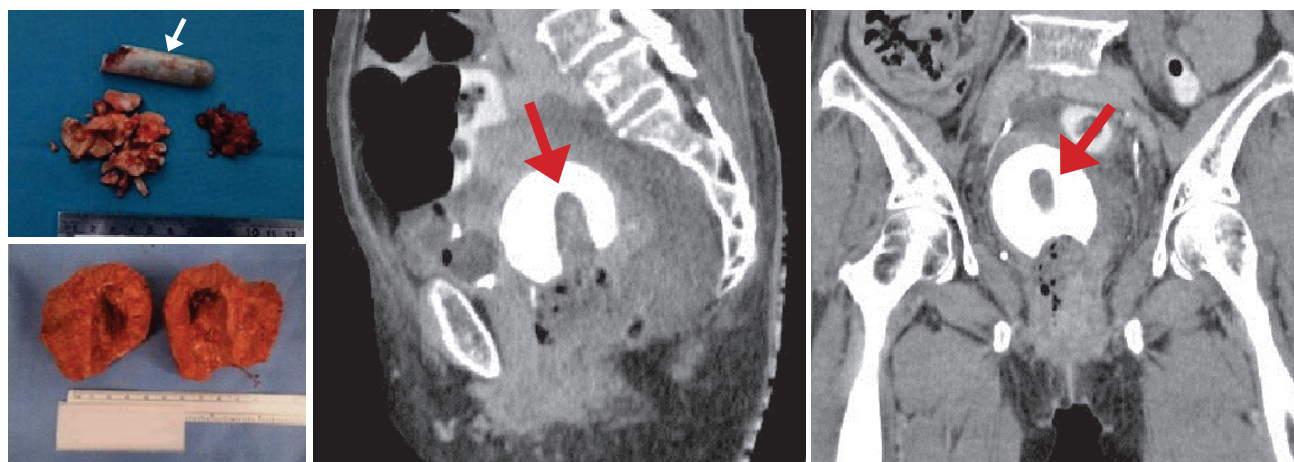
<sup>1</sup> Gynecologic Oncology, Bangkok Hospital Huahin, Thailand.

<sup>2</sup> Imaging Center, Bangkok Hospital Huahin, Thailand

Received: July 10, 2016; Revision received: July 21, 2016 ; Accepted after revision: August 22, 201

BKK Med J 2017;13(1): 113

www.bangkokmedjournal.com



A 74-year old unmarried female presents with the chief complaint of a stinking smell at the pelvic region which is recognized by her relative and brings her to the hospital. She denied inserting any foreign body into vagina. On examination, she is healthy, no fever, heart and lungs appear normal. No abnormal palpable abdominal mass except stinking smell at the pelvic region, on pelvic examination there is matted calcified foreign body in vaginal canal and broken salts bar (inhalant bar) (see arrow Fig A), however the residual foreign body remains in the vaginal canal because it could not evacuate all of the materials. A CT of lower abdomen with and without and IV and contrast enhancement is performed. The images of CT on coronal and sagittal sections reveal large rounded calcified FB in the uterine cavity measuring attenuation 832-1054 Hounsfield Units (HU), with rod like appearance hypoattenuation in the center. A salt bar was removed before this picture taken (see arrows Fig C-D). She underwent a total hysterectomy (Fig B). It shows a salts bar embedded in a calcified foreign body. The patient recovers eventually after the operation without any complication.

The presence of a foreign body (FB) in a genital organ commonly occurs in childhood or in young girls. For the most part, the FB are toys, toilet paper, pen caps.<sup>1,2</sup> In adults FB can include a sex toy. It is an unusual occurrence to present in a female older than 70 years old. Sankhwar, et al.<sup>3</sup> reported two cases, one is eighty-year old with a retained pessary and another one, a seventy-year old found with a dead cricket in the vaginal canal. Both cases present with vaginal discharge. In our case, the patient is a 74 years old unmarried female without any symptoms except her relative found that she developed a stinking smell, and once this was recognized by her relative the patient is brought to the hospital. She denied any FB insertion into the vaginal canal, however we found an old calcified FB and salts bars in the vaginal canal and uterine cavity by pelvic examination and CT image. In all circumstances when a foreign body is inserted into the genital organ regardless of age this can be verified even with a patient denies the insertion having taken place. A pelvic examination is recommended in all cases with suspicious clinical presentation.

### References

1. Paradise JE, Willis ED. Probability of vaginal foreign body in girls with general complaints. *Am J Dis Child* 1985;139(5):472-6.
2. Pushplata S, Devyani M, Pyari JS, et al. Bizarre foreign objects in the genital tract-our experience and review of literature. *Open Journal of Obstetrics and Gynecology* 2014;4:427-31.
3. Mausner EV, Yitta S, Slywotzky CM, et al. Commonly encountered foreign bodies and devices in the female pelvis: MDCT appearances. *AJR Am J Roentgenol* 2011;196:461-70.