

# Evaluation Artificial Intelligent (AI) Assists Radiologist in Radiographic Chest Interpretation

Kamolpong Osatavanichvong, MD<sup>1</sup> ; Eduardo de Goes Nakano, MD<sup>2</sup> ; Gerardo Dessí, MD<sup>3</sup> ; Thanis Saksirinukul, MD<sup>4</sup>



Kamolpong Osatavanichvong, MD

## Abstract

At the present time, real-time web-based imaging AI analytics for chest radiography is proving to be useful in assisting radiologists as a companion, in detecting an abnormality or mass on checkup chest films. It may reduce some cost for unnecessary studies, for instance chest tomosynthesis or high resolution computed tomography (CT) chest examinations. Sampling-case studies found that suspicious lesions especially lung nodules, parenchymatous disease and pneumothorax are sensitive for detection. However, AI analytics are not yet achieving satisfactory results in the detection of bony structures, heart and mediastinal lesions. Furthermore, it also may cause false positive results when a chest film examination is not a true PA (posterior-anterior) or AP (anterior-posterior) position.

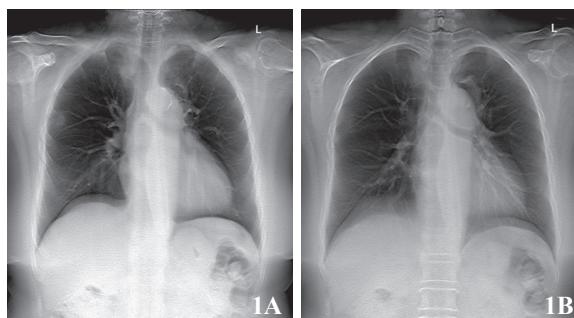
**Keywords:** artificial intelligence, AI, chest image, chest radiograph, chest tomosynthesis, fractured ribs, chest screening, pulmonary tuberculosis

Artificial Intelligence (AI) is integrated in the medical field especially in imaging. Routine chest radiography, mammography, CT and magnetic resonance imaging (MRI) are commonly used in the radiology department<sup>1</sup>, AI images are available to assist radiologists as an imaging companion, to increase quality and decrease time in interpretations. The use of Lunit INSIGHT<sup>2</sup> for chest radiography is evaluated to ascertain the probability of its usefulness and the advantage and disadvantage of this tool. Furthermore, the AI image is an advance in assisting in the upgrade of more crucial diagnosis and it will reduce costs of unnecessary investigations in the near future.

## Sample cases for evaluation:

### Case # 1

A 66-year-old female was married to a smoker, and as a secondary smoker, presented with severe headache for 3 weeks. Chest radiograph PA erect position (Figure A) and chest tomosynthesis (Figure 1B) revealed localized osteolytic lesion at right 4<sup>th</sup> rib near costochondral junction and localized patchy opacity at left upper lobe (see Figure 1). CT chest revealed a solid mass with irregular border at left upper lobe with mediastinal nodal metastases and also an osteolytic metastasis at right 4th rib (Figure 1C-D). MRI brain with gadolinium (Gd) contrast enhancement (not shown) revealed multiple cerebral and cerebellar metastases. Chest radiograph PA erect position with AI image revealed localized blue-spot abnormality at right upper and left upper lung fields (Figure 1E).



<sup>1</sup> Urupong Medical Center, Bangkok, Thailand.

<sup>2</sup> Radiology department, Group Fleury Radiologist at São Luiz Hospitals, São Paulo-SP, Brasil.

<sup>3</sup> Radiology Department, Ats Sardinia, Italy.

<sup>4</sup> Radiology Department, Bangkok Hospital, Bangkok, Thailand.

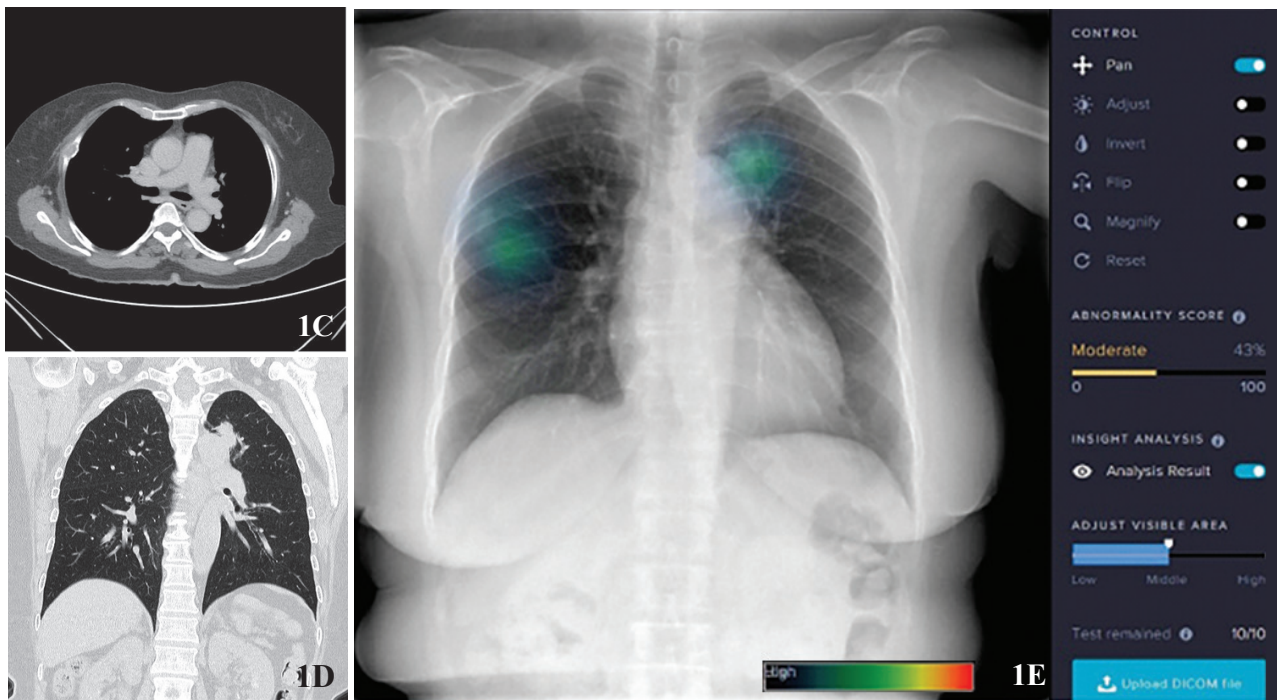
\* Address Correspondence to author:

Thanis Saksirinukul, MD

Radiology Department, Bangkok Hospital,

2 Soi Soonvijai 7, New Petchburi Rd, Bangkok 10310, Thailand.

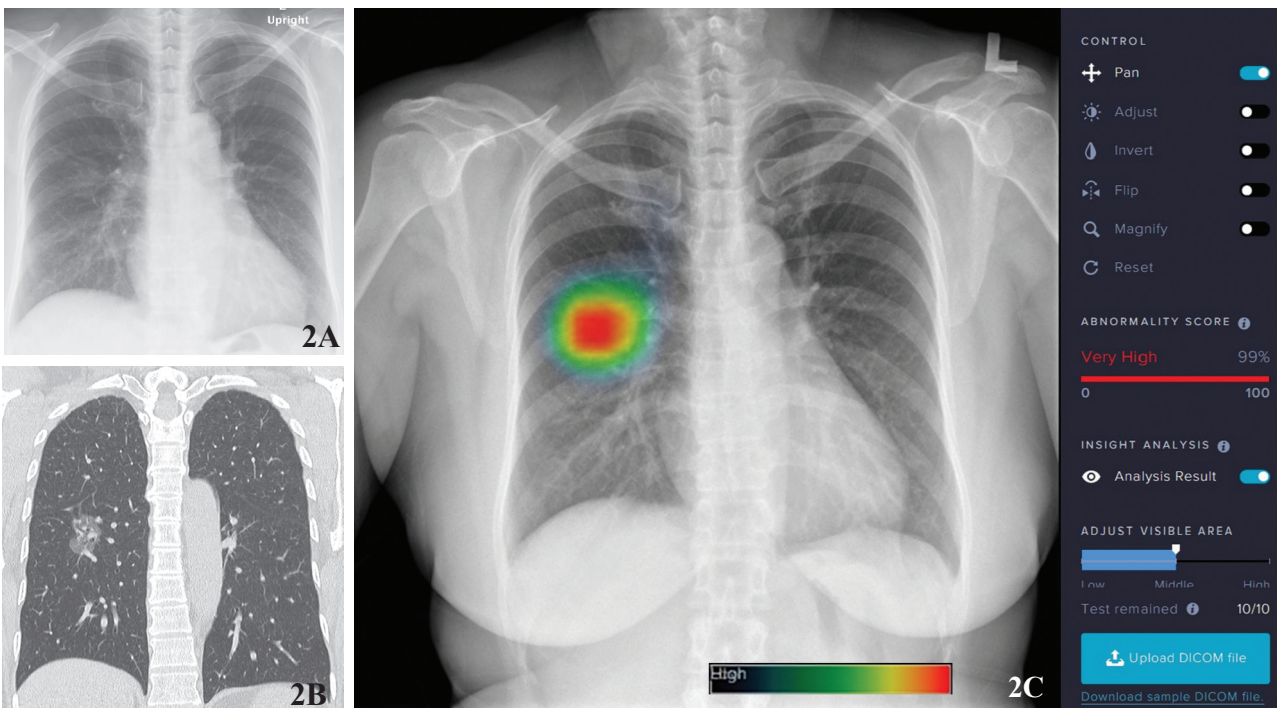
email: thanis.sa@bangkokhospital.com



## Case # 2

A 50-year-old female came in for a check up study. Chest radiograph PA erect position reveals suspected a faint pulmonary nodule at right mid lung zone (Figure 2A). Non-contrast enhanced CT chest confirms a ground-glass nodule at

superior segment of right lower lobe (Figure 2B). AI image reveals focal high score appearance (99%) at right mid lung zone (Focal red color) (Figure 2C). The pathology result showed non-small cell carcinoma.

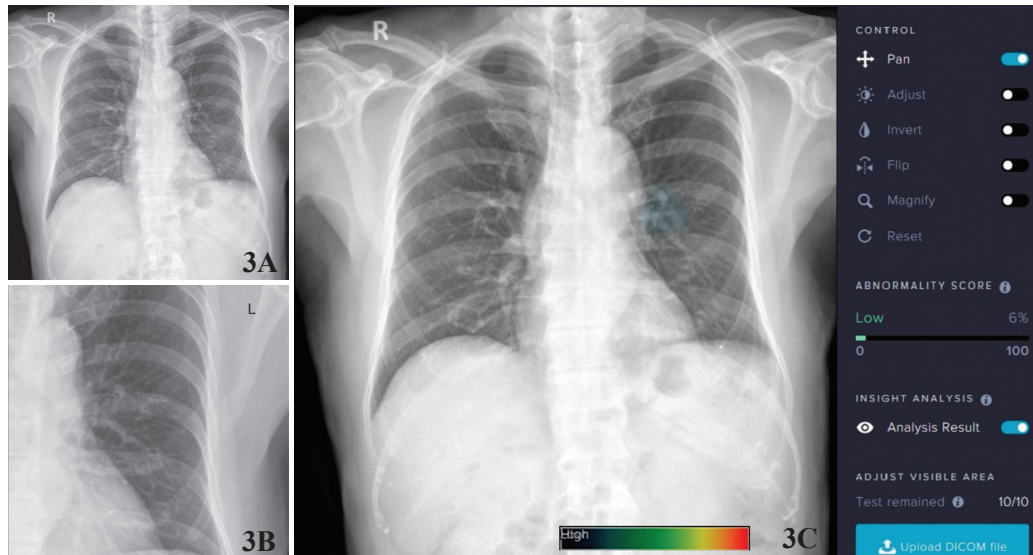




### Case # 3

A 82-year-old male had been taken for a PA chest radiograph as part of an annual checkup. Radiologist suspected a small pulmonary nodule at left middle lung field

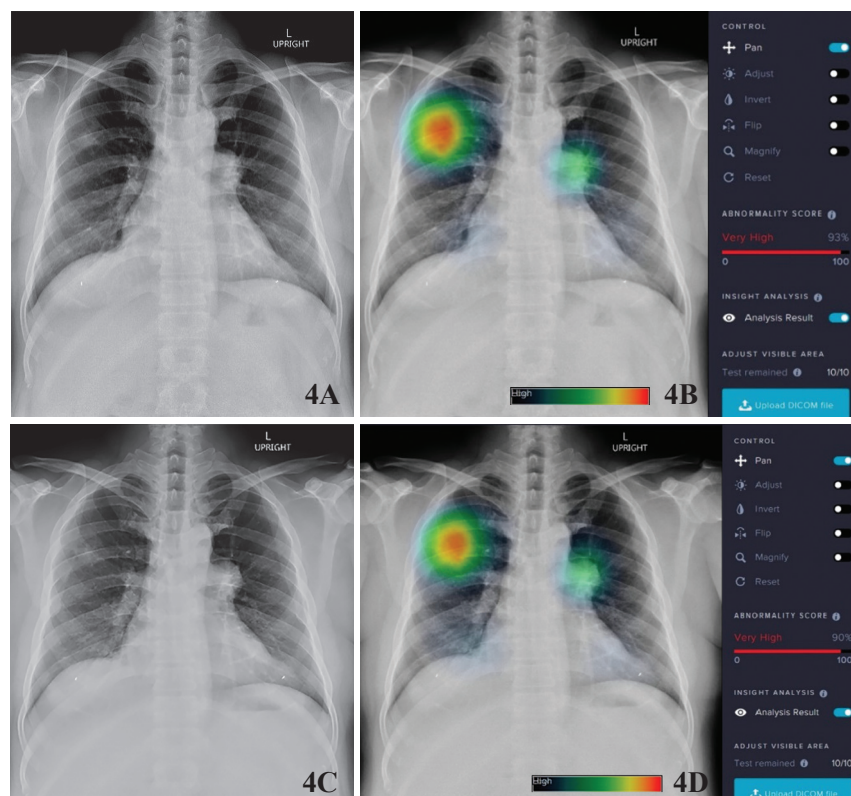
even on spot film (Figure 3A-B). An AI chest image was taken for a second opinion. AI chest image demonstrates (Figure 3C-D) low score, only 6%, at the suspected area.



### Case # 4

A 51-year-old male presents as a known case of pulmonary tuberculosis. Chest radiograph PA erect position taken in Apr 2017, revealed faint focal pulmonary opacity at right upper lobe and enlarged left hilar node (Figure 4A). AI chest image reveals a red-spot lesion at right upper lobe, very high score (93%) and a blue-hotspot at left hilar region as well (Figure 4B).

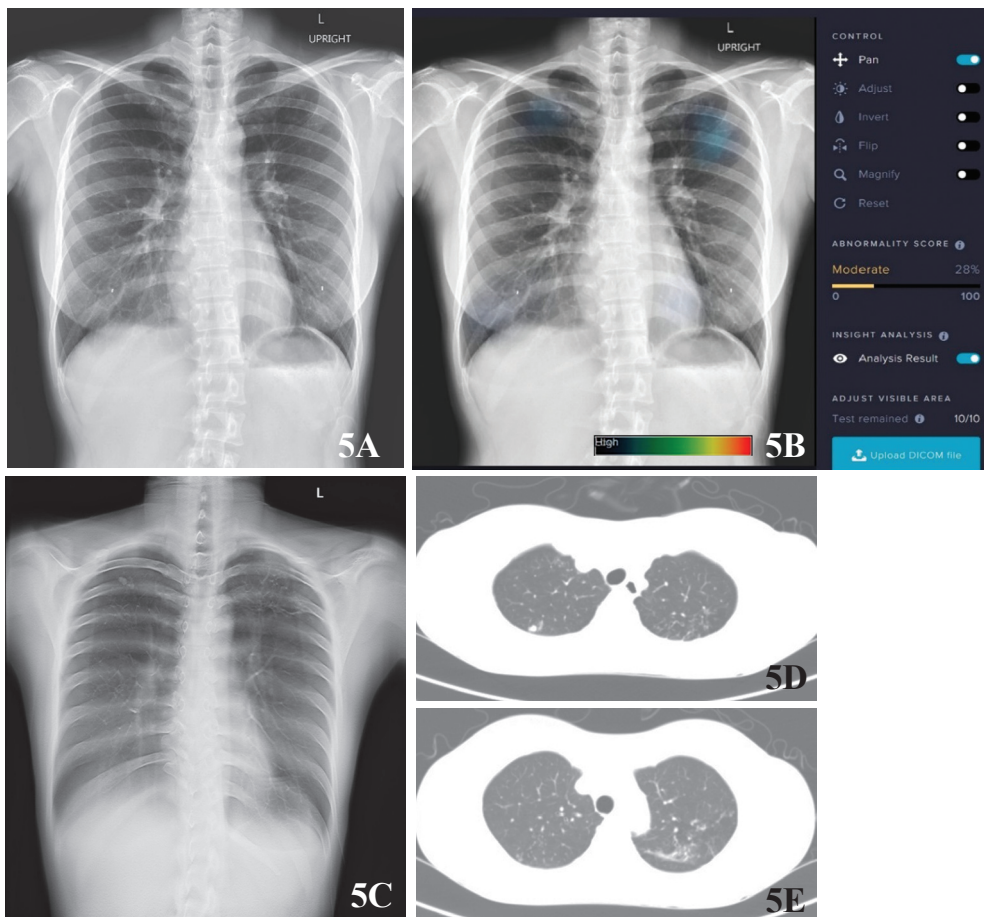
Follow-up chest film in the following year, April 2018, reveals slightly improved pulmonary opacity at right upper lobe but no significant changes in size of left hilar node are noted (Figure 4C). AI chest image reveals the red-spot at right upper lobe score reduced to 90% as well as left hilar node activity (Figure 4D).



## Case # 5

A 33-year-old female presented with dyspnea without fever. PA chest radiograph erect position (Figure 5A) revealed a few tiny nodules at right upper lobe. Left lung is clear. Heart appears normal. AI image chest (Figure 5B) reveals faint blue-spot at left upper lobe, score is 28%. Tomosynthesis chest

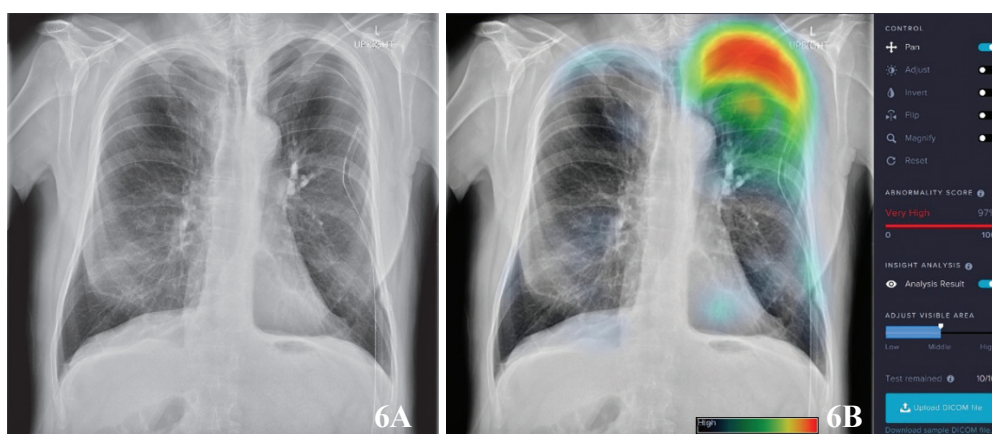
(Figure 5C) reveals focal fibronodular lesion at right upper lobe and focal fibroinfiltration at left upper lobe. CT chest axial sections (Figure 5D-E) reveal few small nodular lesions at right upper lobe and focal fibroinfiltration and nodules at left upper lobe, consistent with pulmonary tuberculosis.



## Case # 6

A 45-year-old male presented with left thoracotomy tube placement and localized pneumothorax at left upper hemithorax. Old fracture at left lateral 8<sup>th</sup> rib with callus formation is noted

(Figure 6A). Chest radiograph PA erect position with AI image revealed patchy red-spot abnormality at left upper hemithorax (Figure 6B) but there was no abnormality at left lateral 8<sup>th</sup> rib.

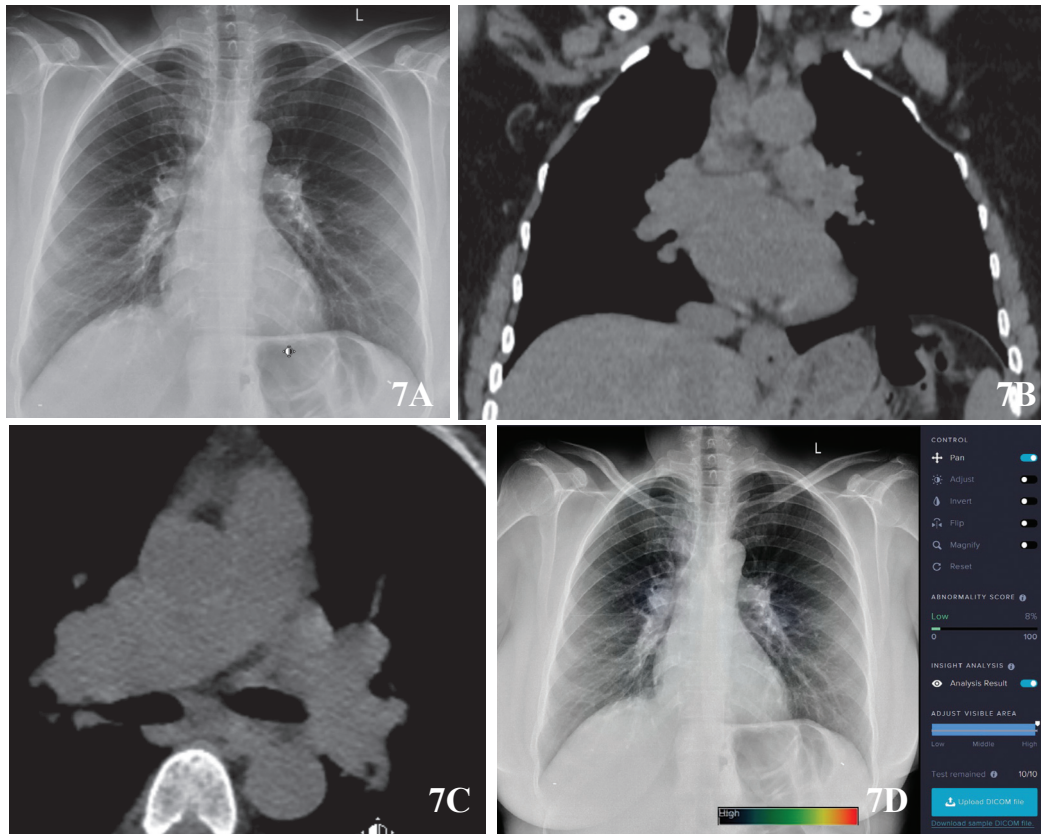




### Case # 7

A 45-year-old Ethiopian female presented with polyarthritis and abnormal chest radiograph, showing fullness of right hilum, suspicious for hilar lymphadenopathy (Figure 7A). CT chest without contrast was performed afterward, resulted in

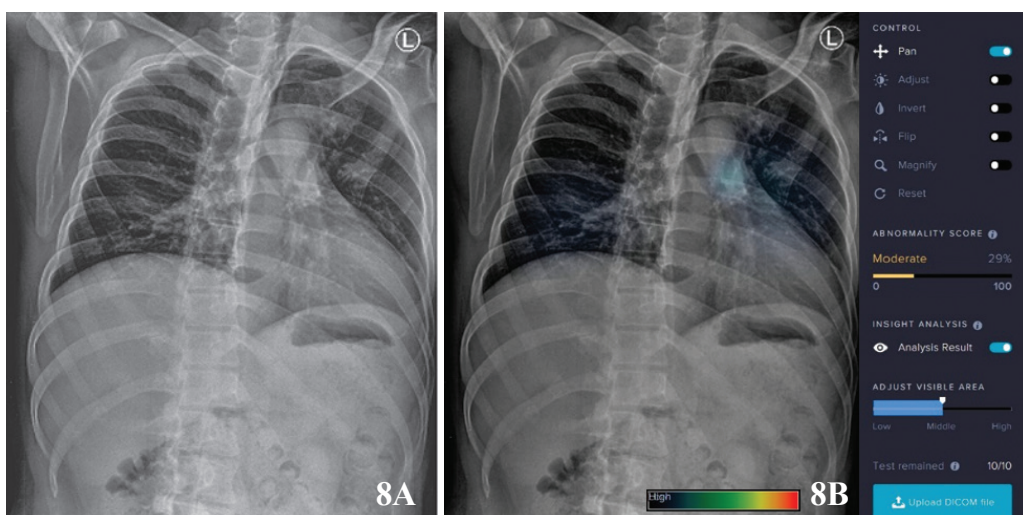
several enlarged bilateral hilar and interlobar nodes. (Figure 7B-C). AI image shows a faint blue focus overlying right hilum, score 8% (Figure 7D)



### Case # 8

A 37-year-old male with history of trauma, X-ray chest left oblique views reveals a linear fracture at left 11<sup>th</sup> rib (Figure 8A). AI image reveals two faint blue spots at left

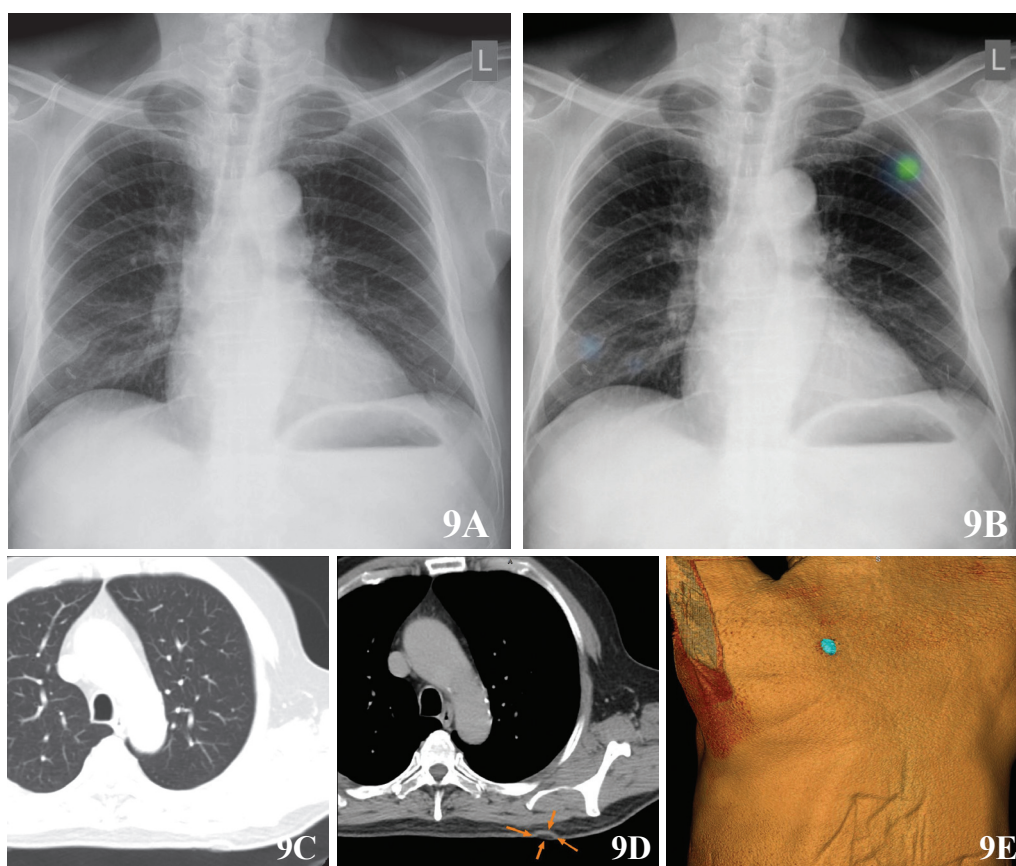
upper and lower lobes but no abnormality at left lower rib is noted. AI chest image can produce false positive findings when the chest image is not a true PA or AP position (Figure 8B).



## Case # 9

A 51-year-old asymptomatic male came for checkup. Chest radiograph found a nodular opacity at left upper lung field (Figure 9A). AI image shows a focal blue-spot, score 66% (Figure 9B), at the same location as chest image findings. Computed tomography with lung window shows no demonstrable pulmonary nodule (Figure 9C), but on soft

tissue window, the opacity at left upper lung field on chest radiography is a superficially cutaneous fatty-dense nodule (Arrow, Figure 9D). On 3D volume rendering image (Figure 8) demonstrates a superficial cutaneous nodule at the left upper back, consistent with nevus lipomatosus cutaneous superficialis.



## Results

Case 1 demonstrates a left upper lobe lesion on AI image, and also a blue spot abnormality area at right upper lung field. On the CT chest reveals pulmonary mass at left upper lobe with irregular border which is consistent with lung cancer, associated with multiple brain metastases on MRI study. An osteolytic lesion at right 4th rib detected by CT image which AI image shows blue spot lesion simulating false positive.

Case 2 reveals suspected lesion at right mid lung zone on chest x-ray film which can be demonstrated by AI image, and also confirmed by CT afterward. Case 3 Annual checkup reveals a suspected small pulmonary nodule at left lung even questionable on cone view. AI image reveals no abnormality at lung parenchyma and Case 4 is a known case of follow-up treatment of pulmonary tuberculosis reveals decreased score of abnormality at right upper lobe and left hilar region.

Case 5 shows a suspected tiny nodule at right upper lobe, other areas appear normal. AI image reveals blue-spots at right upper lobe and left lung, the score is 28%. Tomosynthesis chest and CT chest reveal few small pulmonary nodules at right upper lobe and focal fibro-infiltration and nodule at left upper lobe.

In Case 6-AI image shows a good demonstration of pneumothorax but it does not demonstrate fractured ribs. Case 7-AI image shows a low scoring blue spot at right hilum, consistent with CT findings as mediastinal lymphadenopathy. Case 8-AI image shows no abnormality at ribs on chest radiograph oblique view, but there is a faint hotspot at right hilar region. Furthermore, AI image confirms a superficial cutaneous nodule on Case 9

## Discussion

Case 1 chest radiograph PA erect position with AI image reveals a dramatic result in terms of assisting the radiologist in interpretation, proven by CT chest, as mentioned by Lunit<sup>®2</sup> that could detect lung cancer (97% area under a curve (AUC)). In case 3, AI image may help in case of a radiologist companion. It will reduce the cost of high equipment investigation, for instance chest tomosynthesis or CT studies. In case 4, pulmonary tuberculosis, the AI image is very useful for follow-up evaluation after treatment.

Case 5 and Case 2, AI images show more sensitive than ordinary chest film examination and increased confidence of interpretation. Hence AI image is recommended in case of suspected lung lesions before getting findings from a sophisticated investigation which will lead to higher cost and higher radiation dose. A limitation is observed in Case 9, as the AI image cannot differentiate between extra-pulmonary nodules. Case 6 and 8 reveal failure to demonstrate the fracture lines at ribs but AI image is sensitive to detect pneumothorax on Case 6, Lunit<sup>®2</sup> also revealed 99% AUC of pneumothorax detection.

In Case 7, AI can show a faint blue spot, representing low score, on the equivocal hilar findings as hilar fullness on chest radiograph. This observation shows that AI could raise radiologist awareness of subtle or equivocal abnormality of hilum and/or mediastinum for further investigating. However, in Case 8, AI image shows false positive on left upper and lower lobes at oblique view. The failure to demonstrate fracture rib at the time being is due to the algorithm not being designed to detect fractures.

## References

1. Siemens Healthineers. White paper: Medical imaging in the age of artificial intelligence, 2017. (Accessed May 5, 2018 at <https://www.siemens.com/press/pool/de/events/2017/healthineers/2017-11-rsna/white-paper-medical-imaging-in-the-age-of-artificial-intelligence.pdf>).
2. Lunit INSIGHT: <https://insight.lunit.io/#home>.
3. Harvey H. Separating the art of medicine from artificial intelligence, Dec 21, 2017. (Accessed May 5, 2018 at <https://towardsdatascience.com/separating-the-art-of-medicine-from-artificial-intelligence-6582f86ea244>).

Hugh Harvey<sup>3</sup> commented to develop an AI as actually chest film reading, further researches are concerned as followings; 1). Dataset should be includes patients' details, epidemiology, history, blood tests, following CT resulted, biopsy results and genetics etc. 2). Using experts trained specifically annotates images in the dataset. 3). Using standardize radiological language.

## Conclusion

Further observations and studies of AI chest images are crucial for its development, to lead to improved quality of medical image interpretation in the near future.

AI for chest radiograph is helpful for chest screening, mass chest, routine checkup, hilar lesion in doubt, follow-up after treatment or reduction in the cost of unnecessary studies. AI image is helpful in assisting the radiologist as an image companion. It is not designed for detecting bony structure, heart and mediastinum abnormality. It may give a false positive when it is not at a true PA or AP erect position. Limited differentiation of extra-pulmonary lesion on the AI image is observed. At the present time, AI image cannot differentiate diseases and further development of the algorithm AI system is needed. The most sensitive detections are pneumothorax and lung parenchymatous lesions.

## Acknowledgement

With appreciation to Lunit Company for providing AI radiograph software to evaluate chest radiograph as a radiologist companion. We thank Bangkok Health Research Center and Imaging Center, Bangkok Hospital.