

Rib Fracture Fixation with Osteosynthesis Plates in Bangkok Hospital Headquarters: A Case Report

Pongtorn Sirithianchai, MD¹; Eakachit Srikarinkul, MD¹; Padungkiat tangpiroontham, MD²; Jamorn udomkusonsri, MD²; Suthorn Bavomratanavech, MD¹



Pongtorn Sirithianchai, MD

Abstract

Rib fractures are the most common injury sustained following blunt chest trauma. Since it is a procedure that has been recently introduced, many researchers have been studying and reporting on the advantages of rib fixation for the treatment of rib fractures. The authors of this study developed a guideline for rib fracture fixation in patients who have flail chest or multiple rib fracture injuries. Therefore, this study aimed to report the advantages of conducting rib fracture fixation with osteosynthesis plates at Bangkok Hospital Headquarters. The study consists of three cases who received rib fracture fixation following the suggested guidelines. All three cases demonstrated improvement of ventilation after rib fixation, a short intubation period, and no post-operative pulmonary infection. In conclusion, rib fracture fixation is a treatment option for flail chest patients that reduce indications of mechanical rib cage failure.

Keywords: rib fracture, rib fracture fixation, osteosynthesis, flail chest

Simple rib fractures are the most common injury sustained following blunt chest trauma, accounting for more than half of the thoracic injuries that result from nonpenetrating trauma. Approximately 10% of all patients admitted after blunt chest trauma have one or more rib fractures. These fractures are rarely life-threatening but can be an external marker of severe visceral injury inside the abdomen and the chest.

First-rib fractures are considered to be an indicator of increased morbidity and mortality in major trauma. According to one study from the UK Trauma Audit and Research Network, a first-rib fracture is a significant predictor of injury severity (Injury Severity Score >15) and polytrauma.

Multiple rib fractures are very common in patients with thoracic trauma and are associated with significant morbidity and mortality rates especially in patients with flail chest injuries.¹ A flail chest injury is defined as at least three adjacent ribs fracturing in which there are fractures in at least two places. Flail chest injury presents with paradoxical movement of the chest wall that leads to inadequate breathing and ventilation, pulmonary dysfunction, and potential lung infection.¹⁻³ The reported mortality rate in flail chest injury is about 10-33%.^{1,2} Multiple rib fractures can lead to respiratory insufficiency due to pulmonary contusion, intrathoracic organ injuries, and severe pain with chest wall movement. Respiratory insufficiency can lead to significant morbidity and mortality rates.^{2,4,5}

Conservative treatment of multiple rib fractures is a standard treatment that consists of acute pain management such as analgesic medication and intercostal nerve block,⁶ a mechanical ventilator and pulmonary hygiene. However, in some patients, conservative treatment may result in a prolonged intensive care units (ICU) stay, pulmonary complications or prolonged intubation.^{6,10}

A recent meta-analysis showed rib fixation for flail chest can reduce mortality, lead to a shorter hospital stay, and lower incidences of pneumonia and the need for a tracheostomy compared to non-operative treatments.^{7,8} However, there was insufficient data supporting rib fixation in cases of multiple rib fractures without a flail segment.

¹ Department of orthopedic, Bangkok Hospital Headquarter, Bangkok, Thailand.

² Cardiovascular clinic, Bangkok Heart Hospital, Bangkok, Thailand.

* Address Correspondence to author:

Pongtorn Sirithianchai, MD
Department of orthopedic,
Bangkok Hospital Headquarter,
2 Soi Soonvijai 7, New Petcharuri Rd.,
Bangkok 10310, Thailand.
email: pongtorn.si@bangkokhospital.com

Received: December 06, 2018

Revision received: December 14, 2018

Accepted after revision: January 29, 2019

BKK Med J 2019;15(1): 82-90.

DOI: 10.31524/bkkmedj.2019.02.014

www.bangkokmedjournal.com

In Thailand, rib fixation is a relatively new procedure and the procedure's advantages are doubted. However, based on the evidence that supports the use of rib fixation, especially in cases of flail chest injury, the authors of this study developed a guideline for rib fracture fixation aimed to reduce morbidity and mortality in patients who have a flail chest or multiple rib fractures injury (Figure 1). The contraindications of rib fixation are severe pulmonary contusion, severe head injury, and spinal injury (precluding lateral decubitus position).⁹

In this study, we aimed to report the outcomes from three patients who underwent rib fracture fixation. The operations were performed by four surgeons (two orthopedic trauma surgeons and two cardiovascular surgeons) who attended a Thoracic instructional course cadaveric workshop MatrixRIB system for sternal and rib fixation. All cases in our series use MatrixRib system (Synthes).

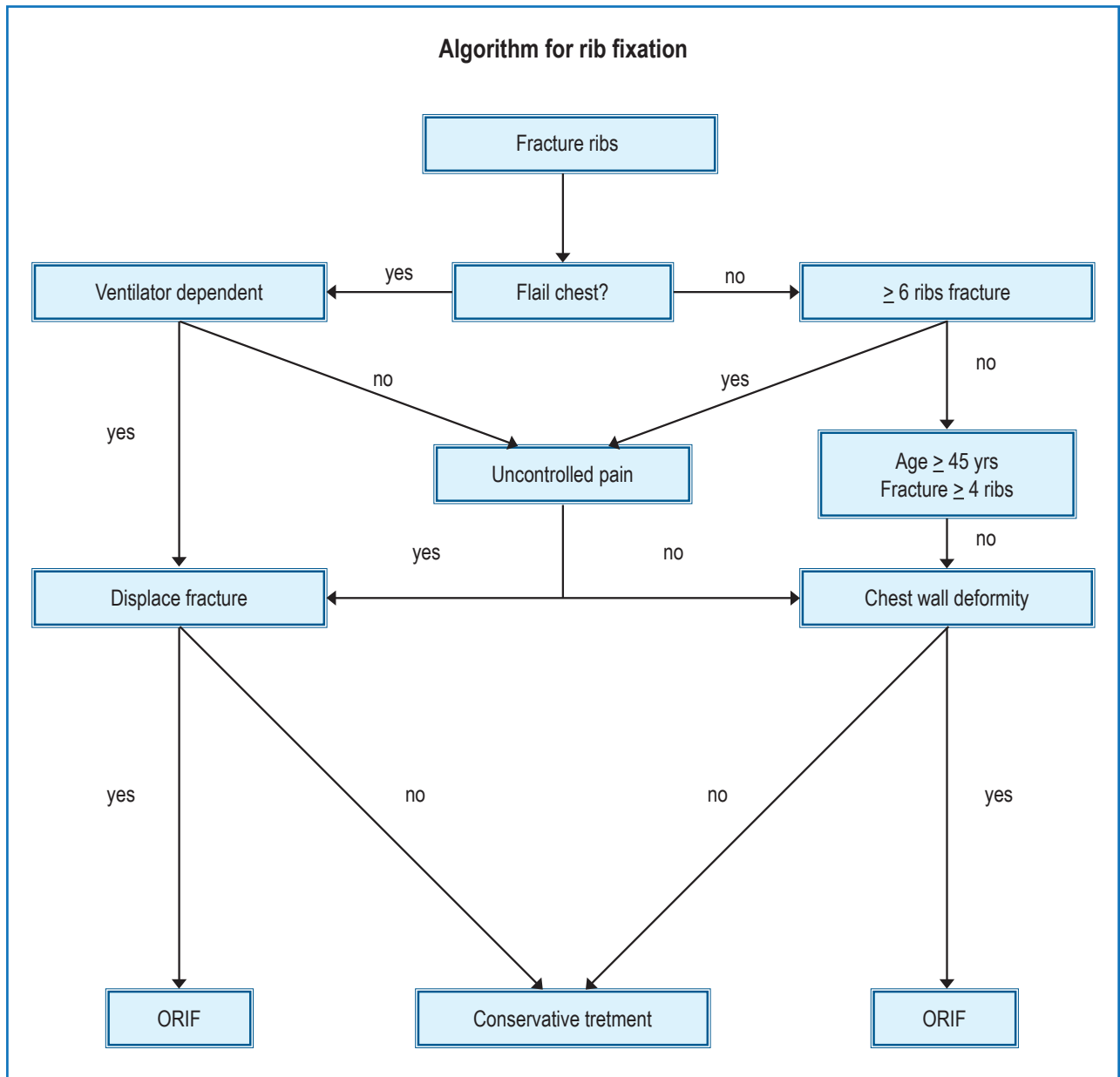


Figure 1: Algorithm for rib fixation at Bangkok Hospital Headquarters (modified from “Rib fractures: To fix or not to fix? An evidence-based Algorithm” Micheal Bemelmann, et al.⁹

Case # 1

A 55 year old man suffered from traumatic injury resulting from a motorcycle accident. Using the Glasgow coma scale, the patient was found to be unconscious with a score of $E_1V_1M_2$. Furthermore, the patient was diagnosed with a paraplegic condition with T11 burst fracture and multiple right ribs fracture with flail chest. In addition, the patient was detected pneumothorax and was initially managed and treated by intercostal drainage (ICD), see Figure 2.

The patient's injury was re-examined and it was confirmed that he had sustained a burst fracture with paraplegia resulting from spinal cord transecting. The patient was assisted with continuous mandatory ventilation (CMV) mode, ICD drainage on the fifth chest. On the 6th day following the injury, the patient underwent spinal surgery with pedicular screw fixation from T9 to L1 and decompression. After spinal fixation, the patient used ventilator support pressure controlled ventilation (PCV) mode, PEEP 5 cmH_2O , FiO_2 0.35. Further diagnosis showed that he suffered with pneumonia due to obstruction with respiratory secretions. With the condition of flail chest and being ventilator dependent, the team decided to use rib fixation approach. In general, the contraindication to rib fixation includes spinal fracture with the exception of this case where the spinal cord and nerve roots has been initially fixed appropriately, rib fixation could be performed. At 10th day after injury, the ultrasound was used to mark the location at the 3rd - 6th rib before incision (Figure 2A - B) and the team operated rib fixation, anterolateral right rib 3rd - 6th with anterolateral approach (Figure2C).

Skin incision was performed in the oblique fashion at anterolateral chest wall, subcutaneous exposure then subperiosteal elevated serratus anterior muscle from their origin (Figure 2D). Reduction of rib 3rd - 6th was performed by gentle direct reduction and remaining aware to avoid pleural injury below the ribs (Figure 2E). Three anatomical plates and one universal plate 8 holes were used and fixed with three locking screws on each side of the fracture (Figure 2F). On the 1st post-operative day, the patient used ventilator PCV mode, PEEP 8, FiO_2 0.4, which helped to clear up the secretion. On the 2nd post-operative day, his ventilation improved, and he was able to use synchronized intermittent mechanical ventilation (SIMV) mode, pressure support 10 PEEP 8, FiO_2 0.5. From the 3rd - 7th post-operative day, he used ventilator continuous positive airway pressure (CPAP) mode, PEEP 8, FiO_2 0.3 with oxygen saturation 98-100%. His secretion decreased, with fewer fever peaks. He was referred back to Australia on the 9th day after rib fixation with stable hemodynamic, no fever, GCS $E_3V_4M_4$. Yet, he remained paraplegic and required ventilator aids in CPAP mode, PEEP 10, FiO_2 0.3. After rib fixation, it was found that his ventilation had improved from full ventilator support CMV mode to CPAP mode and lung secretion also improved.

In this case, we decided only to fix the anterolateral fracture site at each rib due to the posterior site and the skin incision close to the surgical wound of the spinal fixation as they may be future problems from the skin bridge and an increased risk of infection.

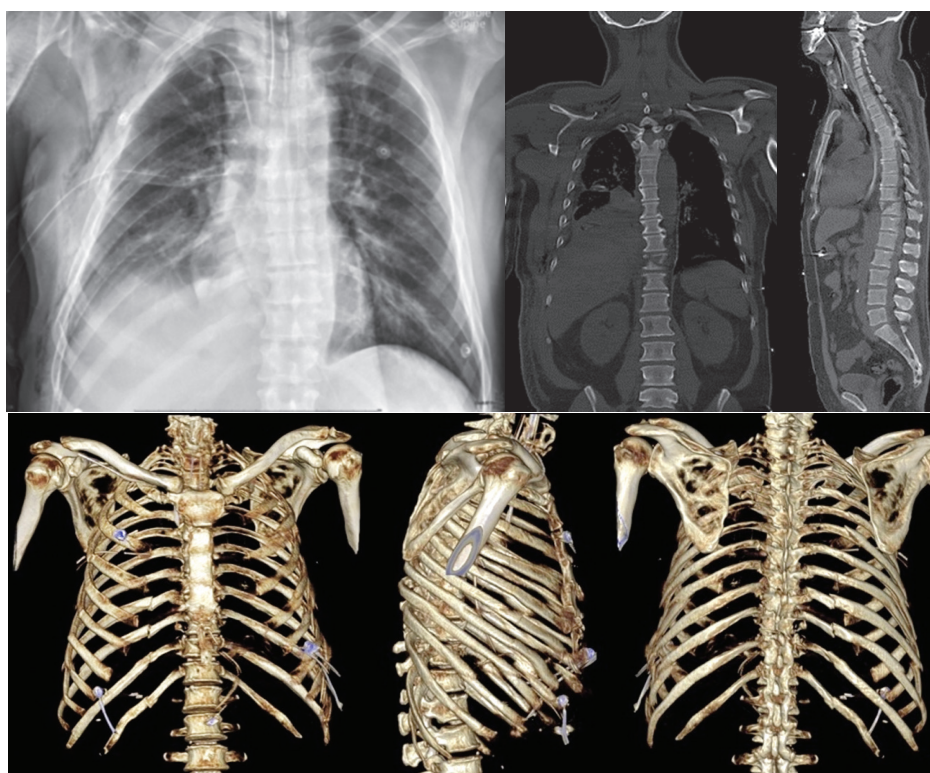


Figure 2: X-ray and computed tomography (CT) scan show multiple right ribs fracture (rib 2nd - 11th) with flail chest.

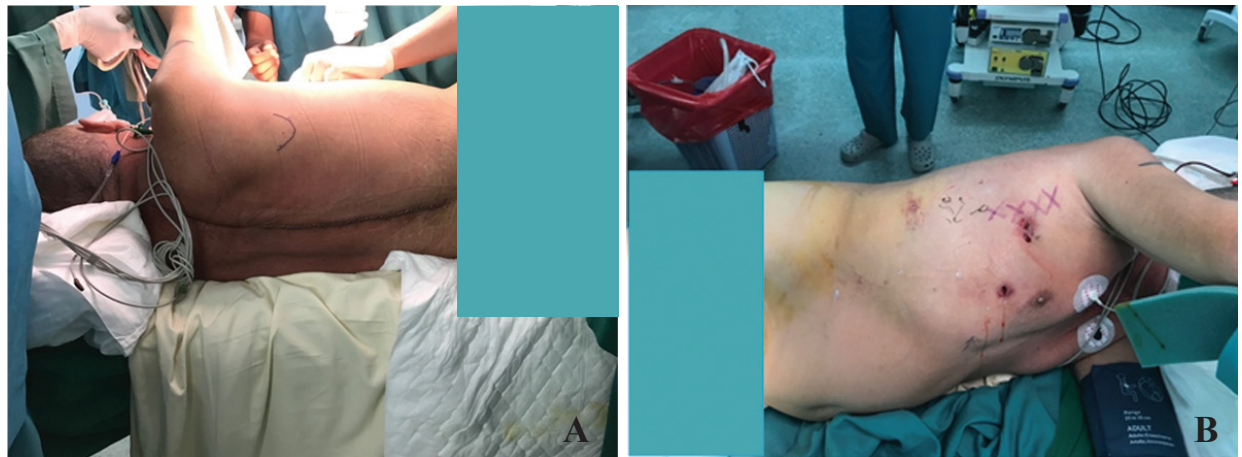
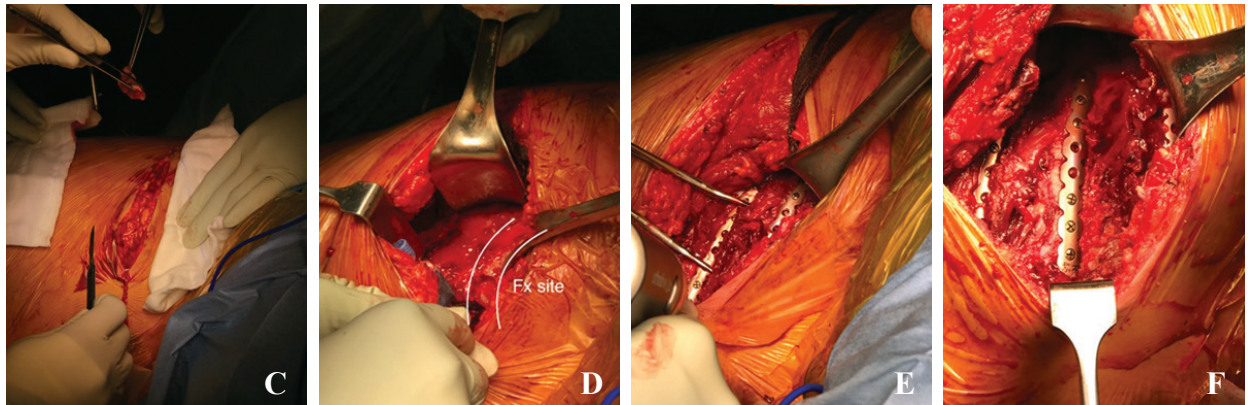


Figure 2A-B: show lateral decubitus position (2A) and ultrasound landmark for rib 3rd- 6th (2B).



2C: Shows anterolateral approach in oblique fashion (same line with anterolateral rib cage)

2D: Shows subperiosteal elevated serratus anterior muscle from the rib

2E: Shows direct reduction

2F: Shows applied matrix rib plate

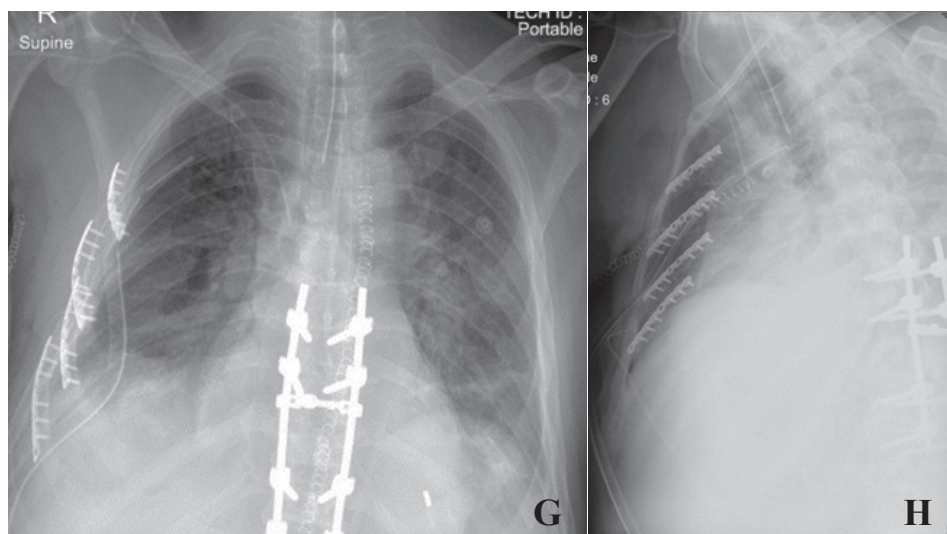


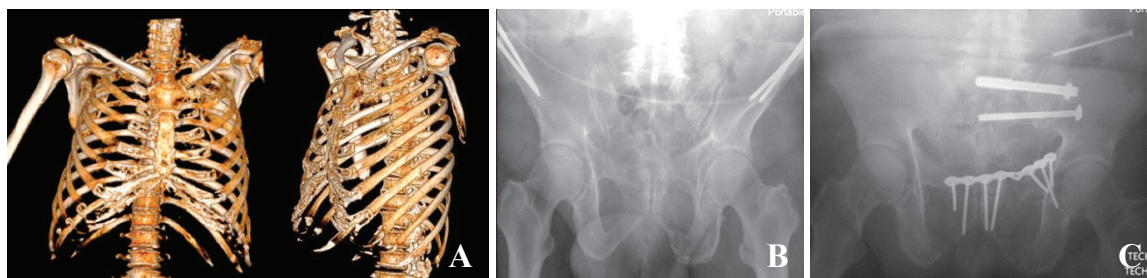Figure 2G-H: Show post-operation x-rays after fixation 3rd - 6th rib

Case # 2

A male aged 82 years old, had a car accident and was sent first to another hospital. He had hypovolemic shock (blood pressure 70/40 mmHg) and remained conscious (GCS E3V1M5) then he was intubated and fluid resuscitation was administered. He had cardiac arrest and underwent CPR for 15 minutes. He was referred to our center after stabilization, intubated with an endotracheal tube and ICD. From the secondary survey, he had head injury, fractures of the left 2nd - 7th ribs with pneumothorax (Figure 3A), pelvic fracture (lateral compression II) and blood pressure was still borderline. He was sent to the operating room for pelvic stabilization with an external fixator and embolization superior gluteal artery (Figure 3B). After the surgery, his vital signs were stable and he was put on the ventilator for full support in CMV mode. A week after his surgery, his ventilation had improved, he was able to use CPAP mode and he then underwent ORIF pelvic fracture (Figure 3C). Then, 3 days after definite fixation of pelvic fracture, the endotracheal tube was extubated. Due to

pain during breathing of left chest wall and inadequate breathing, 4 days after he had been extubated he was re-intubated with the endotracheal tube again with pressure support mode. The team decided to perform ORIF to his left rib due to being ventilator dependent and in uncontrolled pain with displaced fracture of ribs (2 weeks after his injury). Operative planning of fixation of left 5th - 7th ribs used ultrasound to locate skin incision before operation (Figure 3D). With an anterolateral approach, and subperiosteal elevation of serratus anterior muscle then exposed to fracture site, reduction was done by direct reduction, three universal plate 8 holes were used and fixed with three locking screws on each side of the fracture (Figure 3E - H).

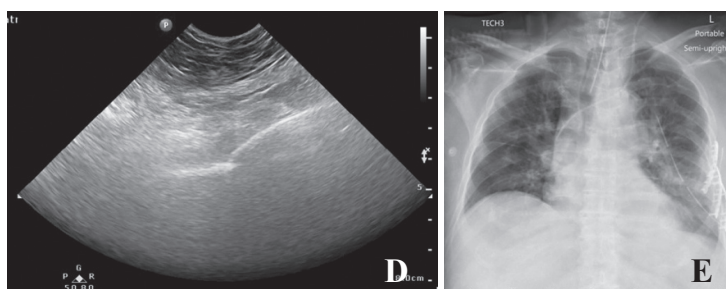
After rib fixation, on the 1st post-operative day, the patient was weaned off the ventilator with T-piece, FiO₂ 0.4 and on the 5th day after rib fixation he was extubated and had spontaneous breathing with O₂ support. On the 6th day after the operation he was transferred back to Germany with O₂ cannula support.



3A: CT 3D reconstruction showed fracture left rib 2nd - 7th

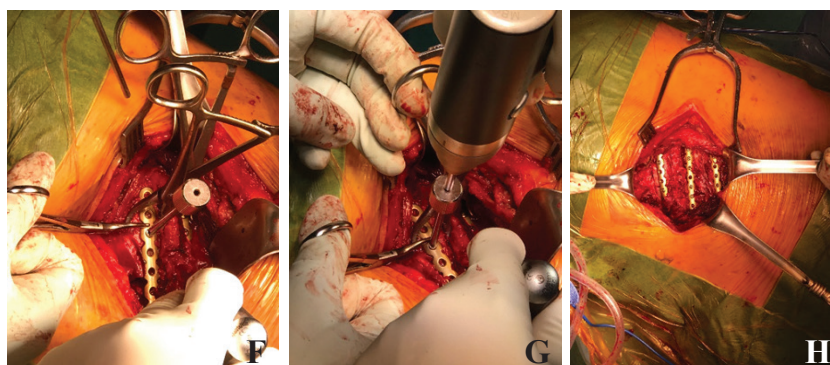
3B: pelvic fracture after external fixator and embolization

3C: after ORIF pelvic fracture



3D: Ultrasound landmark 5th - 7th rib before operation

3E: Post op x-ray after fixation operation



3F-H: reduction and fixation 5th - 7th rib

Case #3

A male aged 74 years old, had a car accident and was sent to a nearby local hospital. Once he was stabilized, he was then referred to our center. It was diagnosed with left 2nd - 7th ribs fracture with flail chest and multiple right 2nd - 7th ribs fractures with bilateral hemopneumothorax. The team initially treated ICD on both sides, fracture sternum, moderate head injury ($E_3V_T M_6$), closed fracture isolated left tibia, closed fracture right clavicle (Figure 4). At first, he sustained ventilator support with CMV mode, PEEP 5 cmH₂O, FiO₂ 0.65 on admission. He had severe pain on both sides of the chest wall, and on the 3rd day after injury he underwent intercostal steroid injection for controlled pain. Although his clinical condition improved he was still unable to move or ambulate properly from the bed due to chest wall pain both sides. On the 7th day of admission, he used ventilator in pressure support 12 cmH₂O, CPAP 10 cmH₂O, FiO₂ 0.3 but still had pain at both chest walls. He was operated and toilet bronchoscopy was applied, with chest wash out due to clot of hemothorax and secretion obstruction. A small amount of blood clot was found, and a mucous plug in right lower lung. On the 9th day, he was still using the ventilator in pressure support mode and still had pain on both chest walls and moderate lung secretion. On the 10th day he underwent rib fracture fixation for both sides due to marked displacement of ribs fracture and uncontrolled pain. The team operated with left decubitus position to fix anterolateral site of right 3rd-5th ribs first with anterolateral approach. The 4th rib was directly

reduced and fixed with 8 - holes anatomical plate. Subsequently, the 3rd rib was exposed. As the fracture location of the 3rd rib underneath the scapula was inaccessible for plate and screw fixation, the authors stabilized the 3rd rib by using Vicryl 2-0 tied to the 4th rib as a buddy splint stabilization (Figure 4A). Then the right 5th rib was reduced and fixed with 8-holes anatomical plate and 3 locking screws on each side of the fracture (Figure 4B). Afterwards, the patient was turned to right lateral decubitus to fix left 4th - 7th ribs through anterolateral approach. Due to segmental fracture, a 17 - holes anatomical plate was fixed to left 6th - 7th ribs with 10 and 8 locking screws respectively. Then 4th - 5th ribs were reduced and fixed with universal plate with 3 locking screws on each side of the fracture (Figure 4C).

On the 2nd post-operative day, the patient was on a ventilator in pressure support mode, 8 cmH₂O, PEEP 5 cmH₂O, FiO₂ 0.3. On the 3rd post-operative day, he was weaned off the ventilator with T-piece FiO₂ 0.3 and extubated on the 4th day after the operation. He developed acute cholecystitis during admission and underwent percutaneous cholecystostomy drainage, his clinical condition improved subsequently. After he was clinically stable, without fever, we operated with a plate and screws on his left tibia (Figure 4E). For the clavicle fracture we treated this conservatively with an arm sling. He was transferred to the ward to continue rehabilitation. He was discharged 3 months after injury.

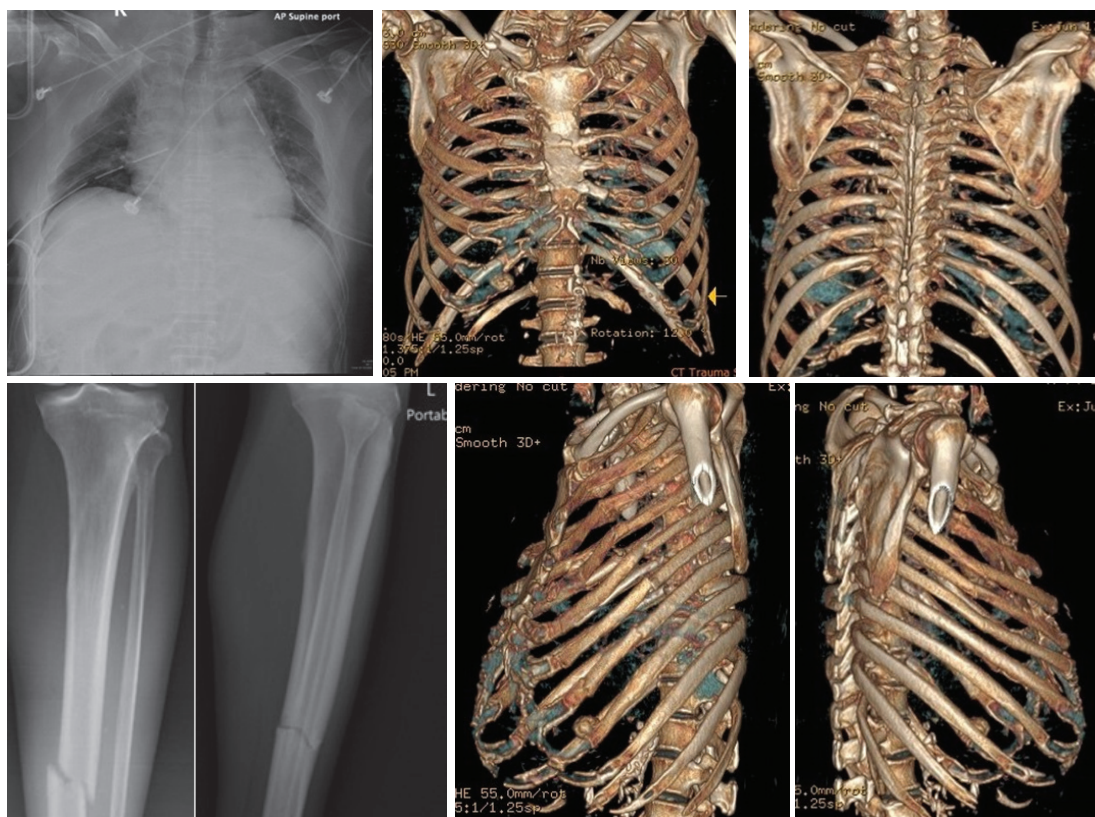
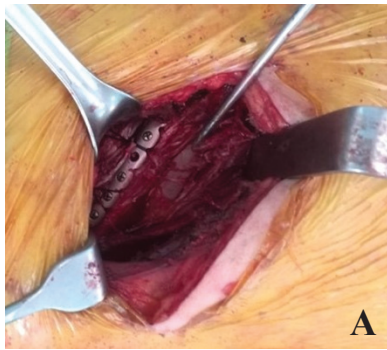
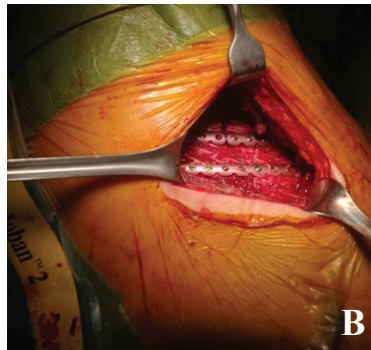

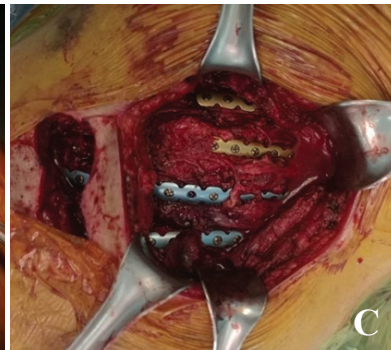Figure 4



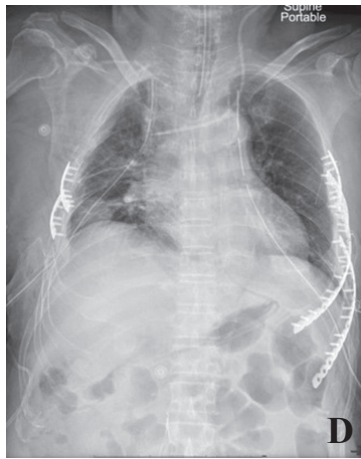4A: After fixation right 4th rib, vicryl suture right 3rd rib to right 4th rib as buddy splint



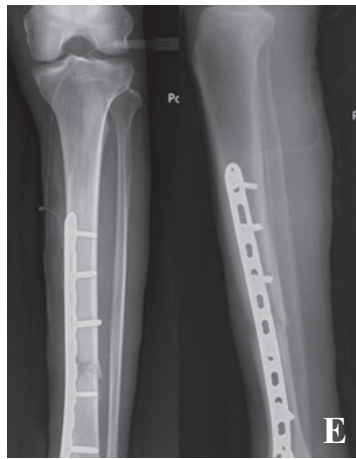4B: After fixation right 5th rib



4C: After fixation left 4th - 7th rib



4D: Post-operative x-ray



4E: After ORIF left tibia

Table 1: summarized information of all cases

Data	Case 1	Case 2	Case 3
Age	55	82	74
Gender	Male	Male	Male
Diagnosis	Fracture Rt 2 nd -11 th ribs with flail chest	Fracture Lt 2 nd - 7 th ribs	Fracture Lt 2 nd - 7 th ribs with flail chest
Indication for surgery	Flail chest with ventilator dependent	Ventilator dependent with uncontrolled pain and displaced fracture	Flail chest and ventilator dependent
Timing to surgery (Day after injury)	10 th	14 th	10 th
Number of rib fixation	Rt 3 rd - 6 th ribs	Lt 5 th - 7 th ribs	Rt 3 rd - 5 th ribs Lt 4 th - 7 th ribs
Post op ventilation mode			
Day1	PCV	T-piece	Pressure support
Day2	SIMV	T-piece	Pressure support
Day3	CPAP	T-piece	T-piece
Day4	CPAP	T-piece	Extubation
Extubate endotracheal tube (day after rib fixation)	refer back with ET tube at day 9 th	5 th	4 th
Post op pulmonary infection	No	No	No
Surgical wound infection	No	No	No

PCV= pressure control ventilation, SIMV= synchronized intermittent mechanical ventilation, CPAP = continuous positive airway pressure

Discussion

Multiple rib fractures and flail chest are common among patients sustaining blunt trauma. Due to the function of the rib cage providing the mechanical support for the respiratory system and to protect intrathoracic organs, multiple rib fractures or flail chest can compromise the respiratory system which results in inadequate breathing, poor ventilation, reduces tidal volume, and can lead to severe pain when breathing and also pulmonary contusion. These problems can lead to a prolonged ICU stay, prolonged intubation period, and a greater need of ventilator support.

Conservative treatment with analgesic medication, ventilator support, and pulmonary toilet is the standard of care.^{6,7,10} However, in some patients, especially in flail chest injury, there is a paradoxical movement of the chest wall leading to mechanical failure of the bony structure of rib cage resulting in respiratory failure. Open reduction and internal fixation is an option in selected cases to improve mechanical structure for respiration.

The advantage of rib fixation was shown in many systematic and meta-analysis reviews as detailed by Reinier B. Beks, et al.⁷ They suggested that rib fixation for flail chest could reduce morbidity compared to non-operative treatment. Furthermore, patients who underwent rib fixation had a shorter length of stay in the ICU, shorter duration of mechanical ventilation and were diagnosed with a lower pneumonia rate.

In a study by Silvana F Marasco, et al.,¹ a prospective randomized controlled trial was conducted to compare ORIF rib with mechanical ventilation management in flail chest patients. The result revealed that the patients in the operated group had a significantly shorter ICU stay and fewer requirements for noninvasive ventilation after extubation.

In addition, Hafiz J Iqbal, et al.,¹¹ also reported on the early surgical stabilization in multiple rib fracture patients. They concluded that early surgical stabilization has a shorter ICU stay and lower incidence of pneumonia. Most of the literatures about rib fracture fixation reported the advantage of a shorter ICU stay, shorter intubation period, fewer pulmonary infections and shorter duration of mechanical ventilation in flail chest patients. However, in multiple rib fracture without flail chest there is insufficient data to support the advantage of operative fixation. Despite operative fixation in multiple rib fracture or flail chest having some advantages, the operation still poses some risks including surgical exposure, iatrogenic pleural injury, infection or implant failure. We have to choose

the proper patients who fulfill the criteria for being suitable candidates for rib fixation, as in our algorithm aiming to identify the patients who will receive the most benefit from fixation. In multiple rib fracture, the number of fixed ribs was at the discretion of the surgeon, and depended on anatomical boundaries and the possibility to regain stability of the chest wall during respiration.^{6,7} The suitability of a fixed fracture rib depends on several factors such as surgical exposure, fracture site and degree of displacement. Anterior and lateral rib fractures were preferentially fixed over posterior rib fractures, due to more reliable fixation and easier access compared with posterior rib fractures.¹ In flail chest, usually addressed by fixing 1 fracture per rib, converting a flail segment to simple fractured ribs is enough.¹ In this report, we did not fix all of the rib fractures but we chose the most displaced and unstable ribs fracture segments with anterolateral approach to anterior or anterolateral rib cage with an easy to access fracture site. In one skin incision (one window) we can expose and fix 3-4 ribs per window.

In our report, with 1 skin incision (one window) we fixed only 3-4 ribs in a multiple rib fracture and fixed at least 1 fracture in flail chest injury. This was sufficient to stabilize the fracture segment, improve patient's ventilation and reduce pain. All of three cases in this report had satisfactory outcomes without complications. However, to fully validate the technique and the outcome shown in these reports, further study with more cases is required.

Limitation: To gain further insight of the outcomes, more examinations with more cases are required to fully understand the benefits and risks of rib fracture fixation.

Conclusion

The main findings from the three patients demonstrated that rib fracture fixation improved the quality of breathing which resulted in a short intubation period. The patients showed no sign of post-operative pulmonary infection. With the findings, the team suggested that rib fracture fixation is an alternative choice of treatment for patients with flail chest.

Disclosure: The authors declare no potential conflicts of interest and there was no source of external funding for this study.

Acknowledgement

The authors would like to thank Bangkok Health Research Center for research assistance.

References

1. Marasco SF, Davies AR, Cooper J, et al. Prospective Randomized Controlled Trial of Operative Rib Fixation in Traumatic Flail Chest. *J Am Coll Surg* 2013;
2. Michelitsch C, Acklin YP, Ha'ßsig G, et al. Operative Stabilization of Chest Wall Trauma: Single-Center Report of Initial Management and Long-Term Outcome. *World J Surg* 2018;

3. Pharaon KS, Marasco S, Mayberry J. Rib Fractures, Flail Chest, and Pulmonary Contusion. *Curr Trauma Rep* 2015;1:237-42.
4. Engel C, Krieg JC, Madey SM, et al. Operative Chest Wall Fixation with Osteosynthesis Plates. *J Trauma*. 2005;58:181-6.
5. Lafferty PM, Anavian J, Will RE, et al. Operative Treatment of Chest Wall Injuries: Indications, Technique, and Outcomes. *J Bone Joint Surg Am* 2011;93:97-110.
6. Beks Rb, de Jong MB, Houwert RM, et al. Long-term follow-up after rib fixation for flail chest and multiple rib fractures. *Eur J Trauma Emergency Surg* 2018;
7. Beks RB, Peek J, de Jong MB, et al. Fixation of flail chest or multiple rib fractures: current evidence and how to proceed. A systematic review and meta-analysis. *Eur J Trauma Emergency Surg* 2018;
8. Slobogean GP, MacPherson CA, Sun T, et al. Surgical Fixation vs Nonoperative Management of Flail Chest: A Meta-Analysis. *J Am Coll Surg* 2013;216:302-11.
9. Bemelman M, de Kruijf MW, Mark van Baal M, et al. Rib Fractures: To Fix or Not to Fix? An Evidence-Based Algorithm. *Korean J Thorac Cardiovasc Surg* 2017;50:229-34.
10. Wijffels MME, Hagenaars T, Latifi D, et al. Early results after operatively versus non-operatively treated flail chest: a retrospective study focusing on outcome and complications. *Eur J Trauma Emergency Surg* 2018;
11. Iqbal HJ, Alsousou J, Shah S, et al. Early Surgical Stabilization of Complex Chest Wall Injuries Improves Short-Term Patient Outcomes. *J Bone Joint Surg Am* 2018;100:1298-308.