Case Report

Concurrent Interdigitating Dendritic Cell Sarcoma and T-Lymphoblastic Leukemia/Lymphoma: A Case Report and Review of Literature

Chutima Pinnark Surintrspanont[1] ; Shanop Shuangshoti[2] ; Pongsada Prasonguppatum[1] ; Kittikrai Kraikaew[3] ; Panathut Klaewvatee[3] ; Narittee Sukswai[4]

Chutima Pinnark Surintrspanont

[1] Institute of Pathology, Department of Medical Services, Ministry of Public Health, Bangkok, Thailand
[2] Department of Pathology and Chulalongkorn GenePRO Center, Faculty of Medicine, Chulalongkorn University, Bangkok, Thailand
[3] Chularat 9 Airport Hospital, Bangkok, Thailand
[4] Precision Pathology of Neoplasia Research Group, Department of Pathology, Faculty of Medicine, Chulalongkorn University, Bangkok, Thailand

*Address Correspondence to author:
Chutima Pinnark Surintrspanont, MD
Institute of Pathology,
Department of Medical Services,
Ministry of Public Health,
2/2 Phayathai Road, Thung Phaya Thai,
Ratchathewi, Bangkok 10400 Thailand
email: memay.mamie@gmail.com

Received: November 20, 2024
Revision received: December 6, 2024
Accepted after revision: February 10, 2025
BKK Med J 2025;21(1): 61-65.
DOI: 10.31524/bkkmedj.2025.12.002
www.bangkokmedjournal.com

Abstract

Interdigitating dendritic cell sarcoma (IDCS) is a rare tumor that arises from classical dendritic cells within the bone marrow. Typically, it is observed subsequent to the development of low-grade B-cell lymphoma. However, there has been only one documented case following T-acute lymphoblastic leukemia/lymphoblastic lymphoma (T-ALL/LBL). The presence of these synchronous tumors with a clonal relationship, indicating a potential transdifferentiation of the tumor. We report a case of concurrent IDCS and T-ALL/LBL. A middle-aged male presented with painful cervical node enlargement. Biopsy revealed parafollicular proliferation of pleomorphic epithelioid cells expressing S100. Immunohistochemistry excluded alternative dendritic cell tumors and melanoma, confirming IDCS diagnosis. Four months post-treatment, generalized lymphadenopathy emerged, revealing small immature T cells clustering amidst IDCS cells in both lymph nodes and bone marrow. Genetic analysis identified *NRAS* mutation in IDCS but not in T-ALL/LBL, whereas TCR gene rearrangement was detected in T-ALL/LBL but absent in IDCS. Unfortunately, we lack conclusive evidence regarding the clonal relationship or transdifferentiation between these two tumors. They could be unrelated and incidentally develop at the same time.

Keywords: interdigitating dendritic cell sarcoma, T-lymphoblastic leukemia/lymphoma

Interdigitating dendritic cell sarcoma (IDCS) is an extremely rare malignant histiocytic neoplasm.[1] Only 100 cases have been documented in English literature over past 35 years (1978-2012).[2]

The pathogenesis of IDCS remains unknown. Usually, interdigitating dendritic cells (IDCs) are found in the thymus, spleen, and lymph nodes and originate from classic or myeloid dendritic cells (cDCs).[3] The prognosis is grim, with a median survival of approximately 9 months.[2] Currently, there is no established standard treatment. Most IDCS cases exhibit a germline configuration of immunoglobulin (Ig) and T-cell receptor (TCR) genes.[1] Reports indicate associations between IDCS and other hematologic malignancies, notably low-grade B-cell lymphoma. Clonal relationships inferred from Ig gene rearrangements and shared chromosomal abnormalities between these tumors suggest potential transdifferentiation from preceding lymphoma cells.[1,4]

Several studies have documented a clonal association between T-lymphoblastic leukemia/lymphoma (T-ALL/LBL) and histiocytic neoplasms, including Langerhans cell histiocytosis and histiocytic sarcoma.[5,6] However, since 1993, there has been only one documented case report describing synchronous IDCS, which is clonally related and presents after T-ALL/LBL.[7] Presented here is a case report detailing IDCS preceding concurrent T-lymphoblastic leukemia/lymphoma (T-ALL/LBL), along with a review of relevant literature.

Case report

A 42-year-old Thai male, without any pre-existing medical conditions, presented with painful, rapidly enlarging right cervical lymph nodes over the

course of one month (solely affecting cervical lymph nodes), without hepatosplenomegaly. The largest lymph node measured 5.5 cm in its greatest dimension. The excisional biopsy was performed and showed infiltration of sinuses by histiocytic cells with paracortical area involvement, small vessels proliferation and focal hemorrhage seen. The atypical cells possess mild to moderately pleomorphic nuclei, irregular nuclear membrane with nuclear grooves, band-like and horse-shoe shape, small visible nucleoli, fine chromatin and moderate amount of amphophilic cytoplasm. Some plasma cells are observed. Eosinophils are not predominant. Germinal centers and follicular architectures remain intact. (Figure 1 and 2)

Immunohistochemical study reveals that the tumor cells are reactive with S100 (cytoplasmic with focal nuclear staining) and CD4; weakly reactive with CD45, CD31 and Fascin; but non-reactive with CD3, CD20, CD30, CD138, CD68 (PGM1), CD163, CD21, CD23, CD1a, Langerin, HMB45, MelanA, SOX10, ERG, HHV8, MPO and EBER. Ki67 displays a low proliferative index, about 10%. BRAF V600E shows equivocal staining with high background stain. The diagnosis is interdigitating dendritic cell sarcoma.

Following localized radiation therapy, the patient initially exhibited a favorable response. However, four months later, bilateral groin node enlargement was observed. Subsequent chest and abdomen CT scans revealed multiple intra-thoracic and intra-abdominal enlarged lymph nodes.

Sections of the core tissue from the groin node show atypical small to medium lymphoid cells aggregating in the background of histiocytoid cells with vague granulomatous pattern. The atypical lymphoid cells are reactive with CD34, TdT, CD3 (weak cytoplasmic stain), CD5 (dim, 90% of blasts), CD7, CD79a (focal and faint), CD117 (focally, 20% of blasts) and MPO (dot granular cytoplasmic, less than 10%); but non-reactive with CD4, CD8, CD20, CD2, TCR-betaF1, CD19, PAX5, CD13, CD14 and CD163. The histiocytoid cells are reactive with S100 and weakly with CD4. No AFB or fungus is identified with Ziehl-Neelsen (acid fast) and GMS stains. (Figure 3)

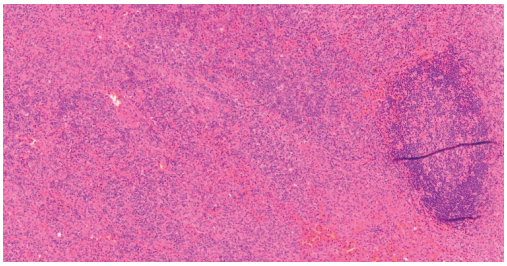

Figure 1: The tumor cells infiltrate in the paracortex of the lymph node with lymphoid follicle sparing (H&E, 200x)

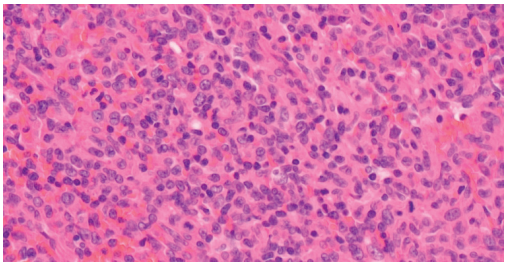

Figure 2: The tumor cells possess mildly pleomorphic round to oval nuclei, irregular nuclear membrane with nuclear indentation and moderate amount of eosinophilic cytoplasm. Mitoses are occasionally seen. (H&E, 630x)

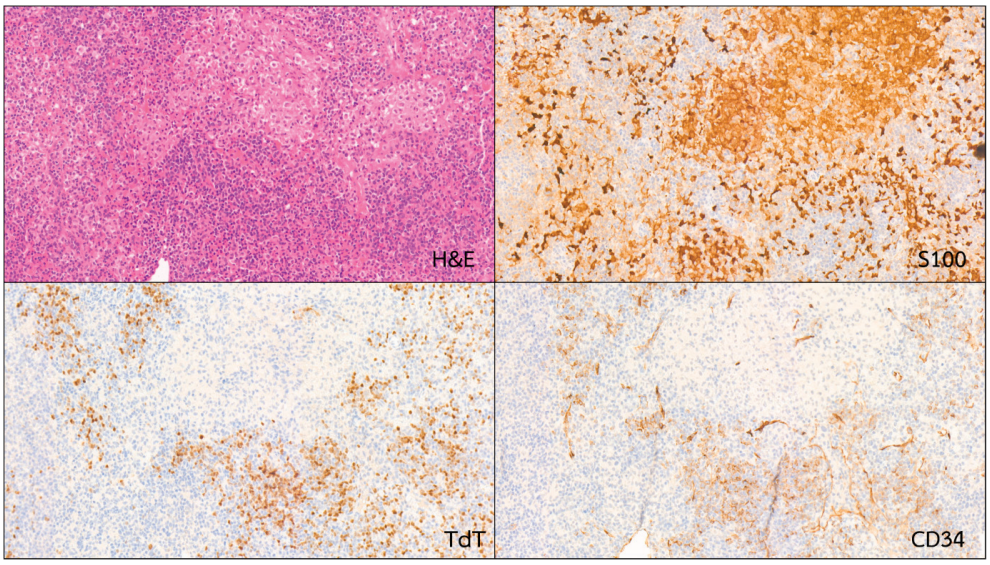

Figure 3: The histology of groin node biopsy and bone marrow is the same as shown in the H&E. There are aggregates of epithelioid histiocytes forming vague granuloma in the upper center part. These cells are reactive with S100 suggesting the presence of residual IDCS. In the right lower part, there are small lymphoid cell infiltrates. These cells have fine chromatin and scant cytoplasm. They are reactive with TdT and CD34, which is consistent with leukemic cell infiltration.

ISSN 2287-0237 (online)/ 2228-9674 (print)

The bone marrow biopsy showed atypical interstitial aggregates of mononuclear cells admixed with clusters of histiocytoid cells forming vague granuloma. The immunohistochemical study demonstrates the similar pattern as in the groin node.

The patient received CHOP regimen. One week later, he developed febrile neutropenia and worsening pneumonia. His family requested palliative treatment and the patient passed away later at home.

Further molecular study of these two tumors have been processed. The IDCS at cervical lymph node has *NRAS G13D* mutation (using Idylla™ *NRAS-BRAF-EGFR-S492R* mutation Assay) without *BRAF* mutation or TCR gene rearrangement (using PCR for TCR beta and TCR gamma gene rearrangement). While T-ALL/LBL at the groin node (tumor isolation by microdissection) shows TCR gene rearrangement without *KRAS or NRAS* mutation.

Discussion

This patient presented with a common presentation of IDCS (painful cervical mass).[8] The histologic morphology of the tumor is epithelioid cells with some kidney-or horseshoe-shaped nuclei that is not a typical pattern described in the World Health Organization (WHO) classification revised 4th edition which is spindle cells proliferating in whorl pattern.[1] Despite the discordance of the cell morphology described in the WHO, the immunohistochemical studies are definitely consistent with the IDCS by excluding all other differential diagnoses (histiocytic sarcoma, Langerhan cell sarcoma, follicular dendritic cell sarcoma, indeterminate cell sarcoma and malignant melanoma). Similar to this case, the epithelioid or pleomorphic morphology of the tumor cells in IDCS has been reported in a case series in 2018 after launching of the WHO 2017 version.[9] The latest version of WHO classification of hematolymphoid tumors 5th edition 2022 has already included the pleomorphic epithelioid cell morphology as a cell morphology of this tumor.[10]

Most of the reported cases and case series demonstrate the relation of IDCS and low-grade B-cell lymphoma with clonal relationship.[4] Few IDCSs have been reported to clonally relate to T-cell neoplasm.[5,11] There is only one report of Horschowski et al.[7] in 1993 described a child with T-acute lymphoblastic leukemia (T-ALL) that was complicated with IDCS 5 months later while receiving treatment for T-ALL. Genetic study was done and found beta-TCR gene rearrangement in IDCS. He concluded that this supported the presence of ability of pluripotent precursor cells that could develop multi-lineage tumor cells or hybrid tumor. According to the definition in Dorland's medical dictionary, synchronous tumors have interval period within 6 months, while metachronous tumors have interval time more than 6 months.[12] That reported case demonstrated synchronously occurrence of the two tumors.

Saygin[2] reviewed the report of Horschowski and concluded that the patient was early T-precursor lymphoblastic leukemia (ETP-ALL). This new entity is first described in 2009 and was put in the WHO revised 2017.[13] ETP-ALL is a subset of T-acute lymphoblastic leukemia/lymphoblastic lymphoma (T-ALL/LBL). It develops from precursor lymphoid cells that migrate to the thymus without irreversibly committed to T cell lineage and have ability to change to be myeloid or dendritic cells. They express CD7 and one or more myeloid or stem cell markers e.g. CD34, CD117, HLA-DR, CD13, CD33, CD11b, and CD65; but MPO should be negative.[1] Some studies show clonal relationship between Langerhans cell histiocytosis and T-ALL/LBL[5,11]

Our case showed dot and granular cytoplasmic staining of MPO; but less than 10%. According to the threshold in WHO 5th edition,[14] this neoplasm should be T-ALL/LBL. Early T-precursor lymphoblastic leukemia/lymphoma (ETP-ALL) is less likely, because the tumor cells express CD5 more than 75%, though dim, and express CD117 less than 25%.[15] Mixed-phenotype acute leukemia, T/myeloid (MPAL-T/M) is also less possible due to lack of significant expression of MPO and monocytic markers. However, we need to exclude the MPAL with defined genetic alterations according to the latest version of WHO classification.[14]

Flow cytometry of the marrow will give us more information about protein expression of the tumor cells. Unfortunately, there is no flow cytometry performed in this case.

According to the clinical course of our case, IDCS occurred before the presence of T-ALL/LBL 4 months later after radiation therapy, unlike the previous reported case of Horschowski. By the definition, they are still synchronous tumors (within 6 months' duration).[12] However, we do not know what tumor developed first at the beginning. They might simultaneously occur in the bone marrow, but IDCS cells moved outside faster and resided in the same area as normal interdigitating dendritic cells did which was parafollicular area of the lymphoid tissue.[16] While the neoplastic T lymphoblasts synchronously proliferate, but they still stay in the bone marrow.

Regarding to the treatment for IDCS in this patient, which is localized radiation therapy, before T-ALL occurred 4 months later, this also raised the possibility of therapy-related ALL (t-ALL). Acute myeloid leukemia (AML) or myeloid neoplasm post cytotoxic therapy (DNA-damaging cytotoxic chemotherapy and/or large-field radiation therapy, usually within 10 years post treatment) is well defined in the latest version of WHO classification,[17] but not for t-ALL. In 2019, Saygin et al.[18] studied t-ALL and suggested that it is a distinct entity owing to poorer outcome than de novo ALL (dn-ALL) and ALL with prior malignancy (no therapy received) (pm-ALL). In this study, they did not clearly define the extent of the therapy like those in AML. They did mention that t-ALL occurred in a shorter time interval from the prior malignancy comparing to dn-ALL and pm-ALL.

Nevertheless, we tried to search for the relationship between these two tumors using PCR for TCR gene rearrangement and commonly abnormal genes to prove the transdifferentiation hypothesis, we found no common genetic abnormality or any clonal relationship. The *NRAS* mutation may be deleted while it transdifferentiates to T-ALL/LBL. Our instruments are not sensitive enough. Lastly, they may have possibly occurred separately. And the T-ALL could be t-ALL as per Saygin's suggestion.

Analysis of transcription factors and high-density array comparative genomic hybridization2 might help in identifying the genetic similarity and difference of both tumors. We may have more information to infer the relation of these tumors. Unfortunately, we do not have these facilities currently.

Conclusion

IDCS is a rare and aggressive tumor that requires close monitoring. It should be considered in the differential diagnosis when encountering atypical spindle-shaped to epithelioid histiocyte-like cells. Histiocytic tumors are often found synchronously or metachronously with other hematologic malignancies, highlighting the high plasticity of these tumors and their association with hematologic disorders. Recurrent masses during or after treatment may not always represent the same tumor. Further molecular and genetic studies on transdifferentiation are essential, even if evidence for such phenomena is not always present.

Disclosure of conflict of interest

The author has no conflict of interest.

Ethics approval statement

The project was approved by an institutional ethics committee.

Acknowledgment

This case report is financially supported by Institute of Pathology, Medical Services, Bangkok, Thailand.

References

1. Weiss LM, Chan JKC. Interdigitating dendritic cell sarcoma. Histiocytic and dendritic cell neoplasms, WHO classification of tumours of haematopoietic and lymphoid tissues, Revised 4th Edition, Volume 2. 2017;2:475-6.
2. Saygin C, Uzunaslan D, Ozguroglu M, et al. Dendritic cell sarcoma: a pooled analysis including 462 cases with presentation of our case series. *Crit Rev Oncol Hematol*. 2013;88(2):253-71. doi: 10.1016/j.critrevonc.2013.05.006.
3. Johansson B, Ingvarsson S, Björck P, et al. Human interdigitating dendritic cells induce isotype switching and IL-13-dependent IgM production in CD40-activated naive B cells. *J Immunol.* 2000 Feb 15;164(4):1847-54. doi: 10.4049/jimmunol.164.4.1847.
4. Fraser CR, Wang W, Gomez M, et al. Transformation of chronic lymphocytic leukemia/small lymphocytic lymphoma to interdigitating dendritic cell sarcoma: evidence for transdifferentiation of the lymphoma clone. *Am J Clin Pathol.* 2009;132(6):928-39. doi: 10.1309/AJCPWQ0I0DGXBMHO.
5. Feldman AL, Berthold F, Arceci RJ, et al. Clonal relationship between precursor T-lymphoblastic leukemia/lymphoma and langerhans-cell histiocytosis. *Lancet Oncol*. 2005;6(6):435-7. doi: 10.1016/S1470-2045(05)70211-4.
6. Feldman AL, Minniti C, Santi M, et al. Histiocytic sarcoma after acute lymphoblastic leukemia: a common clonal origin. *Lancet Oncol.* 2004;5(4):248-50. doi: 10.1016/S1470-2045(04)01428-7.
7. Horschowski N, Guitard AM, Arnoux I, et al. Interdigitating cell sarcoma: occurrence during incomplete remission of a lymphoblastic lymphoma. *Pathol Biol (Paris).* 1993;41(3):255-9.
8. Luis MJS, Samir D, Diego CR, et al. "Interdigitating Dendritic Cell Sarcoma." *Atlas of Genetics and Cytogenetics in Oncology and Haematology,* December 2018.
9. Xue T, Jiang XN, Wang WG, et al. Interdigitating dendritic cell sarcoma: clinicopathologic study of 8 cases with review of the literature. *Ann Diagn Pathol.* 2018;34:155-160. doi: 10.1016/j.anndiagpath.2018.03.008.
10. Li X, Calaminici M, Wang H ,et al. Interdigitating Dendritic Cell Sarcoma. *WHO Classification of Tumours Editorial Board. Haematolymphoid Tumours,* International Agency for Research on Cancer, 2022. Web. 14 May 2023. (WHO classification of tumours series, 5th ed.; vol.11). Available from: https://tumourclassification.iarc.who.int/chaptercontent/63/104.
11. Rodig SJ, Payne EG, Degar BA, et al. "Aggressive Langerhans cell histiocytosis following T-ALL: clonally related neoplasms with persistent expression of constitutively active NOTCH1. *Am J Hematol*. 2008;83(2):116-21. doi: 10.1002/ajh.21044.
12. Newman DorlandW. Dorland's Illustrated Medical Dictionary. 2018.
13. Sin CF, Man PM. Early T-cell precursor acute lymphoblastic leukemia. *Front Oncol.* 2021;11:750789. doi: 10.3389/fonc.2021.750789. eCollection 2021.
14. Xiao W, Chen W, Tembhare P, et al. "Mixed-Phenotype Acute Leukaemia, T/Myeloid." *WHO Classification of Tumours Editorial Board. Haematolymphoid Tumours*, International Agency for Research on Cancer, 2022. Web. 19 March 2024. (WHO classification of tumours series, 5th ed.; vol.11). Available from: https://tumourclassification.iarc.who.int/chaptercontent/63/81.
15. Czader M, Molina TJ, Choi JK, et al. Early T-precursor lymphoblastic leukaemia/lymphoma. *WHO Classification of Tumours Editorial Board. Haematolymphoid Tumours*, International Agency for Research on Cancer, 2022. Web. 12 November 2024. (WHO classification of tumours series, 5th ed.; vol.11). Available from: https://tumourclassification.iarc.who.int/chaptercontent/63/205

16. Wang Y, Xiang Y, Xin VW, et al. Dendritic cell biology and its role in tumor immunotherapy. *J Hematol Oncol.* 2020;13(1):107. doi: 10.1186/s13045-020-00939-6.
17. Kanagal-Shamanna R, Germing U, Bejar R, et al. Myeloid neoplasm post cytotoxic therapy. *WHO Classification of Tumours Editorial Board. Haematolymphoid Tumours*, International Agency for Research on Cancer, 2022. Web. 28 January 2025. (WHO classification of tumours series, 5th ed.; vol.11). Available from: https://tumourclassification.iarc.who.int/chaptercontent/63/27
18. Saygin C, Kishtagari A, Cassaday RD, et al. Therapy-related acute lymphoblastic leukemia is a distinct entity with adverse genetic features and clinical outcomes. *Blood Adv.* 2019;3(24):4228-4237. doi: 10.1182/bloodadvances.2019000925.