

บทความพิเศษ

Laparoscopy : Direct Trocar Insertion Without Pneumoperitoneum

Kittinan Thaisriwong M.D.*

Abstract This paper presents the technique of directly inserting the laparoscopic trocar without establishing a previous pneumoperitoneum. The technique is fully described. The advantages of this method are discussed. It is consider to be an easy and safer means of performing laparoscopy.

Introduction

A successful pneumoperitoneum before trocar entry has generally been regarded as the first step in laparoscopy.¹ The rationale for an adequate pneumoperitoneum is that it provides a buffer space between the insertion site and pelvic or abdominal viscera. However, recent experience with laparoscopy has revealed significant complications associated with Veress needle insufflation, such as gas embolism, subcutaneous or subfascial insufflation, failed pneumoperitoneum with resultant failed laparoscopy, and bowel or visceral insufflation.^{2,3}

Direct trocar insertion technique was described by Dingfelder as both a safe and effective method of laparoscopy.⁴ He believed that abdominal wall elevation was the key safety factor independent of technique, and this

was best accomplished without establishing a pneumoperitoneum. Copeland et al described the use of this technique in over 2000 unselected cases, with only three major complications.⁵ Byron et al preferred the direct insertion technique for trocar placement because it had fewer minor complications and required less operating time.⁶ This technique has become increasingly popular in many institutions in the United States.

At Prapokklao Hospital, Chanthaburi, almost all laparoscopies done still are conventional method with prior pneumoperitoneum before trocar entry. The author abandoned the conventional technique and has performed the direct trocar insertion without pneumoperitoneum for over ten years. The purpose of the present report is to describe the detailed procedure and

* Department of Obstetrics and Gynecology, Prapokklao Hospital, Chanthaburi Province

reassure the safety of this technique at the time of laparoscopy.

Materials and Methods

After the institution of general anesthesia, the patient was prepped and draped in the usual fashion in a low lithotomy, slight Trendelenberg position with the thighs flexed at a 45° angle from the body plane. Anatomical landmarks including aortic pulse, iliac spines, and uterine fundus were recognized. A 1.5–2.0 cm. horizontal or vertical infraumbilical incision was then made. The lower abdomen was grasped with left hand midway between the umbilicus and pubic symphysis, and elevated. With elevation of the abdominal wall, a 10 mm. Surgiport Disposable Surgical Trocar and Sleeve was slowly inserted directly in the incision using a twisting motion with the tip aimed toward the uterus. As the trocar passed through the peritoneum, the shield locked in place over the tip of the trocar and a small ‘click’ could be heard as well as felt. The laparoscope was

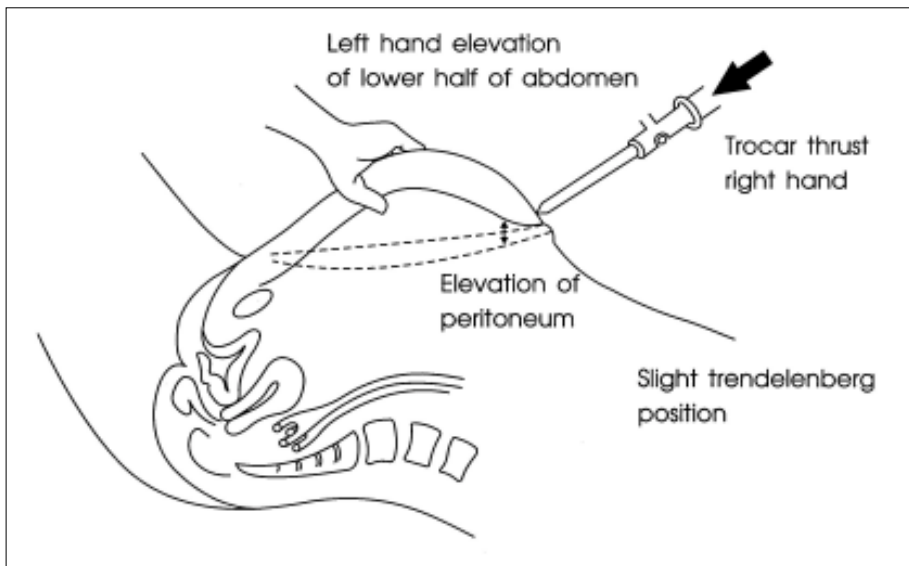
then introduced with the light on, the proper intra-abdominal placement was confirmed. Once the entry was confirmed, then pneumoperitoneum was established while the operative procedure or exploration was continued.

Technique of Direct Trocar Insertion

Because meticulous attention to a few key surgical points is critical, this procedure is described in detail.

Relaxation : Adequate general anesthesia is essential to assure lower abdominal wall relaxation for proper elevation. It is also preferred for obese women because elevation of a heavy abdominal wall can require painful pulling on the skin by two surgeons to achieve the proper anatomical relationships.

Sharp Trocar : Sharpness of the pyramidal trocar should be checked before every entry by this technique, because the force necessary to insert a dull trocar will bring the abdominal wall back down onto the bowel and vessels at the time of entry.



Adequate Incision : A horizontal or vertical infraumbilical incision was appropriately made wide enough (1.5–2.0 cm.) for the trocar to be inserted without undue resistance from the skin, so that the trocar passed through the fascia and the peritoneum more easily.

Technique of elevation of the abdomen : Because most surgeons stand on the patient's left side, the surgeon's left hand should grasp the patient's lower abdomen at a point midway between the umbilicus and the pubic symphysis. Elevation of the abdominal wall at this point will elevate the umbilicus slightly and put it on a stretch, so that trocar entry can be directed simultaneously 1) toward the true pelvis (or the uterus), 2) away from the bowels and the large vessels, and 3) at right angles to the skin. These three simultaneous objectives should be thought of at the time of all entries. The left hand also provide countertraction for the trocar entry by tenting the lower abdomen in a 45° angle. These relationships are shown in the figure below.

Results

Between January 1991 and December 2004, the author performed 84 laparoscopies using this technique. One third of the laparoscopies were done for tubal sterilization, while the others were done for diagnosis in cases of infertility, pelvic pain and for treatments of endometriosis, ovarian cysts and ectopic pregnancies.

There were no complications related to trocar entry or insufflation. All cases were done with single attempt. In no case was there failure to insert the trocar properly into the abdomen or

to create a pneumoperitoneum. There were no bowel, bladder or vessel perforations.

Discussion

Direct trocar insertion without previous pneumoperitoneum has been shown before to be a safe and effective method associated with fewer complications.^{4,5,6} Minor complications were significantly more frequent in the Veress needle group.⁸ This was generally because of insufficient depth achieved with placement of the Veress needle, resulting in preperitoneal insufflation and subsequent placement of the laparoscope more difficult, or even failed. Direct trocar insertion results in a decrease in operating time because it eliminates the time-consuming step of assuring proper placement of the Veress needle, as well as creation of a pneumoperitoneum before laparoscope placement. Byron JW, et al compared the two techniques and found that Veress needle preinsufflation technique spent approximately four minutes more.⁸ Another advantage of direct trocar insertion is the ability to visualize the pelvis directly from the outset of the procedure which means that less gas is used for insufflation and proper laparoscope entry is confirmed.

The author has used this technique since 1991 and become rapidly familiar with it. Elevating the abdominal wall and inserting the trocar before insufflation makes it easier to feel each layer during trocar insertion than it is when the abdomen is distended with gas. Abdominal distention secondary to insufflation necessitates increased force to achieve trocar

insertion.^{4,7} In the author's opinion, this method is easier, safer and more effective than the standard Veress needle technique. No complications have occurred so far, but the reported cases may be too small. The autor believes that this technique, when taught under supervision and practiced on appropriate abdomens not previously operated upon, is clinically more secure than the standard Veress needle insufflation technique. In the final analysis, the emphasis in relaxed abdomen, sharp instruments, adequate incision, anatomic knowledge and proper elevation of the abdomen demanded by this technique is no more than the sound surgical principles required for any technique of surgery.

References

1. Gunning JE. The history of laparoscopy. J Reprod Med 1974;12:222.
2. Mintz JP. Risks and prophylaxis in laparoscopy, a survey of 100,000 cases. J Reprod Med 1977;18:269.
3. Cunanan RG Jr, Courey NG, Lippes J. Complications of laparoscopic tubal sterilization. Obstet Gynecol 1980;55:501.
4. Dingfelder JR. Direct laparoscope trocar insertion without prior pneumoperitoneum. J Reprod Med 1978;21:45-7.
5. Copeland C, Wing R, and Hulka JF. Direct trocar insertion at laparoscopy : An evaluation. Obstet Gynecol 1983;62:656-9.
6. Byron JW, Fujiyoshi CA , and Miyazawa K. Evaluation of the direct trocar insertion technique at laparoscopy. Obstet Gynecol 1989;74:423-5.
7. Jarelt JC. Laparoscopy: Direct trocar insertion without pneumoperitoneum. Obstet Gynecol 1990;75:725-7.
8. Byron JW, Markenson G, and Miyazawa K. A randomized comparison of veress needle and direct trocar inseetion for laparoscopy. Surg Gynecol Obstet 1993;177:259-62.