

Aesthetic Outcomes of Intra-Umbilical Incision vs Infra-Umbilical Incision in Postpartum Tubal Sterilization: A Randomized Controlled Trial

Watcharin Chirdchim¹, Preecha Wanichsetakul², Jayanton Patumanond³

¹ Department of Obstetrics and Gynecology, Phrapokklao Hospital, Chanthaburi, Thailand

² Department of Obstetrics and Gynecology, Faculty of Medicine, Thammasat University, Pathum Thani, Thailand

³ Department of Clinical Epidemiology and Clinical Statistics, Faculty of Medicine, Thammasat University, Pathum Thani, Thailand

Background: An incision inside the umbilicus is popular used in single port surgery intra-umbilical skin incision surgeries have been proven efficient and safe. When compared to infra-umbilical skin incisions, an incision wound was invisible after the operation. Why not use intra-umbilical skin incision in postpartum tubal sterilization.

Objective: To compare aesthetic scores of an incision wound, surgical time and complications in postpartum sterilization under infra-umbilical and intra-umbilical skin incision.

Methods: This was a randomized controlled trial conducted in Prapokkhlo Hospital, Chanthaburi, Thailand. Patients (n = 58) with informed consents were randomly assigned to one of the two skin incision techniques for postpartum sterilization (n = 29 for each arm). Surgical times were recorded. Both the patients and an independent physician made wound aesthetic assessments one week after the operation using the Patient and Observer Scar Assessment Scores (POSAS), which compares the wound to the nearby skin. *T* tests and exact probability statistical tests were used for statistical analysis.

Results: The surgeon's POSAS scores in intra-umbilical incisions were significantly closer to normal skin than those in infra-umbilical incisions (6.8 ± 1.5 vs 12.5 ± 5.0 ; $P < .001$). A similar finding was observed for patient POSAS scores (6.5 ± 1.2 vs 15.4 ± 5.0 ; $P < .001$). The operation times were also shorter (9.1 ± 2.8 vs 11.8 ± 4.7 minutes; $P = .009$). Neither intra-abdominal injuries nor wound infections were observed.

Conclusions: Postpartum sterilization using intra-umbilical skin incision was more efficient in regard to aesthetic concerns and operation time.

Keywords: Aesthetics, Postpartum, Skin Incision, Sterilization, Umbilicus

Rama Med J: doi:10.33165/rmj.2019.42.1.109492

Received: March 20, 2018 Revised: June 20, 2018 Accepted: January 11, 2019

Corresponding Author:

Watcharin Chirdchim
Department of Obstetrics
and Gynecology,
Phrapokklao Hospital,
38 Reabnearn Road,
Tambon Wat Mai,
Amphoe Muang Chanthaburi,
Chanthaburi 22000, Thailand.
Telephone: +66 3931 9666
Fax: +66 3931 1511
E-mail: watcharin.ch@cpird.in.th





Introduction

Postpartum sterilization is an efficient method for permanent contraception with relatively low failure rates. In typical clinical practice, surgeons make a transverse skin incision just below the umbilicus (infra-umbilicus). Making the skin incision inside an umbilicus (intra-umbilicus) is not regularly practiced, due to old-time beliefs that it is difficult, unclean and might increase the risk of infection.^{1,2}

Recent medical technology has introduced abdominal surgery under a scope, particularly a single port surgery, in which an incision is made inside the umbilicus. Such single port, intra-umbilical skin incision surgeries have been proven efficient and safe. When compared to infra-umbilical skin incisions, an incision wound was invisible after the operation and an increase in wound infection has not been reported.^{3,4}

Anatomically, the overlying skin inside the umbilicus is thinner than that of normal skin, infra-umbilicus. In pregnant women, the base of an umbilicus usually raises as the uterus enlarges, allowing easier access for an intra-umbilical skin incision. Intra-umbilical approaches could be performed in less time, with much more ease and less bleeding. In addition to aesthetic concerns, skin incisions made through the umbilicus might be equally or even more efficient.

The aim of the present study was to compare satisfaction scores concerning aesthetic perceptions and operative times between intra-umbilical and infra-umbilical skin incisions in postpartum sterilization.

Methods

Design, Settings, and Subjects

This was a therapeutic efficacy study with a randomized controlled trial. The study was conducted between February and August 2016, in Prapokkhlo Hospital, Chanthaburi, Thailand. The hospital is a referral hospital located in the vicinity of the eastern seaboard of

Thailand. It is a university-affiliated hospital, performing approximately two thousand deliveries and two to three hundred postpartum sterilizations annually. Eligible patients were postpartum women (both normal and assisted deliveries) who requested and were scheduled for sterilization (n = 90). Those with obstetric complications (severe hypertension, eclampsia, and A2 gestational diabetes mellitus), those with umbilical skin lesions, umbilical hernia, HIV, and previous surgical scars on the abdomen and those expected to be operated on later than 72 hours after delivery were excluded from randomization (n = 32) (Figure 1).

Randomization, Concealment, and Blinding

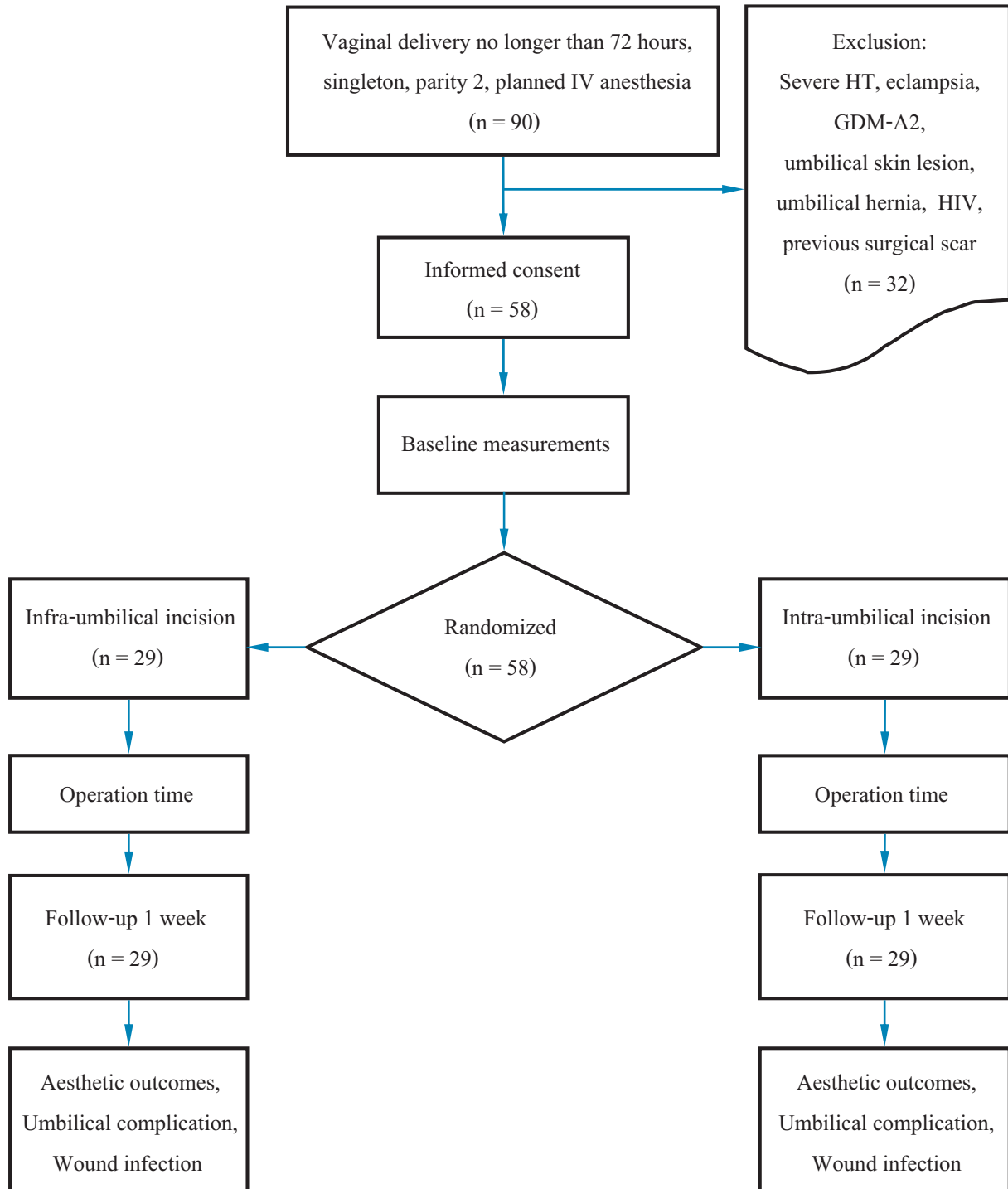
After patients were informed of the trial and informed consents were signed, participants (n = 58) were randomly assigned to one of the two skin incision techniques, either infra-umbilical (n = 29) or intra-umbilical (n = 29). The randomization scheme was prepared with sealed opaque envelopes. Concealments were kept until skin incision was ready, and one assisting nurse was assigned to open the envelope for each case.

Operative Procedure

All operations were performed by an experience staff, under intravenous anesthesia within 6 to 72 hours after delivery. Patients were operated on supine position. The skin was scrubbed with Hibiscrub[®] and painted with 2% chlorhexidine in alcohol, respectively. After draping with sterilized cloth, skin incisions were made with a surgical scalpel blade number 24.

For infra-umbilical skin incisions, the horizontal skin incision was made below the lower rim of the umbilicus and just above the uterine fundal height. The incision length was smaller than the diameter of the umbilicus. For intra-umbilical skin incisions, the rim of the umbilicus was raised with Allis tissue forceps, and the vertical incision was made from the upper to lower rim of the umbilicus.

Figure 1. Participants Enrollment



After entering the abdominal cavity, the bed was in the Trendelenburg position or tilted head down. Tubal ligation was performed using a routine procedure until the skin was closed. Skin suturing was performed using subcuticular sutures in both groups.

Clinical Endpoints

Primary endpoints were the aesthetic features of the wounds, evaluated by both an independent surgeon and the patients one week after surgery using the Patient and Observer Scar Assessment Scores (POSAS), scaled from 6 to 60. Secondary endpoints were operative times and wound infections and/or complications, also reported at one week after surgery.

Study Size Estimations and Statistical Analysis

To detect a statistically significant increase in POSAS from 6.0 ± 3.0 in intra-umbilical incisions to 9.0 ± 4.5 in infra-umbilical incisions (an expectation based on a pilot study performed earlier), given a significance level of 0.05 and a power of 0.80 using a one-sided test,

the estimated number of patients per arm was 21. To compensate for 30% of incomplete data, we decided to recruit 29 subjects per arm.

Statistical comparisons of POSAS and operative times were analyzed with *t* tests, and infections and/or complications were analyzed with exact probability tests.

Ethical Considerations

The study was approved by the Research in Human Ethical Committee of Chanthaburi Province, document ID number CTIREC-061 and was registered in the Thai Clinical Trial Registration (TCTR-20160426007). Informed consents were signed by all patients. Previously, we had conducted another clinical trial with the same design but totally different sample.²¹

Results

Patients in the two intervention groups were similar in age, body mass index (BMI), and time from delivery to surgery (Table 1).

Table 1. Baseline Characteristics

Characteristic	Mean \pm SD		P Value
	Intra-umbilical (n = 29)	Infra-umbilical (n = 29)	
Age, y	29.8 \pm 5.5	29.4 \pm 4.4	.77
Body weight, kg	67.4 \pm 12.3	64.3 \pm 11.3	.33
Height, cm	158.1 \pm 6.4	159.9 \pm 6.0	.28
BMI, kg/m ²	26.9 \pm 4.5	25.1 \pm 4.0	.11
Delivery to operation time, h	39.8 \pm 20.9	38.6 \pm 23.5	.83
Parity, n (%)			
\leq 2	12 (41.4)	15 (51.7)	.59
$>$ 2	17 (58.6)	14 (48.3)	

Abbreviations: BMI, body mass index; SD, standard deviation.

Anesthetic regimens used via intravenous anesthesia were also similar, including the dosage administered (Table 2). The operative times were shorter for intra-umbilicus than for infra-umbilicus incisions in all operative procedures: initial skin incision through entering the abdominal cavity (9.1 ± 2.8 vs 11.8 ± 4.7 minutes; $P = .009$), entering the abdominal cavity through skin closure (0.6 ± 0.6 vs 1.0 ± 0.6 minutes; $P = .021$) and the total operation time (8.5 ± 2.6 vs 10.8 ± 4.5 ; $P = .025$) (Table 2).

Focusing on aesthetic satisfaction one week after

surgery, as assessed by POSAS scores (scaling 6 - 60), higher scores were assigned for infra-umbilicus than for intra-umbilicus, both from the independent surgeon in charge (6.8 ± 1.5 vs 12.5 ± 5.0 ; $P < .001$) and from the patients (6.5 ± 1.2 vs 15.4 ± 5.0 ; $P < .001$), including the overall opinion scores (scaling 0 - 10) provided by the patients (1.1 ± 0.1 vs 3.5 ± 1.0 ; $P < .001$). There were no postoperative umbilical complications nor wound infections (Table 3). No other complications were observed nor reported by the patients on follow-up.

Table 2. Operative Characteristics

Characteristic	Mean \pm SD		P Value
	Intra-umbilical (n = 29)	Infra-umbilical (n = 29)	
Anesthetic regimens, n (%)			
3 drugs	10 (34.5)	13 (44.8)	.59
4 drugs	19 (65.5)	16 (55.2)	
Anesthetic doses, mg			
Midazolam (n = 24, 25)	1.4 ± 0.4	1.5 ± 0.3	.30
Morphine (n = 23, 25)	8.8 ± 1.7	11.2 ± 10.3	.28
Ketamine (n = 28, 25)	75.0 ± 29.8	80.0 ± 27.1	.52
Fentanyl (n = 5, 4)	75.0 ± 8.7	95.0 ± 10.0	.01
Propofol (n = 25, 25)	102.8 ± 52.7	133.6 ± 110.7	.21
Operation time, min			
Total	9.1 ± 2.8	11.8 ± 4.7	.009
Skin incision to abdominal cavity	0.6 ± 0.6	1.0 ± 0.6	.02
Abdominal cavity to closing skin	8.5 ± 2.6	10.8 ± 4.5	.02

Abbreviation: SD, standard deviation.

Table 3. Aesthetic Outcomes and Complications

Outcome	Mean \pm SD		P Value
	Intra-umbilical (n = 29)	Infra-umbilical (n = 29)	
POSAS scores			
Surgeon (scale 6 - 60)	6.8 ± 1.5	12.5 ± 5.0	< .001
Patient (scale 6 - 60)	6.5 ± 1.2	15.4 ± 5.0	< .001
Patients overall opinion to scars*	1.1 ± 0.3	3.5 ± 1.0	< .001

Abbreviations: POSAS, patient and observer scar assessment scores; SD, standard deviation.

* Compared to normal skin (scale 1 - 10).

Discussion

It has been long perceived that operations involving an umbilicus are unclean. Therefore, postpartum sterilization has been performed using infra-umbilicus skin incisions.¹ Umbilical bases in pregnant women are usually raised up to the same level as the surrounding skin, or even protruded near term. The debates on uncleanliness of intra-umbilicus skin incision may be questionable. To avoid visibility of the wound after intra-umbilical skin incision, skin closure may be done by suturing only fascia and subcutaneous fat without any skin stitching.^{3, 5-8} Several intra-umbilical surgeries, involving intra-umbilicus skin opening, exist including umbilical hernia repairs and various laparoscopic operations in surgical or gynecological conditions particularly single port laparoscopic sterilization.²⁻¹⁰

Wound Infections

A study in laparoscopic operations of perforated appendicitis, after intra-umbilicus vs infra-umbilicus skin incisions, reported non-significant (0.6% vs 4.1%, respectively) wound infection rates³. There were no surgical site infections in our study.

Aesthetics

Earlier, in single port laparoscopic hysterectomy⁵ and oophorectomy after intra-umbilicus incision, patients graded satisfaction on the aesthetic appearance of the wound. Intra-umbilicus incisions for single port laparoscopic surgeries have become popular, partly due to greater patient satisfaction regarding aesthetics of the wounds and similar complication rates compared to infra-umbilicus incisions.³⁻⁸ However, earlier studies mostly focused on patient aesthetic concerns, as timing of the operation could not be controlled for various operations. Our study supported the findings that patients were more satisfied with their surgical wounds after intra-umbilicus incision. The surgeon in charge was also more satisfied with the appearance of the wounds.

Other Complications

The fact that subcutaneous skin adhesions were reported in 21% of patients with subsequent laparoscopic surgeries¹¹ raised debates on the benefits of umbilicus incisions. In practice, an open entry technique, a direct optical entry or an alternative site for primary port insertion may be used if such adhesions were encountered.¹²⁻¹⁴

Umbilical incision hernia may be considered as one of the delayed complications. The reported incidence varies among studies. The incidence of port-site hernia in single port laparoscopic surgeries was 2.9% on average, varying based on types of surgery, age and patient body weight.¹⁵

Port-site hernia from single port laparoscopic surgery vs conventional laparoscopic surgery in cholecystectomy was 9.6% vs 5.3%, respectively, which was non-significant.¹⁶ However, we found no reports of incision hernia post-sterilization.

Operation Times

The average operation time for postpartum sterilization in Thailand was 11 - 15 minutes.^{17, 18} In the present study, the operation time for intra-umbilicus incision was significantly shorter than for infra-umbilicus incision. The present study may be among the earliest to compare the two skin incision sites for postpartum sterilization, in which aesthetic satisfaction was assessed from both surgeons and patients. The study strictly controlled nothing-per-oral 8 hours before surgery to avoid the risk of aspiration.^{19, 20} One study limitation may be that only one surgeon was responsible for the surgeries, however this was done to avoid bias due to different skill levels between surgeons. Another limitation may be that only operations under intravenous anesthesia were studied.

To reduce bias, the researchers conducted another study²¹ by replacing the operating surgeon with six-year medical students and controlling the anesthetic confounder by using spinal anesthesia. The results showed that operative times in the intra-umbilical group were shorter



(24.9 ± 6.3 vs 41.6 ± 13.2 minutes; $P < .001$). Patient scar assessment scores in intra-umbilical incisions were significantly closer to normal skin than infra-umbilical incision scores (7.8 ± 1.6 vs 14.5 ± 2.4 ; $P < .001$).

umbilical skin incisions. Both the patients and the physicians expressed greater satisfaction with the aesthetic appearance of the wounds, and the procedure required shorter operative times.

Conclusions

An intra-umbilical skin incision for postpartum sterilization may be applied in routine practice as an alternative method to the usual practice of infra-

Acknowledgments

We would like to particularly thank you for the all the mothers who participated in our study.

References

1. Rock JA, Jones HW. *Te Linde's Operative Gynecology*. 10th ed. Philadelphia, PA: Lippincott Williams & Wilkins; 2008.
2. Park SY, Kim KH, Yuk JS, Ji HY, Lee JH. Skin closure methods after single port laparoscopic surgery: a randomized clinical trial. *Eur J Obstet Gynecol Reprod Biol*. 2015;189:8-12. doi:10.1016/j.ejogrb.2015.03.014.
3. Lee JS, Hong TH, Kim JG. A comparison of the periumbilical incision and the intraumbilical incision in laparoscopic appendectomy. *J Korean Surg Soc*. 2012;83(6):360-366. doi:10.4174/jkss.2012.83.6.360.
4. Phongnarisorn C, Chinthakanan O. Transumbilical single-incision laparoscopic hysterectomy with conventional laparoscopic instruments in patients with symptomatic leiomyoma and/or adenomyosis. *Arch Gynecol Obstet*. 2011;284(4):893-900. doi:10.1007/s00404-010-1770-0.
5. Arslan S, Korkut E. The intra-umbilical approach in umbilical hernia. *Eurasian J Med*. 2014;46(1):32-35. doi:10.5152/eajm.2014.06.
6. Angioni S, Pontis A, Sedda F, et al. Single-port versus conventional multiport access prophylactic laparoscopic bilateral salpingo-oophorectomy in high-risk patients for ovarian cancer: a comparison of surgical outcomes. *Oncol Targets Ther*. 2015;8:1575-1580. doi:10.2147/OTT.S82570.
7. Matsui Y, Satoi S, Hirooka S, Kon M. Simple suturing technique for umbilical dimple wound after single-incision laparoscopic surgery. *J Am Coll Surg*. 2015;221(4):e61-e63. doi:10.1016/j.jamcollsurg.2015.07.006.
8. Song T, Cho J, Kim TJ, et al. Cosmetic outcomes of laparoendoscopic single-site hysterectomy compared with multi-port surgery: randomized controlled trial. *J Minim Invasive Gynecol*. 2013;20(4):460-467. doi:10.1016/j.jmig.2013.01.010.
9. Draaijers LJ, Tempelman FR, Botman YA, et al. The patient and observer scar assessment scale: a reliable and feasible tool for scar evaluation. *Plast Reconstr Surg*. 2004;113(7):1960-1965.
10. Wheelless CR. A rapid inexpensive and effective method of surgical sterilization by laparoscopy. *J Reprod Med*. 1969;3:65-69.
11. Sepilian V, Ku L, Wong H, Liu CY, Phelps JY. Prevalence of infraumbilical adhesions in women with previous laparoscopy. *JSLS*. 2007;11:41-44.
12. Tinelli A, Malvasi A, Guido M, et al. Laparoscopy entry in patients with previous abdominal and pelvic surgery. *Surg Innov*. 2011;18(3):201-205. doi:10.1177/1553350610393989.
13. Parker J, Reid G, Wong F. Microlaparoscopic left upper quadrant entry in patients at high risk of periumbilical adhesions. *Aust N Z J Obstet Gynaecol*. 1999;39(1):88-92. doi:10.1111/j.1479-828X.1999.tb03452.x.



14. Levrant SG, Bieber EJ, Barnes RB. Anterior abdominal wall adhesions after laparotomy or laparoscopy. *J Am Assoc Gynecol Laparosc.* 1997;4(3):353-356.
15. Agaba EA, Rainville H, Ikedilo O, Vemulapali P. Incidence of port-site incisional hernia after single-incision laparoscopic surgery. *JSLS.* 2014;18(2):204-210. doi:10.4293/108680813X13693422518317.
16. Krajinovic K, Koeberlein C, Germer CT, Reibetanz J. The incidence of trocar site hernia after single-port laparoscopic cholecystectomy-A single center analysis and literature review. *J Laparoendosc Adv Surg Tech A.* 2016;26(7):536-539. doi:10.1089/lap.2015.0596.
17. Satyapan S, Varakamin S, Suwannus P, Chalapati S, Onthuam Y, Dusitsin N. Postpartum tubal ligation by nurse--midwives in Thailand: a field trial. *Stud Fam Plann.* 1983;14(4):115-118.
18. Dusitsin N, Chalapati S, Varakamin S, Boonsiri B, Ningsanon P, Gray RH. Post-partum tubal ligation by nurse-midwives and doctors in Thailand. *Lancet.* 1980;1(8169):638-639.
19. Bucklin BA. Postpartum tubal ligation: timing and other anesthetic considerations. *Clin Obstet Gynecol.* 2003;46(3):657-666.
20. Bucklin BA, Smith CV. Postpartum tubal ligation: safety, timing, and other implications for anesthesia. *Anesth Analg.* 1999;89(5):1269-1274.
21. Chirdchim W, Wanichsetakul P, Suwannarurk K, Patumanond J. Intraoperative outcomes of intra-umbilical incision vs infra-umbilical incision in post-partum tubal sterilization: a randomized control trial study. *Ramathibodi Medical Journal.* 2017;40:29-37.

ความพึงพอใจและความสวยงามของแผลผ่าตัดทำหมันระหว่างการลงแผลในสะดือและใต้สะดือ: การศึกษาแบบกลุ่ม

วัชรินทร์ เจริญดี¹, ปรีชา วาณิชเศรษฐกุล², ชัยนัครธร ปทุมมานนท์³

¹ กลุ่มงานสูติรีเวช โรงพยาบาลพระปกเกล้า จันทบุรี ประเทศไทย

² ภาควิชาสูติศาสตร์-นรีเวชวิทยา คณะแพทยศาสตร์ มหาวิทยาลัยธรรมศาสตร์ ปทุมธานี ประเทศไทย

³ ภาควิชาโรคผิวหนังวิทยาคลินิก คณะแพทยศาสตร์ มหาวิทยาลัยธรรมศาสตร์ ปทุมธานี ประเทศไทย

บทนำ: การลงแผลผ่าตัดในสะดือ (Intra-umbilical) มักนิยมทำในการผ่าตัดส่องกล้องแบบแผลเดียว หลังแผลหายมองไม่เห็นแผลเมื่อเทียบกับการลงแผลใต้สะดือ (Infra-umbilical) แต่การทำหมันหลังคลอดยังคงลงแผลใต้สะดือ เหตุใดจึงไม่ลงแผลทำหมันหลังคลอดในสะดือเช่นเดียวกับการทำผ่าตัดส่องกล้องแผลเดียว

วัตถุประสงค์: เพื่อเปรียบเทียบความพึงพอใจ ความสวยงาม และภาวะแทรกซ้อนในการทำหมันหลังคลอดระหว่างการลงแผลในสะดือและใต้สะดือ

วิธีการศึกษา: การศึกษาแบบกลุ่มโดยการจัดผู้ป่วยเข้ากลุ่มด้วยวิธีการสุ่มที่แผนกสูติรีเวช โรงพยาบาลพระปกเกล้า จังหวัดจันทบุรี ในผู้ป่วยที่ต้องการทำหมันหลังคลอด จำนวน 58 คน โดยการลงแผลผ่าตัดสองวิธี คือ ในสะดือ จำนวน 29 คน และใต้สะดือ จำนวน 29 การผ่าตัดทำโดยสูติรีแพทย์เพียงหนึ่งท่าน โดยใช้การระงับปวดแบบฉีดยาสลบเข้าหลอดเลือด จากนั้นประเมินความพึงพอใจและความสวยงามของแผลผ่าตัดด้วย Patient and observer scar assessment score (POSAS) การวิเคราะห์ข้อมูลเพื่อเปรียบเทียบความแตกต่างของแผลผ่าตัดกับผิวหนังบริเวณที่ปกติที่ 1 สัปดาห์หลังคลอดโดยตัวผู้ป่วยเองและแพทย์ที่ไม่ใช่ผู้ผ่าตัด ใช้สถิติ *t* test และการเปรียบเทียบการติดเชื้อของแผลผ่าตัดที่ 1 สัปดาห์ และภาวะแทรกซ้อนของการผ่าตัด 1 สัปดาห์หลังคลอด ใช้สถิติ Exact probability test

ผลการศึกษา: ความพึงพอใจและความสวยงามที่ประเมินโดยแพทย์ที่ไม่ใช่ผู้ผ่าตัดเมื่อเปรียบเทียบกับผิวหนังบริเวณที่ปกติพบว่า การผ่าตัดลงแผลในสะดือดีกว่าอย่างมีนัยสำคัญ (6.8 ± 1.5 และ 12.5 ± 5.0 ; $P < .001$) ซึ่งสอดคล้องกับการประเมินโดยผู้ป่วย (6.5 ± 1.2 และ 15.4 ± 5.0 ; $P < .001$)

สรุป: การทำหมันหลังคลอดโดยลงแผลในสะดือสามารถทำได้อย่างมีประสิทธิภาพรวมทั้งให้ผลความพึงพอใจและความสวยงามดีกว่าการลงแผลใต้สะดือ

คำสำคัญ: ความพึงพอใจ ความสวยงาม หลังคลอด แผลผ่าตัด ทำหมัน สะดือ

Rama Med J: doi:10.33165/rmj.2019.42.1.109492

Received: March 20, 2018 Revised: June 20, 2018 Accepted: January 11, 2019

Corresponding Author:

วัชรินทร์ เจริญดี

กลุ่มงานสูติรีเวช

โรงพยาบาลพระปกเกล้า

38 ถนนเลียบเนิน

ตำบลวัดใหม่ อำเภอเมือง

จันทบุรี 22000 ประเทศไทย

โทรศัพท์ +66 3931 9666

โทรสาร +66 3931 1511

อีเมล watcharin.ch@cpird.in.th

