Indocyanine Green Fluorescence-Guided Laparoscopic Management of Postcholecystectomy Mirizzi Syndrome Caused by a Retained Stone in the Gallbladder Remnant: A Case Report and Review of the Literature

Ativitch Asavachaisuvikom

Department of Surgery, Faculty of Medicine Ramathibodi Hospital, Mahidol University, Bangkok, Thailand

Citation: Asavachaisuvikom A. Indocyanine green fluorescence-guided laparoscopic management of postcholecystectomy Mirizzi syndrome caused by a retained stone in the gallbladder remnant: a case report and review of the literature. *Res Med J*. 20XX; XX(X):e284106. doi:10.33165/rmj.2028.e284106

Corresponding Author: ativitch.asa@mahidol.ac.th

Received: 9 August 2026
Revised: 3 November 2026
Accepted: 9 November 2026
Published Online: 12 November 2026

Copyright © 2026 by the Author(s). Licensee RMJ. This article is licensed under the Creative Commons Attribution (CC BY) License.

Abstract

Background: Mirizzi syndrome is an uncommon complication of gallstone disease characterized by extrinsic compression of the common hepatic duct or common bile duct due to an impacted stone in the cystic duct or gallbladder neck. It is caused by the inflammatory changes and distorted biliary anatomy associated with this condition. The reports describing the laparoscopic management of postcholecystectomy Mirizzi syndrome (PCMS) are limited; this study reports this case to highlight the diagnostic and operative challenges and the potential role of indocyanine green (ICG)-guided laparoscopy.

Case Presentation: A 64-year-old Thai male presented with a significant medical history of cholecystitis, having undergone an open cholecystectomy 30 years prior. He reported experiencing epigastric pain accompanied by fever over the past 3 days. Computed tomography of the upper abdomen demonstrated postpartial cholecystectomy Mirizzi syndrome, in conjunction with acute calculous cholecystitis. The patient was subsequently admitted for antibiotic therapy and underwent endoscopic retrograde cholangiopancreatography. The procedure identified a fistula from the gallbladder remnant to the mid common bile duct, Csendes classification III, and a biliary stent was appropriately inserted. Following this intervention, this patient was then scheduled for a laparoscopic remnant cholecystectomy. Indocyanine green (ICG) was administered before surgery to aid identification of the extrahepatic biliary anatomy. Intraoperative cholangiography and cholangioscopy were performed, with no postoperative bile leakage reported. At the 6-month follow-up, he was symptom-free with normal liver function tests.

Conclusions: PCMS from a retained stone in the gallbladder is an important differential diagnosis for recurrent biliary symptoms. ICG fluorescent cholangiography was used as an adjunct to anatomical assessment during laparoscopic reoperation; its role in similar cases requires further evaluation.

Keywords: Case report, Indocyanine green, Laparoscopic surgery, Mirizzi syndrome

Article in Press

Introduction

Postcholecystectomy Mirizzi syndrome (PCMS) is a rare condition that can occur after gallbladder removal, primarily due to retained or recurrent gallstones within a remnant of

the cystic duct or residual gallbladder tissue.[1-4] Currently, the standard treatment for Mirizzi syndrome is controversial. Due to the high conversion rate and significant risk of bile duct injury, open surgery is generally preferred over laparoscopic surgery.[5,6] Laparoscopic treatment of Mirizzi syndrome Csendes classification III was still limited.[7] Previous reports mention the benefit of indocyanine green (ICG) in difficult cholecystectomy in terms of shorter operative time.[8,9] This technique can enhance real-time visualization of the extrahepatic biliary structures, thereby helping to prevent bile duct injuries in complex cases.[10] This fluorescent imaging can enable a safe and precise laparoscopic removal of the retained stone and excision of the gallbladder remnant. This is a rare case report presenting the application of ICG guidance in laparoscopic surgery for PCMS, Csendes classification III.

Case Presentation

A 64-year-old Thai male presented with right upper quadrant pain and fever and was diagnosed with acute calculous cholecystitis and underwent an open cholecystectomy with an extended upper midline incision. After the surgery, he was free from biliary symptoms for 30 years. He experienced epigastric pain and fever for 3 days. In the emergency room, vital signs showed body temperature 38.2 °C, Pulse rate 110 bpm, and blood pressure 114/72 mmHg. Physical examination revealed mild icteric sclerae, tenderness in the epigastric region, with no guarding or rebound tenderness. Laboratory tests indicated a white blood cell count of 6890 cells/mm^3, total bilirubin level of 3.0 mg/dL, and direct bilirubin level of 1.1 mg/dL. Aspartate aminotransferase was 41 U/L, alanine aminotransferase was 34 U/L, alkaline phosphatase was 144 U/L, and lactate level was 3.6 mmol/L. A computed tomography (CT) scan of the upper abdomen showed changes consistent with a gallbladder remnant with a perilesional hyperdense lesion, as well as acute calculous cholecystitis. There was mild dilatation of the bilateral intrahepatic ducts and the common hepatic duct, suggesting possible Mirizzi syndrome, along with several calcified stones (Figure 1A and 1B). The gallbladder remnant showed diffuse wall thickening and perilesional fat stranding (Figure 1A).

This patient was diagnosis with acute remnant gallbladder cholecystitis grade II with acute cholangitis grade I with Mirizzi syndrome, as per the Tokyo guideline.[11,12] The patient was admitted for antibiotic treatment and underwent urgent endoscopic retrograde cholangiopancreatography (ERCP), which revealed a fistula between the gallbladder remnant involving two-thirds of the common hepatic duct with a filling defect into the common hepatic duct, defined as Mirizzi syndrome Csendes classification III.[13] Sphincterotomy was performed. A biliary plastic stent, pigtail 7 Fr, was then inserted. After the ERCP procedure, the patient's clinical condition improved, including the resolution of fever and a decrease in jaundice. After 4 weeks, the patient was scheduled for a laparoscopic remnant cholecystectomy with intraoperative cholangiogram. A fixed dose of 2.5 mg of ICG was administered intravenously 30 minutes before imaging. Near-infrared fluorescent imaging was performed using the KARL STORZ system. The port planning was performed as a conventional 4-port laparoscopic cholecystectomy, but the epigastric port was changed to a 10 mm port to use 10 mm instruments, including a 10 mm right-angle and a cholangioscopy.

During the procedure, after lysis of adhesions with a sharp cut and ultrasonic device, the common bile duct (CBD) was identified using an ICG fluorescent camera, which illuminated the CBD in bright green to help identify the landmark (Figure 2A and 2B). The intraoperative cholangiogram showed that the CBD was involved by fistula one-third

Article in Press

to two-thirds of its diameter, consistent with Mirizzi syndrome, Csendes classification III (Figure 3). The surgical team dissected the common bile duct, removed the stone, and performed intraoperative cholangioscopy, which showed no distal stricture caused by prolonged inflammation. The anterior part was dissected to one-third of the CBD diameter to remove the stone. The posterior wall of the gallbladder was left. The primary repair was performed using absorbable Vicryl 4-0 sutures at the CBD and the posterior wall of the gallbladder to perform choledochoplasty (Figure 4). The remnant of this patient's gallbladder was successfully removed and gallstone with a laparoscopic procedure. Total operative time was 280 minutes. Intraoperative blood loss was 100 mL. There was no conversion to open surgery. Following the surgery, a drain was placed. The drain output was serosanguineous fluid, approximately 20-30 mL, and was removed on postoperative day 3 after laboratory testing. The patient was discharged on postoperative day 4 and had an appointment 2 weeks after surgery. The pathological report was chronic cholecystitis; no malignancy was seen. The plastic stent was scheduled for removal with ERCP after 3 months of this surgery. The intraoperative cholangiogram showed no stricture at the common hepatic duct (Figure 5). This patient had no clinical signs of recurrent cholangitis or biliary stricture for 6 months after surgery.

Figure 1. Computed Tomography Scan of the Upper Abdomen

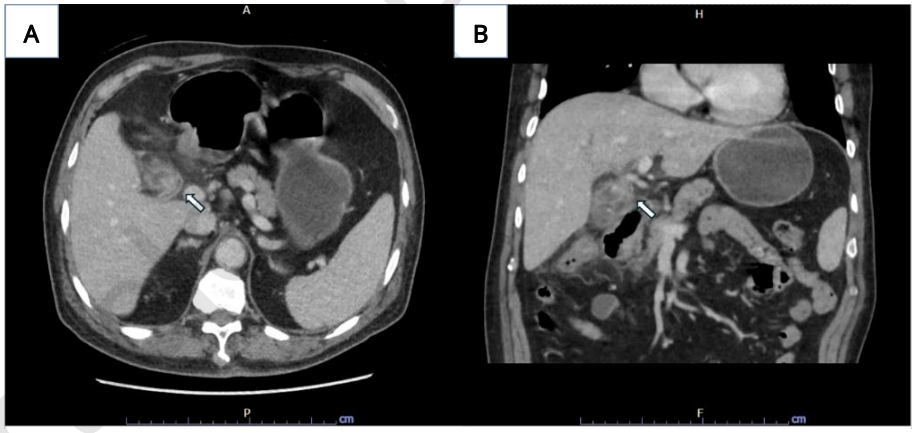

A, In the axial plane, there is mild dilation of the bilateral intrahepatic ducts and the common hepatic duct, accompanied by several calcified stones (indicated by arrows) with perilesional hyperechoic areas at the gallbladder fossa, consistent with acute calculous cholecystitis.

B, In the coronal plane, there is compression of the common hepatic duct by the calcified stones, suggesting the possibility of Mirizzi syndrome (arrow sign).

Figure 2. Intraoperative Identified Using an Indocyanine Green Fluorescent Camera

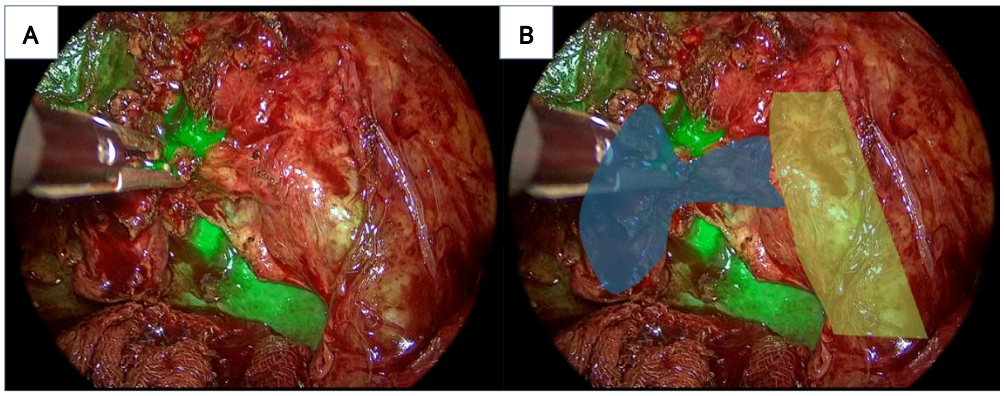

A, Indocyanine green (ICG) guidance demonstrating fluorescent structure of the suspected common bile duct in the extrahepatic biliary tree.

B, The yellow color represents the common bile duct, while the blue color indicates the gallbladder remnant.

Figure 3. Intraoperative Cholangiogram of Common Hepatic Duct

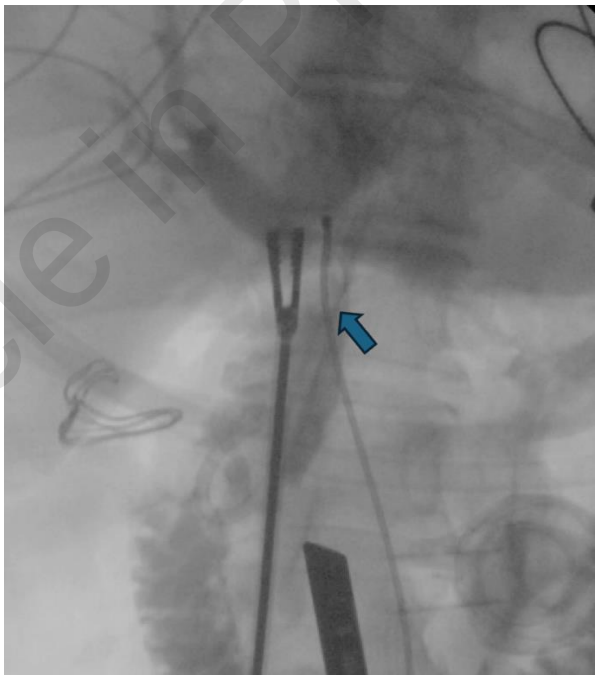

Filling defect in the common hepatic duct (blue arrow) was shown, compressing between one-third and two-thirds of the common bile duct diameter.

Article in Press

Figure 4. Primary Repair of the Common Hepatic Duct

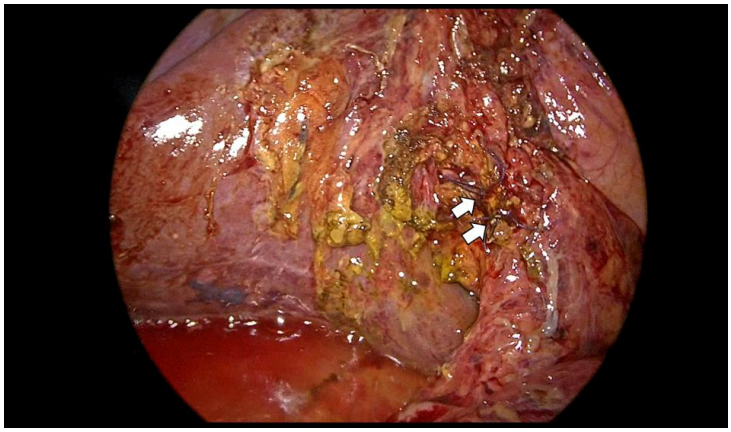

The primary repair was performed after the removal of the gallbladder remnant and a calcified stone (white arrow).

Figure 5. Endoscopic Retrograde Cholangiopancreatography

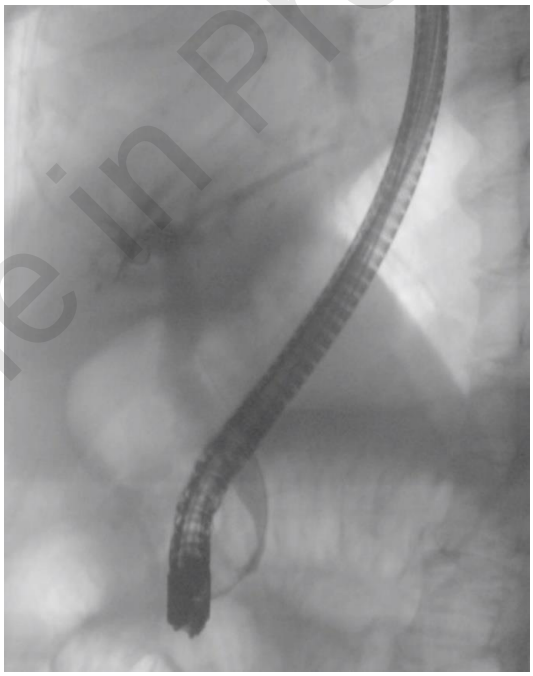

The intraoperative cholangiogram showed no stricture at the common hepatic duct after stent removal.

Article in Press

Discussion

PCMS is a rare condition that occurs after a cholecystectomy. It most commonly results from retained or recurrent stones within a cystic duct remnant or residual gallbladder tissue, leading to biliary obstruction.[1,3] Patients frequently present months to years after the initial operation with symptoms of biliary obstruction, and the diagnosis is often delayed because of its rarity and nonspecific clinical manifestations.[6]

The pathogenesis of PCMS is multifactorial. A long cystic duct remnant, subtotal cholecystectomy, severe inflammation during the initial operation, and retained calculi have all been implicated as predisposing factors. In a difficult cholecystectomy, surgeons may intentionally leave a longer cystic duct stump to minimize the risk of bile duct injury. While this strategy is justified intraoperatively, residual stones or subsequent stone formation within the remnant duct may later lead to recurrent biliary obstruction and Mirizzi syndrome.[14] Furthermore, a prior study has reported that PCMS can be caused by the migration of polymeric surgical clips.[15] Therefore, preoperative imaging is essential for evaluating the pathophysiology of PCMS.

Historically, open surgery has been viewed as the standard treatment approach for PCMS, primarily because this condition often involves severe adhesions and changes in the anatomy of the hepatobiliary system. As a result, these factors can complicate the surgical procedure.[6] In contrast, laparoscopic management of Mirizzi syndrome presents unique challenges, especially in patients classified as Csendes classification III, where the anatomical alterations may be less severe but still significant enough to complicate the procedure. In such cases, careful planning and advanced surgical techniques are crucial to successfully navigate the complexities of the anatomy and minimize the risk of complications. A previous report showed postoperative bile leakage after choledochoplasty in Mirizzi Csendes classification III.[16] Therefore, in our case, we decided to leave a biliary stent for decompression in the common bile duct and common hepatic duct. Laparoscopic approaches can offer benefits like reduced recovery time and less postoperative pain, but they require a high level of skill and experience from the surgical team.[17] The complete laparoscopic approach for Csendes type III is still limited because of the challenges posed by dense adhesions, chronic inflammation, and changes to Calot's triangle that often occur following previous surgeries. One of the most significant complications associated with Mirizzi syndrome is bile duct injury, largely due to these factors, which dramatically increases the risk of misidentifying the common bile duct.[18] Another important consideration is minimizing the long-term risk of biliary stricture. In this patient with Csendes type III Mirizzi syndrome, choledochoplasty was chosen to repair the bile duct defect. A biliary-enteric bypass may be considered when inflammation causes distal common bile duct stricture, the defect is extensive, or the remaining tissue is unsuitable for repair. In this paient's staged laparoscopic approach, preoperative ERCP with biliary stent placement was intended to facilitate intraoperative identification of the bile duct in the setting of severe inflammation and to provide biliary decompression after repair, potentially avoiding the need for T-tube drainage.

ICG fluorescent imaging has gained widespread acceptance during difficult laparoscopic cholecystectomy to improve visualization of the extrahepatic biliary anatomy, although its application in PCMS has rarely been reported.[19] In this challenging setting, real-time near-infrared fluorescence enables dynamic identification of the common hepatic duct and common bile duct without requiring cystic duct cannulation or intraoperative cholangiography, thereby providing additional anatomical orientation throughout dissection.[10,20,21] Another important advantage of ICG fluorescence in this case was its ability to define the relationship between the remnant cystic duct and the extrahepatic biliary tree before opening the remnant duct for stone extraction. In this case, ICG fluorescent cholangiography and intraoperative cholangiography served complementary roles. ICG provided real-time visualization of the biliary anatomy during dissection without bile duct cannulation, whereas intraoperative cholangiography was used to assess the bile duct lumen for residual stones or strictures. However, ICG fluorescent imaging

Article in Press

has several limitations. First, limited tissue penetration may impair visualization of the bile ducts through inflamed or fibrotic tissue or in patients with obesity. When the overlying tissue is thick, careful dissection to reduce tissue coverage may therefore be necessary before the biliary structures can be clearly visualized with fluorescence. Second, the optimal timing of ICG administration remains uncertain, and high background hepatic fluorescence may obscure the common bile duct. Despite these limitations, the real-time anatomical guidance provided by ICG fluorescent imaging may be particularly useful in reoperative hepatobiliary surgery, where tissue planes are often obscured by fibrosis.

This case report has 2 main limitations. First, the follow-up period was limited to 6 months, precluding assessment of long-term outcomes, particularly late biliary stricture and recurrent cholangitis. Second, the findings are based on a single patient, which limits their generalizability.

This case highlights the effectiveness of ICG fluorescent cholangiography as an important adjunct in identifying biliary anatomy during reoperative laparoscopic surgery. This technique enhances the visualization of bile ducts, which can be particularly beneficial in situations where the anatomy is complicated.

Conclusions

PCMS caused by a retained cystic duct remnant stone is a rare but important differential diagnosis in patients presenting with recurrent biliary symptoms after cholecystectomy. Careful preoperative imaging combined with advanced minimally invasive techniques enables successful surgical management in selected patients. Staged ERCP decompression followed by laparoscopic remnant cholecystectomy is feasible in experienced hands. This case has highlighted that ICG fluorescent cholangiography was a useful adjunct for anatomical orientation, while its contribution to safety requires further study.

Article in Press

Additional Information

Ethics Approval: This case report obtained approval from the Human Research Ethics Committee of the Faculty of Medicine Ramathibodi Hospital, Mahidol University (MURA2026/554) on 6 July 2026. Written informed consent was obtained from the patient prior to inclusion in the study.

Financial Support: No financial support was provided for this study.

Conflict of Interest: The author declares no conflict of interest.

Declaration of AI Assistance: The author declares that no generative AI tools were used in the preparation of this manuscript. All content was created solely by the author.

Author Contributions:
Conceptualization: Ativitch Asavachaisuvikom
Data Curation: Ativitch Asavachaisuvikom
Investigation: Ativitch Asavachaisuvikom
Methodology: Ativitch Asavachaisuvikom
Project Administration: Ativitch Asavachaisuvikom
Resources: Ativitch Asavachaisuvikom
Visualization: Ativitch Asavachaisuvikom
Writing – Original Draft: Ativitch Asavachaisuvikom
Writing – Review & Editing: Ativitch Asavachaisuvikom

Article in Press

References

1. Borz-Baba C, Levy DA, Cohen ME. Post-cholecystectomy Mirizzi syndrome: a case report and review of the literature. *Am J Case Rep.* 2019;20:1290-1298. doi:10.12659/AJCR.916364
2. Alkhatib AA, Kalas MA, Balci N, Khaskheli AM, Kumar S. Post-cholecystectomy Mirizzi syndrome. *Cureus.* 2022;14(4):e24379. doi:10.7759/cureus.24379
3. Wani NA, Khan NA, Shah AI, Khan AQ. Post-cholecystectomy Mirizzi's syndrome: magnetic resonance cholangiopancreatography demonstration. *Saudi J Gastroenterol.* 2010;16(4):295-298. doi:10.4103/1319-3767.70620
4. Lim MS, Jeon JY, Kwon JW, et al. Laparoscopic treatment for post-cholecystectomy Mirizzi syndrome. *Korean J Hepatobiliary Pancreat Surg*. 2013;17(2):79-82. doi:10.14701/kjhbps.2013.17.2.79
5. Clemente G, Tringali A, De Rose AM, et al. Mirizzi syndrome: diagnosis and management of a challenging biliary disease. *Can J Gastroenterol Hepatol.* 2018;2018:6962090. doi:10.1155/2018/6962090
6. Erben Y, Benavente-Chenhalls LA, Donohue JM, et al. Diagnosis and treatment of Mirizzi syndrome: 23-year Mayo clinic experience. *J Am Coll Surg*. 2011;213(1):114-121. doi:10.1016/j.jamcollsurg.2011.03.008
7. Yetışır F, Şarer AE, Acar HZ, et al. Laparoscopic treatment of type III Mirizzi syndrome by T-tube drainage. *Case Rep Surg.* 2016;2016:1030358. doi:10.1155/2016/1030358
8. Xu C, Yin M, Wang H, et al. Indocyanine green fluorescent cholangiography improves the clinical effects of difficult laparoscopic cholecystectomy. *Surg Endosc.* 2023;37(8):5836-5846. doi:10.1007/s00464-023-10035-8
9. Ravikumar S, Musham R, Vardhan Rao GV, Eppa VR. Impact of indocyanine green (ICG) fluorescence cholangiography on operative time and safety in laparoscopic cholecystectomy: a prospective randomized controlled study. *Cureus.* 2025;17(7):e88639. doi:10.7759/cureus.88639

10. Zhou J, Tan Z, Sun B, Leng Y, Liu S. Application of indocyanine green fluorescence imaging in hepatobiliary surgery. *Int J Surg.* 2024;110(12):7948-7961. doi:10.1097/JS9.0000000000001802
11. Yokoe M, Hata J, Takada T, et al. Tokyo Guidelines 2018: diagnostic criteria and severity grading of acute cholecystitis (with videos). *J Hepatobiliary Pancreat Sci.* 2018;25(1):41-54. doi:10.1002/jhbp.515
12. Kiriyama S, Kozaka K, Takada T, et al. Tokyo guidelines 2018: diagnostic criteria and severity grading of acute cholangitis (with videos). *J Hepatobiliary Pancreat Sci.* 2018;25(1):17-30. doi:10.1002/jhbp.512
13. Csendes A, Díaz JC, Burdiles P, Maluenda F, Nava O. Mirizzi syndrome and cholecystobiliary fistula: a unifying classification. *Br J Surg.* 1989;76(11):1139-1143. doi:10.1002/bjs.1800761110
14. López-López J, García-Covarrubias L, Flores de León SY, et al. Post-cholecystectomy Mirizzi syndrome by calculus in the remaining cystic duct: case report and review of literature. *Case Rep Surg*. 2026; 2026:6658220. doi:10.1155/cris/6658220
15. Nagorni EA, Kouklakis G, Tsaroucha A, et al. Post-laparoscopic cholecystectomy Mirizzi syndrome induced by polymeric surgical clips: a case report and review of the literature. *J Med Case Rep.* 2016;10:135. doi:10.1186/s13256-016-0932-5
16. Nassar AHM, Nassar MK, Gil IC, Ng HJ, Yehia AM. One-session laparoscopic management of Mirizzi syndrome: feasible and safe in specialist units. *Surg Endosc.* 2021;35(7):3286-3295. doi:10.1007/s00464-020-07765-4
17. Sato H, Hiraki M, Miyoshi A, Ikeda S, Koga H, Kitahara K. The strategy for Mirizzi syndrome type II with laparoscopic surgery: a case report. *Int J Surg Case Rep.* 2020;77:673-676. doi:10.1016/j.ijscr.2020.11.106
18. Chen H, Siwo EA, Khu M, Tian Y. Current trends in the management of Mirizzi syndrome: a review of literature. *Medicine.* 2018;97(4):e9691. doi:10.1097/MD.0000000000009691
19. Utsunomiya T, Sakamoto K, Sogabe K, et al. Laparoscopic remnant cholecystectomy for calculi in the remnant gallbladder following subtotal-cholecystectomy: a report of two cases. *Surg Case Rep*. 2021;7(1):250. doi:10.1186/s40792-021-01333-1
20. van den Bos J, Wieringa FP, Bouvy ND, Stassen LPS. Optimizing the image of fluorescence cholangiography using ICG: a systematic review and ex vivo experiments. *Surg Endosc.* 2018;32(12):4820-4832. doi:10.1007/s00464-018-6233-x
21. Dip F, Aleman J, DeBoer E, et al. Use of fluorescence imaging and indocyanine green during laparoscopic cholecystectomy: results of an international Delphi survey. *Surgery.* 2022;172(6S):S21-S28. doi:10.1016/j.surg.2022.07.012

Article in Press