

The Unstable Trochanteric Fractures Treated with Proximal Femoral Nail

Antirotation versus Sliding Hip Screw

Thananit Sangkomkamhang, MD

Department of Orthopedic Surgery, Khon Kaen Regional Hospital,
Khon Kaen, Thailand

Purpose: To compare the complications and functional outcomes of patients with unstable trochanteric fractures AO/OTA 31-A2 treated with a proximal femoral nail antirotation (PFNA) device versus sliding hip screw (SHS).

Methods: A prospective randomized study of patients with unstable trochanteric fractures AO/OTA 31-A2 from January 2010 to December 2012 was performed. A total of 181 patients were randomized into two groups: the PFNA group (n = 95) and the SHS group (n = 86). Perioperative and postoperative data, functional outcomes, and complications were recorded and assessed.

Results: Although the reoperation rate was lower in the PFNA group than in the SHS group, there was no significant difference between the reoperation rates of the two groups in the patients with unstable trochanteric fractures. There was also no significant difference in functional outcome between the PFNA group and the SHS group. The SHS group had a prolonged operative time and produced more blood loss than the PFNA group.

Conclusion: For treatment of unstable trochanteric fractures (AO/OTA 31-A2) of proximal femur, the sliding hip screw should remain the standard treatment of care. However, the PFNA device is still useful for the treatment of unstable trochanteric fractures (AO/OTA 31-A2) that involve the lateral cortex.

Keywords: Proximal femoral nail antirotation, sliding hip screw, trochanteric fractures

The Thai Journal of Orthopaedic Surgery: 39 No.3-4: 17-24

Full text. e journal: <http://www.rcost.or.th>, <http://thailand.digitaljournals.org/index.php/JRCOST>

Introduction

Intertrochanteric fracture of the proximal femur is a common injury in the geriatric population and is often associated with underlying diseases. Operation has become the treatment of choice for the prevention of serious complications. Despite improvements in the operative techniques, the morbidity and mortality rates are still increased.⁽¹⁾ Many instrument designs have been developed to improve fracture fixation, for early ambulation and to reduce the risk of complications.⁽¹⁻³⁾ Internal fixation devices can be divided into two groups: extramedullary fixation and intramedullary fixation devices. Intertrochanteric fractures of the proximal part of the femur have been treated successfully by using of the sliding hip screw (SHS) over the past few decades. From literature reviews, it can be concluded that this implant is the treatment of choice for stable (AO/OTA [Arbeitsgemeinschaft für Osteosynthesefragen/Orthopaedic Trauma Association] 31-A1) fractures⁽³⁾, but it was still controversial with regard to the treatment of the more unstable (AO/OTA 31-A2 and A3) fractures. The evidence is increasingly clear that an intramedullary fixation device is the best treatment

of choice for reverse obliquity fractures of the proximal part of the femur (AO/OTA 31-A3)⁽⁴⁾; however, the suitable treatment for comminuted fractures involving the lesser trochanter (AO/OTA 31-A2) is still unclear. The limitations of evidence-based medicine indicated that one type of device should be preferred more than the others. Biomechanical studies have shown that intramedullary fixation devices are more stable under loading but many studies have also indicated that there were a significant number of technical failures leading to the limited use of this implant⁽⁴⁻⁶⁾. When compared with extramedullary fixation techniques, the values for the short-term advantages of intramedullary fixation, including postoperative partial to full weight-bearing, are a slightly higher incidence of reoperation due to technical problems⁽⁷⁾. This study aimed to compare the reoperation rate of AO/OTA 31-A2 fractures of the proximal part of the femur between using the sliding hip screws and the proximal femoral nail antirotation (PFNA).

Patients and methods

A prospective randomized study of patients with unstable trochanteric fractures

AO/OTA 31-A2 from January 2010 to December 2012 was performed. The consecutive patients with trochanteric femoral fractures who were candidates for surgery were randomized into two groups: those for fixation with the SHS and those for the PFNA device collected from January 2010 to December 2012. Plain radiographs were obtained on admission and all fractures were categorized according to AO/ASIF classification⁽⁸⁻⁹⁾ (31-31-A2/trochanteric fracture). Patients with a pathological fracture or multiple injuries were excluded from the study. This study was approved by the Ethics Committee of Khon Kaen Hospital and all participants provided written informed consents. Randomization was carried out with sealed envelopes generated by a medical statistician. Consent was obtained after a patient met appropriate inclusion criteria. An envelope was selected and opened in the morning conference daily for the appropriate operative planning.

A total of 250 envelopes were generated, and 245 patients were recruited. There was unblinding of trial participants to their treatment allocation for either the patients or the orthopedists involved in the patients' care. Two hundred and six patients who met the inclusion criteria were enrolled into the trial and were divided into two groups: 105 for the PFNA and 101 for the SHS group. Two patients in the SHS group died before surgery (Fig. 1). Patients were admitted to the orthopaedic ward and managed with the same standard preoperative protocol in both groups.

Surgery was performed with the patient in the supine position on a fracture table, with the injured extremity slightly adducted to facilitate insertion of the implant. Fracture fixation with the PFNA device was performed according to the surgical technique described by Simmermacher *et al.*⁽¹⁰⁾ and fracture fixation with the SHS was performed according to the surgical technique described by Rüedi *et al.*⁽¹¹⁾. After surgery, the patients were mobilized and given standard rehabilitation instructions by a physiotherapist. All patients received a prophylactic intravenous antibiotic during their hospitalization.

Patient's age and gender, preoperative information (time to surgery), underlying diseases (such as diabetes mellitus, hypertension, cardiovascular, and cerebrovascular diseases) and perioperative information including operative time, volume of blood loss, fluoroscopy time and length of hospital stay were recorded. Follow-up evaluations consisting of clinical examination, assessment of functional outcome, and radiographs, were evaluated at 1, 2, 4 and 6 months, and then annually. Patients were followed up for a minimum of 1 year and maximum to 2 years. They were also interviewed and examined by two independent observers. For fracture evaluation, they were

divided into two groups depending on the intactness of their lateral cortexes of trochanteric areas which were used for subgroup analysis. Every follow-up, radiographs were taken and evaluated for reduction status, tip apex distance (TAD), displacement, screw position, cut-out (where the screw moves through and out of the femoral head), and fracture union. Radiographic fracture healing was defined as the presence of bridging callus on radiographs.

Statistical analysis

The power calculation was based on the primary outcome measure of implant failure or cut-out, with anticipated failure rates of 5% for the long gamma nail and 18% for the sliding hip screw. A two-tailed continuity corrected Chi squared test with 80% power and a 5% level of significance produced a required sample size of 210 patients (105 per group). Statistical analysis was performed using the STATA statistical analysis software package, version 10 (StataCorp, College Station, TX, United State) for Windows®. Data are reported as mean \pm standard deviation (SD). Student's *t*-test and Fisher's exact test were used to compare non-parametric means. A *P*-value < 0.05 was considered to be statistically significant.

Results

A total of 181 patients with unstable trochanteric femoral fractures (31-31-A2) were included in this study from January 2010 to December 2012. Ninety five patients in the PFNA group and 86 patients in the SHS group were analysed. There were 50 intact lateral cortexes and 45 broken lateral cortexes in the PFNA group, and 52 intact lateral cortexes and 34 broken lateral cortexes in the SHS group. The mean age was 72 years in the PFNA group (range 53-91 years) and 70 years the SHS group (range 51-85 years) (Table 1). The operative time was significantly higher in the SHS group than in the PFNA group (65 ± 13 vs 45 ± 10 min, $P < 0.05$) whereas the fluoroscopy time was significantly greater in the SHS group when compared with the PFNA group (8 ± 3 vs 5 ± 2 min, $P < 0.05$). The TAD was not significantly different between the SHS group and the PFNA group (20 ± 3 vs 18 ± 4 mm) ($P > 0.05$). The external blood loss during surgery was significantly lower in the PFNA group than in the SHS group (140 ± 24 vs 250 ± 65 ml) ($P < 0.05$). There were no significant differences between the time to surgery (5 days) and the length of hospital stay (11 days) in both treatment groups and among different types of fractures. In addition, there was no statistically significant difference in the complication rate between the two treatment groups and among different types of fractures (Table 2).

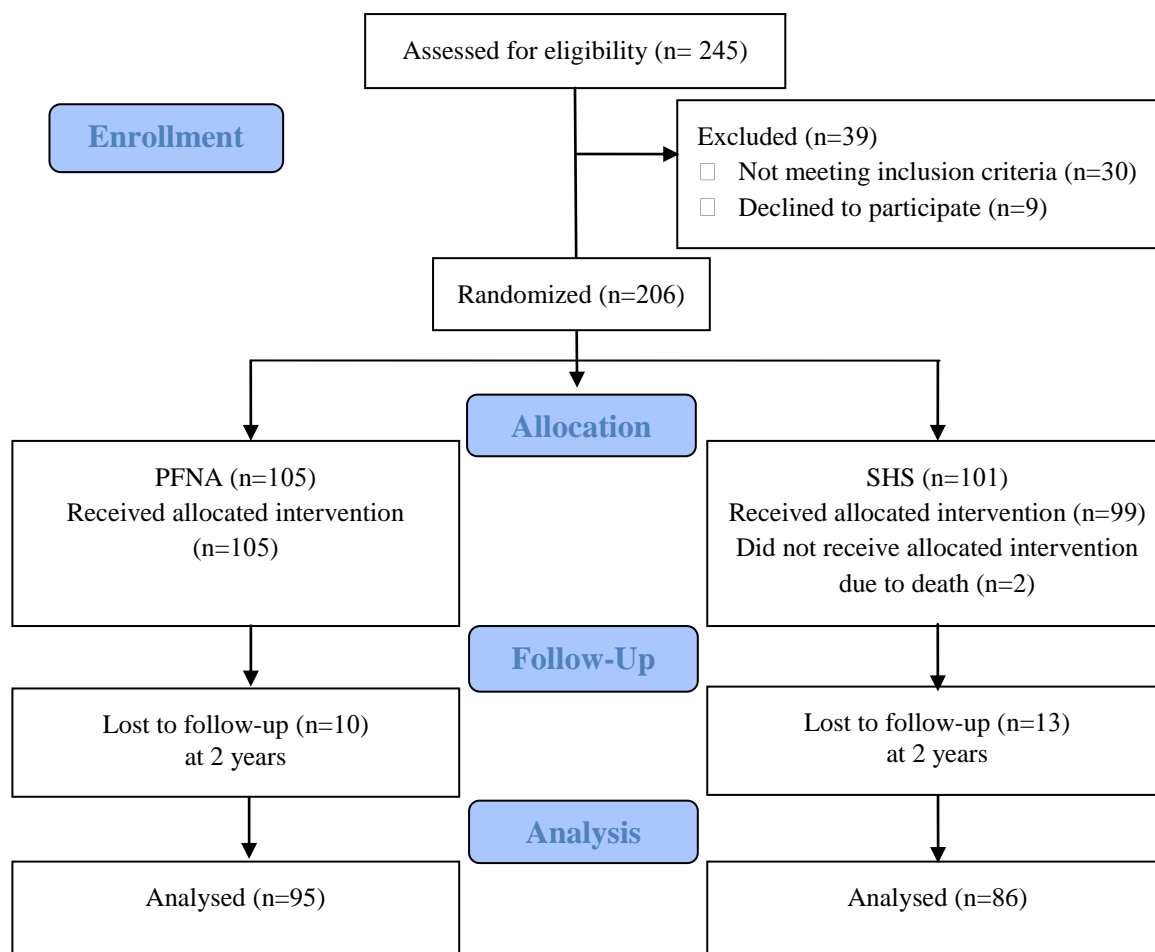


Fig. 1 Flow diagram of participants through each stage of the trial

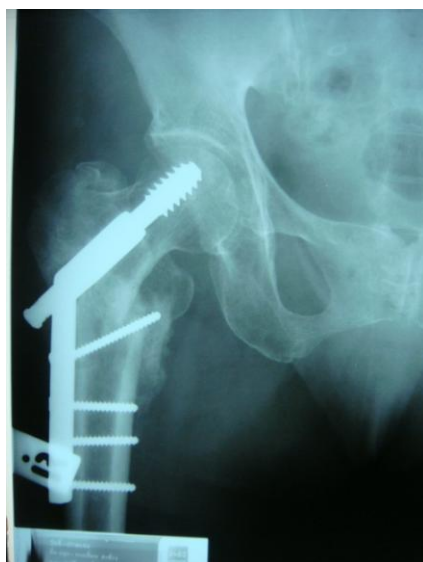

Fig. 2 Radiograph at 6 months after treatment showing a collapse and break of the lateral cortex

For intact lateral cortex fractures in the SHS group, one patient with wound infection required antibiotics and debridement and one patient required reoperation due to failure of the implant. In 45 broken lateral cortex fractures, one patient in the PFNA group had a superficial wound infection without reoperation, and two patients in the SHS group required reoperative surgery both due to a collapse and cut through (Fig. 2). The postoperative radiographs of a 70-year-old woman with an AO/OTA 31-A2 -type trochanteric fracture which demonstrated that the instrument failure (Fig. 3)

Table 1 Demographic characteristics

No. of patients	Total n=181	PFNA n=95	SHS n=86	P-value
Female		59 (79%)	50 (76%)	>0.05
Age (years)		72 (53-91)	70 (51-85)	>0.05
Subgroup*				
- Intact lateral cortex		50	45	>0.05
- Break lateral cortex		45	41	
Time to surgery (days)		5	5	>0.05
Underlying Diseases		75%	73%	>0.05

*Divided into two groups: intact and break through lateral cortex of trochanteric areas

Table 2 Results of patients treated with the proximal femoral nail antirotation versus the dynamic hip screw

	PFNA	SHS	P-value	Estimate	95%CI
Tip apex distance(TAD)(mm)	18 (±4)	20 (±3)	0.54	0.61	0.53-2.15
No. of complication	5	8	0.67	1.71	0.28-8.42
Operative time (minutes)	45 (±10)	63 (±13)	0.000	41	44 -37
Fluoroscopy time (minutes)	5 (± 3)	8 (± 2)	0.000	2	1.14-2.86
Blood loss (ml)	140 (± 24)	250 (± 65)	0.000	254	-270 -238
Length of hospital stay (days)	11 (5-22)	11 (6-24)	0.86	0.82	0.61-1.13

Table 3 Complications in patients treated with the proximal femoral nail antirotation versus the dynamic hip screw needed for reoperation and divided into 2 subgroups (intact or broken lateral cortex of trochanteric areas)

Complication	PFNA		SHS	
	Intact lateral cortex	Break lateral cortex	Intact lateral cortex	Break lateral cortex
	n=50	n=45	n=45	n=41
Cut out	1	3	1	3
Non union	-	-	-	1
Screw migration	-	-	-	1
Implant failure	-	-	1	1
Wound infection		1	-	
Total	1	4	2	6

Data show No. of patients

No statistically significant differences between the two treatment groups or for different types of fracture

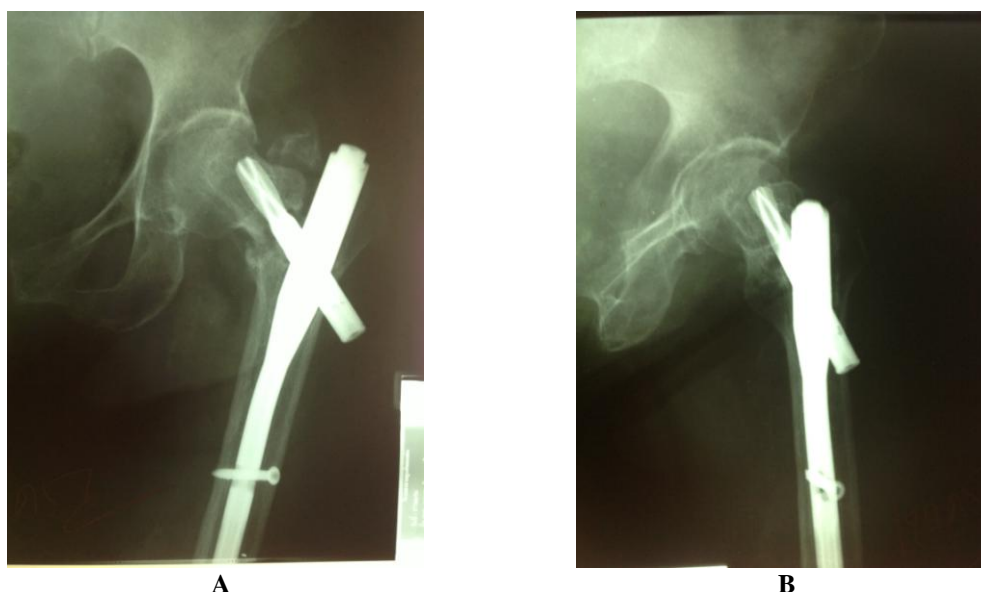


Fig. 3 Postoperative anteroposterior (A) and lateral (B) radiographs of a 70-year-old woman with an AO/OTA 31-A2 -type trochanteric fracture indicating instrument failure

Discussion

The outcome of treatment for trochanteric fractures depends on various factors, including age of the patients, underlying diseases, time from fracture to treatment, adequacy of treatment, bone quality and fixation stability⁽⁸⁾. The ideal implant for the treatment of unstable trochanteric fractures (AO/OTA 31-A2) is still controversial. The SHS was introduced over thirty years ago and remains to be the implant of choice for the treatment of trochanteric fractures because of its favorable outcome, low rates of non-union and fixation failure⁽¹²⁾. However, the placement of SHS requires a relatively large exposure, significant soft tissue injury, intraoperative time, blood loss, and the need for anatomical reduction. Additionally, the screws and side plate create stress risers in the bone that can increase the risk of distal fractures to the implant⁽¹³⁻¹⁴⁾. Furthermore, the side plate should be attached to lateral cortex of the trochanter preventing the collapse and the cut-out of the sliding screw. Intramedullary fixation implants including the PFNA or gamma nail device show higher biomechanical loading than the SHS type of implant. The gamma nail is associated with specific complications such as anterior thigh pain, fracture of the femoral shaft and the proximal part of nail needing to be large for Asian patients⁽¹⁵⁾. The proximal femoral nail has been shown to prevent fractures of the femoral shaft by having a smaller proximal and distal shaft diameter, which reduces the stress concentration at the tip. However, the screw cut-out, especially from varus angulation, rotation, or collapse, is one of the most important considerations. These patterns of fixation failure are most often directly due to insufficient purchase

of the implant in the femoral neck and head. The device has to achieve sufficient purchase in the femoral head in order to decrease risk of a cut-out.

Three different versions of the PFNA device were designed. The distal part of the nail is available in diameters of 9, 10, 11 or 12 mm, and its proximal section is 16.5 mm in diameter. The tip of the nail is specially shaped to reduce stress. The implant was designed for the use of a helically-shaped blade with a large surface area that can compact and preserve cancellous bone. Anatomical and biomechanical studies have shown that the superomedial quadrant of the femoral head is the weakest part of the implant. The screw cut-out often occurs there, particularly in osteoporotic bone⁽¹⁶⁻¹⁷⁾. Many studies have suggested that rotation of the head/neck fragment appeared in all types of devices in these fractures, so progress of this rotation until fracture healing has occurred seems to be the issue to solve⁽¹⁸⁾. Intramedullary fixation of intertrochanteric fractures with a nail and a single column device might, therefore, be an ideal instrument.

This study prospectively and randomly compared the PFNA and the SHS devices in patients with trochanteric fractures. The results showed that fracture fixation with the SHS required a significantly prolonged operative time and resulted in significantly greater intraoperative blood loss than the PFNA because the SHS needed an intraoperative open reduction technique. For the primary outcome, the reoperation rate was lower in the PFNA group than the SHS group. But the reoperation rate did not differ significantly between the two groups. For subgroup analysis, the SHS had shown more complications but there was no

significant difference. Due to limitation in the reoperation rate), further study is needed to identified the importance of that the lateral cortex of trochanteric areas that play a role for cut-out or collapse of screw especially in SHS implant.

The strengths of the present study include the randomization design and the appropriate number of patients. However, there were limitations in the high rate of follow-up patient loss, and the power to analyse the subgroups. Another weakness of this study is that the patients and surgeons were unblinded.

Conclusion

This study shows no difference in the reoperation rate in the treatment of unstable trochanteric fractures of the femur (AO/OTA 31-A2) with a PFNA device or a sliding hip screw. We concluded that the sliding hip screw should remain the standard treatment for the patients with trochanteric fractures (AO/OTA 31-A2) because it is associated with similar complications. But the PFNA device is an intramedullary device that allows for immediate postoperative partial or full weight bearing. The present study showed that the PFNA device could be effectively used to treat trochanteric fractures involving the lateral cortex of trochanter area because of lower complication rates.

Acknowledgements

The authors wish to thank Assoc. Prof. Dr. Bandit Thinkhamrop, Department of Biostatistics and Demography, Faculty of Public Health, Khon Kaen University, Khon Kaen, Thailand who provided appropriate guidance and comments to this study.

Conflicts of interest

None

References

- Haynes RC, Pöll RG, Miles AW, Weston RB. Failure of femoral head fixation: a cadaveric analysis of lag screw cut-out with the gamma locking nail and AO dynamic hip screw. *Injury* 1997; 28: 337-341.
- Utrilla AL, Reig JS, Muñoz FM, Tufanisco CB. Trochanteric gamma nail and compression hip screw for trochanteric fractures: a randomized, prospective, comparative study in 210 elderly patients with a new design of the gamma nail. *J Orthop Trauma* 2005; 19: 229-233.
- Butt MS, Krikler SJ, Nafie S, Ali MS. Comparison of dynamic hip screw and gamma nail: a prospective, randomized, controlled trial. *Injury* 1995; 26: 615-618.
- Lunsjö K, Ceder L, Stigsson L, Hauggaard A. Two-way compression along the shaft and the neck of the femur with the Medoff sliding plate: one-year follow-up of 108 intertrochanteric fractures. *J Bone Joint Surg Br* 1996; 78: 387-390.
- Simmermacher RK, Bosch AM, Van der Werken C. The AO/ASIF-proximal femoral nail (PFN): a new device for the treatment of unstable proximal femoral fractures. *Injury* 1999; 30: 327-332.
- Bridle SH, Patel AD, Bircher M, Calvert PT. Fixation of intertrochanteric fractures of the femur. A randomised prospective comparison of the gamma nail and the dynamic hip screw. *J Bone Joint Surg Br* 1991; 73: 330-334.
- Takigami I, Matsumoto K, Ohara A, Yamanaka K, Naganawa T, Ohashi M, et al. Treatment of trochanteric fractures with the PFNA (proximal femoral nail antirotation) nail system – report of early results. *Bull NYU Hosp Jt Dis* 2008; 66: 276-279.
- Müller ME, Nazarian S, Koch P, Schatzker J, Heim U. The Comprehensive Classification of Fractures of the Long Bones. Berlin: Springer, 1990.
- Lorich DG, Geller DS, Nielson JH. Osteoporotic pertrochanteric hip fractures. Management and current controversies. *Instr Course Lect* 2004; 53: 441-454.
- Simmermacher RK, Ljungqvist J, Bail H, Hockertz T, Vochteloo AJ, Ochs U. The new proximal femoral nail antirotation (PFNA) in daily practice: results of a multicentre clinical study. *Injury* 2008; 39: 932-939.
- Rüedi TP, Murphy WM, Hoffman R, Haas NP. Femur: proximal. In: *AO Principles of Fracture Management* (Rüedi TP, Murphy WM, eds). Stuttgart: Thieme, 2000; pp 441 – 454.
- Pajarinen J, Lindahl J, Michelsson O, Savolainen V, Hirvensalo E. Pertrochanteric femoral fractures treated with a dynamic hip screw or a proximal femoral nail. A randomised study comparing post-operative rehabilitation. *J Bone Joint Surg Br* 2005; 87: 76-81.
- Kim WY, Han CH, Park JI, Kim JY. Failure of intertrochanteric fracture fixation with a dynamic hip screw in relation to pre-operative fracture stability and osteoporosis. *Int Orthop* 2001; 25: 360-362.

14. Herrera A, Domingo LJ, Calvo A, Martínez A, Cuenca J. A comparative study of trochanteric fractures treated with the Gamma nail or the proximal femoral nail. *Int Orthop* 2002; 26: 365-369.
15. Rosenblum SF, Zuckerman JD, Kummer FJ, Tam BS. A biomechanical evaluation of the Gamma nail. *J Bone Joint Surg Br* 1992; 74: 352-357.
16. Barton TM, Gleeson R, Topliss C, Greenwood R, Harries WJ, Chessier TJ. A comparison of the long gamma nail with the sliding hip screw for the treatment of AO/OTA 31-A2 fractures of the proximal part of the femur: a prospective randomized trial. *J Bone Joint Surg Am* 2010; 92: 792-798.
17. Schipper IB, Steyerberg EW, Castelein RM, van der Heijden FH, den Hoed PT, Kerver AJ, et al. Treatment of unstable trochanteric fractures. Randomised comparison of the gamma nail and the proximal femoral nail. *J Bone Joint Surg Br* 2004; 86: 86-94.
18. Sommers MB, Roth C, Hall H, Kam BC, Ehmke LW, Krieg JC. A laboratory model to evaluate cutout resistance of implants for pertrochanteric fracture fixation. *J Orthop Trauma* 2004; 18: 361-368.

การเปรียบเทียบการรักษากระดูกสะโพกหักระหว่างโทรแคนเตอร์ด้วยเครื่องมือ *Proximal Femoral Nail Antirotation* และ *Sliding Hip Screw*

ธนิตย์ สังคมกำแหง, พบ

วัตถุประสงค์: เพื่อศึกษาเปรียบเทียบภาวะแทรกซ้อนและผลการทำงานของร่างกายจากการผ่าตัดรักษา กระดูกสะโพกหักระหว่างโทรแคนเตอร์ด้วยเครื่องมือ *Proximal Femoral Nail Antirotation (PFNA)* และ *Sliding Hip Screw (SHS)*

วิธีการศึกษา: เป็นงานวิจัย *prospective randomized controlled trial* ศึกษาในผู้ป่วยกระดูกสะโพกหักระหว่างโทรแคนเตอร์ (AO31-A2) ซึ่งได้รับการรักษาโดยการผ่าตัดตามกระดูกด้วยเครื่องมือ *Proximal Femoral Nail Antirotation* และ *Sliding Hip Screws* ในโรงพยาบาลศูนย์ขอนแก่น ระหว่างปี พ.ศ. 2553-2555 โดยศึกษาเปรียบเทียบภาวะแทรกซ้อนและผลการทำงานของร่างกาย รวมถึงข้อมูลก่อนการผ่าตัด ระหว่างการผ่าตัด และหลังการผ่าตัด

ผลการศึกษา: ผู้ป่วยจำนวน 181 รายเข้าร่วมในการศึกษานี้ โดยกลุ่ม PFNA มีจำนวน 95 ราย และกลุ่ม SHS มีจำนวน 86 ราย ผลปรากฏว่า ภาวะแทรกซ้อนหลังการผ่าตัดในผู้ป่วยทั้งสองกลุ่มไม่แตกต่างกัน แต่ภาวะแทรกซ้อนในกลุ่ม PFNA มีจำนวนน้อยกว่าในกลุ่ม SHS โดยเฉพาะในผู้ป่วยที่มีกระดูกต้นขาด้านนอกแตกร่วมด้วย การเสียเลือดหลังการผ่าตัดและระยะเวลาที่ใช้ในการผ่าตัดในกลุ่ม PFNA น้อยกว่าในกลุ่ม SHS อย่างมีนัยสำคัญทางสถิติ อย่างไรก็ตาม ไม่พบความแตกต่างในเรื่องการให้เลือดแก่ผู้ป่วยระหว่างทั้งสองกลุ่ม

สรุป: การผ่าตัดรักษา กระดูกสะโพกหักระหว่างโทรแคนเตอร์ด้วยเครื่องมือ *Sliding Hip Screws* ยังคงเป็นเครื่องมือมาตรฐานในการรักษา สำหรับเครื่องมือ *Proximal Femoral Nail Antirotation* ก็มีความเหมาะสมในกรณีที่มีกระดูกต้นขาด้านนอกแตกร่วมด้วย
