

# ENDOSCOPIC SINUS SURGERY : ประสบการณ์ใน โรงพยาบาลพหลพลพยุหเสนา

สมพงษ์ ศิริรัตน์

รพ. พหลพลพยุหเสนา

## ABSTRACT :

**Sirirat S. Endoscopic Sinus Surgery : Experience at Paholpolpayuhasaena Hospital.**  
(Region 7 Medical Journal 1998 ; 1 : 83-90).

Department of Otolaryngology, Paholpolpayuhasaena Hospital, Kanchanaburi, Thailand.

A retrospective review of the patients who have undergone endoscopic sinus surgery in Paholpolpayuhasaena hospital during May 1995 - October 1997 was conducted to determine indications, out come and complications.

There were 40 patients, 19 males and 21 females, receiving 43 times of this surgery. The most frequent indication was chronic sinusitis with polyps (75%).

In our series, no severe complication existed except 5 patients (12.5%) who retained residual disease, three of them were operated again and get good result.

**บทคัดย่อ :**

**สมพงษ์ ศิริรัตน์. Endoscopic Sinus Surgery : ประสบการณ์ในโรงพยาบาลพหลพลพยุหเสนา.**  
(วารสารแพทย์เขต 7 2541 1 : 83-90)

กลุ่มงาน โสต ศอ นาสิก, รพ. พหลพลพยุหเสนา, กาญจนบุรี.

ศึกษาย้อนหลังผู้ป่วยที่เข้ารับการผ่าตัดบริเวณโพรงจมูกและโพรงข้างจมูกด้วย Endoscope ในโรงพยาบาลพหลพลพยุหเสนา ระหว่างเดือนพฤษภาคม 2538 ถึงเดือนตุลาคม 2540 พบผู้ป่วยจำนวน 40 ราย เป็นเพศชาย 19 ราย เพศหญิง 21 ราย อายุเฉลี่ย 30 ปี (9-62 ปี)

จำนวนครั้งของการผ่าตัด 43 ครั้ง จำนวนโพรงข้างจมูกทั้งหมด 72 ข้าง เวลาที่นอนพักในโรงพยาบาลเฉลี่ย 4 วัน

ร้อยละ 75 ของผู้ป่วยเข้ารับการผ่าตัด เนื่องจากโพรงข้างจมูกอักเสบเรื้อรังร่วมกับริดสีดวงจมูก รายงานนี้ไม่พบผลแทรกซ้อนที่รุนแรงอื่น ผลแทรกซ้อนที่พบบ่อยที่สุดคือรอยโรคหลงเหลือต้องรับการผ่าตัดซ้ำ จำนวน 5 ราย คิดเป็นร้อยละ 12.5

## Introduction

The modern trend in the surgical treatment of intranasal disease and sinus disease such as, chronic ethmoiditis, including nasal polyps, chronic maxillary sinusitis, choanal polyp etc., is functional endoscopic sinus surgery or endoscopic endonasal surgery which has been pioneered by Messerklinger.<sup>1</sup> Since then, this surgical technique has appeared in the publications of Stammberger.<sup>2,3</sup> The first publication on the use of this technique in the USA appeared in 1985,<sup>4</sup> and in 1987 this operation was first done in Thailand at Ramathibodi hospital Bangkok,<sup>5</sup> and at Songklanagarind hospital in 1990.<sup>6</sup>

Paholpolpayuhasaena hospital start to use this technique in 1995 and endoscopic sinus surgery is the standard technique in the treatment of chronic sinusitis with or without nasal polyp and other intranasal and sinus disease in this hospital.

The evolution of this technique is based on the modern understanding of the pathophysiological concepts of sinusitis.<sup>7-9</sup>

### Modern theory and concepts of sinusitis

Since the nasal cavities and the paranasal sinuses possess close anatomical and functional relationships, many of the inflammatory processes of the sinuses result from the extension of the intranasal disease,<sup>8</sup> one should regard the chronic sinusitis as recurrent or chronic rhinosinusitis.

The main causative agent of chronic maxillary sinusitis is bacterial, either aerobic or anaerobic or both.<sup>10</sup> Naumann emphasized the role of the ostiomeatal unit in chronic sinusitis : this unit includes

the middle meatal "natural" ostium, the anterior ethmoidal air cells (also the bulla ethmoidalis), the middle turbinate and the mucosa in the unit : Several conditions can block the drainage of the sinuses via this unit eg. infection, pus, mucosal oedema, swollen and abnormal middle turbinate and poor mucociliary transport, leading to a viscous cycle of closure of the ostium.<sup>11</sup> Messerklinger studied the mucociliary clearance of the sinuses by means of endoscopic examination of patients with chronic sinusitis and time-lapsed in fresh autopsy specimens<sup>7</sup> : he noted that wherever two mucosal layers came into contact, there was a localised disruption of the mucociliary clearance with retention of the secretion in the area of contact and thus created an increase potential for infection. Many years of such investigations have led Stammberger to state that :

1. most infections of the paranasal sinuses are rhinogenic,
2. if a sinusitis does not heal or is recurring, a focus of reinfection is usually the stenotic area that fuels the ongoing infection or from which the dependent sinuses are reinfected,
3. the narrow or stenotic areas involved are the ethmoidal infundibulum at the entrance of the maxillary sinus and the frontal recess at the entrance of the frontal sinus thus the anterior ethmoidal air cells (part of the ostiomeatal unit) play a significant part in the pathophysiology of recurrent rhinosinusitis.<sup>8</sup>

Functional endoscopic sinus surgery is base upon the theory and the concepts mentioned and its aim is to remove the disease of the ostiomeatal unit.<sup>2-4,7,8</sup>

The purpose of this report is to show the indication, the result and complication of endoscopic sinus surgery at Paholpolpayuhasaena hospital during May 1995 to October 1997.

## Materials and Method

A retrospective review of the patients who have undergone endoscopic sinus surgery in Paholpolpayuhasaena hospital during May 1995 - October 1997. The patient has done by Messerklinger technique under local or general anesthesia. Postoperative the patient received antibiotic, decongestant, nasal packing and come back to clean blood clot and secretion regularly. Endoscopic examination by 30 degree telescope was performed in the OPD for more detailed analysis.

## Results

During May 1995 - October 1997, 40 patients underwent endoscopic sinus surgery at Paholpolpayuhasaena hospital. The ages ranged from 9 to 62 years, with a mean of 30 years : 19 were male (47.5%) and 21 were female (51.5%). The patient underwent surgery for 43 operations (72 sinuses), 26 patients (65%) for bilateral sinus surgery, 9 patients (25.5%) for left side and 5 patients (12.5%) for right side, 9 cases (22.5%) did CT scan and 31 cases (77.5%) did not.

The diagnosis : 30 patients (75%) were nasal polyp and chronic sinusitis, 3 patients (7.5%) were chronic sinusitis without nasal polyp (the maxillary mucosa were polypoid with small polyp or retention cyst), 5 patients (12.5%) were choanal polyp, 1 patient (2.5%) was non-invasive fungal maxillary

sinusitis and 1 patient (2.5%) had mass in left nose was misdiagnosis to be polyp but the pathological section was squamous cell carcinoma, poorly differentiated and sent to radiation. 2 patients (5%) had previous intranasal polypectomy.

In the patients who had nasal polyp, intranasal polypectomy was initially performed, later the telescopes were used to view the endoscopic sinus surgery according to the techniques of Messerklinger and Stammberger.<sup>2,3</sup>

The operating time ranged from 45 minutes to 120 minutes, with a mean 80 minutes.

The period of hospitalization ranged from 2 to 5 days (mean 4 days). The follow up intervals ranged from 1 to 2 weeks at which symptomatic questioning, E N T examination and intranasal cleaning were done. The follow up periods ranged from 2 weeks to 15 months with a mean 4.5 months.

The postoperative symptomatic results were good, in that there was some or complete relief of nasal obstruction and reduction of the post nasal drip. There was improvement in the sinusitis, as evident on the nasal discharge (clear), paranasal sinus X-ray and symptomatic improvement. 5 patients had recurrence of nasal polyp and 3 patients were endoscopic surgeried again and all 3 got good result.

There was no operative or early operative complication in all 40 patients. None of the patients had significant haemorrhage and there was no ophthalmological complication eg. diplopia, loss of vision etc. There was no serious complication such as cerebrospinal fluid leak etc. Therefore the opera-

## Indication

Disease	Number of operations	Percent
chronic sinusitis with polyps	33	76.7
chronic sinusitis	3	7.0
chonal polyp	5	11.6
Fungal infection	1	2.3
Intranasal Squamous cell carcinoma	1	2.3
<b>Total</b>	<b>43</b>	

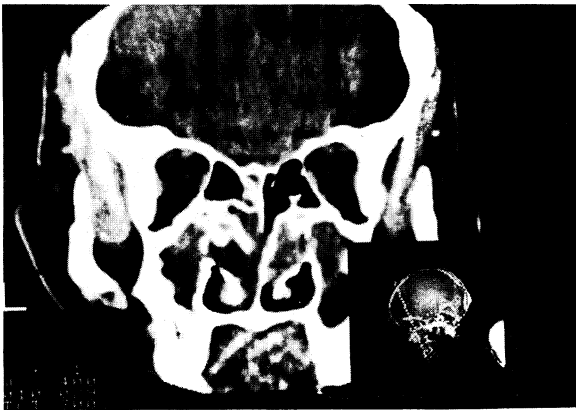


Figure 1 chronic sinusitis with polyp

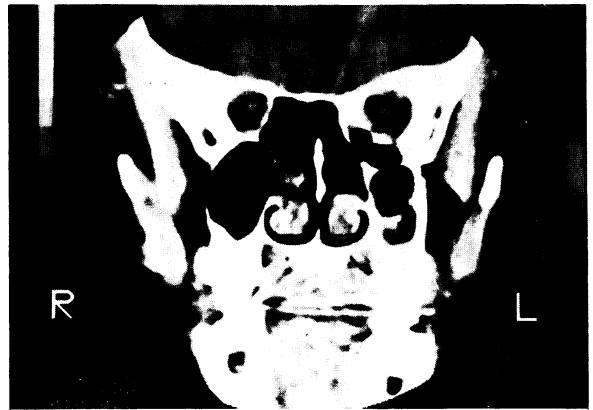

Figure 2 chronic sinusitis, polypoid mucosa and retentioncyst in maxillary sinus

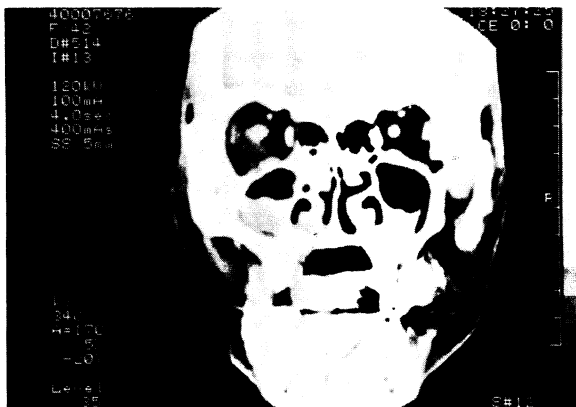


Figure 3 Fungal sinusitis

tive and postoperative complication rate was 0%.

## Discussion

To date endoscope are commonly use in the nose and paranasal sinus surgery. From the review articles, the indications are ;

1. Functional endoscopic sinus surgery for chronic sinusitis.<sup>2</sup>
2. Transnasal orbital decompression in Grave's disease.<sup>12</sup>
3. Epistaxis.<sup>13</sup>

4. Congenital choanal atresia.<sup>14</sup>
5. Dacryocystorhinostomy.<sup>15</sup>
6. Endoscope with KTP laser.<sup>16</sup>
7. Sphenoid sinus disease.<sup>17</sup>
8. Vidian neurectomy.<sup>18</sup>
9. CSF rhinorrhea.<sup>19,20</sup>
10. Antrochoanal polyp.<sup>21</sup>
11. Allergic rhinitis and chronic headache.<sup>22</sup>
12. Mycoses of paranasal sinus.<sup>22</sup>
13. Pituitary tumour.<sup>23</sup>

In Paholpolpayuhasaena hospital endoscopic sinus surgery was performed for the patients who were chronic sinusitis with or without polyp, 75% of the patients had polyp compared to the paper of Stammberger<sup>7</sup> who have 60% and 61.6% at Songklanagarind hospital.<sup>6</sup>

**Contraindications** ; The Messerklinger technique is not designed for the surgical approach to extensive invasive processes in the area of the paranasal sinuses or the skull base. Extensive bony changes such as a broadly based osteoma are also not suitable subjects for this technique.<sup>22</sup>

Functional endoscopic sinus surgery (FES) or endoscopic endonasal surgery has been performed at Graz university by Messerklinger and Stammberger more than elsewhere,<sup>3</sup> a total of more than 2,500 operations. They stated that :

- 1) blood losses were always negligible and never required administration of conserved blood<sup>3</sup>
- 2) to date, none of the patients has suffered injury to roof of the ethmoid or even the dura<sup>3</sup>
- 3) air emphysema in individual cases but this was always reabsorbed within a few days after

prescription of antibiotics and recommendation that the patient not to blow his nose.<sup>3</sup>

4) posterior ethmoid cells and especially the sphenoid sinus can be in close relation to the optic nerve<sup>2</sup>

5) if the agger nasi air cells are pneumatized, these cells may contact the lacrimal sac and if they extend towards the maxillary ostium, one might get close to the nasolacrimal duct<sup>2</sup>

6) most frequent problems are scars and synerchia in the operated ethmoid, especially between the turbinate head and the lateral nasal wall<sup>3</sup>

7) stenosis of the maxillary ostium is very rare<sup>3</sup>

8) diseased ethmoid cells that have not been completely evacuated or have been overlooked can of course cause polyps to recur or symptoms to persist.<sup>3</sup>

There has been no significant complication after endoscopic sinus surgery and polypectomy at Paholpolpayuhasaena hospital but the number is small (40 compared with over 2,500). 5 cases had residual and recurrent polyp, all 5 cases had no CT, compared with 9/105 at Songklanagarind hospital.<sup>6</sup> No one received blood transfusion. In Kennedy's experience of 40 patients who had FES, there was no serious intraoperative complication such as major bleeding, cerebrospinal fluid leak or visual problem. In Freedman and Kerns' review, major complications included 12 cases of haemorrhage, 1 meningitis and 1 cerebrospinal fluid leak.<sup>14</sup> Despite the low rate of complication, this should be a warning to those who wish to perform endoscopic sinus surgery.

The operating time when use endoscope was 45 min. to 120 min. (mean 80 min.) compare to the classic method (snaring &/or antrostomy) 30-60 min. (mean 45 min.) When use endoscope the operating time is longer may be from the less experience of the surgeon and may be improve continuously. The more advantage of the endoscopic technique is the low recurrent rate, maintain better anatomy, good ventilation and drainage of the sinus, no need for blood transfusion and can do under local anaesthesia. The cost of endoscopic sinus usrgery is more in the starting for endoscopes and some surgical instruments but in the long term due to better result, low recurrent rate, less time for hospitalization and low complication, the use of endoscope is very valuable.

## Summary

Endoscopic sinus surgery is one of the standard surgery now use in Paholpolpayuhasaena hospital for intranasal and sinus disease and have good result and low complication. But the surgeon must try to improve diagnosis ability and gain more experience to reduce number of recurrent disease, get good result and low complication.

## References

1. Messerklinger W. Endoscopy of the nose. Baltimore/ Munich : Urban & Schwarzenberg, 1978.
2. Stammberger H. Endoscopic surgery for mycotic and chronic recurring sinusitis. *Ann Otol Rhinol Laryngol* 1985 ; 94 (supplement part 2) : 1-11.
3. Stammberger H. Endoscopic endonasal surgery- Concepts in treatment of recurring rhinosinusitis (Part II) Surgical technique. *Otol Head & Neck Surg* 1986 ; 94 : 147-56.
4. Kennedy DW. Functional endoscopic surgery-technique. *Arch Otolaryngol* 1985 ; 111 : 643-9.
5. Muntrabhorn K. Functional endoscopic sinus surgery. *Ramathibodi Med J* 1987 ; 10 : 171-5.
6. Prukpitigul S, Peeravud S, Bunyapipatra P, Seung-sontiporn S, Preuksanusak K, Chittumnan P. Endoscopic sinus surgery : experience at Songklanagarind Hospital. *Otolaryngology-Head & Neck Surgery* 1992 ; 7(1) : 37-40.
7. Messerklinger W. About the frontal recess and his clinic. *Laryngol Rhinol Otol* 1982 ; 61: 217-24.
8. Stammberger H. Endoscopic endonasal surgery - Concepts in treatment of recurring rhinositis[part I]. Anatomical and pathophysologic considerations. *Otolaryng Head & Neck Surg* 1986 ; 94 : 143-6.
9. Kennedy DW, Zinreich J, Rosenbaum AE, Johns ME. Functional endoscopic sinus surgery Theory and Diagnostic Evaluation. *Arch Otolaryngol* 1985 ; 111 : 576-82.
10. Karma P, Jokipii L, Sipila P, Luotonen J, Jokipii AMM. Bacteria in Chronic Maxillary Sinusitis. *Arch Otolaryngol* 1979 ; 105 : 386-90.
11. Naumann HH. Pathological anatomy of chronic rhinitis and sinusitis. *Proceeding VII International Congress Series number 113. Amsterdam/Newyork : Exerpta Medica Foundation, 1965.*
12. Kennedy DW, Goodstein ML, Zinreich SJ. Endoscopic transnasal orbital decompression. *Arch Otolaryngol Head Neck Surg* 1990 ; 116 : 275-82.
13. Marcus MJ. Nasal endoscopic control of epistaxis A preliminary report. *Otol Head and Neck Surg* 1990 ; 102 : 273-5.

14. Stankiewicz JA. The endoscopic repair of choanal atresia. *Otol Head and Neck Surg* 1990 ; 100 : 1344-7.
15. Metson R. The endoscopic approach for revision dacryocystorhinostomy. *Laryngoscope* 1990 ; 100 : 1344-7.
16. Levine HL. Endoscopy and the KTP/532 laser for nasal sinus disease. *Ann Otol Rhinol Laryngol* 1989 ; 98 : 46-51.
17. Stankiewicz JA. The endoscopic approach to the sphenoid sinus. *Laryngoscope* 1989 ; 99 : 218-21.
18. Shazly MA. Endoscopic surgery of the vidian nerve. preliminary report. *Ann Otol Rhinol Laryngol* 1991 ; 100 : 536-9.
19. Papay FA, Maggiano H, KominQuez S, Hassenbusch SJ, Levine HL, Lavertu P. Rigid endoscopic repair of paranasal sinus cerebrospinal fluid fistulas. *Laryngoscope* 1989 ; 99 : 1195-201.
20. Mattox DE, Kennedy DW. Endoscopic management of cerebrospinal fluid leaks and cephaloceles. *Laryngoscope* 1990 ; 100 : 857-62.
21. Kamel R. Endoscopic transnasal surgery in antrochoanal polyp. *Arch Otol Head Neck Surg* 1990 ; 116 : 841-3.
22. Stammberger H. *Functional endoscopic sinus surgery* 1st ed. Philadelphia : BC Decker, 1991: 1-529.
23. Jankowski R, Augue J, Simon C, Marshal JC, Hepner H, Wayoff M. Endoscopic pituitary tumor surgery. *Laryngoscope* 1992 ; 102 : 198-202.
24. Freedman HM, Kern EB. Complication of intranasal ethmoidectomy : a review of 1,000 consecutive operations. *Laryngoscope* 1979 ; 89 : 421-34.
25. Muntarhorn K. Early experience with microscopic and endoscopic ethmoidal surgery. Printed abstracts handed out at the annual Thai ORL meeting : 7 August 1987.
26. Maniglia AJ, Chandler JR, Goodwin WJ, Flynn J. Rare complications following ethmoidectomies : a report of 11 cases. *Laryngoscope* 1981 ; 91 : 1234-44.