

Case report

Cholesteatoma of the Maxillary Sinus

Watcharaporn Burchom and Pariyanun Jaruchinda

Department of Otorhinolaryngology, Phramongkutklao Hospital

Abstract

Cholesteatoma is a relatively common pathology in the middle ears and mastoid cavity, but is a rare disease for the paranasal sinuses, especially in the maxillary sinus. The cholesteatoma of the paranasal sinus should be considered in the differential diagnosis of slowly expanding lesions of the sinuses and is difficult to distinguish from paranasal sinus malignancy. The author describes a rare case of cholesteatoma in the maxillary sinus of an elderly woman presenting swelling at hard palate over 3 months. The swelling began at the right side hard palate and gradually enlarged over 2 months. She had right side facial swelling and nasal obstruction. Several biopsies were performed under local anesthesia using the transnasal, sinuscope and sublabial approaches (Caldwell-luc). The last histopathological report showed consistency with cholesteatoma. The patient was operated by medial maxillectomy and complete tumor removal. The patient experienced disease free survival about 18 months and afterwards she died from cerebrovascular disease. This is the second case in Asia and first case reported in Southeast Asia.

Keywords: ● Cholesteatoma ● Maxillary sinus ● Medial maxillectomy ● Caldwell-luc

RTA Med J. 2019;72(1):83-88.

Received 14 December 2018 Corrected 4 January 2019 Accepted 7 February 2019

Correspondence should be addressed to Maj. Watcharaporn Burchom, MD., Department of Otorhinolaryngology, Phramongkutklao Hospital, Ratchathewi, Bangkok 10400 E-mail: wat_bour03@hotmail.com

Introduction

Cholesteatoma of the maxillary sinus occurs when the normal respiratory epithelium (ciliated pseudostratified columnar epithelium) that lines the sinus is replaced by keratinized squamous epithelium.

The first reported cholesteatoma of the maxillary sinus was by Hutcheon¹ in 1941. He considered it a malignant lesion because of its erosive nature and rapid uncontrolled growth. Therefore, the differential diagnosis of any lesion within the maxillary sinus is important. Current theories of pathogenesis suggest that cholesteatoma can be either congenital or acquired.

Case report

A 74-year-old woman presented underlying dyslipidemia, gouty arthritis, hypertension and deep vein thrombosis (DVT) of the left leg due to immobilization. She presented swelling at hard palate over three months. The swelling began slowly at the right side of the hard palate. It became gradually larger over two months. She had right side facial swelling and nasal obstruction. She visited the dentist clinic because she could not fit the obturator in her mouth and lost one tooth about four month earlier. She had no history of facial trauma, nasal discharge, chronic sinusitis or sinonasal surgery.

On physical examination, she presented right facial swelling, a small ulcer on the right side of her face (Figure 1) and bulging hard palate on the right side 3 cm. in diameter. Examination of the right nasal cavity revealed that the medial wall had encroached on the septum and had completely obstructed the nasal cavity. Eye examination and facial sensation were normal. The other ENT examinations and blood tests were normal.

Computed tomography (CT) scan of the paranasal sinuses demonstrated a large heterogenous enhanced lesion at the right hard palate and maxillary sinus with bony destruction measuring 5.5 x 5.3 x 5 cm. in transverse, AP and vertical diameters, respectively (Figure 2). Medially, the expanded

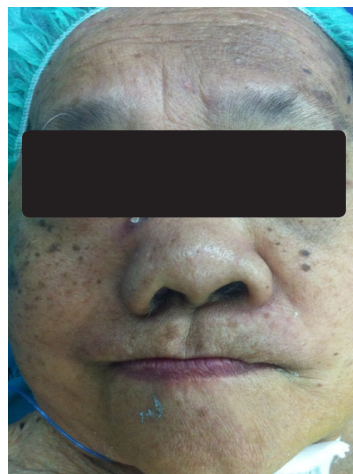

Figure 1 show right facial swelling and small ulcer on the right side of her face

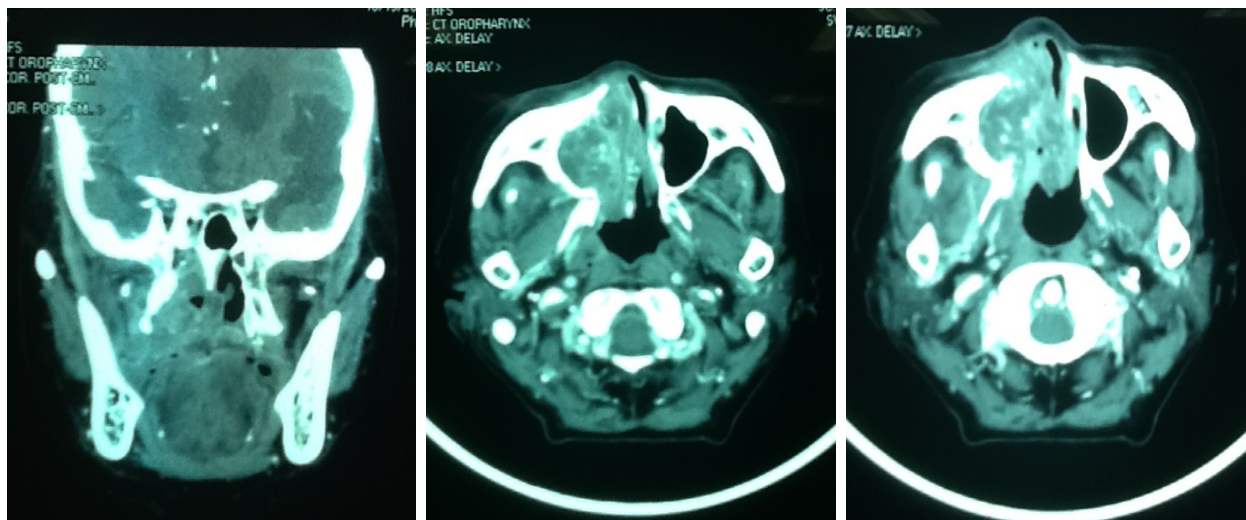


Figure 2 : Show CT scan paranasal sinus coronal and axial view

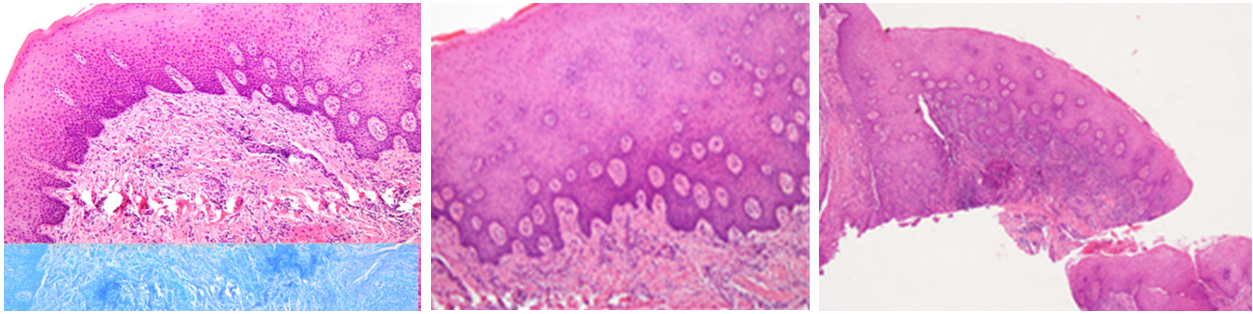


Figure 3 The histopathological report show hyperplastic squamous epithelium with hyperkeratosis, focal hypergranulosis, acute and chronic inflammation, consistent with cholesteatoma of maxillary sinus.

sinus had encroached the nasal cavity abutting the nasal septum and contralateral side. Laterally, involvement and bony destruction was observed of the right maxillary sinus. Inferiorly, a bony density lesion in the right maxillary sinus involved the right side of the hard palate. Anteriorly, it extended beyond the right maxilla and maxillary sinus, from the nasal cavities to the subcutaneous tissue. No extension in the orbit was seen, and the other sinuses were normal.

Several biopsies were performed under local anesthesia using transnasal and sinuscope through the inferior meatus. The histopathological report showed squamous mucosal hyperplasia, acute and chronic inflammation and no neoplasm or dysplastic change was seen. The last biopsy using the sublabial approach (Caldwell-luc) was performed. The histopathological report showed consistency with cholesteatoma (Figure 3).

A medial maxillectomy was performed under general anesthesia. Grayish-white debris was seen in the right maxillary sinus protruding through the eroded anteromedial wall and floor of the maxillary sinus. The anterior wall of the maxillary sinus was opened and one tooth was found in the right maxillary sinus. The tooth, sac and its contents were removed. The patient was followed up for 18 months and no evidence of recurrence was observed. Afterwards she died from cerebrovascular disease, so the patient had disease free survival for about 18 months.

Discussion

Cholesteatoma of the maxillary sinus is a rare condition. Hutcheon¹ reported the first case of maxillary sinus in 1941. The symptoms and signs were more suggestive of carcinoma of the antrum and adjacent nasal wall. This finding means that despite its rarity, this non-neoplastic entity should at least be considered in the differential diagnosis of any erosive lesion of the maxillary sinus. Haeggstrom² reported the first case of frontal sinus cholesteatoma in a patient with proptosis and diplopia in 1961. The frontal sinus is the most common site of origin followed by the ethmoid sinus, while maxillary sinus involvement is rare.³⁻⁶ This patient is the first reported in Southeast Asia and the second case in Asia.

The pathogenesis of cholesteatoma⁷ can be either congenital or acquired. Four basic theories have been reported as described below. First, the theory of congenital epithelial rests (1854) Remark and Bucy states that cholesteatomas arise from misplaced epithelial rests that develop during the embryonic stage. Second, the metaplasia theory (1873) Wendt theorizes that the nonkeratinizing squamous epithelium that lines a cavity undergoes a metaplastic change, possibly in response to infection and begins to produce keratin. Third, the immigration theory (1888) Habermann hypothesized that cholesteatoma is caused by the migration of keratinizing squamous epithelium in an area where it would not

usually be found. Last, the implantation theory (1928) Ewing proposes that cholesteatomas arise secondary to the direct entry of epithelium during trauma. Cholesteatomas have been reported to occur at the site of a previous injury and after nasal or sinus surgery.

Regarding other characteristics, the cholesteatomas are not biologically neoplastic. It has the capacity to erode bone and expand into adjacent areas. The capacity to erode bone has been attributed to enzymes.^{3-5,8} In 1962, Harris⁹ demonstrated two proteolytic enzymes; leucine aminopeptidase and a nonspecific esterase in the subepithelial layer of cholesteatomas. Recently, further investigations in bony erosions of cholesteatomas have highlighted the role of cytokines such as TNF α . This cytokine is thought to act directly on bone and indirectly by stimulating the release of proteolytic enzymes. These studies have only been performed on temporal bone cholesteatomas and further investigation of paranasal sinus cholesteatomas is required.¹⁵

The cause of cholesteatoma in this patient should have been from immigration or implantation theory because the author found the tooth in the maxillary sinus; therefore, the keratinize squamous epithelium in the oral cavity may migrate to the maxillary sinus.

The clinical presentations are difficult to distinguish from those of malignancy.³ The presenting symptoms, possibly occurring as a result of the interaction between bone erosion and infection, determined by the anatomic relationship of the maxillary antrum (including the orbit, nasal cavity, teeth and mouth) and the pterygomaxillary space.⁵ Symptoms are caused by the expansion of the lesion. As the cholesteatoma grows, pain becomes more severe. The differential diagnosis includes both non-neoplastic lesions (mucocoele, mucus retention cyst, pyocoele and pseudocyst) and neoplastic lesions may be benign or malignant.

The appropriate treatment for cholesteatoma is surgery. The procedure of choice for maxillary sinus cholesteatoma is Caldwell-Luc surgery.³⁻⁵ The wall of the cholesteatoma should be completely removed to stop further erosion of the surrounding structures and to prevent recurrence.² To avoid long term complications, adequate drainage and sinusotomy for postoperative follow-up are recommended.⁶

This patient's right medial maxillectomy was operated on because one time she received the Caldwell-luc operation and we found rather large tumor involved superiorly nearly at the floor of orbit and had a tooth in the lateral part of maxillary sinus. The small ulcer on the skin was cut at the surgical wound and the cholesteatoma sac was removed including one tooth and open drainage for follow up.

Conclusion

Cholesteatoma of the maxillary sinus is a rare condition. Remembering and considering the differential diagnosis of slowly expanding and erosive lesions of the maxillary sinus is important. Distinguishing from paranasal sinus malignancy remains difficult. Appropriate treatment of cholesteatoma is surgery, complete removal and adequate drainage.

Reference

1. Hutcheon JR. A case of rhinolith combined with cholesteatoma of the maxillary antrum. *Med J Aust.* 1941;1:451.
2. Haeggstrom AA. Cholesteatoma removed from the maxillary sinus. *Hygiea.* 1916;78:1122.
3. Storper IS, Newman AN. Cholesteatoma of the maxillary sinus. *Arch Otolaryngol Head Neck Surg.* 1992;118:975-7.
4. Campanella RS, Caldarelli DD, Friedberg SA. Cholesteatoma of the frontal and ethmoid areas. *Ann Otol Rhinol Laryngol.* 1979;88:518-23.
5. Pogorel BS, Budd EG. Cholesteatoma of the maxillary sinus: A case report. *Arch Otolaryngol.* 1965;82:532-4.

6. Hartman JM, Stankiewicz JA. Cholesteatoma of the paranasal sinuses: Case report & review of the literature. *Ear Nose Throat J.* 1991;70:719-25.
7. Viswanatha B, Nayak LK, Karthik S. Cholesteatoma of the maxillary sinus. *Ear Nose Throat J.* 2007;86:351-3.
8. Chole RA, Choo MJ. Chronic otitis media, mastoiditis and petrositis. In: Cummings CW, Fredrickson JM, Harker LA, et al. eds, *Otolaryngology- Head and Neck Surgery*, 3rd ed. St. Louis: Mosby. 1998:3026-46.
9. Harris AJ. Cholesteatosis and chronic otitis media. *Laryngoscope.* 1962;72:954-980.
10. Mohamed SA, Hussein FW, Zakhary MM. Clinical and biochemical studies of bone destruction in cholesteatoma. *J Laryngol Otol.* 1996;110:534-9.
11. Wenig BL, Sciubba JJ, Zielinski BZ, et al. Mucin impaction tumor of the paranasal sinuses: A new clinical entity. *Laryngoscope.* 1983;93:621-6.

