

## Original article

# The effect of Ki67 visual scale to improve accuracy of Ki67 index estimation in breast cancer

Padol Chamninawakul, Pongsada Prasonguppatum and Songkhun Vinyuvat

Institute of Pathology, Department of Medical Services, Ministry of Public Health

### Abstract:

**Background:** The Ki67 index is an important prognostic marker in breast cancer. The current Ki67 index estimation by unaided optical microscope is widely criticized on the grounds of high inter-observer and intra-observer variability. For more accurate assessment, we create the Ki67 visual scale by using figures from digital image analysis. The aim of this study was to validate the effect of Ki67 visual scale to improve the accuracy of Ki67 index estimation in breast cancer. **Methods:** This is an experimental study including 30 cases diagnosed with invasive breast carcinoma. The Ki67 index was determined using digital image analysis. Manual Ki67 scoring by visual estimate was performed with and without the aid of Ki67 visual scale sheet. Inter-observer agreements between Ki67 index by visual estimate (with and without Ki67 visual scale) and by digital image analysis were assessed using Kendall's correlation coefficients and scatterplots. **Results:** Correlation for inter-observer agreement between visual estimate without scale sheet and digital image analysis revealed an almost perfect agreement with a Kendall's correlation coefficient of 0.826 ( $p < 0.01$ ), whereas the correlation between visual estimate with scale sheet and digital image analysis also revealed an almost perfect agreement but with a Kendall's correlation coefficient of 0.950 ( $p < 0.01$ ). Although the correlation coefficients of both comparisons similarly revealed an almost perfect agreement, the correlation for inter-observer agreement between visual estimate with scale sheet and digital image analysis was even higher. **Conclusions:** Ki67 visual scale would appear to improve the accuracy and reproducibility of Ki67 index estimation using optical microscope in breast cancer patients. Such study would help define a practical tool for more standardized Ki67 index estimation by optical microscope.

**Keywords:** ● Breast cancer ● Ki67 index ● Digital image analysis ● Ki67 visual scale ● Immunohistochemistry ● Visual estimate ● Manual scoring

**RTA Med J 2022;75(2):79-86.**

Received 9 December 2021 Corrected 25 March 2022 Accepted 31 March 2022

Corresponding Author: Dr Padol Chamninawakul, Institute of Pathology, Department of Medical Services, Ministry of Public Health, 2/2 Phayathai road, Thung-Phayathai, Ratchathewi, Bangkok 10400. Telephone: +66 (0) 95 954 9591 Email: Padol14331@hotmail.com

## นิพนธ์ต้นฉบับ

# ผลของการใช้เกณฑ์บอกขนาด Ki67 เพื่อเพิ่มความแม่นยำในการประเมินค่าดัชนี Ki67 ในผู้ป่วยมะเร็งเต้านม

ภาดล ชำนินาวกุล พงษ์ภา ประสงค์อุปถัมภ์ และ ทรงคุณ วิญญูวรรณ

สถาบันพยาธิวิทยา กรมการแพทย์ กระทรวงสาธารณสุข

### บทคัดย่อ

**วัตถุประสงค์** การตรวจวัดค่าดัชนีการเพิ่มจำนวนของเซลล์ “Ki67” มีความสำคัญในการช่วยพยากรณ์โรคในผู้ป่วยมะเร็งเต้านมเฉพาะราย ในปัจจุบันการประมาณค่าดัชนี Ki67 ยังคงค่อนข้างขึ้นอยู่กับอัตวิสัยของพยาธิแพทย์แต่ละบุคคล ผู้วิจัยจึงได้สร้าง “เกณฑ์บอกขนาด Ki67” ขึ้นโดยใช้มาตรฐานส่วนจากการประมวลผลภาพดิจิทัล โครงการวิจัยนี้จึงทำขึ้นเพื่อศึกษาผลของการใช้เกณฑ์บอกขนาด Ki67 ในการเพิ่มความแม่นยำของการประเมินค่าดัชนี Ki67 ในผู้ป่วยมะเร็งเต้านม **วิธีการศึกษา** งานวิจัยนี้เป็นการวิจัยเชิงทดลองในผู้ป่วยจำนวน 30 ราย ทำการประเมินค่าดัชนี Ki67 ด้วยการประมวลผลภาพดิจิทัล จากนั้นพยาธิแพทย์ผู้ร่วมวิจัยประเมินค่าดัชนี Ki67 ด้วยกล้องจุลทรรศน์ โดยใช้และไม่ใช้เกณฑ์บอกขนาด Ki67 ประกอบการประเมิน วิเคราะห์ความสอดคล้องระหว่างค่าดัชนี Ki67 จากการประเมินด้วยกล้องจุลทรรศน์โดยใช้และไม่ใช้เกณฑ์บอกขนาด Ki67 ประกอบการประเมิน เทียบกับการประเมินด้วยการประมวลผลภาพดิจิทัล โดยใช้ค่าสัมประสิทธิ์สหสัมพันธ์ของ Kendall **ผลการศึกษา** ค่าสัมประสิทธิ์สหสัมพันธ์ระหว่างค่าดัชนี Ki67 จากการประเมินด้วยกล้องจุลทรรศน์โดยใช้เกณฑ์บอกขนาด Ki67 ประกอบการประเมิน เทียบกับการประเมินด้วยการประมวลผลภาพดิจิทัล นั้น มีค่ามากกว่า ค่าสัมประสิทธิ์สหสัมพันธ์ระหว่างค่าดัชนี Ki67 จากการประเมินด้วยกล้องจุลทรรศน์โดยไม่ใช้เกณฑ์บอกขนาด Ki67 ประกอบการประเมิน เทียบกับการประเมินด้วยการประมวลผลภาพดิจิทัล อย่างมีนัยสำคัญทางสถิติ **สรุป** เกณฑ์บอกขนาด Ki67 สามารถเพิ่มความแม่นยำของการประเมินค่าดัชนี Ki67 ด้วยกล้องจุลทรรศน์ และสามารถนำมาใช้ในเวชปฏิบัติอันจะนำไปสู่แนวทางการประเมินค่าดัชนี Ki67 ด้วยกล้องจุลทรรศน์ที่ได้มาตรฐานมากขึ้น

**คำสำคัญ:** ● มะเร็งเต้านม ● ดัชนี Ki67 ● เกณฑ์บอกขนาด Ki67 ● การประมวลผลภาพดิจิทัล ● อิมมูโนฮิสโตเคมี

**เวชสารแพทย์ทหารบก 2565;75(2):79-86.**

ได้รับต้นฉบับเมื่อ 9 ธันวาคม 2564 แก้ไขบทความ 25 มีนาคม 2565 ได้ตีพิมพ์เมื่อ 31 มีนาคม 2565

ผู้รับผิดชอบหลัก ภาดล ชำนินาวกุล สถาบันพยาธิวิทยา กรมการแพทย์ กระทรวงสาธารณสุข Email: Padol14331@hotmail.com

## Introduction

Breast cancer is the most frequent cancer in women worldwide, and one of the leading causes of cancer-associated morbidities and mortalities<sup>1</sup>. Anatomical pathology plays one of the most critical roles for patient management and diagnosis of breast cancer.

Ki67 is a nuclear antigen which is present in all except the G0 phase of the cell cycle and therefore expressed in proliferating cells. Immunohistochemistry for Ki67 can be used to determine tumor proliferation index<sup>2</sup>. Ki67 is an important prognostic and predictive marker in breast cancer patients used in international therapy guidelines<sup>3-4</sup>. Therefore, accurate estimation of the Ki67 index is very important for proper management of patients with breast cancer.

In routine practice, Ki67 scoring is often performed on the whole tissue sections, and is also recommended by the International Ki67 in Breast Cancer Working Group<sup>4</sup>. Nevertheless, the current Ki67 index estimation by unaided optical microscope is widely criticized on the grounds of high inter-observer and intra-observer variability<sup>5-8</sup>. Besides, manual counting is time-consuming since at least 500-1,000 cells must be counted to achieve acceptable error rates<sup>3-4</sup>.

Digital pathology is now an emerging approach used in many tasks since microscopic images contain a huge amount of data that can be gained by multitudinous methods to visualize tissue and its components by processing the scanned images<sup>9-10</sup>. Digital image analysis can open new perspectives for pathology to serve the needs of personalized medicine, by providing more accurate and reproducible measurements for tissue-based diagnosis, prognosis, and prediction<sup>8</sup>.

Many studies are now proposing digital image analysis as an efficient method of Ki67 index estimation, with benefits of increased precision and accuracy in comparison with visual estimate<sup>11</sup>. Recent studies showed that

automated assessment of Ki67 index correlates better with clinical and pathological characteristics of breast cancer as well as the prognostic factors<sup>12</sup>.

However, the cost of digital image analysis would seem to be expensive, as it requires a scanner for digitalization of the images, digital image analysis software, and a technician to carry out the analysis<sup>13</sup>. Furthermore, the calibration is also the key to success of digital image analysis as it needs machine learning<sup>8</sup>. Such optimal calibration would require close collaboration between the pathologist who has clinical expertise and the platform engineer who has technical expertise<sup>13</sup>.

To define more practical and simplified tools for routine uses in centers with more limited resources, we create the Ki67 visual scale by using figures from digital image analysis software to assist the Ki67 index estimation by optical microscope. Our Ki67 visual scale was also confirmed by manual counting. The aim of this study was to validate the effect of Ki67 visual scale to improve the accuracy of Ki67 index estimation in breast cancer.

## Materials and methods

### Ethics and patients

The study was approved by the Research Ethics Committee, Institute of Pathology, Department of Medical Services. We analyzed 30 cases of invasive breast carcinoma collected from the Institute of Pathology, Department of Medical Services in 2020. Histologic sections and Ki67-immunostained slides were obtained from paraffin blocks of 30 specimens. All of the Ki67-immunostained slides were scanned using the slide scanner (3D-Histech, P-1000) present in the Institute of Pathology, Department of Medical Services. All samples were processed in a pathology laboratory consistent with the standardized institutional protocols. All data were anonymized once we collected them. Patient's

age ranges between 33 and 79 years old. Patients whose Ki67-immunostained slides were not performed and those diagnosed with only carcinoma in situ were excluded from the study.

### Digital image analysis

The whole scanned sections were examined then the resident pathologist selected particular areas. Areas which were rich in tumor cells were preferably chosen. Areas showing necrosis or significant lymphocytic infiltration were avoided to reduce false positive results. Eventually, a digital image analysis of Ki67 index was performed corresponding to the digital quantitative assessment of the percentage of the positive tumor cells for Ki67 using 3D-Histech software called *QuantCenter*. The software made the color image marking stained and unstained nuclei according to the parameters calibrated for the analysis and provided a percentage of positive nuclei. Then the final value of Ki67 index was calculated by taking the arithmetic mean of all particular areas for each case individually by means of the whole slide scoring protocol.

### Visual estimate

Ki67 index estimation by optical microscope (Olympus, BX-51) were performed as followed. Firstly, all Ki67-immunostained slides were assessed by a pathologist during routine reading. Secondly, at least three months later, the pathologist was asked to re-estimate the Ki67 index for each of the 30 cases with the aid of *Ki67 visual scale sheet* (Figure 3). The Ki67 index was estimated using the whole slide scoring protocol in all cases. The pathologist performed Ki67 index estimation independently and was blinded to the previous estimated values as well as the patient outcome.

### Statistical analysis

Kendall's correlation coefficients were calculated for the inter-observer agreement between Ki67 index by visual estimate without the aid of Ki67 visual scale sheet

and Ki67 index by digital image analysis, then the study of agreement between Ki67 index results provided by using visual estimate with the aid of Ki67 visual scale sheet in comparison to digital image analysis was done. Scatterplots were created to assess the inter-observer correlation in relation to data ranges. Statistical analysis and scatterplots formation were performed using IBM SPSS Statistics for Windows version 20. All testing was two sided.  $p$ -values  $< 0.01$  were considered significant. There is no standard criteria for correlation coefficients. The following criteria, similar to the kappa coefficient, were used here to aid interpretation: 0.00-0.20 was interpreted as "slight correlation"; 0.21-0.40 as "fair correlation"; 0.41-0.60 as "moderate correlation"; 0.61-0.80 as "substantial correlation"; and  $> 0.80$  as "almost perfect correlation"<sup>14</sup>.

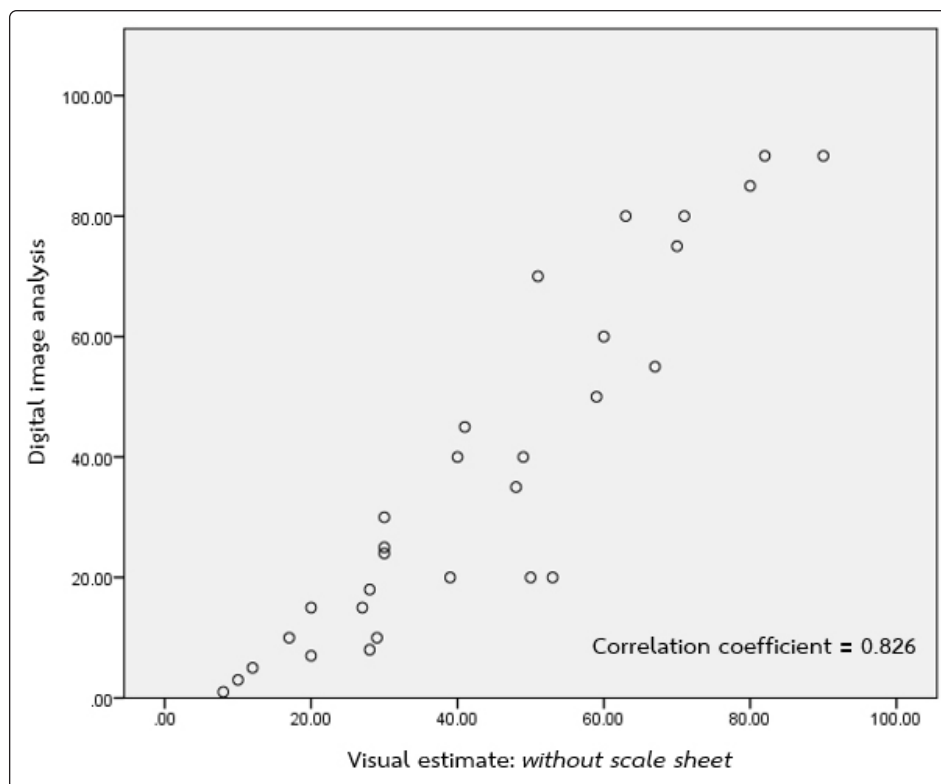
## Results and discussion

Scatterplot of visual estimate *without scale sheet* compared to digital image analysis is displayed in Figure 1. Correlation for inter-observer agreement between visual estimate *without scale sheet* and digital image analysis revealed an almost perfect agreement with a Kendall's correlation coefficient of 0.826 ( $p < 0.01$ ).

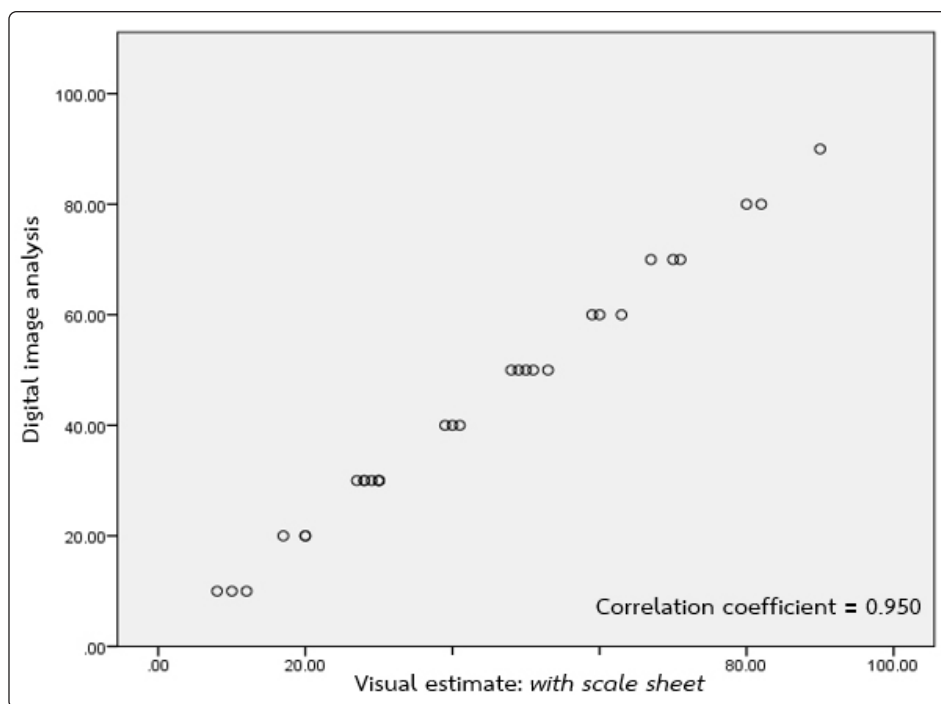
Scatterplot of visual estimate *with scale sheet* compared to digital image analysis is displayed in Figure 2. Correlation for inter-observer agreement between visual estimate *with scale sheet* and digital image analysis revealed an almost perfect agreement with a Kendall's correlation coefficient of 0.950 ( $p < 0.01$ ).

Although the correlation of both comparisons similarly revealed an almost perfect agreement, the correlation for inter-observer agreement between visual estimate *with scale sheet* and digital image analysis was even higher, as shown in Table 1.

By summarizing all of these data, it seems that Ki67 visual scale can improve the inter-observer variability and consistency in Ki67 index assessment by visual estimate.



**Figure 1** Correlation between visual estimate of Ki67 index on optical microscope *without the aid of Ki67 visual scale sheet* and digital image analysis results

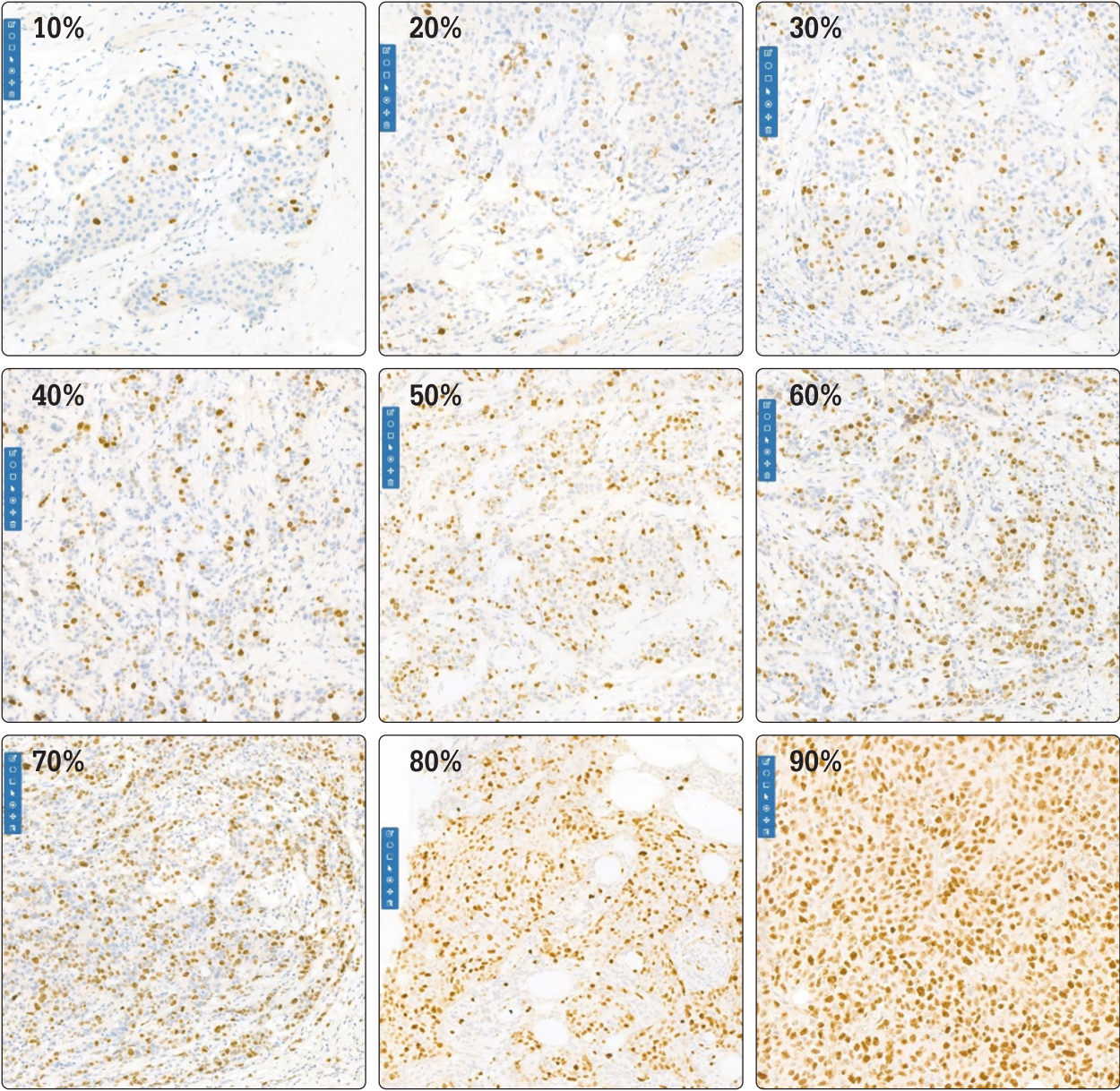


**Figure 2** Correlation between visual estimate of Ki67 index on optical microscope *with the aid of Ki67 visual scale sheet* and digital image analysis results



**Table 1** Correlation between visual estimates of Ki67 index on optical microscope (with and without Ki67 visual scale sheet) and digital image analysis results

		Digital image analysis	
		Correlation Coefficient	Significance
Visual estimates	Without scale sheet	0.826	0.0001**
	With scale sheet	0.950	0.0001**



**Figure 3** Ki67 visual scale sheet

Through our study, we noticed possible problems in visual estimate without the aid of the Ki67 visual scale sheet as followed. Heterogeneity was the most common difficulty. The peripheral tumor areas are more likely to have higher Ki67 index. Biopsied specimens are always problematic seeing that they often have relatively few tumor cells that are interrupted by stroma. Area selection remains the most crucial aspect of Ki67 index estimation yet area selection is always accompanied by selection bias unless the entire slide is assessed. For the most part, the accuracy of the Ki67 index estimation relies on the number of cells estimated, which is a critical parameter in Ki67 quantification by digital image analysis. Thus, assessing the whole slide section is a way to solve the heterogeneity problems. Accordingly, in practice, we recommended that the Ki67 visual scale sheet would help pathologists assess more areas multiple times that at least 1,000 tumor cells are counted. Pathologists are advised to cautiously consider area selection and may try to estimate more areas multiple times with Ki67 visual scale to improve the accuracy of Ki67 index estimation by optical microscope.

The other problem was interpretation error in visual estimate. Mostly, pathologists have their own individual threshold in Ki67 index visual estimate during their routine reading. We think that the use of Ki67 visual scale sheet can ameliorate the interpretation error seeing that the Ki67 visual scale can adjust individual pathologist's threshold to be more precise.

On the contrary, digital image analysis was also problematic. The most frequent problem was misidentification of tumor cells. Ki67-negative tumor cells were not identified in a few cases. This might have been due to weak hematoxylin staining and limitation of the digital image analysis software algorithm<sup>15</sup>. In addition, tumor cells whose nuclei are markedly pleomorphic or possess a dumbbell-shaped morphology were typically detected as two cells.

Another problem in an automated method was misidentification of non-tumor cells as Ki67-negative tumor cells. Digital image analysis can misidentify stromal cells and lymphocytes as tumor cells; ergo, they were misinterpreted as Ki67-negative tumor cells. Thereupon, it was beneficial that lymphocytes and stromal cells were excluded from the estimated area as far as was reasonably practicable. Nevertheless, lymphocytes and stromal cells were unavoidably included in a certain number of cases.

Poor Ki67 immunostaining quality also caused difficulty. Possible causes of this particular issue are poor tissue fixation, poor tissue processing, thick slices due to abundant adipose tissue, et cetera. Poor fixation can also cause an alteration of tumor cells to display spindling morphology which could be difficult to distinguish them from stromal cells on digital image analysis.

When we recognized these errors during the process, we re-calibrated the digital image analysis software's preanalytical parameters; then, re-analyzed and contemplated whether the digital image analysis result was appropriate. To overcome these abovementioned issues, we think that the semi-automated evaluation of Ki67 index would allow determination of the exact proliferation index value by marking optimal regions of interest as well as the stained and unstained nuclei manually then the cells are automatically counted and the percentage between the positive and negative cells gives the most precise Ki67 index value. In this way, the digital image analysis is quite time-consuming as well.

In our study, we manually selected the case that was not problematic to create the Ki67 visual scale by automated analysis with a confirmation by manual counting, hence the visual estimate of Ki67 index with the aid of the Ki67 visual scale sheet is indeed a great combination of superiority from not only automated but also manual scoring.

### Conclusion

To summarize, Ki67 visual scale would appear to improve the accuracy and reproducibility of Ki67 index estimation using optical microscope in breast cancer patients. Such study would help define a practical tool for more standardized Ki67 index estimation by optical microscope.

### Acknowledgements

We would like to thank the Institute of Pathology, Department of Medical Services, Ministry of Public Health. No additional funding resource was involved.

### References

1. American Cancer Society. *Global Cancer Facts & Figures*. 3<sup>rd</sup> Edition. Atlanta: American Cancer Society; 2015. p. 37
2. Gerdes J, Lemke H, Baisch H, Wacker HH, Schwab U, Stein H. Cell cycle analysis of a cell proliferation-associated human nuclear antigen defined by the monoclonal antibody Ki-67. *J Immunol*. 1984;133(4):1710-15.
3. Denkert C, Budczies J, von Minckwitz G, Wienert S, Loibl S, Klauschen F. Strategies for developing Ki67 as a useful biomarker in breast cancer. *Breast*. 2015;24(Suppl 2):S67-72. doi: 10.1016/j.breast.2015.07.017.
4. Dowsett M, Nielsen TO, A'Hern R, Bartlett J, Coombes RC, Cuzick J, et al; International Ki-67 in Breast Cancer Working Group. Assessment of Ki67 in breast cancer: recommendations from the International Ki67 in Breast Cancer working group. *J Natl Cancer Inst*. 2011;103(22):1656-64. doi: 10.1093/jnci/djr393.
5. Polley MY, Leung SC, McShane LM, Gao D, Hugh JC, Mastropasqua MG, et al; International Ki67 in Breast Cancer Working Group of the Breast International Group and North American Breast Cancer Group. An international Ki67 reproducibility study. *J Natl Cancer Inst*. 2013;105(24):1897-1906. doi: 10.1093/jnci/djt306.
6. Polley MY, Leung SC, Gao D, Mastropasqua MG, Zabaglo LA, Bartlett JM, et al. An international study to increase concordance in Ki67 scoring. *Mod Pathol*. 2015;28(6):778-86. doi: 10.1038/modpathol.2015.38.
7. Leung SCY, Nielsen TO, Zabaglo L, Arun I, Badve SS, Bane AL, et al; International Ki67 in Breast Cancer Working Group of the Breast International Group and North American Breast Cancer Group. Analytical validation of a standardized scoring protocol for Ki67: phase 3 of an international multicenter collaboration. *NPJ Breast Cancer*. 2016;2:16014. doi: 10.1038/npjbcancer.2016.14.
8. Laurinavicius A, Plancoulaine B, Laurinaviciene A, Herlin P, Meskauskas R, Baltrusaityte I, et al. A methodology to ensure and improve accuracy of Ki67 labelling index estimation by automated digital image analysis in breast cancer tissue. *Breast Cancer Res*. 2014;16(2):R35. doi: 10.1186/bcr3639.
9. Soenksen D. Digital pathology at the crossroads of major health care trends: corporate innovation as an engine for change. *Arch Pathol Lab Med*. 2009;133(4):555-9. doi: 10.5858/133.4.555.
10. Kayser K, Borkenfeld S, Kayser G. How to introduce virtual microscopy (VM) in routine diagnostic pathology: constraints, ideas, and solutions. *Anal Cell Pathol*. 2012;35(1):3-10. doi: 10.3233/ACP-2011-0044.
11. Purdie CA, Quinlan P, Jordan LB, Ashfield A, Ogston S, Dewar JA, et al. Progesterone receptor expression is an independent prognostic variable in early breast cancer: a population-based study. *Br J Cancer*. 2014;110(3):565-72. doi: 10.1038/bjc.2013.756.
12. Abubakar M, Orr N, Daley F, Coulson P, Ali HR, Blows F, et al. Prognostic value of automated Ki67 scoring in breast cancer: a centralised evaluation of 8088 patients from 10 study groups. *Breast Cancer Res*. 2016;18(1):104. doi:10.1186/s13058-016-0765-6.
13. Koopman T, Buikema HJ, Hollema H, de Bock GH, van der Vegt B. Digital image analysis of Ki67 proliferation index in breast cancer using virtual dual staining on whole tissue sections: clinical validation and inter-platform agreement. *Breast Cancer Res Treat*. 2018;169(1):33-42. doi: 10.1007/s10549-018-4669-2.
14. Ayad E, Soliman A, Anis SE, Salem AB, Hu P, Dong Y. Ki 67 assessment in breast cancer in an Egyptian population: a comparative study between manual assessment on optical microscopy and digital quantitative assessment. *Diagn Pathol*. 2018;13(1):63. doi:10.1186/s13000-018-0735-7
15. Kwon AY, Park HY, Hyeon J, Nam SJ, Kim SW, Lee JE, et al. Practical approaches to automated digital image analysis of Ki-67 labeling index in 997 breast carcinomas and causes of discordance with visual assessment. *PLoS One*. 2019;14(2):e0212309. doi: 10.1371/journal.pone.0212309.