

# Unusual Pediatric Abdominal Cysts: A Pictorial Review of Imaging Findings

Pira Neungton, M.D., Preeyacha Pacharn, M.D., Kriengkrai Iemsawatdikul, M.D.

Department of Radiology, Faculty of Medicine Siriraj Hospital, Mahidol University, Bangkok 10700, Thailand.

## ABSTRACT

This article presents images and imaging features of unusual abdominal cysts in pediatric population. Recognition of imaging features and their location are helpful in diagnosis and therapeutic decision. Meconium pseudocyst usually has calcified wall and may contain debris or air. Lymphangioma can be located in mesentery or omentum and presents as uni or multilocular cyst. Pseudocyst is the most common complication of acute pancreatitis. Ovarian cyst is sometimes present as an abdominal mass in the newborn and young child. Cystic mass containing fat and calcifications is the pathognomonic finding of mature cystic teratoma. Duplication cyst has gut signature or double wall sign on ultrasound. Communication with bile duct is the helpful clue in diagnosis of choledochal cyst. When adrenal hemorrhage liquefies, it becomes cystic and gradually decreases in size.

**Keywords:** Cyst; pediatric; abdominal; imaging (Siriraj Med J 2018;70: 260-264)

## INTRODUCTION

Abdominal cyst is common problem in infants and children who are referred to the radiology department. Hydronephrosis and cystic renal diseases are the most frequent. Nevertheless, there are many groups of nonrenal cysts which are less common but challenging in clinical practice. A cyst can be palpated either by the parents or a physician, but the child sometimes experiences no symptom. When a cyst is large, the patient usually presents with symptom related with the mass effect such as increasing abdominal girth, abdominal pain, gut obstruction and jaundice.

Plain abdominal radiograph should be the first imaging procedure in every child who presents with abdominal mass. Ultrasound is the modality of choice to evaluate cystic mass while computed tomography (CT) and magnetic resonance imaging (MRI) are helpful in diagnosis and determination of the origin and extension. Although all of them are cystic in appearance, clinical history and imaging findings can provide clues in diagnosis.

This article presents unusual abdominal cysts in pediatric population including meconium pseudocyst,

omental and mesenteric cysts, pancreatic pseudocyst, ovarian cyst, cystic teratoma, duplication cyst, choledochal cyst and adrenal hemorrhage.

## Meconium pseudocyst

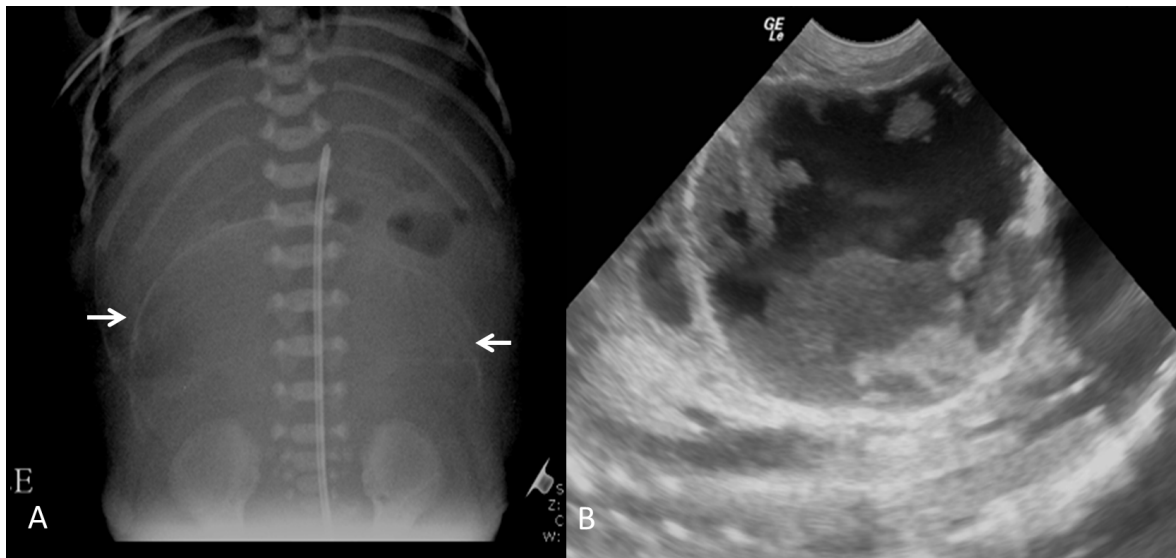
Meconium pseudocyst is a complication of meconium peritonitis secondary to perforation of bowel in utero.<sup>1</sup> Extruded meconium into the peritoneal cavity results in cystic mass formation to seal off the perforation. Calcium deposits are the pathognomonic finding of the meconium pseudocyst which can demonstrate on plain abdominal radiograph and ultrasound. (Fig 1) Occasionally, a scrotal mass is present because the calcifications extend to the scrotal sac. Sonographically, it has a thick, well-defined, echogenic wall and may contain debris or air.<sup>2</sup> Other imaging findings include dilated bowel loops, extraluminal air and intraperitoneal calcifications. There is a wide spectrum of clinical outcomes, ranging from a healthy newborn to a newborn with intestinal obstruction and perforation requiring surgical intervention.<sup>3</sup> Early detection in utero does not correlate with poor postnatal outcome.<sup>4</sup>

Correspondence to: Pira Neungton

E-mail: tom.pira@gmail.com

Received 31 July 2017 Revised 8 December 2017 Accepted 14 December 2017

doi:10.14456/smj.2018.42



**Fig 1.** Meconium pseudocyst in a 1-day-old infant with abdominal mass. (A) Abdominal radiograph reveals a large rim calcified mass within the abdomen (arrow). (B) Ultrasound reveals a complex cystic mass.

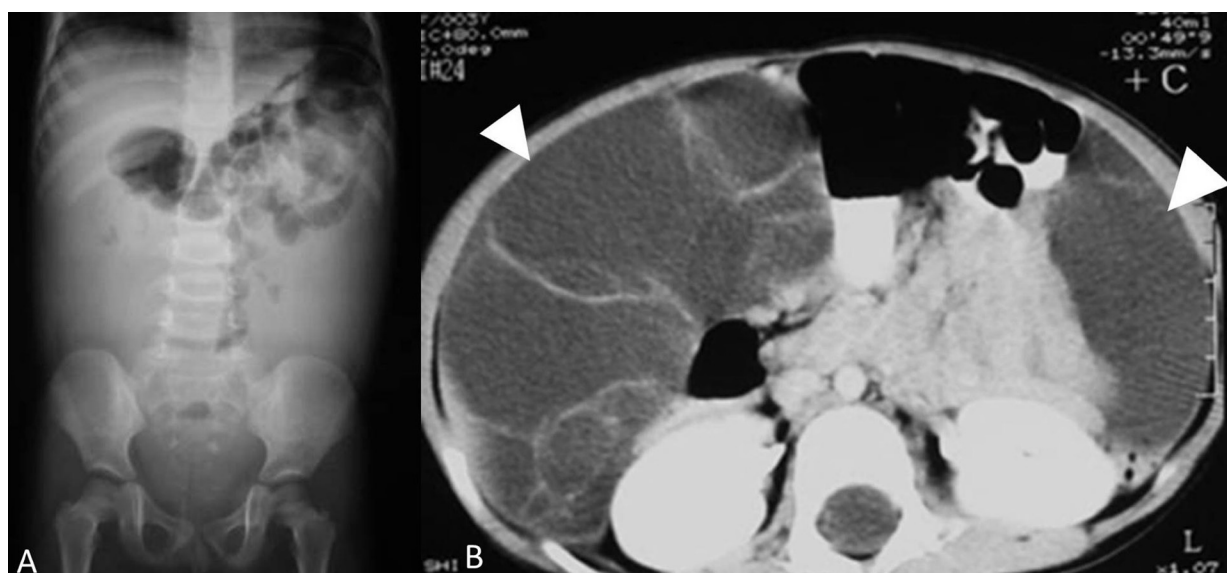
### Omental and mesenteric cysts (Lymphangioma)

It is believed that both conditions are obstructive malformation of the lymphatic vessels. The omental cysts are located in the greater and lesser omentum whereas the mesenteric cysts are located between the leaves of small bowel mesentery and the transverse mesocolon. They can manifest as a unilocular cyst, multilocular cyst or diffuse lymphangiomas.<sup>5</sup> Calcifications are rare. Sonographically, lymphangiomas are most often multilocular cystic masses which are anechoic or contain

echogenic debris. Due to its thin wall, that it may be seen to fill the entire abdomen, and resembles ascites. Contrast enhanced CT may demonstrate enhancement of cyst wall and septa.<sup>6</sup> (Fig 2) The definitive treatment is surgical excision.

### Pancreatic pseudocyst

The incidence of acute pancreatitis has been rising in pediatric population over the past decades.<sup>7</sup> In a series of 589 patients, no etiology was identified in nearly 25%



**Fig 2.** Omental cyst in a 3-year-old girl with chronic abdominal pain. (A) Mass effect within abdomen causes displacement of bowel loops on AP view of plain abdominal radiograph. (B) Axial CT demonstrates the cystic mass arising from the omentum (arrowhead).

of patients. Other etiologies include trauma, structural anomalies, multisystem disease, drugs and toxins, viral infections, hereditary and metabolic disorders.<sup>8</sup> Pseudocysts are the most common complication of acute pancreatitis and usually occur after 4 weeks of developing acute pancreatitis. Most of the fluid occurs adjacent to the pancreas resolve, although some may be walled off by fibrous tissue and develop pseudocyst. Sonography and CT usually reveal single and unilocular cyst with a thick wall. Calcifications are rare. The fluid is hypoechoic on sonography and of water attenuation on CT. Fluid-debris level and internal echoes may be seen if there is infection or hemorrhage. Sign of pancreatitis is a useful clue of diagnosis. Drainage is required in case of large size and superimposed infection and surgery is the treatment of choice in case of bleeding or rupture.

### Ovarian cysts

Frequently, ovarian cysts in the newborn and young child extend into the abdomen and present as an abdominal mass.<sup>9</sup> They can be detected prenatally by ultrasound or MRI. The cyst is stimulated by fetal, placental or maternal hormones. The management for the simple cysts that are smaller than 5 cm is observation in asymptomatic patients, because they will resolve spontaneously after hormone level decreases. However, the management for

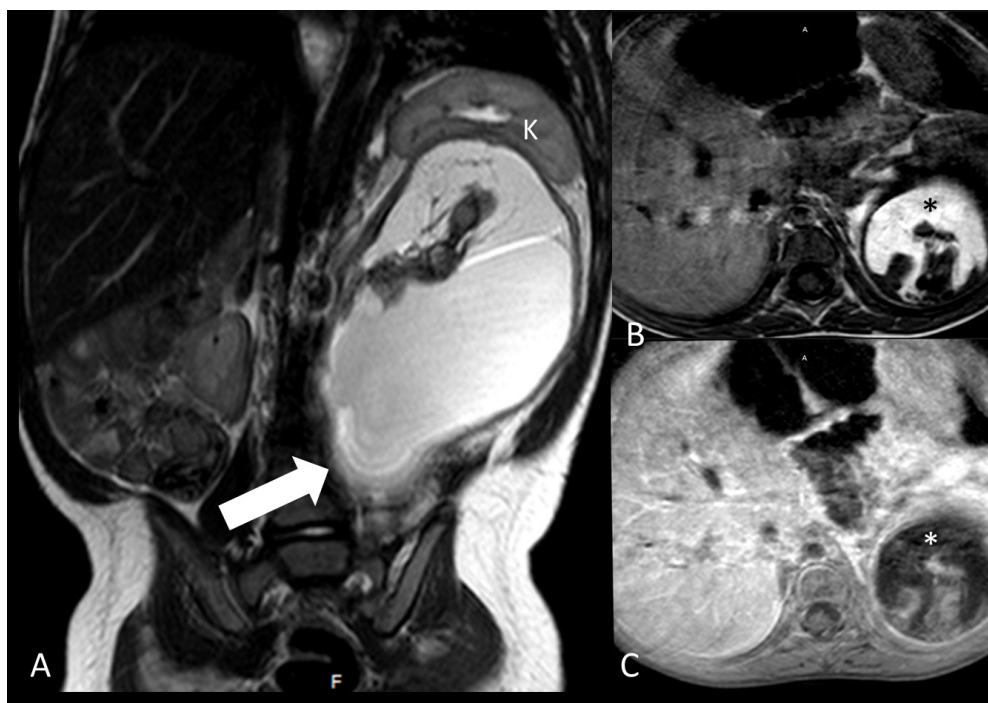the cysts which are larger than 5 cm is quite controversial. If the patient has symptom or the cyst persists, surgery is recommended.<sup>10</sup> Complications include rupture, torsion and bleeding. When the fluid debris level is detected, preceding ovarian torsion should be considered.<sup>11</sup>

### Mature cystic teratoma (dermoid cyst)

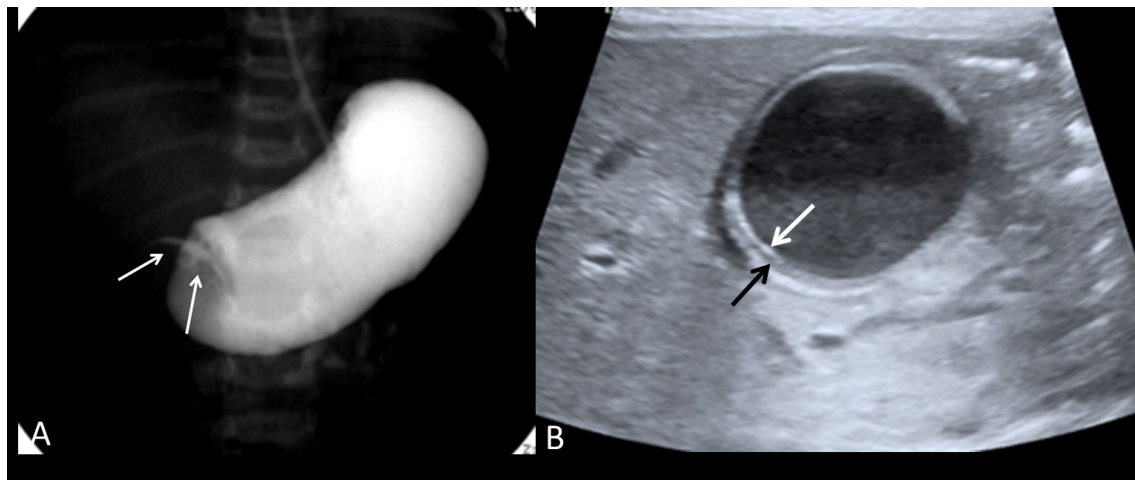
Although most common site of teratoma is the sacrococcygeal region and ovary, abdominal or retroperitoneal teratoma is not infrequent. Cystic teratomas are the common variety and usually benign. Sonographically, they manifest as the cystic mass with echogenic sebaceous material and calcifications. At CT and MRI, fat density and calcifications within the cyst are diagnostic. (Fig 3)

### Duplication cyst (enteric cyst)

A gastrointestinal (GI) duplication cyst is a congenital anomaly which may occur anywhere along the GI tract and is attached to the GI tract. The distal ileum is the most common location. These cysts are lined with epithelium and have smooth muscle in its wall. They are usually close to the gastrointestinal tract, but do not communicate. Presenting symptoms depend on the location and size. A characteristic sonographic finding is presence of gut signature or double wall sign, inner echoic layer of mucosa and outer hypoechoic layer of muscle. (Fig 4)



**Fig 3.** Retroperitoneal mature cystic teratoma in a 1-year-old girl with abdominal distension. (A) Coronal T2-weighted MRI reveals a large cystic mass located in left sided retroperitoneum (arrow) displaced left kidney (K) superiorly. (B) Axial T1-weighted image shows hyperintensity of the fat (\*) at superior aspect of the mass and (C) axial fat suppression image shows its hypointensity (\*).



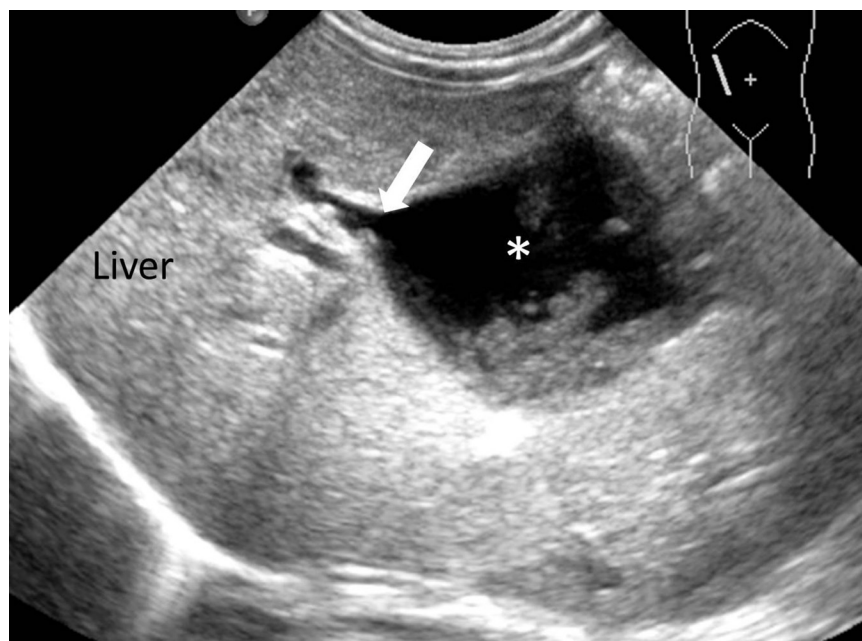
**Fig 4.** Duplication cyst of the stomach in a 7-day-old neonate with feeding intolerance and vomiting. (A) Upper gastrointestinal series demonstrate difficulty emptying of contrast and extrinsic compression at gastric outlet (arrow). (B) Ultrasonography demonstrates a cystic mass with gut signature: inner echoic layer of mucosa (white arrow) and outer hypoechoic layer of muscle (black arrow), located anteriorly to the pancreas.

### Choledochal cyst

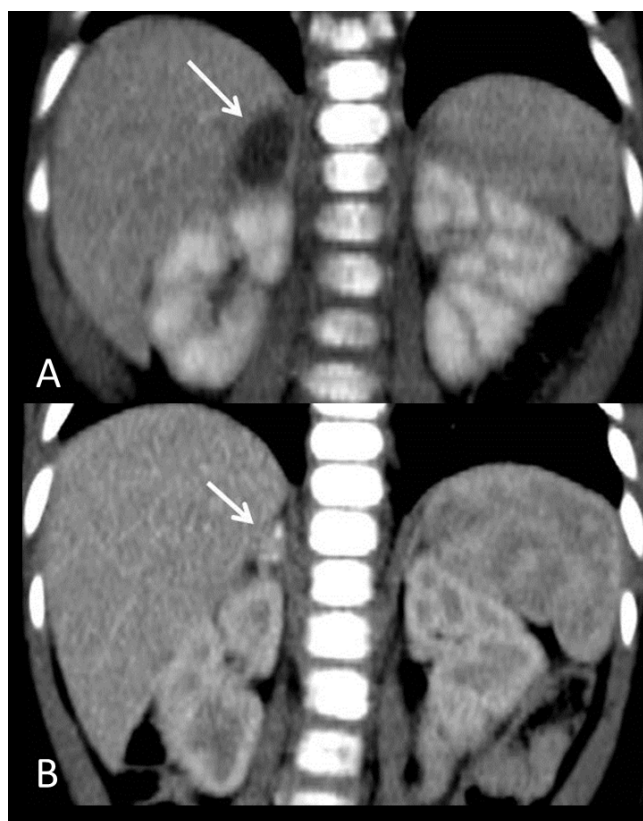
Choledochal cyst is one of the most common congenital hepatobiliary abnormalities and characterized by biliary tree dilatation. There are five types from Todani classification with different pathogenesis and appearance and type I is the most common. A minority of patients present with the triad of palpable abdominal mass, jaundice and fever. Sonography is usually the first imaging modality and demonstrates cystic mass at porta hepatis communicated with bile duct, which is the helpful clue. (Fig 5) It may contain stones or sludge. Surgical excision is the definitive treatment.

### Adrenal hemorrhage

Adrenal hemorrhage usually occurs in newborn with birth trauma, hypoxia and sepsis. It is sometimes asymptomatic, but may present as palpable mass, anemia, or hypovolemic shock. Neonatal adrenal hemorrhage may be detected as cystic suprarenal mass due to liquefaction which overlaps with congenital cystic neuroblastoma. Sequential ultrasonography, CT or MR is helpful. The hemorrhage gradually decreases in size, changes echogenicity and eventually disappears or may calcify.<sup>12,13</sup> (Fig 6)



**Fig 5.** Choledochal cyst in a 27-day-old neonate with jaundice. Ultrasonography demonstrates dilated bile duct (arrow) emptying directly into the cystic mass (\*) at porta hepatis containing echogenic debris.



**Fig 6.** Adrenal hemorrhage in a 1-month-old neonate with jaundice. (A) Initial coronal CT shows a cystic adrenal mass (arrow). (B) Follow up CT demonstrates the mass resolved and was calcified (arrow).

## CONCLUSION

There is a wide variety of cystic abdominal masses in infant and children. The most helpful factor in diagnosis is their location and imaging appearance. Fortunately, the majority in the pediatric age group are benign. Adrenal hemorrhage gradually decreases in size and disappears. Management of asymptomatic small ovarian cyst is observation. Most pancreatic pseudocysts resolve, but drainage and sometimes surgery are required when there are complications such as rupture, bleeding and

infection. Surgery is the treatment of choice for omental and mesenteric cysts, dermoid cyst, choledochal cyst, duplication cyst and cystic teratoma and imaging can provide clues in diagnosis, determining the extension and guide surgical management.

## REFERENCES

1. McNamara A, Levine D. Intraabdominal fetal echogenic masses: a practical guide to diagnosis and management. *Radiographics*. 2005;25:633-45.
2. Siegel MJ, Coley BD. *The core curriculum: pediatric imaging*. Philadelphia: Lippincott Williams & Wilkins; 2006.
3. Ionescu S, Andrei A, Oancea M, Licsandru E, Ivanov M, Marcu V, et al. Postnatal treatment in antenatally diagnosed meconium peritonitis. *Chirurgia*. 2015;113(6):538-44.
4. Wang C, Chang S, Chao A, Wang T, Tseng L, Chang Y. Meconium peritonitis in utero-the value of prenatal diagnosis in determining neonatal outcome. *Taiwan J Obstet Gynecol*. 2008;47(4):391-6.
5. Swischuk LE. *Imaging of the newborn, infant, and young child*. 5<sup>th</sup> ed. Philadelphia: Lippincott Williams & Wilkins; 2004.
6. Levy AD, Cantisani V, Miettinen M. Abdominal lymphangiomas: imaging features with pathologic correlation. *AJR*. 2004;182: 1485-91.
7. Nydegger A, Heine RG, Ranuh R, Gegati-Levy R, Cramer J, Oliver MR. Changing incidence of acute pancreatitis: 10-year experience at the Royal Children's Hospital, Melbourne. *J Gastroenterol Hepatol*. 2007;22(8):1313-6.
8. Mony B, Zvi W. Acute pancreatitis in childhood: analysis of literature data. *J Clin Gastroenterol*. 2003;37(2):169-72.
9. Papic JC, Billmire DF, Rescorla FJ, Finnell ME, Leys CM. Management of neonatal ovarian cysts and its effect on ovarian preservation. *J Pediatr Surg*. 2014;49(6):990-3.
10. Brandt ML, Helmrath MA. Ovarian cysts in infants and children. *Semin Pediatr Surg*. 2005;14(2):78-85.
11. Bruyn RD. *Pediatric ultrasound: how, why and when*. 1<sup>st</sup> ed. China: Elsevier; 2005.
12. Westra SJ, Zaninovic AC, Hall TR, Kangaroo H, Boechat MI. Imaging of the adrenal gland in children. *Radiographics*. 1994;14:1323-40.
13. Eo H, Kim JH, Jang KM, Yoo S, Lim G, Kim M, et al. Comparison of clinico-radiological features between congenital cystic neuroblastoma and neonatal adrenal hemorrhagic pseudocyst. *Korean J Radiol*. 2011;12(1):52-58.