

Digital Photographic Measurements of the Proximal Femoral Anatomy

Sarut Waranuchitkul, M.D.*,**, Pisit Lertwanich, M.D.*

*Department of Orthopaedic Surgery, Faculty of Medicine Siriraj Hospital, Mahidol University, Bangkok 10700, **Department of Orthopedics, Sampran Hospital, Nakhon Pathom 73110, Thailand.

ABSTRACT

Objective: This study evaluated the morphology of the proximal femur in the Thai population, especially the femoral head-neck relationship and the femoral neck-shaft relationship, using digital photographs.

Methods: The morphology of each proximal femur was evaluated via the standard anteroposterior and cephalocaudal views of digital photographs. The femoral head-neck junction morphology was evaluated for translation, rotation, and concavity. The femoral neck-shaft anatomy was measured with the neck-shaft angle and the neck version.

Results: Fifty-nine Thai femora with an average age of 45.4 years were evaluated. For the femoral head-neck translation, the average superior/inferior offset ratio was 1.01, and the average anterior/posterior offset ratio was 0.97. For the femoral head-neck rotation, the average anteroposterior and lateral physeal angles were 77.5° and 81.9°, respectively. Regarding the head-neck junction concavity, the average gamma, delta, alpha, and beta angles were 45.6°, 44.5°, 45.5°, and 36.2°, respectively. The average femoral neck-shaft angle was 129.5°, and the average femoral neck version was 5.7° of anteversion.

Conclusion: Thai femora had their heads located almost at the center of the femoral neck, and they were rotated in abduction and anteversion relative to the neck axis. The femoral head-neck junctions showed less concavity anteriorly and superiorly.

Keywords: Digital photograph; femoral head-neck junction; femoral neck-shaft angle; femoroacetabular impingement syndrome; proximal femoral anatomy (Siriraj Med J 2018;70: 484-489)

INTRODUCTION

The morphology of the proximal femur has been evaluated to explain the biomechanics of the normal hip and pathophysiology of various hip disorders.¹⁻³ Some conditions with an abnormal morphology of the proximal femur (especially the relationships between the femoral head, neck, and shaft) can be the causes of early osteoarthritis of the hip.¹ Femoroacetabular impingement (FAI) syndrome is a hip disorder caused by abnormal morphologic features of the proximal femur (cam morphology) and/or the acetabulum (pincer

morphology).⁴ Repetitive abnormal contact between the femoral head-neck junction and the acetabular rim results in chondral and labral damage.⁵ These chondral and labral lesions cause groin pain and contribute to the development of early osteoarthritis of the hip.^{1,5}

The cam morphology of the proximal femur is characterized by the presence of a flattening or convexity at the femoral head-neck junction.^{4,5} This abnormality can be identified with plain radiographs, CT scans, and MRIs.⁶⁻⁸ A prospective cohort by Agricola et al.⁹ demonstrated that patients with a higher severity of cam

Correspondence to: Pisit Lertwanich

E-mail: pisit.ler@mahidol.ac.th

Received 30 April 2018 Revised 22 August 2018 Accepted 11 September 2018

doi:10.14456/smj.2018.78

morphology had higher adjusted odds ratios in progression to end-stage osteoarthritis. Regarding FAI syndrome, the femoral neck-shaft relationship also determined the degree of labral damage. Ejnisman et al.,¹⁰ revealed that patients undergoing hip arthroscopy for FAI syndrome who had greater femoral anteversion were more likely to have larger labral tears and more anterior extension of the labral lesions.

Previous studies of the morphology of the proximal femur of Thais usually focused on the femoral neck and proximal shaft dimensions for orthopedic implant designs¹¹ and hip fracture risk assessments.^{12,13} Digital photographs have been used to evaluate the proximal femoral anatomy of Caucasian and African-American skeletons.^{3,14} The purpose of this study was to evaluate the morphology of the proximal femur in Thai skeletons, especially the femoral head-neck relationship and the femoral neck-shaft relationship, using digital photographs.

MATERIALS AND METHODS

Samples of Thai femora were obtained from the Department of Anatomy, Faculty of Medicine Siriraj Hospital. Exclusion criteria were aged less than 20 years at the time of death, and femora with an obvious abnormal appearance by gross visual inspection (such as osteoarthritis, osteonecrosis, previous fractures, and other deformities). One femur was randomly selected from each human skeleton.

Each specimen was photographed with a digital camera (Nikon D7000; Nikon, Tokyo, Japan) in 2 standard positions: the anteroposterior (AP) and the cephalocaudal views. For the AP photographs, each femur was placed in a supine position on a flat table, with the anterior surface pointing to the ceiling. The femoral neck was then positioned parallel to the table surface. If the neck axis was anteverted, the femoral shaft was rotated internally, using paper cards to increase the support under the lateral femoral condyle, until the neck axis was parallel to the table surface by cephalocaudal inspection. The femur was rotated externally by supporting the medial condyle if the neck axis was retroverted. The AP photographs were then taken from the direct overhead position, perpendicular to the femoral neck axis.

For the cephalocaudal photographs, each femur was placed on a flat table with the anterior surface facing up, and both femoral condyles resting on the table surface. The femoral shaft was abducted until the neck axis was parallel to the edge of the table by overhead inspection. The cephalocaudal photographs were taken with the camera's view that was parallel to the floor and perpendicular to the femoral neck.

The AP and cephalocaudal photographs of all specimens were measured using ImageJ software (National Institutes of Health, Bethesda, MD, USA). The femoral head-neck relationship was evaluated by measurements of translation, rotation, and concavity.³ The femoral neck-shaft relationship was assessed by the neck-shaft angle and neck version measurements.^{3,14}

Femoral head-neck translation refers to the amount of femoral head translation on the femoral neck in the direction that is perpendicular to the neck axis.^{3,15} The superior (SOS) and inferior (IOS) offsets were measured in the AP pictures (Fig 1), while the anterior (AOS) and posterior (POS) offsets were obtained from the cephalocaudal pictures (Fig 2). The amount of offset in each direction was the minimum distance between a line drawn parallel to the femoral neck axis and tangential to the femoral head, and a parallel line tangential to the most concave point of the femoral neck. These 4 offset measurements were used to calculate 2 offset ratios: AOS/POS ratio, and SOS/POS ratio. In addition, the anterior head-neck offset ratio was the proportion between the AOS distance and the femoral head diameter measured in the cephalocaudal view (Fig 2).¹⁶

The femoral head-neck rotation was characterized by the orientation of the physeal scar at the head-neck junction with respect to the femoral neck axis.³ In the AP photographs, the AP physeal angle was the superolateral angle between the line of the anterior physeal scar and a line representing the neck axis (Fig 3). In the

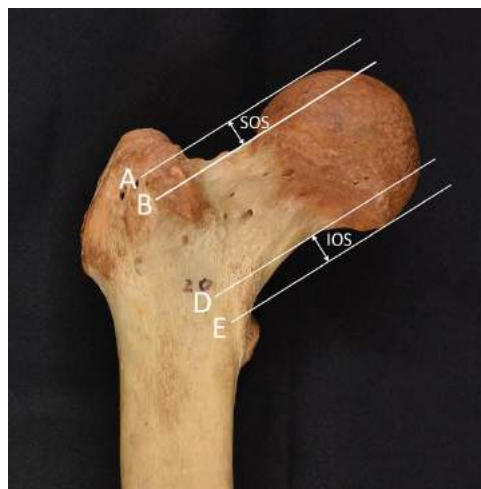


Fig 1. For the femoral head-neck translation, measured in the AP photographs, the superior offset (SOS) was the minimum distance between a line drawn parallel to the femoral neck axis and tangential to the femoral head (line A), and a parallel line tangential to the most concave point of the superior aspect of the femoral neck (line B). The inferior offset (IOS) was the minimum distance between lines D and E, which were located inferiorly. If the SOS/IOS ratio was less than 1, the femoral head translated inferiorly from the femoral neck axis.

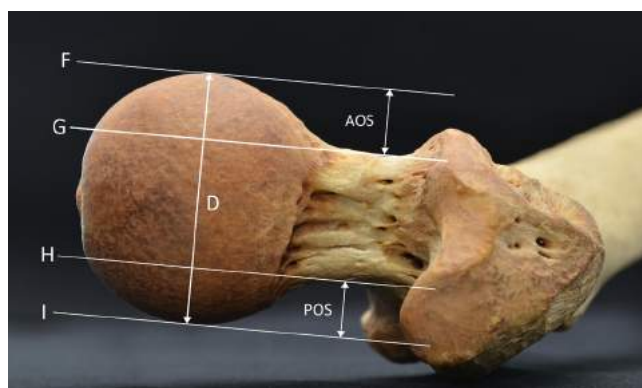


Fig 2. For the femoral head-neck translation, measured in the cephalocaudal photographs, the anterior offset (AOS) was the minimum distance between a line drawn parallel to the femoral neck axis and tangential to the femoral head (line F), and a parallel line tangential to the most concave point of the anterior aspect of the femoral neck (line G). The posterior offset (POS) was the minimum distance between lines H and I, which were located posteriorly. If the AOS/POS ratio was less than 1, the femoral head translated posteriorly from the femoral neck axis. In addition, the anterior head-neck offset ratio was the proportion between the AOS distance and the femoral head diameter (D).

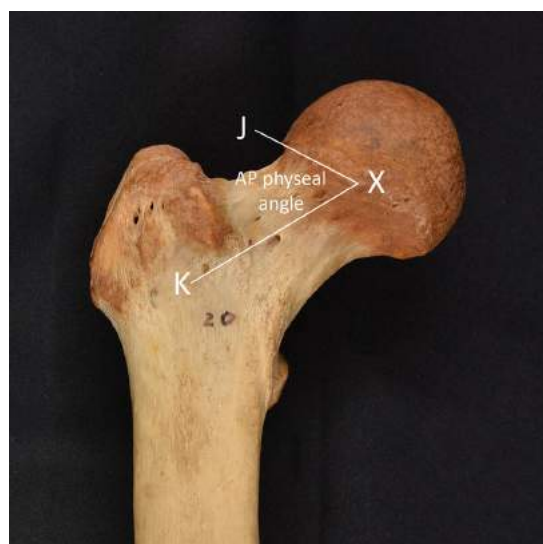


Fig 3. The AP physal angle, measured in the AP photographs, was the supero-lateral angle between the line of the anterior physal scar (line XJ) and a line representing the neck axis (line XK). If the AP physal angle was less than 90 degrees, the femoral head was abducted with respect to the femoral neck axis.

cephalocaudal photographs, the lateral physal angle was the anterosuperior angle between the line of the superior physal scar and a line representing the neck axis (Fig 4).

The femoral head-neck junction concavity was created from a near spherical femoral head joining a femoral neck. This parameter was quantified in each direction with a measurement that was modified from the alpha

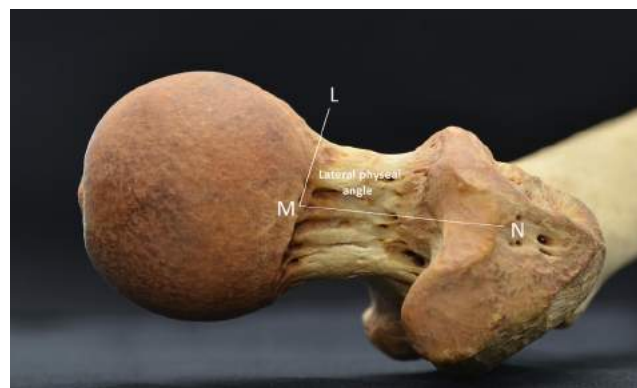


Fig 4. The lateral physal angle, measured in the cephalocaudal photographs, was the antero-lateral angle between the line of the superior physal scar (line LM) and a line representing the neck axis (line MN). If the lateral physal angle was less than 90 degrees, the femoral head was anteverted with respect to the femoral neck axis.

angle measurement method for MRIs described by Nötzli et al.⁷ The alpha angle is the angle between the femoral neck axis and a line from the femoral head center to the point marking the beginning of the asphericity of the anterior head-neck junction. Using the same measurement method, the femoral head-neck junction concavity was measured via the gamma and delta angles, superiorly and inferiorly, in the AP photographs (Fig 5). In addition, the alpha and beta angles were measured anteriorly and posteriorly in the cephalocaudal photographs (Fig 6). Smaller angles for these parameters represented more concavity of the femoral head-neck junctions.

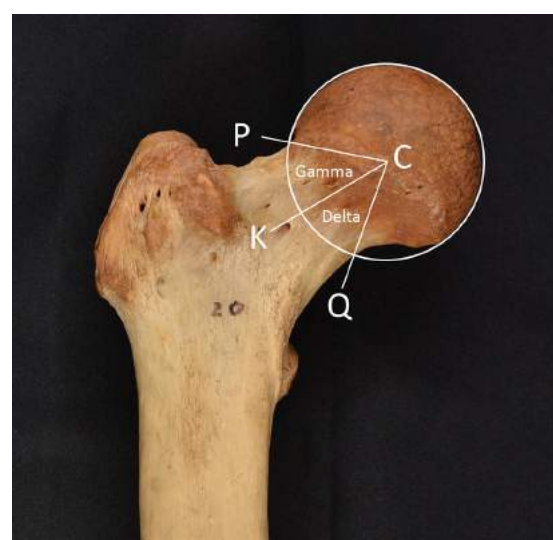


Fig 5. For the femoral head-neck concavity, measured in the AP photographs, the gamma angle was the angle between the femoral neck axis (line CK) and a line from the femoral head center (C) to the point marking the beginning of the asphericity of the superior head-neck junction (line CP). The delta angle was the angle between lines CK and CQ, which represented the concavity of the inferior head-neck junction.

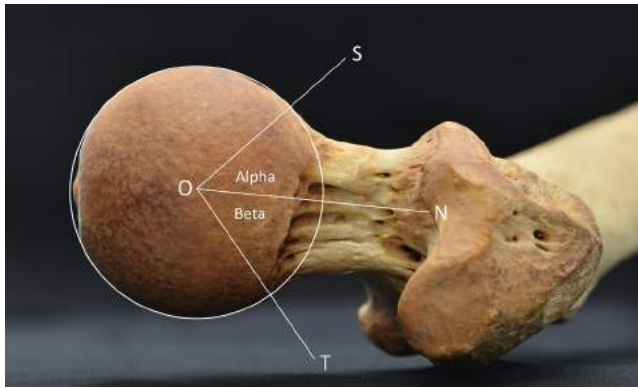


Fig 6. For the femoral head-neck concavity, measured in the cephalocaudal photographs, the alpha angle was the angle between the femoral neck axis (line ON) and a line from the femoral head center (O) to the point marking the beginning of the asphericity of the anterior head-neck junction (line OS). The delta angle was the angle between lines ON and OT, which represented the concavity of the posterior head-neck junction.

The femoral neck-shaft relationship was evaluated with the neck-shaft angle and the neck version. In the AP photographs, the femoral neck-shaft angle was created by the intersection of the femoral neck axis and the femoral shaft axis. In the cephalocaudal photographs, the femoral neck version was the angle created by the intersection of the neck axis and the bicondylar plane, which was a line parallel to the table surface which both femoral condyles had been placed on. When the femoral neck was anteverted, this angle was located anterior to the bicondylar plane and was recorded as a positive number.

All of the measurements on the AP and cephalocaudal photographs were presented as means, standard deviations, ranges, and 95% confidence intervals. Statistical analysis was performed using SPSS Statistics for Windows, version 18.0 (SPSS Inc., Chicago, IL, USA).

RESULTS

Fifty-nine femora with an average age of 45.4 years at time of death were evaluated in this study. Forty-six femora (78%) were obtained from male skeletons, and 30 (51%) were right. The average femoral head diameter was 43.2 ± 3.6 mm (range: 35.5 to 50.7 mm). The results of the photographic measurements of the femoral head-neck relationships and neck-shaft relationships are in [Table 1](#). The femoral head was located almost at the center of the femoral neck, which was demonstrated by the values of both the SOS/IOS and AOS/IOS ratios being close to 1. Both the AP and lateral physeal angles of the specimens were less than 90 degrees, so the femoral heads of this population were abducted and anteverted.

The femoral head-neck junctions presented their greatest concavity posteriorly because the average beta angle was lower than the average gamma, delta, and alpha angles. Regarding the parameters related to the cam morphology, 14 femora (24%) had an alpha angle greater than 50 degrees ([Table 2](#)), but all specimens had an anterior femoral head-neck offset ratio of more than 0.15. There were 7 femora (12%) that had a gamma angle greater than 50 degrees, but all specimens had a beta angle less than 50 degrees.

DISCUSSION

This study demonstrated that the femoral heads of Thai femora were located almost at the center of the femoral neck, with an abducted and anteverted rotational relationship to the neck axis. The femoral head-neck junctions demonstrated less concavity anteriorly and superiorly. Regarding the femoral neck-shaft morphology, the average femoral anteversion was 5.7 degrees, and the average neck-shaft angle was 129.5 degrees.

The values of the femoral head-neck translation in the present study was close to 1 for both the SOS/IOS and AOS/POS ratios. Toogood et al.,³ evaluated the proximal femoral anatomy using digital photographic measurements of Caucasian and African-American femora. They demonstrated that the femoral head translated inferiorly with an average SOS/IOS ratio of 0.90, and anteriorly with an average AOS/IOS ratio of 1.14. The mean alpha angle was 45.6 degrees, which was comparable to the present study, but the mean gamma angle was 53.5 degrees, which was 7.9 degrees higher than that of the present study. This racial difference in the femoral head-neck morphology has also been demonstrated in the radiographic findings of the cam morphology of asymptomatic volunteers, which demonstrated a difference between Belgian and Chinese subjects.¹⁷ This could be one of explanations for racial differences in the prevalence of hip osteoarthritis, which is much lower in the Asian population.¹⁸

The femoral head-neck rotation was evaluated by measuring the physeal scar orientation relative to the femoral neck axis. The results showed that the femoral head was rotated in abduction and anteversion, which could explain why there was less concavity of the femoral head-neck junction anteriorly and superiorly. Siebenrock et al.,¹⁵ showed that there was greater lateral epiphyseal extension and less femoral head-neck offset at the anterosuperior quadrant in FAI patients than in control subjects.

Regarding the femoral neck-shaft relationship, the average neck-shaft angle in this study was 129.5

TABLE 1. Photographic measurements of the femoral head-neck and neck-shaft relationships.

Measurements	Mean (SD)	Range (Min, max)	95% CI (Lower, upper)
Head-neck translation			
SOS (mm.)	7.4 (1.3)	4.5, 11.2	7.0, 7.7
IOS (mm.)	7.4 (1.2)	5.0, 10.5	7.1, 7.7
SOS/IOS ratio	1.01 (0.21)	0.58, 1.53	0.96, 1.06
AOS (mm.)	10.0 (1.4)	7.1, 14.5	9.7, 10.4
POS (mm.)	10.4 (1.3)	7.2, 13.4	10.1, 10.8
AOS/POS ratio	0.97 (0.09)	0.74, 1.18	0.94, 0.99
Anterior head-neck offset ratio	0.23 (0.03)	0.17, 0.29	0.23, 0.24
Head-neck rotation			
AP physeal angle (°)	77.5 (11.0)	49.3, 105.4	74.6, 80.3
Lateral physeal angle (°)	81.9 (7.9)	64.7, 104.6	79.9, 83.1
Head-neck junction concavity			
Gamma angle (°)	45.6 (6.9)	37.6, 77.5	43.8, 47.4
Delta angle (°)	44.5 (3.4)	36.8, 52.7	43.7, 45.4
Alpha angle (°)	45.5 (11.1)	27.9, 80.2	42.6, 48.4
Beta angle (°)	36.2 (5.5)	25.1, 49.8	34.8, 37.7
Neck-shaft relationship			
Neck-shaft angle (°)	129.5 (5.1)	120.6, 141.9	128.2, 130.9
Neck version (°)	5.7 (7.8)	-12.6, 23.3	3.6, 7.7

Abbreviations: SOS = superior offset; IOS = inferior offset; AOS = anterior offset; POS = posterior offset; AP = anteroposterior

TABLE 2. Femoral head-neck junction concavity.

Measurements	< 50°	50° to 55°	> 55°
Gamma angle (n, %)	52 (88%)	2 (3%)	5 (8%)
Delta angle (n, %)	55 (93%)	4 (7%)	0
Alpha angle (n, %)	45 (76%)	2 (3%)	12 (20%)
Beta angle (n, %)	59 (100%)	0	0

degrees, which was comparable to the results reported by Toogood et al.,³ but it was slightly higher than the previous three-dimensional measurement in computer aided design models of Thai subjects, which showed an average neck-shaft angle of 127.8 degrees.¹¹ In this study, the femoral neck orientation was 5.7 degrees of anteversion to the bicondylar plane, which was less than those found in previous studies, which reported values from 8.3 to 10.1 degrees of anteversion.^{3,11,14}

There were some limitations. The higher proportion of male specimens might affect the values of the femoral head-neck morphology because the prevalence of cam morphology is usually male predominant.^{5,8} There was no information on the height of the cadavers, although the average femoral head diameter in this study was 43 mm, which was similar to the mean value for 120 Thai volunteers in a study by Chantarapanich et al.¹¹

In conclusion, the Thai femora had their heads located almost at the center of the femoral neck, and they were rotated in abduction and anteversion relative to the neck axis. The femoral head-neck junctions showed less concavity anteriorly and superiorly.

ACKNOWLEDGEMENTS

The authors gratefully acknowledge Miss Natnicha Sriburiruk for the statistical analysis, and Miss Waraporn Chalermasuk for the manuscript preparation.

Conflicts of interest: The authors declare that there are no conflicts of interest related to this study.

REFERENCES

- Ganz R, Leunig M, Leunig-Ganz K, Harris WH. The etiology of osteoarthritis of the hip: an integrated mechanical concept. *Clin Orthop Relat Res.* 2008;466(2):264-72.
- Lerch TD, Todorski IAS, Steppacher SD, Schmaranzer F, Werlen SF, Siebenrock KA, Tannast M. Prevalence of Femoral and Acetabular Version Abnormalities in Patients With Symptomatic Hip Disease: A Controlled Study of 538 Hips. *Am J Sports Med.* 2018;46(1):122-34.
- Toogood PA, Skalak A, Cooperman DR. Proximal femoral anatomy in the normal human population. *Clin Orthop Relat Res.* 2009;467(4):876-85.
- Griffin DR, Dickenson EJ, O'Donnell J, Agricola R, Awan T, Beck M, et al. The Warwick Agreement on femoroacetabular impingement syndrome (FAI syndrome): an international consensus statement. *Br J Sports Med.* 2016;50(19):1169-76.
- Ganz R, Parvizi J, Beck M, Leunig M, Notzli H, Siebenrock KA. Femoroacetabular impingement: a cause for osteoarthritis of the hip. *Clin Orthop Relat Res.* 2003(417):112-20.
- Clohisey JC, Carlisle JC, Beaule PE, Kim YJ, Trousdale RT, Sierra RJ, et al. A systematic approach to the plain radiographic evaluation of the young adult hip. *J Bone Joint Surg Am.* 2008;90 (Suppl 4):47-66.
- Notzli HP, Wyss TF, Stoecklin CH, Schmid MR, Treiber K, Hodler J. The contour of the femoral head-neck junction as a predictor for the risk of anterior impingement. *J Bone Joint Surg Br.* 2002;84(4):556-60.
- Tannast M, Siebenrock KA, Anderson SE. Femoroacetabular impingement: radiographic diagnosis--what the radiologist should know. *AJR Am J Roentgenol.* 2007;188(6):1540-52.
- Agricola R, Heijboer MP, Bierma-Zeinstra SM, Verhaar JA, Weinans H, Waarsing JH. Cam impingement causes osteoarthritis of the hip: a nationwide prospective cohort study (CHECK). *Ann Rheum Dis.* 2013;72(6):918-23.
- Ejnisman L, Philippon MJ, Lertwanich P, Pennock AT, Herzog MM, Briggs KK, et al. Relationship between femoral anteversion and findings in hips with femoroacetabular impingement. *Orthopedics.* 2013;36(3):e293-300.
- Chantarapanich N, Rojanasthien S, Chernchujit B, Mahaisavariya B, Karunratanakul K, Chalermkarnnon P, et al. 3D CAD/reverse engineering technique for assessment of Thai morphology: Proximal femur and acetabulum. *J Orthop Sci.* 2017;22(4):703-9.
- Lektrakul N, Ratarasarn O. Geometry of proximal femur in the prediction of femoral neck fracture in the elderly female Thai population. *J Med Assoc Thai.* 2009;92 (Suppl 5):S60-6.
- Vaseenon T, Chaimuang C, Phanphaisarn A, Namwongprom S, Luevitonvechkij S, Rojanasthien S. Correlation of proximal femoral bone geometry from plain radiographs and dual energy X-ray absorptiometry in elderly patients. *J Med Assoc Thai.* 2015;98(1):39-44.
- Unnanuntana A, Toogood P, Hart D, Cooperman D, Grant RE. Evaluation of proximal femoral geometry using digital photographs. *J Orthop Res.* 2010;28(11):1399-404.
- Siebenrock KA, Wahab KH, Werlen S, Kalhor M, Leunig M, Ganz R. Abnormal extension of the femoral head epiphysis as a cause of cam impingement. *Clin Orthop Relat Res.* 2004(418):54-60.
- Beaule PE, Harvey N, Zaragoza E, Le Duff MJ, Dorey FJ. The femoral head/neck offset and hip resurfacing. *J Bone Joint Surg Br.* 2007;89(1):9-15.
- Van Houcke J, Yau WP, Yan CH, Huysse W, Dechamps H, Lau WH, et al. Prevalence of radiographic parameters predisposing to femoroacetabular impingement in young asymptomatic Chinese and white subjects. *J Bone Joint Surg Am.* 2015;97(4):310-7.
- Nevitt MC, Xu L, Zhang Y, Lui LY, Yu W, Lane NE, et al. Very low prevalence of hip osteoarthritis among Chinese elderly in Beijing, China, compared with whites in the United States: the Beijing osteoarthritis study. *Arthritis Rheum.* 2002;46(7):1773-9.