

# Gummy Smile: A Review of Etiology, Manifestations, and Treatment

Basel Mahardawi, B.D.S.\*, Teeranut Chaisamut, D.D.S.\*, Natthamet Wongsirichat, B.Sc., D.D.S.\*,\*\*

\*Department of Oral Maxillofacial Surgery, Faculty of Dentistry, Mahidol University, Bangkok 10400, \*\*Walailak University International College of Dentistry, Bangkok 10400, Thailand.

## ABSTRACT

Excessive gingival display, or what is known as Gummy Smile, is a clinical condition which is attracting a great attention and focus recently. Having knowledge and background about the cause and the treatment of each case of excessive gingival display is essential for making the accurate diagnosis and performing the correct procedure. This article reviews the most common causes of excessive gingival display, manifestations of this condition, and some of the important treatment options for Gummy Smile. In addition, the article also puts the light on some points regarding the accepted measurement in several studies, and considers the prediction planning for Gummy Smile associated with a skeletal etiology.

**Keywords:** Excessive gingival display; gummy smile; vertical maxillary excess (Siriraj Med J 2019;71: 168-174)

## INTRODUCTION

A wonderful smile is an essential feature of beauty to which society gives an increasing importance currently. The concept of a nice smile basically depends on the entity of three anatomic components: gum, teeth, and lips.<sup>1</sup> In the meantime, an increasing awareness regarding beauty and physical appearance has become a motivation for every clinician to evaluate the important aspects of patient's smile and link the dynamic relationship between the teeth, gingiva, and lips together when smiling.<sup>2</sup>

The gingiva is a crucial aspect to be considered in the esthetics of smiling<sup>1</sup>, in which the upper lip should be elevated around 80% of its normal length, exposing teeth and gingiva.<sup>3</sup> Sharma et al.,<sup>2</sup> defined the normal gingival display as the gum exposure between the inferior border of upper lip and gingival margin of anterior central incisors when smiling. An exposure of gingiva around 0-2 mm when smiling, and 2-4 mm of the maxillary incisor

edges when the lips are at the rest state are considered as acceptable. While more than 2 mm of gingival exposure when a person smiles is stated by experts as an excessive gingival display, or what is known as "Gummy Smile",<sup>4</sup> which is more of a descriptive term than a diagnosed condition, and affects a notable proportion of the population, especially women who are affected more than men.<sup>5</sup> Maxillary excess both vertically and anteroposteriorly (Bimaxillary protrusion), hyper mobility of the upper lip due to hyper function of labial elevator muscles, and excessive gingival display associated with altered passive eruption are the three major causes of this condition.<sup>6</sup> In addition to the stated reasons, medications, dental plaque, hereditary and incompetent lip can also result in abnormal gingival display.<sup>5</sup>

For adults, improved aesthetic outcomes are becoming increasingly essential in these procedures to the point where some patients are pursuing only the esthetic side,

Corresponding author: Natthamet Wongsirichat

E-mail: natthamet.won@mahidol.ac.th

Received 25 August 2018 Revised 6 December 2018 Accepted 24 December 2018

ORCID ID: <http://orcid.org/0000-0003-3005-2680>

<http://dx.doi.org/10.33192/Smj.2019.26>

not a functional benefit.<sup>7</sup> Therefore, finding an effective treatment for each cause of the gummy smile is a must.

### Etiologies of gummy smile:

Many studies have stated the main causes of excessive gingival display, presenting the most important factors which may lead to having a Gummy Smile. The study of Roe et al.,<sup>8</sup> described that lip length and the upper lip mobility rate are the main contributing factors. The previous research of Peck et al.,<sup>9</sup> stated that the exposure of teeth and gingiva depends on the integrated effects of a number of variables (increased muscle capacity, vertical maxillary excess, greater interlabial gap at resting position, and the amount of overjet and overbite). Pausch et al.,<sup>4</sup> mentioned that abnormal gingival and maxillary anterior teeth display may take place due to numerous anatomic or functional factors, either hereditary or inborn. A narrow upper lip, an irregular eruption of teeth, excessive protuberance or vertical maxillary growth, and hypermobility of the maxillary lip and elevator muscle are common reasons for a Gummy Smile.

In fact, several contributing factors are affecting individuals to have a Gummy Smile. Sometimes one of them is presented, although in some cases more than only one cause can be seen. Correct diagnosis of the reason leads to a proper treatment plan. The most common and discussed factors associated with Gummy Smile are:

### Altered passive eruption:

Also known as impaired passive eruption,<sup>1</sup> is defined as a condition in which the relationship between teeth, alveolar bone in the maxilla, and the soft tissues displays an excessive gingiva. This, in turn, reveals the clinical characteristic of Gummy Smile.<sup>10</sup> In other words, altered passive eruption (APE) is characterized by excessive gingival exposure in relation to the crowns of the maxillary teeth.<sup>11</sup> In this case, the gingiva fails to migrate in the apical direction during the eruption of teeth, thus, it remains in a coronal position in relation with the cemento enamel junction (CEJ), which results in having an unacceptable gingival exposure and unfavorable small size of the teeth when smiling.<sup>5</sup> Miskinyar et al.,<sup>12</sup> found that the prevalence of this condition is about 12% of the population. Altered passive eruption was first identified by the study of Coslet et al.,<sup>13</sup> and according to Rossi et al.,<sup>10</sup> it was classified into two types and two subtypes (Fig 1):

1. *Type I*: the vertical length of keratinized gingiva is greater than normal, the mucogingival junction (MGJ) is located in an apical position to the level of the cemento enamel junction (CEJ), and clinical crowns appear shorter.

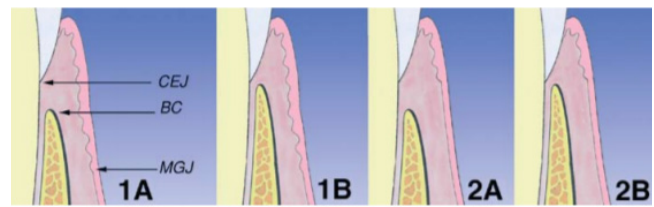


Fig 1. Classification of altered passive eruption (APE)<sup>14</sup>

2. *Type II*: the vertical dimension of the keratinized gingiva is normal, although the mucogingival junction is positioned at the level of the CEJ.

2.1 *Subtype A*: the measurement between the maxillary alveolar crest and the CEJ is around 1.5 mm, and in this case a regular attachment can be found.

2.2 *Subtype B*: the level of maxillary alveolar crest is at the level of the CEJ, or occlusal to the CEJ in some cases.

### Bony maxillary excess:

This includes vertical maxillary excess and bimaxillary protrusion.

### Vertical maxillary excess:

Wolford et al.,<sup>15</sup> defined Maxillary vertical hyperplasia or vertical maxillary excess as an excessive vertical growth of the maxilla which may or may not lead to an anterior open bite. In his study Robbins<sup>16</sup> explained that to make the correct diagnosis, the face must be divided into three equal thirds or parts for the critical evaluation of the height of the face. Vertical maxillary excess is noticed when the length of the lower third of the face is more than the other two thirds, causing an excessive gingival display.<sup>5</sup>

In the analysis of the face, vertical maxillary excess has the following features: longer lower third of the face, in relation with the upper and middle thirds, a greater display of maxillary incisors at rest, an incompetent lip, inclination towards class II malocclusion with or without open bite, and a noticeable Gummy Smile. The nose is longer as well, the alar bases are small and the zygoma appears to be generally flat. The lower third of the face is long, leading to a retrognathic shape of the jaw.<sup>17</sup> Furthermore, the incisal edge of the upper anterior teeth might be covered by the lower lip because of the extravagant downward growth of the maxilla.<sup>16</sup> Peck et al.,<sup>9</sup> and Mackley<sup>18</sup> found that a Gummy Smile is highly related to anterior vertical maxillary excess (about 2-3 mm). Moreover, Ezquerro and Berrazueta<sup>19</sup> discuss that excessive maxilla associated with the protrusion of anterior alveolar bone consequently produce a Gummy

Smile. Whilst Wu et al.,<sup>6</sup> in their study also stated that anterior maxillary height (upper incisor to the palatal plane) was considerably more in both male (+1.03 mm) and female (+2.13 mm) groups who have Gummy Smile.

### **Bimaxillary protrusion:**

Bimaxillary protrusion is a frequently diagnosed deformity in African Americans<sup>20</sup> and Asian populations as well. This deformity is described regarding the protrusive and buccally positioned maxillary and mandibular incisors, as well as the enlarged protrusion of the lips. It can be found with an incompetent lip, excessive gingival display, mentalis strain with an anterior open bite. Bimaxillary protrusion refers to an abnormally protruded maxillary and mandibular dentoalveolus. Generally, this presents with malocclusion and dentoalveolar flaring of both the maxillary and mandibular anterior teeth, which cause the lips to be protruded, thus, producing an additional convexity of the facial profile. Bimaxillary protrusion is mainly accompanied by several degrees of lip deficiency (defined as more than 4 mm of lip detachment at the rest state). The tendency of the anteroposterior correlation is to be a class II malocclusion with a deficient mandible, although it may also range from severe class II to class III.<sup>21</sup>

The etiology behind bimaxillary protrusion is associated with various reasons between genetics and environment, such as mouth breathing, lip biting habit and large size of the tongue.<sup>22</sup>

Keating et al.,<sup>23</sup> discovered that in Caucasians with bimaxillary protrusion, it is likely to notice a posterior cranial base which is shorter than normal, a prognathic maxilla with vertical excess, mild class II skeletal occlusion, and a prostrate profile.

### **Conditions causing gingival enlargement**

Gingival enlargement might be the outcome of bacterial plaque-enhanced chronic inflammation and medications.<sup>5</sup> Narwal et al.,<sup>24</sup> showed in their case report an abnormal unilateral palatal soft tissue enlargement in a 61-year-old hypertensive female using amlodipine, which is a safe antihypertensive drug. Ritchhart et al.,<sup>25</sup> stated a process behind uncontrolled cell proliferation in drug-induced gingival overgrowth which is the suppression of apoptotic pathways, with the following effect on the normal gingival formation by cell turnover. Hormonal differences which take place in pregnancy and puberty, in addition to the use of oral contraceptives have been associated with gingival overgrowth.<sup>5</sup> Other effects such as age, demographic and pharmacokinetic changes, genetic predisposition, oral hygiene condition, as well as

molecular and cellular variables may impact the mechanism of gingival enlargement.<sup>25, 26</sup> Orthodontic treatment using orthodontic appliances can also participate in the presence of gingival enlargement.<sup>27</sup> In the case of leukemia, leukemic cells might infiltrate to the gingiva,<sup>28</sup> and this will cause some manifestations to be present such as gingival enlargement and bleeding.<sup>29</sup>

### **Short upper lip**

The upper lip length is defined as the length from the base of the nose (subnasale point) to the inferior part of the upper lip (upper lip stomion point),<sup>8</sup> which is normally around 23 mm in males and 20 mm in females.<sup>3</sup> If an individual with excessive gingival display has a short upper lip as well, the esthetic compromise will be affected.<sup>16</sup> The diagnosis of an excessive gingival display can be done regarding the clinical measurement of the upper lip length with an excessive amount of tooth display at rest.<sup>5</sup> Conversely, Roe et al.,<sup>8</sup> found in their study that in maximum smile, there is no notable difference in the gingival display between an individual with a short or normal upper lip, and they concluded that the association of some factors such as higher muscle capacity, vertical maxillary excess, excessive interlabial gap at rest, and the amount of overjet and overbite have a greater effect on the gingival display than the upper lip length itself. Moreover, Sarver et al.,<sup>30</sup> explained that what is crucial is the correspondence between the upper lip length, the maxillary incisors, and the commissure of the mouth. In other words, the lip length should be almost equal to the commissure of the mouth.

### **Hypermobility of the upper lip:**

In the case of normal face height, gingival levels, lip length and length of central incisors in a patient who has an excessive gingival display, the possible etiology is hypermobility of the maxillary upper lip.<sup>16</sup> Upper lip mobility was explained as the volume of lip movement that exists when an individual smiles. This was measured by deducting the incisal shown at rest from the dentogingival display during a full smile.<sup>8</sup> Hypermobility of the upper lip is associated with a hyper function of the lip elevator muscles and basically leads to excessive gingival display.<sup>19</sup>

Peck and Peck<sup>31</sup> reported an average lip movement of 5.2 mm (23% decrease) from a measured lip length of 22.3 mm during a full smile. Furthermore, in a study evaluating spontaneous smiles, Tarantili et al.,<sup>32</sup> identified a 28% decrease in the initial upper lip length, while Roe et al.,<sup>8</sup> concluded the overall means of lip mobility for females with normal lip length, females with short lip length, males with normal lip length and males with

short lip length were  $5.8 \pm 1.7$  mm,  $5.0 \pm 1.3$  mm,  $6.7 \pm 1.5$  mm, and  $5.7 \pm 1.1$  mm, respectively. Moreover, Sabri et al.,<sup>3</sup> stated that in smiling, the upper lip is elevated by about 80% of its original length. Bhola et al.<sup>5</sup>, as well as Robbins<sup>16</sup> stated that the upper lip is generally elevated around 6-8 mm from the rest position to the position reached when a full smile takes place.

### Treatment of gummy smile:

Excessive gingival display can be managed by a variety of procedures. These procedures include non-surgical and surgical methods. The underlying cause of excessive gingival display or Gummy Smile has the main effect on the type of procedure that will be performed.<sup>33</sup> Non-surgical procedures may include Botulinum toxin type A injection as well as orthodontics, While surgical procedures might include lip repositioning or orthognathic surgery following orthodontics.

Robbins<sup>16</sup> defined the healthy gingiva as having a minimal length of approximately 3 mm from the gingival crest to the alveolar crest. In the case of altered passive eruption, a higher amount will exist, and the treatment of choice is normally gingivectomy following by aesthetic crown lengthening to attain the desired dimension and morphology of teeth. However, when the diagnosis shows bone levels close to the CEJ, a gingival flap with ostectomy is performed, or what is also known as an apically positioned flap.<sup>34</sup> Orthodontic eruption or intrusion can also be done when having gingival asymmetry on one or multiple anterior teeth<sup>34</sup>

In the case of vertical maxillary excess, the only treatment option to consider is orthognathic surgery.<sup>11</sup> This is applied to impact the maxilla considering the amount of gingival exposure diagnosed. Maxillary impaction allows correction of the Gummy Smile, long face syndrome, specific types of open bite from a skeletal origin and labial sealing.<sup>35</sup> The Le Fort I osteotomy of the maxilla allows reduction of bone between the nasal floor and apices of maxillary teeth which permits superior repositioning (impaction) of the maxilla.<sup>17</sup>

When having bimaxillary protrusion, the treatment option may be composed of first premolar extractions followed by the osteotomy through the extraction sites to mobilize the anterior segment of the maxilla. The aim is to setback the segment in addition to lessening the labial flaring of the incisors. Maxillary setback alone can sometimes provide a substitute for the treatment of anterioposterior maxillary excess without any need for tooth extraction or segmental osteotomy in these cases:

(1) it is contraindicated to perform extractions in an orthodontic diagnosis (no dental crowning, adequate

curve of Spee, etc.),

(2) the proclination of maxillary incisors can be adjusted to an acceptable position with a Le Fort I osteotomy in addition to clockwise rotation.<sup>21</sup>

In the presence of external factors causing gingival overgrowth, the treatment plan should be focused on the exact cause of the enlarged gingiva. Meticulous history taking, in addition to an excisional/incisional biopsy and/or hematologic/histologic inspection might be performed generally to make the correct diagnosis of the uncommon conditions of gingival enlargement. Plaque control is an important aspect of treatment in all the patients. Some of these cases may resolve when the external element that is inducing the gingival enlargement is adjusted or suspended, For example, gingival overgrowth during pregnancy and puberty might need the elimination of all local irritants followed by surgical treatment for the removal of any fibrotic residuals.<sup>36</sup>

For the excessive gingival display resulted from short upper lip and/or hypermobility of the upper lip, a surgical procedure known as lip repositioning surgery is preferred for a minimally invasive surgery. It is composed of an oval mucosal excision followed by coronally advanced flap. This procedure is done to reduce the hyperactivity of the elevator muscles and reform the depth of the vestibule.<sup>37</sup> It was first described by Rubinstein and Kostianovsky<sup>38</sup> and the aim was the treatment of excessive gingival display associated with hypermobility of the lip, and was then modified by Litton and Fournier<sup>39</sup> to include also the treatment of Gummy Smile caused by short upper lip, by separating the muscles from the underlying bony structures to place the upper lip in a coronal position. This surgical procedure was accompanied with no complications, although there were some incidences of relapse,<sup>40</sup> consequently, some attempts were done to improve it by Miskinyar.<sup>12</sup> Recently, Bhola et al.,<sup>5</sup> described a technique similar to the one which was described by the article of Rubinstein and Kostianovsky under the name of Lip Stabilization Technique (LipStaT). The only obvious difference between the two techniques is that in LipStaT, a vertical incision is done posteriorly to connect the inferior incision (at the mucogingival junction) and the superior incision (into the vestibule). The ratio of this incision is the height being double of gingival exposure during a full smile. While in Rubinstein and Kostianovsky technique, the two incisions were approximated till they meet posteriorly.

Currently, another nonsurgical treatment option is the injection of Botulinum toxin type A which has been suggested for treatment of hypermobility of the upper lip, but this may only provide temporary advantages.<sup>41</sup>



Polo<sup>41</sup> reported a relapse of around 2 mm after 24 weeks of following up. This was similar for Indra et al.,<sup>42</sup> by reporting a relapse of treatment in the third month. Yet it is still a viable option for those who do not prefer undergoing surgeries, and need only a minimal treatment procedure.

## DISCUSSION

It was stated recently that the dimension and visibility of teeth, and upper lip position were crucial effects when judging smile attractiveness.<sup>43</sup> Many studies described the acceptable gingival exposure and the concept of Gummy Smile (table below). Having an acceptable smile in the eyes of other people is, in fact, a subjective view, because the perception of a nice smile has differed from country to country, from study to study, and even when males or females are evaluating the smile. In other words, a study showed that the male raters differed in respect of gender specificity when judging the attractiveness of the smile, while female raters rated males less gender specific.<sup>4</sup> Therefore, no reliable or unified measurements were stated in the literature regarding a clear description of having an attractive smile or when it is diagnosed as a Gummy Smile. Although the different visions of an accepted gingival exposure were evaluated in different countries, they should be identical for the same ethnic origins. Sabri et al.<sup>3</sup> concluded that an ideal smile has the features of an upper lip that will reach the gingival edges when smiling, in addition to an upward or straight curvature through the philtrum and commissures; with maxillary incisal margins parallel to the lower lip line; with no lateral negative space or minimal if it presents; and a commissural line, as well as an occlusal frontal plane parallel to the line drawn through the pupils of the eyes; and attractive integration of gingiva and teeth. The acceptable amount of gingival exposure when smiling was mentioned in several studies. For instance, Kokich et al.,<sup>44</sup> reported noticeably unattractive lip to gingiva distance when the exposure is 4 mm by laypersons and when it is 2 mm by orthodontists, while Geron and Atalia<sup>45</sup> accepted only 1 mm of gingival display when smiling. Pausch et al.,<sup>4</sup> concluded in their study that a 0- to 2-mm exposure of the maxillary gingiva was acceptable when an individual smiles. In addition to that, they found that although the Gummy Smile is unattractive, it is much better than invisible or minimally visible maxillary teeth when smiling. Bhola et al.,<sup>5</sup> explained that affected by the increased aesthetic concerns, a gingival exposure of more than 1 mm during smiling might be diagnosed as excessive gingival display (EGD). Van der Geld et al.<sup>43</sup> concluded in their study that a lip line height that exposed more than 4 mm of gingival display was considered as

a Gummy Smile line. Jannani et al.<sup>46</sup> stated that a smile is introduced as attractive when the maxillary teeth are entirely shown in addition to approximately 1 mm of gingival display. However, a gingival display not more than 2-3 mm is also contemplated as acceptable, while a disproportionate exposure (>3 mm) is basically stated as not pleasant. Pinto et al.,<sup>11</sup> mentioned three kinds of a smile: high, medium and low, and the high smile is considered acceptable when accompanied with exposed gingiva of 1 to 3 mm.

Moreover, treatment of Gummy Smile was being practiced many years ago. Several techniques and procedures were developed to reduce the excessive gingival display and change it into an aesthetic, acceptable appearance. Taking the bony maxillary excess into consideration, a review of the literature may conclude that although the treatment of Gummy Smile caused by vertical maxillary excess and/or bimaxillary protrusion is not a new procedure, no studies have made a clear treatment plan, and no one has described a step by step way to predict the treatment according to a certain prediction plan before performing orthognathic surgery, based on clear measurements of moving the maxilla. Thus, a thorough prediction and movement plan of the maxilla for Gummy Smile treatment might be of a great value to help surgeons establish an accurate treatment plan based on scientific data, not only experience. The acceptable gingival exposure and the diagnosis of Gummy Smile in some previous studies is shown in [Table 1](#).<sup>4,5,11,43-46</sup>

## CONCLUSION

Gummy Smile is a condition in which an increasing awareness has been noticed recently. Therefore, it is attracting more attention from all the clinicians to find the best solutions with the least complications and relapse, as well as the most satisfying results for every patient. Additional unified standards of accepting and not accepting the amount of gingival exposure might be better to help with diagnosing and deciding whether to perform surgery or consider the gingival exposure as acceptable. This should be decided considering the ethnic origin and trying to collect a wider range of opinions, not only taking experts' view because they will judge more critically. This could be done by performing a greater statistical analysis regarding this topic, including more people to evaluate and judge.

In addition, clear prediction planning of moving the maxilla to improve the condition of Gummy Smile, taking into account if it is resulted from vertical maxillary excess alone or with bimaxillary protrusion, would be of a great benefit to perform a well-planned surgery. This

**TABLE 1.** Acceptable gingival exposure and the diagnosing of Gummy Smile in some studies in the literature.

Authors	Year	Acceptable gingival exposure	Having a Gummy Smile
Kokich et al. <sup>44</sup>	1999	Less than 4 mm by laypersons Less than 2 mm by orthodontists	4 mm or more by laypersons 2 mm or more by orthodontists
Geron and Atalia <sup>45</sup>	2005	Untill 1 mm	More than 1 mm
Van der Geld et al. <sup>43</sup>	2011	Untill 4 mm	More than 4 mm
Jannani et al. <sup>46</sup>	2014	2-3 mm	More than 3 mm
Pinto et al. <sup>11</sup>	2015	1-3 mm	More than 3 mm
Bhola et al. <sup>5</sup>	2015	Untill 1 mm	More than 1 mm
Pausch et al. <sup>4</sup>	2017	0-2 mm	More than 2 mm

surgery should be done according to certain principles and criteria, not depending upon each surgeon's experience or preference. To reach this stratified surgical plan, this literature review suggests further studies to design a prediction formula of moving the maxilla, following certain calculations regarding the amount of vertical maxillary excess, bimaxillary protrusion, x-rays, and considering opinions of experienced surgeons to get the best aesthetic results.

## ACKNOWLEDGMENTS

The authors would like to acknowledge the staff, dental assistants, and our colleagues in the Department of Oral and Maxillofacial Surgery, Faculty of Dentistry, Mahidol University.

**Funding:** The authors received no funding

**Conflict of interest:** The authors declared that they have no conflicts of interest.

**Ethics approval:** Not required

## REFERENCES

- Izraelewicz-Djebali E, Chabre C. Gummy smile: orthodontic or surgical treatment? *Dentofacial Anom Orthod* 2015;18:102. Published online: 04 September 2015.
- Sharma A, Sharma S, Garg H, Singhal V, Mishra P. Lip repositioning: A boon in smile enhancement. *J Cutan Aesthet Surg* 2017;10:219-22.
- Sabri R. The eight components of a balanced smile. *J Clin Orthod* 2005;39:155-67.
- Pausch NC, Katsoulis D. Gender-specific evaluation of variation of maxillary exposure when smiling. *J Craniomaxillofac Surg* 2017;45:913-20.
- Bhola M, Fairbairn PJ, Kolhatkar S, Chu SJ, Morris T, de Campos M. LipStaT: The Lip Stabilization Technique- Indications and Guidelines for Case Selection and Classification of Excessive Gingival Display. *Int J Periodontics Restorative Dent* 2015;35: 549-59.
- Wu H, Lin J, Zhou L, Bai D. Classification and craniofacial features of gummy smile in adolescents. *J Craniofac Surg* 2010;21:1474-9.
- Charrier JB. Orthognathic surgery of adults and facial aesthetics. *J Dentofacial Anom Orthod* 2012;15:302.
- Roe P, Rungcharassaeng K, Kan JYK, Patel RD, Campagni WV, Brudvik JS. The Influence of Upper Lip Length and Lip Mobility on Maxillary Incisal Exposure. *Am J Esthet Dent* 2012;2:116-125.
- Peck S, Peck L, Kataja M. The gingival smile line. *Angle Orthod* 1992;62:91-100.
- Rossi R, Brunelli G, Piras V, Piloni A. Altered passive eruption and familial trait: a preliminary investigation. *Int J Dent* 2014; 2014:874092.
- Pinto SCS, Higashi C, Bonafé E, Pilatti GL, Santos FA, Tonetto MR, et al. Crown Lengthening as Treatment for Altered Passive Eruption: Review and Case Report. *World J Dent* 2015;6:178-83.
- Miskinyar SA. A new method for correcting a gummy smile. *Plast Reconstr Surg* 1983;72:397-400.
- Coslet JG, Vanarsdall R, Weisgold A. Diagnosis and classification of delayed passive eruption of the dentogingival junction in the adult. *Alpha Omegan* 1977;7:24-8.
- Alpiste-Illueca F. Altered passive eruption (APE): a little-known clinical situation. *Med Oral Patol Oral Cir Bucal* 2011;16: e100-4.
- Wolford LM, Karras SC, Mehra P. Considerations for orthognathic surgery during growth, part 2: maxillary deformities. *Am J Orthod Dentofacial Orthop* 2001;119:102-5.
- Robbins JW. Differential diagnosis and treatment of excess gingival display. *Pract Periodontics Aesthet Dent* 1999;11:265-72.
- Nascimento Meger M, Tiboni F, dos Santos FS, Verbicaro T, Deliberador TM, Scariot R, et al. Surgical correction of

- vertical maxillary excess associated with mandibular self-rotation. *RSBO* 2017;14:56-61.
18. Mackley RJ. An evaluation of smiles before and after orthodontic treatment. *Angle Orthod* 1993;63:183-90.
  19. Ezquerro F, Berrazueta MJ, Ruiz-Capillas A, Arregui JS. New approach to the gummy smile. *Plast Reconstr Surg* 1999;104:1143-50.
  20. Scott SH, Johnston LE. The perceived impact of extraction. and nonextraction treatments on matched samples of African American patients. *Am J Orthod Dentofacial Orthop* 1999;116:352-8.
  21. Chu YM, Bergeron L, Chen YR. Bimaxillary protrusion: an overview of the surgical-orthodontic treatment. *Semin Plast Surg* 2009;23:32-9.
  22. Lamberton CM, Reichart PA, Triratananimit P. Bimaxillary protrusion as a pathologic problem in the Thai. *Am J Orthod* 1980;77:320-9.
  23. Keating PJ. Bimaxillary protrusion in the Caucasian: a cephalometric study of the morphological features. *Br J Orthod* 1985;12:193-201.
  24. Narwal A, Singh V, Bala S. Drug-induced atypical hyperplasia enveloping salivary gland malignancy. *J Indian Soc Periodontol* 2017;21:409-11.
  25. Ritchhart C, Joy A. Reversal of drug-induced gingival overgrowth by UV-mediated apoptosis of gingival fibroblasts - an in vitro study. *Ann Anat* 2018;217:7-11.
  26. Nakib N, Ashrafi SS. Drug-induced gingival overgrowth. *Dis Mon* 2011;57:225-30.
  27. Trossello VK, Gianelly AA. Orthodontic treatment and periodontal status. *J Periodontol* 1979;50:665-71.
  28. Savona M, Talpaz M. Chronic myeloid leukemia: changing the treatment paradigms. *Oncology (Williston Park)* 2006;20:707-11.
  29. Chowdhri K, Tandon S, Lamba AK, Faraz F. Leukemic gingival enlargement: A case report and review of literature. *J Oral Maxillofac Pathol* 2018;22(Suppl 1):S77-S81.
  30. Sarver DM, Ackerman MB. Dynamic smile visualization and quantification: Part 2. Smile analysis and treatment strategies. *Am J Orthod Dentofacial Orthop* 2003;124:116-27.
  31. McNamara JA. Jr, Brust EW, Riolo ML. Soft tissue evaluation of individuals with an ideal occlusion and a well-balanced face. In: McNamara JA Jr. (Ed.) *Esthetics and the Treatment of Facial Form*. Monograph 28. Craniofacial Growth Series. Center for Human Growth and Development, Ann Arbor; 1993.
  32. Tarantili VV, Halazonetis DJ, Spyropoulos MN. The spontaneous smile in dynamic motion. *Am J Orthod Dentofacial Orthop* 2005;128:8-15.
  33. Abdullah WA, Khalil HS, Alhindi MM, Marzook H. Modifying gummy smile: a minimally invasive approach. *J Contemp Dent Pract* 2014;15:821-6.
  34. Dolt AH 3rd, Robbins JW. Altered passive eruption: an etiology of short clinical crowns. *Quintessence Int* 1997;28:363-72.
  35. Steinhäuser S, Richter U, Richter F, Bill J, Rudzki-Janson I. Profile changes following maxillary impaction and autorotation of the mandible. *J Orofac Orthop* 2008;69:31-41.
  36. Agrawal AA. Gingival enlargements: Differential diagnosis and review of literature. *World J Clin Cases* 2015;3:779-88.
  37. Humayun N, Kolhatkar S, Souiyas J, Bhola M. Mucosal coronally positioned flap for the management of excessive gingival display in the presence of hypermobility of the upper lip and vertical maxillary excess: a case report. *J Periodontol* 2010;81:1858-63.
  38. Rubinstein AM, Kostianovsky AS. Cosmetic surgery for the malformation of the laugh: Original technique in Spanish. *Prensa Med Argent* 1973;60:952.
  39. Litton C, Fournier P. Simple surgical correction of the gummy smile. *Plast Reconstr Surg* 1979;63:372-3.
  40. Grover HS, Gupta A, Luthra S. Lip repositioning surgery: A pioneering technique for perio-esthetics. *Contemp Clin Dent* 2014;5:142-45.
  41. Polo M. Botulinum toxin type A (Botox) for the neuromuscular correction of excessive gingival display on smiling (gummy smile). *Am J Orthod Dentofacial Orthop* 2008;133:195-203.
  42. Aly LA, Hammouda NI. Botox as an adjunct to lip repositioning for the management of excessive gingival display in the presence of hypermobility of upper lip and vertical maxillary excess. *Dent Res J (Isfahan)* 2016;13:478-83.
  43. Van der Geld P, Oosterveld P, Schols J, Kuijpers-Jagtman AM. Smile line assessment comparing quantitative measurement and visual estimation. *Am J Orthod Dentofacial Orthop* 2011;139:174-80.
  44. Kokich Jr VO, Kiyak HA, Shapiro PA. Comparing the Perception of Dentists and Lay People to Altered Dental Esthetics. *J Esthetic Dentistry* 1999;11:311-24.
  45. Geron S, Atalia W. Influence of sex on the perception of oral and smile esthetics with different gingival display and incisal plane inclination. *Angle Orthod* 2005;75:778-84.
  46. Jananni M, Sivaramakrishnan M, Libby TJ. Surgical correction of excessive gingival display in class I vertical maxillary excess: Mucosal strip technique. *J Nat Sci Biol Med* 2014;5:494-8.