

Imatinib Mesylate-Induced Lichen Planus and Plamopantar Hyperkeratosis: A Case Report and Literature Review

Alita Sombatmaithai, M.D., Charussri Leeyaphan, M.D., Woraphong Manuskiatti, M.D., Penvadee Pattanaprichakul, M.D.

Department of Dermatology, Faculty of Medicine Siriraj Hospital, Mahidol University, Bangkok 10700, Thailand.

ABSTRACT

Imatinib mesylate is a tyrosine kinase inhibitor. Lichenoid reaction due to imatinib mesylate is rare. Most cases have cutaneous lesion with or without mucosal lesion. Mucosal involvement alone was rare. The length of time before the adverse effects appeared after the initiation of the drug ranged from one to six months. There have been few case reports with palmoplantar hyperkeratosis after one to seven months of imatinib mesylate treatment. Nail dystrophy was also present. This presented patient demonstrated cutaneous and mucosal lichenoid lesions as well as plamopantar hyperkeratosis after taking imatinib for ten weeks. Histopathology was consistent with lichenoid reaction. Therefore it is important to recognize this side effect of imatinib for early diagnosis and treatment.

Keywords: Imatinib, lichenoid reaction, plamopantar hyperkeratosis

Siriraj Med J 2014;66:231-233

E-journal: <http://www.sirirajmedj.com>

CASE REPORT

A 70-year-old Thai female presented with abdominal pain in January 2010. She was diagnosed with gastrointestinal stromal tumor and was treated with imatinib mesylate 400 mg/day. Ten weeks after starting the treatment, she developed a generalized pruritic violaceous eruption on her trunk, face, palms and soles.

Her underlying disease was hypertension and was previously treated with amlodipine and hydrochlorothiazide. She discontinued all medications by herself because of abdominal pain since

December 2009. She had no history of previous drug allergy. There was no family history of similar skin condition.

Physical examination revealed whitish reticulated plaques which were seen on the buccal mucosa and tongue and generalized well-defined scaly violaceous papules and plaques on the trunk, face and lower lip. Well-defined hyperkeratotic plaques were noted on palms and soles. Nails, hairs and genitalia were normal.

The histologic examination demonstrated markedly irregular acanthosis of the epidermis with compact orthokeratosis and focal parakeratosis. There was wedge-shaped hypergranulosis with vacuolar degeneration of basal cells obscured by lichenoid infiltration composed of lymphocytes and eosinophils. Scattered necrotic keratinocytes were found at her dermoepidermal junction with melanin incontinence in the papillary dermis.

Correspondence to: Charussri Leeyaphan

E-mail: charussrilee@gmail.com

Received 30 July 2014

Revised 9 September 2014

Accepted 16 September 2014

Direct immunofluorescence (DIF) study showed C3 deposited at her dermoepidermal junction with granular pattern and at colloid body. DIF of fibrin was negative.

DISCUSSION

Imatinib mesylate (Gleevec[®]) is a tyrosine kinase inhibitor. This agent blocks signaling via BCR-ABL, c-kit and platelet-derived growth factor receptor (PDGFR) by binding to the adenosine triphosphate-binding pocket which is required for phosphorylation and activation of the receptor. The end result is inhibition of tumor proliferation. Gastrointestinal stromal tumor (GIST) demonstrates mutation of KIT or PDGFR proto-oncogenes. The mutation leads to abnormal protein which is activated and enables oncogenic signaling in the cell. Imatinib mesylate has been approved in the USA as the first line therapy for GIST and chronic myeloid leukemia.^{1,2}

Most adverse reactions of imatinib mesylate including nausea, abdominal pain, diarrhea, myalgia and edema (commonly involving the periorbital areas and lower extremities) which are mild to moderate.² Approximately 31-44% of patients taking imatinib mesylate experience cutaneous reactions.³ The most common cutaneous reaction is a maculopapular rash affecting the forearms and trunk.² Other cutaneous reactions include hair hypopigmentation, pruritus and pityriasis rosea-like eruption.^{4,5} Severe cases with acute generalized exanthematous pustulosis, exfoliative dermatitis and Stevens-Johnson syndrome have also been reported.⁶⁻⁸

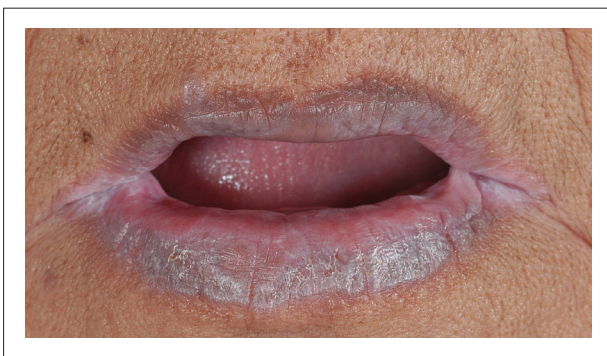

Fig 1. Physical examination revealed generalized well-defined scaly violaceous plaques on lower lip.

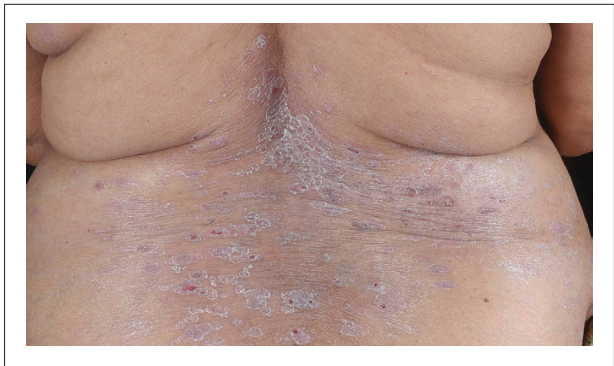


Fig 2. Physical examination revealed generalized well-defined scaly violaceous papules and plaques on the trunk.

Lichenoid reaction due to imatinib mesylate is rare. In 2010, Kuraishi N, et al., reviewed cutaneous side effect from Imatinib mesylate which had variable degrees of involvement. Most of them (78.6%) had only cutaneous lesions which might be mild to extensive. Mucosal involvement alone was rare (14.3%).² Moreover, from the literature reviews, there were only three cases presented with mucocutaneous eruption with palmoplantar involvement, the same clinical presentation as the presented patient.^{1,2} The length of time before the adverse effects appeared after the initiation of the drug ranged from one to six months.² Nail dystrophy was also present.^{1,2} The incidence and severities of adverse effects tend to depend on the dosage of imatinib mesylate. Most of the patients took imatinib mesylate 400 mg/day when they

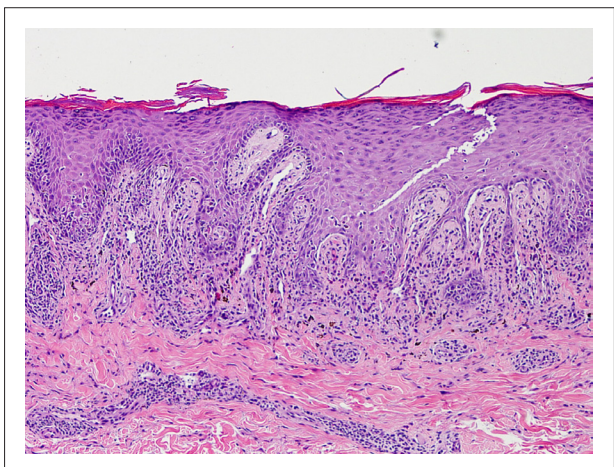


Fig 3. The histologic examination demonstrated focal parakeratosis. There are wedge-shaped hypergranulosis with vacuolar degeneration of basal cells obscured by lichenoid infiltration.

developed reaction. Discontinuation or dosage reduction of imatinib mesylate might have led to the improvement of lesions. Most of the patients could continue imatinib mesylate treatment by controlling skin lesion with topical steroid. In few patients, a systemic corticosteroid was required to improve the skin symptoms.² There was a report of a patient whose skin lesion was successfully treated with acitretin, enabling the continuation of the effective imatinib mesylate dosage.⁹

The mechanism of cutaneous reaction from imatinib mesylate is unclear. Patch testing and drug-induced lymphocyte stimulation test for imatinib mesylate were usually negative. The dose dependency of adverse events and its relatively low molecular weight support a hypothesis that imatinib mesylate-related cutaneous reactions are mediated by its pharmacological effect changing tyrosine kinase signalling rather than immunological mechanisms including hypersensitivity to this drug. A gradual increase in the dose may allow us to reinstitute the therapy after the resolution of cutaneous eruptions. The use of a systemic or topical corticosteroid and a gradual increase in the imatinib mesylate dose could be a practical strategy to enable the continuation of treatment with imatinib mesylate.^{1,2}

Although PDGF and c-kit have not been identified in normal keratinocytes, c-kit was recently found to be expressed by murine epithelial cells. Several lines of evidence have suggested that PDGF and stem cell factor may be involved in the pathogenesis of psoriasis, suggesting a possible mechanism of action for imatinib mesylate in the induction of the psoriasiform palmoplantar hyperkeratosis. The possibility that altered expression of c-kit may induce epidermal inflammation and other changes in epidermal homeostasis need further investigation.^{1,2} Hypopigmentation due to imatinib mesylate may be related to the inhibition of melanocyte c-kit receptor tyrosine kinase.¹⁰

Lichenoid drug eruption must be differentiated to idiopathic lichen planus, as they have similar clinical and histological features. Absence of Wickham striae, predominately photo distributed pattern with onset corresponding with the drug administration may be suggestive of lichenoid drug eruption. Histologically, focal parakeratosis

and the presence of eosinophils are compatible with lichenoid drug eruption. Although, the presented patient had widespread cutaneous lesions which were not spared from her sun-protected area, the onset of the eruption occurred after exposure to this medication and the histopathology showed focal parakeratosis and eosinophils infiltration were suggestive of lichenoid drug eruption. This presented patient demonstrated cutaneous and mucosal lichenoid lesions as well as palmoplantar hyperkeratosis after taking imatinib for ten weeks. Histopathology was consistent with lichenoid reaction. Therefore it is important to recognize this side effect of imatinib for early diagnosis and treatment.

REFERENCES

1. Deguchi N, Kawamura T, Shimizu A, Kitamura R, Yanagi M, Shibagaki N, et al. Imatinibmesylate causes palmoplantar hyperkeratosis and nail dystrophy in three patients with chronic myeloid leukaemia. *Br J Dermatol*. 2006 Jun;154(6):1216-8.
2. Kuraishi N, Nagai Y, Hasegawa M, Ishikawa O. Lichenoid drug eruption with palmoplantar hyperkeratosis due to imatinibmesylate: a case report and a review of the literature. *Acta Derm Venereol*. 2010;90(1):73-6.
3. Feininger MW, O'Brien SG, Ford M. Practical management of patients with chronic myeloid leukemia receiving imatinib. *J Clin Oncol*. 2003 Apr 15;21(8):1637-47.
4. Guilhot F. Indications for imatinibmesylate therapy and clinical management. *Oncologist*. 2004;9(3):271-81.
5. Konstantopoulos K, Papadogianni A, Dimopoulou M, Kourelis C, Meletis J. Pityriasisrosea associated with imatinib (STI571,Gleevec). *Dermatology*. 2002;205(2):172-3.
6. Brouard MC, Prins C, Mach-Pascual S, Saurat JH. Acute generalized exanthematouspustulosis associated with STI571 in a patient with chronic myeloid leukemia. *Dermatology*. 2001;203(1):57-9.
7. Banka N, Aljurf M, Hamadah I. Imatinib (STI-571)-induced exfoliative dermatitis in a Saudi patient with deck chair sign. *Dermatology*. 2003;207(3):329-30.
8. Hsiao LT, Chung HM, Lin JT, Chiou TJ, Liu JH, Fan FS, et al. Stevens-Johnson syndrome after treatment with STI571: a case report. *Br J Haematol*. 2002 Jun;117(3):620-2.
9. Dalmau J, Peramiquel L, Puig L, Fernandez-Figueras MT, Roe E, Alomar A. Imatinib-associated lichenoid eruption: acitretin treatment allows maintained antineoplastic effect. *Br J Dermatol*. 2006 Jun;154(6):1213-6.
10. Leong KW, Lee TC, Goh AS. Imatinibmesylate causes hypopigmentation in the skin. *Cancer*. 2004 Jun 1;100(11):2486-7.