

# Laparoscopic Resection of a Large Omental Cyst: A Case Report

Anuchit Lerstsirithong, M.D.\*, Thawatchai Akaraviputh, M.D.\*, Ananya Pongpaibul, M.D.\*\*\*, Atthaporn Trakarnsgna, M.D.\*, Chainarong Phalanusitthepha, M.D.\*, Voraboot Taweeruthchana, M.D.\*, Asada Methasate, M.D.\*, Jirawat Swangsri, M.D.\*, Thammawat Parakonthun, M.D.\*, Vitoon Chinswangwattanakul, M.D.\*

\*Department of Surgery, \*\*Department of Pathology, Faculty of Medicine Siriraj Hospital, Mahidol University, Bangkok 10700, Thailand.

## ABSTRACT

**Objective:** Mesenteric and omental cyst are the rare intra-abdominal pathologies. We report laparoscopic excision of a large omental cyst in an adult patient.

**Methods:** A 56 year-old female presented with a year history of upper abdominal pain with palpable mass at epigastrium. On physical examination, a non-tenderness mass, 8 cm in diameter, was noted in the right upper abdomen. Abdominal CT revealed large thin wall cyst without solid nodule or septation at right upper abdomen. Endoscopic ultrasonography revealed no demonstration of its origin without connection to duodenal wall, pancreatic and bile duct. The patient underwent a complete excision by laparoscopic approach. Intraoperative finding revealed an encapsulated thin wall smooth surface cystic mass in lesser sac. The patient made an uneventful postoperative recovery. Pathological examination showed simple mesothelial cyst.

**Discussion:** Omental cysts often tends to be asymptomatic and is identified incidentally on imaging studies or at laparotomy. Ultrasonography, computed tomography and magnetic resonance imaging is a useful investigation to a correct diagnosis in patients with large cystic mass. Endoscopic ultrasonography is useful in distinguishing lesions arising in the wall of the GI tract from lesions. The complete excision is the treatment of choice. The advantages of laparoscopic approaches compared with open surgery are less postoperative pain, earlier recovery, shorter hospital stay, and better cosmetic. However, minimally invasive techniques should not compromise the basic surgical principles of complete excision.

**Conclusion:** In our patient, we confirm the feasibility and safety of laparoscopic resection in large omental cyst.

**Keywords:** Omental cyst; laparoscopic resection; mesenteric cyst

Siriraj Med J 2016;68:313-316

E-journal: <https://www.tci-thaijo.org/index.php/sirirajmedj>

## INTRODUCTION

Mesenteric and omental cyst are the rare intra-abdominal pathologies occurring in approximately 1 of 105,000 hospitalized patients.<sup>1</sup> The omental cysts are rarer that was first described by Gairdner in 1852<sup>2</sup>, with

only about 150 cases reported till now<sup>3-5</sup>, the true incidence of omental cyst may be much higher than reported cases in literature because usually only cysts of clinical importance are reported. Omental cysts occur more frequently in childhood and nearly 70% are diagnosed before the age of 30 years.<sup>1</sup>

Nowadays, helicoidal CT scan allows a better preoperative diagnosis. In surgical literature, there are many authors reported laparoscopic excision of a omental cyst, showing feasibility and the advantages of the technique. We report

Corresponding Author: Thawatchai Akaraviputh

E-mail: [sitak@mahidol.ac.th](mailto:sitak@mahidol.ac.th)

Received 22 September 2016

Revised 5 October 2016

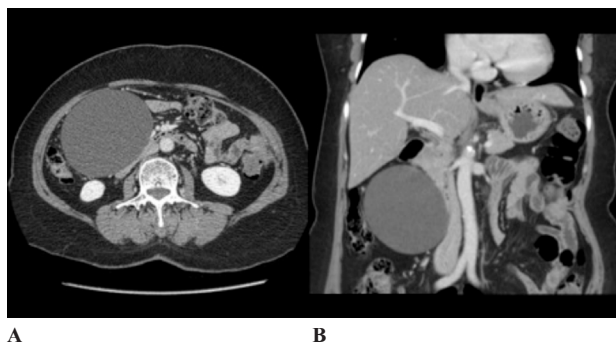
Accepted 10 October 2016

laparoscopic excision of a large omental cyst in an adult patient.

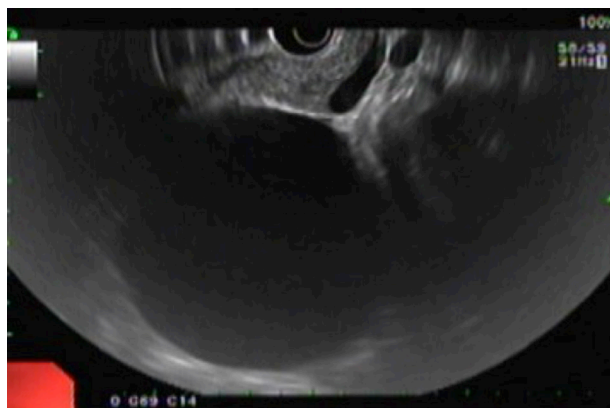## CASE REPORT

A 56-year-old female presented with a year history of upper abdominal pain with palpable mass at epigastrium. The pain was described as dull without radiation. There were no aggravating or relieving factors. She had no gastrointestinal or genitourinary symptoms. Past medical history was unremarkable but she had history of lower abdominal surgery (TAH with BSO) with low-midline surgical scar since 4 years ago. Previously, she went to other hospital and abdominal ultrasonography was performed. After observed and followed up, the abdominal mass increased in size.

On physical examination, a non-tenderness mass, 8 cm in diameter, was noted in the right upper abdomen. The remainder of the examination was normal. Abdominal CT revealed large thin wall cyst without solid nodule or septation at right upper abdomen, anterior to duodenum and compress third part duodenum but no evidence of gut obstruction (Fig 1). Some parts of cyst abut against third part of duodenum without fat plane in between. Endoscopic ultrasonography was performed to evaluate the invasion of this lesion (Fig 2). It revealed large thin wall cyst without septation or nodule at antero-lateral to second part of duodenum and no demonstration of its origin without connection to duodenal wall, pancreatic and bile duct. There was no adjacent lymph node enlargement.

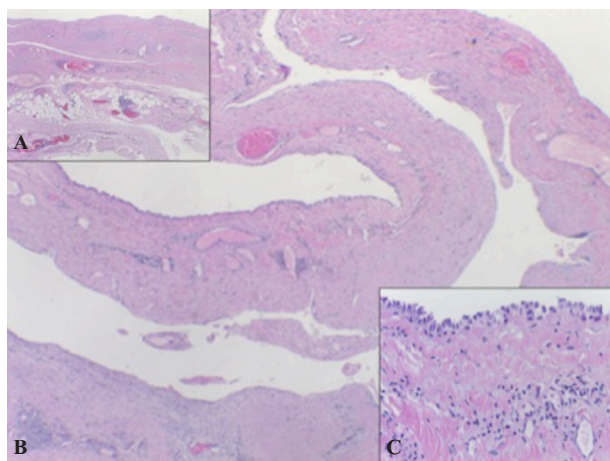


**Fig 1.** Contrast enhanced computed tomography showing large thin wall cyst without solid nodule or septation at right upper abdomen, anterior to duodenum. (a. Cross sectional view, b. Coronal view)



**Fig 2.** Endoscopic ultrasonography showing large thin wall cyst without septation or nodule at antero-lateral to second part of duodenum and no demonstration of its origin.

The patient underwent a complete excision by laparoscopic approach. Vertical supra-umbilical incision was made then balloon port 10 mm was placed and carbon dioxide was insufflated to establish a pneumoperitoneum of 12 to 14 mm Hg. Once the pneumoperitoneum was established, 10 mm 30 degrees laparoscope was applied. The initial evaluation revealed an encapsulated thin wall smooth surface cystic mass located in lesser sac between stomach, duodenum and transverse colon, 6 cm in diameter. Two of additional ports 5 mm were placed at epigastric area and left upper quadrant mid clavicular line, 5 cm from costal margin. Cyst was dissected from omentum and surrounding tissue. Feeding vessels from greater omentum were ligated by 2 hemolocks then



**Fig 3.** The cyst wall composes of fibrous tissue with mild chronic inflammation (a). Part of the cyst wall is covered by omental fat (b). The inner surface of the cyst is focally lined by mesothelial cells (c).

divided. After a full mobilization, the cyst was aspirated without spillage by a laparoscopic needle, which showed deep straw-color fluid inside and sent for cytological study and CEA. The collapsed cyst was removed intact and taken away into Endo-bag and removed via laparoscopic port. The patient made an uneventful postoperative recovery. Diet was commenced the next day of surgery and she was discharged the postoperative day 2.

Pathological examination showed fibrous wall cyst with mild chronic inflammatory infiltration. The inner surface of the cyst wall was mostly denuded. Focal area demonstrated mesothelial cell lining (Fig 3). Cytological examination revealed only mature lymphocytes without malignant cells and CEA was 11.45 ng/ml. The patient remains well with no evidence of recurrence 1 year following surgery.

## DISCUSSION

The pathogenesis of primary cysts of the omentum is unclear. Embryonic, traumatic, neoplastic or infectious etiologies have been suggested.<sup>6</sup> The most common theory is that it is benign proliferations of ectopic lymphatics that lack communication with the normal lymphatic system that had failed to communicate normally with the lymphatic system.<sup>7</sup> The incidence of mesenteric and omental cyst is approximately 1 of 105,000 in hospitalized adult patients.<sup>1</sup> In 1852, Gairdner described an omental cyst<sup>2</sup> defined as a cyst within the lesser or greater omentum, with endothelium lining, representing 1/3 to 1/10 of mesenteric cysts. The true incidence of omental cyst may be much higher than reported cases in literature because usually only cysts of clinical importance are reported.

Omental cysts often are asymptomatic and identified incidentally on imaging studies or at laparotomy. Clinical presentations include an abdominal painless mass, abdominal distention, abdominal pain, and possible ascites.<sup>8-10</sup> Acute abdominal pain symptom may be present due to torsion, intracystic hemorrhage, or rupture. Clinically, omental cysts have been described as being mobile in all directions in contrast to

mesenteric cysts, which are usually mobile in one plane only.<sup>1,11</sup> Apart from ascites, other differential diagnoses of omental cysts include cystic lesions such as choledochal cysts, splenic cysts, pancreatic cysts and cystadenomas, multicystic dysplastic kidney, gastrointestinal duplication cysts, and ovarian cysts.<sup>12</sup>

Ultrasonography (US) is a useful preliminary investigation in assessment of patients suspected of having a cystic abdominal mass but may fail to determine the precise location. Computed tomography (CT) and magnetic resonance imaging (MRI) help establish a correct diagnosis in patients with large cystic masses, because they are generally able to differentiate mesenteric, omental, and retroperitoneal cysts from other cystic lesions, such as enteric duplication, ovarian cyst, and pancreatic pseudocyst.<sup>13</sup> Our patient underwent endoscopic ultrasonography (EUS) due to there are some parts of cyst abut against third part of duodenum from CT. The utility of EUS is in providing a minimally invasive approach to the preoperative diagnosis of an omental cyst. It is especially useful in distinguishing lesions arising in the wall of the GI tract from lesions which are outside but are abutting against the wall.<sup>14</sup>

The complete excision is the treatment of choice for omental cystic, an intestinal resection is virtually never indicated. The elevated incidence of relapse and infection contraindicate other conservative procedures, like percutaneous aspiration, marsupialization, or laparoscopic unroofing of the surface.<sup>6,15</sup> Nowadays, there are several laparoscopic managements of omental cysts.<sup>11,16-20</sup> The advantages of these laparoscopic approaches compared with open surgery are almost the same as for other laparoscopic procedures; e.g. less postoperative pain, earlier recovery, shorter hospital stay, and better cosmetic. However, minimally invasive techniques should not compromise the basic surgical principles of complete excision without tumor violation. In the case reported, careful dissection allowed for mobilization, complete resection, controlled decompression, and intact removal of the cyst. If this cannot be accomplished or doubt exists as to the benignity of the lesion, conversion to open laparotomy must be performed.

## CONCLUSION

In our patient, we confirm the feasibility and safety of laparoscopic resection in large omental cyst without compromising surgical principles and helps in early recovery.

## REFERENCES

1. Vanek VW, Phillips AK. Retroperitoneal, mesenteric, and omental cysts. *Arch Surg* 1984;119(7):838-42.
2. Gairdner W. A remarkable cyst in the omentum. *Trans Pathol Soc Lond* 1852;3:374-5.
3. Mattioli EN. Complications of mesenteric cysts; report of two cases. *J Med Soc N J* 1959;56(2):49-54.
4. Walker AR, Putnam TC. Omental, mesenteric, and retroperitoneal cysts: a clinical study of 33 new cases. *Ann Surg* 1973;178(1):13-9.
5. Bodai BI, Jung W, Marr C. Omental cyst: Case report and review of the literature. *Contemp Surg* 1983;22:83-6.
6. Kurtz RJ, Heimann TM, Holt J, Beck AR. Mesenteric and retroperitoneal cysts. *Ann Surg* 1986;203(1):109-12.
7. Kumar S, Agrawal N, Khanna R, Khanna AK. Giant lymphatic cyst of omentum: a case report. *Cases J* 2009;2:23.
8. Rahman GA, Abdulkadir AY, Olatoke SA, Uwaezuoke S, Yusuf IF, Braimoh KT. Giant neoplastic omental cyst masquerading as ascites: a case report. *Cases J* 2009;2:6482.
9. Menon P, Rao KL. Giant omental cyst masquerading as hemorrhagic ascites. *Indian Pediatr* 2005;42(4):395-6.
10. Shafi SM, Malla MA, Reshi FA. Giant primary omental cyst mimicking a pseudoascites. *Afr J Paediatr Surg* 2009;6(1):58-60.
11. Kuriansky J, Bar-Dayana A, Shabtai M, Barshach I, Rosin D, Ayalon A. Laparoscopic resection of huge omental cyst. *J Laparoendosc Adv Surg Tech A* 2000;10(5):283-5.
12. Wootton-Gorges SL, Thomas KB, Harned RK, Wu SR, Stein-Wexler R, Strain JD. Giant cystic abdominal masses in children. *Pediatr Radiol* 2005;35(12):1277-88.
13. Bhandarkar D, Ghuge A, Kadakia G, Shah R. Laparoscopic excision of an omental leiomyoma with a giant cystic component. *JSLs* 2011;15(3):409-11.
14. Goh BK, Tan YM, Ong HS, Chan WH, Yap CK, Wong WK. Endoscopic ultrasound diagnosis and laparoscopic excision of an omental lymphangioma. *J Laparoendosc Adv Surg Tech A* 2005;15(6):630-3.
15. Shamiyeh A, Rieger R, Schrenk P, Wayand W. Role of laparoscopic surgery in treatment of mesenteric cysts. *Surg Endosc* 1999;13(9):937-9.
16. Deshpande AA, Dalvi AN. Laparoscopic excision of a giant mesothelial omental cyst. *J Minim Access Surg* 2012;8(2):57-8.
17. Horiuchi T, Shimomatsuya T. Laparoscopic excision of an omental cyst. *J Laparoendosc Adv Surg Tech A* 1999;9(5):411-3.
18. Sakurai Y, Taniguchi K, Uyama I, Inaba K, Furuta S, Sunagawa R, et al. Laparoscopic excision of the cystic lymphangioma occurred in the lesser omentum: report of a case and review of literature. *Surg Laparosc Endosc Percutan Tech* 2009;19(1):e11-4.
19. Conlon KC, Dougherty EC, Klimstra DS. Laparoscopic resection of a giant omental cyst. *Surg Endosc* 1995;9(10):1130-2.
20. Conzo G, Vacca R, Grazia Esposito M, Brancaccio U, Celsi S, Livrea A. Laparoscopic treatment of an omental cyst: a case report and review of the literature. *Surg Laparosc Endosc Percutan Tech* 2005;15(1):33-5.