
CASE REPORT

Pulmonary Endometriosis: A case report

Phornsawan Wasinghon, M.D.^{*,**},
Ming-Ju Hsieh, M.D.^{***,****},
Kuan-Gen Huang, M.D.^{*,***}

^{*} Department of Obstetrics and Gynecology, Chang Gung Memorial Hospital at Linkou, Kweishan, Taoyuan, Taiwan

^{**} Department of Obstetrics and Gynecology, Buddhachinnaraj Hospital, Phitsanulok, Thailand

^{***} Chang Gung University College of Medicine, Kweishan, Taoyuan, Taiwan

^{****} Department of Thoracic Surgery, Chang Gung Memorial Hospital at Linkou, Kweishan, Taoyuan, Taiwan

ABSTRACT

A 49-year-old female had progressive diffused chest tightness for one week. Physical examination and chest film showed the right-side pneumothorax as over 40% pneumothorax. After the pneumothorax was drained by a pigtail catheter, an exploratory thoracotomy operation was conducted. The right upper lobe and pleural lesions were resected by a thoracic surgeon. The histopathology revealed emphysema of the lung, with pulmonary and pleural endometriosis. The gynecologist was consulted and laparoscopic surgery was performed for diagnosis. The endometriosis was shown at the diaphragmatic area without pelvic endometriosis. The lesions were resected. The histopathology showed endometriosis of diaphragmatic area. The five-year follow-up did not show evidence of recurrence, and hormonal treatment was not used.

Keywords: emphysema, pulmonary endometriosis, pneumothorax.

Correspondence to: Kuan-Gen Huang, M.D., Department of Obstetrics and Gynecology, Chang Gung Memorial Hospital, Linkou Medical Center and Chang Gung University College of Medicine, 5, Fuxing Street, Kweishan, Taoyuan, Taiwan 333, E-mail: kghuang@ms57.hinet.net

Received: 7 January 2019, **Revised:** 1 November 2019, **Accepted:** 6 December 2019

Introduction

Endometriosis is the presence of endometrial tissue outside of the uterus. The most common sites are the ovaries, uterosacral ligaments, uterus, and the peritoneum. The extrapelvic- endometriosis is also known as the ectopic endometrium which has been found in the umbilicus, abdominal scars, breasts, extremities, pleural cavity, and lungs. The presence of endometrial tissue in the lung is called thoracic

endometriosis syndrome (TES)⁽¹⁻²⁾. Thoracic endometriosis affects the airway, pleura, and lung parenchyma. The clinical symptoms of lung endometriosis are associated with catamenial chest pain and hemoptysis. Imaging studies and histopathological examination play important roles in the diagnosis of TES. Surgery of lung endometriosis is able to provide radical relief⁽²⁾. Important recent advances in the understanding of lung endometriosis

could guide physicians to improve the diagnosis and treatment.

Case Report

In June of 2013, a 49-year-old woman, parity 0, who had no underlying disease had progressive diffused chest tightness for one week. She had regular menstruation with no dysmenorrhea. The symptoms she suffered included mild shortness of breath and intermittent headaches for which she had visited at the emergency room at Chang Gung Memorial Hospital, Linkou, Taiwan. The patient had no fever, palpitation, or diarrhea, nor abdominal or urinary discomfort. The physical examination and chest film showed the right-side pneumothorax as over 40% pneumothorax (Fig. 1). The patient had a history of spontaneous pneumothorax for the last three years. The first episode of spontaneous pneumothorax which had occurred three years previously was treated with intercostal drainage (ICD). The second episode of pneumothorax required drainage of the pneumothorax by a pigtail catheter, by which a pigtail catheter had been used in draining air from the pleural spaces internally. The thoracic

surgeon provided treatment for wedge resection at the upper lobe of the right lung, and the right pleural lesions. The histopathology revealed emphysema, endometriosis at the right lung, and the pleura of the right lung. After the exploratory thoracotomy, the histopathological confirmation of ectopic endometriosis was obtained. The thoracic surgeon had then transferred the patient to a gynecological department for the treatment of endometriosis. The pelvic examination had regularly pelvic organs and cul-de-sac. The ultrasonography showed normal uterus and both ovaries. The ectopic endometriosis was diagnosed preoperatively. The application of laparoscopy was a consideration for intra-abdominal diagnosis. There was no evidence for pelvic endometriosis. The endometriosis spots were seen in the diaphragmatic area and were resected (Fig. 2). The tissue biopsies showed the endometriosis from the histopathological report. On the basis of the clinical outcome, the patient did not undergo the hormonal treatment. The patient had then followed-up for five years without recurrence. The study was exempt from the requirement for approval by an institutional review board.

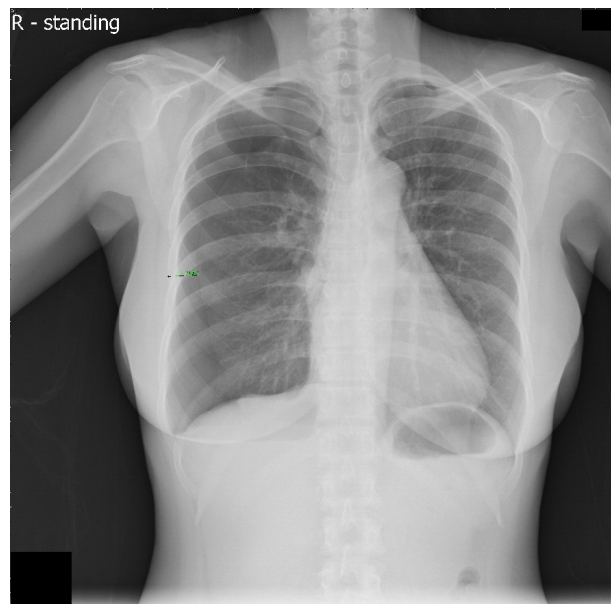


Fig. 1. Chest film showed the pneumothorax of the right lung (green line).

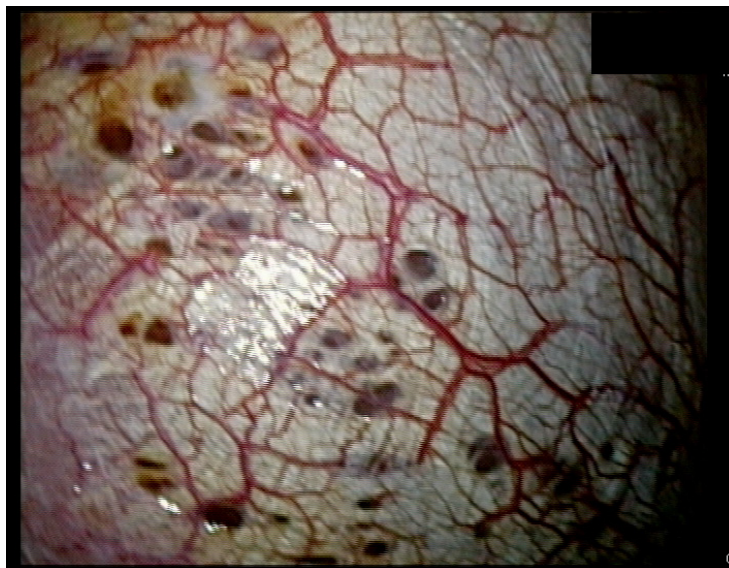


Fig. 2. The endometriotic spots located at the right diaphragmatic area.

Discussion

Endometriosis was first reported by Carl Von Rokitansky in 1860. The characteristic of endometriosis is the presence of endometrial glands outside the uterine cavity. The extrapelvic endometriosis can occur at the lung, which was called pulmonary endometriosis and thoracic endometriosis. Endometriosis of the lung is a clinically serious form of the disease. Bronchopulmonary endometriosis was first described by Hart in 1912, and the catamenial pneumothorax was described in 1956. The symptoms consist of catamenial pneumothorax, catamenial hemoptysis, catamenial haemothorax, and pulmonary nodule⁽¹⁾. The spread of distant endometriosis rests on hypotheses of venous or lymphatic circulation⁽²⁾. The catamenial hemoptysis had been reported for 74 cases. Of these, 37 cases were in the right lung, 19 cases were in the left, and 6 cases were bilateral⁽¹⁾. Thoracic endometriosis appears through various clinical presentations such as catamenial pneumothorax (73%), catamenial hemothorax (14%), catamenial hemoptysis (7%), and lung nodules (6%). The 61 patients with pulmonary endometriosis who underwent gynecological

examination showed no evidence of pelvic endometriosis. The Computed-Tomography (CT) findings for pulmonary endometriosis included well-defined opacities, thin-wall cavities, and nodular lesions⁽³⁾. As in our case, the patient suffered from tightness of breath, and right side spontaneous pneumothorax without underlying disease, while she had a history of spontaneous pneumothorax for the last three years. The CT findings showed nodular lesions and well-defined opacities in both lungs and the right lung pneumothorax. The thoracic endometriosis had been reported with the recurrence rate of pneumothorax within four years. Surgical treatment is controversial while depending on the severity of the clinical symptoms and signs⁽¹⁻³⁾ as shown in Table 1. In our case, the first episode of spontaneous pneumothorax from three years previously was treated with ICD. The patient had undergone resection of the tissues at the upper lobe of the right lung and the right pleural nodule lesions to relieve dyspnea in the second episode of spontaneous pneumothorax. The patient had histopathological endometriosis of the lung. Laparoscopy was used to explore the pelvic endometriosis, and then the endometriosis spots

were seen in the diaphragmatic area and were resected. The histopathological examination confirmed endometriosis of the diaphragmatic area with no pelvic endometriosis. The pulmonary endometriosis was mostly diagnosed with thoracoscopy or thoracic surgery. The prognosis depended on the response of hormonal therapy during follow-up⁽⁷⁾. The patient had been followed up for 5 years without recurrence of pulmonary endometriosis or pelvic endometriosis, so hormonal treatment was not prescribed for the long-term treatment of this patient. After surgery, the recurrence rate during hormonal therapy was 0.05 times per year. The recurrences were detected during the period without hormonal therapy were 0.14 times per

year⁽⁷⁾. The postoperative hormonal treatment could reduce the recurrence rate including gonadotropin-releasing hormone agonist (GnRH), dienogest, continuous oral contraceptives (OCs), and cyclic OCs⁽¹⁻⁸⁾. The recurrence rates were 0%, 16.7%, 18%, 33% with GnRH agonists, dienogest, continuous OCs, cyclic OCs⁽⁷⁾.

The pulmonary endometriosis is preoperatively difficult to diagnose from the symptom of catamenial pneumothorax. The multidisciplinary team consisting of a pulmonologist, thoracic surgeon, pathologist, gynecologist, and the radiologist is required to helping diagnose and provide treatment of pulmonary endometriosis as soon as possible to avoid delayed diagnoses.

Table 1. The review of pulmonary endometriosis.

Author	Year	Age	Symptoms	Investigation	Surgery
Huang H, et al. ⁽¹⁾	2013	29	Catamenial hemoptysis	Chest CT: opaque lesion in the left superior lobe	Explore thoracotomy
Pankratjevaite L, et al. ⁽²⁾	2017	36	Chest pain, breathlessness	Severe bleeding through the chest probe	Right side minithoracotomy
Maniglio P, et al. ⁽³⁾	2017	37	Chest pain, breathlessness	Chest film and CT chest: pneumothorax	Thoracoscopic resection
Ichiki Y, et al. ⁽⁴⁾	2012	28-40	Right side spontaneous pneumothorax	Chest film and CT chest: pneumothorax	VATS
Mukku V, et al. ⁽⁵⁾	2019	40	Chest tightness	Chest CT: pneumothorax	VATS
Shikino K, et al. ⁽⁶⁾	2016	46	Chest pain	Chest CT: pneumothorax	VATS
Fukuda S, et al. ⁽⁷⁾	2018	18-47	Dyspnea	Chest film or Chest CT	Thoracoscopic surgery
Furuta C, et al. ⁽⁸⁾	2018	26-42	Dyspnea	Chest film or Chest CT	Thoracoscopic surgery

CT: Computed Tomography, VATS: Video assist thoracoscopic surgery

Acknowledgement

The authors appreciate the Asia-Pacific Association for Gynaecologic Endoscopy and Minimally Invasive Therapy (APAGE) for providing the International Fellowship Endoscopy Training Program at Chang Gung Memorial Hospital for Dr. Phornsawan Wasinghon

Potential conflicts of interest

The authors declare no conflict of interest.

References

1. Huang H, Li C, Zarogoulidis P, Darwiche K, Machairiotis N, Yang L. et al. Endometriosis of the lung: report of a case and literature review. *Eur J Med Res* 2013;18:13-8.
2. Pankratjevaite L, Samiatina-Morkuniene D. A case report of thoracic endometriosis - A rare cause of haemothorax. *Int J Surg Case Rep* 2017;33:139-42.
3. Maniglio P, Ricciardi E, Meli F, Vitale SG, Noventa M, Vitagliano A. et al. Catamenial pneumothorax caused by thoracic endometriosis. *Radiol Case Rep* 2018;13:81-5.
4. Ichiki Y, Nagashima A, Yasuda M, Takenoyama M, Toyoshima S. Surgical treatment of catamenial pneumothorax: report of three cases. *Asian J Surg* 2015;38:180-5.
5. Mukku V, Cassidy E, Negulescu C, Jagneaux T, Godke J. Large Spontaneous Right Catamenial Pneumothorax with Diaphragmatic Defect and Liver Herniation. *Case Rep pulmonol* 2019:1-4.
6. Shikino K, Ohira Y, Ikusaka M. Catamenial pneumothorax. *J Gen Intern Med* 2016;31:1260.
7. Fukuda S, Hirata T, Nerilshi K, Nakazawa A, Takamura M, Izumi G. et al. Thoracic endometriosis is syndrome: Comparison between catamenial pneumothorax or endometriosis-related pneumothorax and catamenial hemoptysis. *Eur J Obstet Gynecol Reprod Biol* 2018;225:118-23.
8. Furuta C, Yano M, Numanami H, Yamaji M, Taguchi R, Haniuda M. Nine cases of catamenial pneumothorax: a report of a single center experience. *J Thorac Dis* 2018;10:4801-5.