
OBSTETRICS

Prediction of the Mode of Delivery using Intrapartum Translabial Ultrasound in a Teaching Hospital in South India – A prospective observational study

Vinutha MB, MBBS, DGO, Secondary DNB.*,

Vinutha Vinod, MBBS, DGO, DNB.*

Chitra Kotian, BDS, MPH.*,

Krupa Shah, MBBS, M.D.*,

Shashikala K Bhat, MBBS, M.D.*

** Department of Obstetrics and Gynecology, DR. TMA Pai Hospital, Udupi, Melaka Manipal Medical College, Manipal Academy of Higher Education, Karnataka, India*

ABSTRACT

Objectives: Cervical effacement and dilatation, station of the presenting part, and fetal head position are the key determinants of progress of labor. There is growing evidence about the usefulness of intrapartum ultrasound in evaluating the labor parameters objectively to decide about the labor management. Hence, intrapartum translabial ultrasound was studied to predict the mode of delivery.

Materials and Methods: 185 laboring women with singleton pregnancy, term gestation, and cephalic presentation with 4 cm. cervical dilatation were included. Intrapartum translabial ultrasound was done to note angle of progression (AoP), cervical length, and position of the fetal head.

Results: Among 185 women, 121 (65.4%) had vaginal (112 normal and 9 assisted vaginal) and 64 cesarean (34.6%) delivery. An angle of progression of 89° with area under the curve (AUC) 0.789 ($p \leq 0.0001$) measured in the early active phase of labor had a sensitivity, specificity, positive predictive value and negative predictive value of 79.3% and 65.6%, 81.3% and 62.7% respectively. The positive likelihood ratio and the negative likelihood ratio were 2.3 and 0.315, respectively. The clinical utility index for AoP was 0.644 in predicting the mode of delivery. AUC for cervical length was 0.534 ($p = 0.452$), which was not significant. The odds ratio for occipitoanterior position in predicting vaginal delivery was 3.9.

Conclusion: Intrapartum translabial ultrasound is a reproducible and feasible method to evaluate labor parameters. Assessing multiple components like the angle of progression, cervical length, and position of the fetal head in early labor could help to predict the mode of delivery.

Keywords: angle of progression, cervical length, mode of delivery, position of fetal head, intrapartum translabial ultrasound.

Correspondence to: Shashikala K Bhat, M.D., Department of Obstetrics and Gynecology, DR. TMA Pai Hospital, Udupi, Melaka Manipal Medical College, Manipal Academy of Higher Education, Karnataka, India
Email: shashikala.bhat@manipal.edu

Received: 8 April 2021, **Revised:** 4 August 2021, **Accepted:** 4 August 2021

Introduction

Cervical effacement and dilatation, station of the presenting part, and fetal head position are the key determinants of labor progress. Progress of labor has been evaluated clinically by transvaginal digital examination traditionally. Ultrasound has become an useful investigation in the labor rooms in the current day practice^(1,2). Novel intrapartum ultrasound techniques^(3,4) were introduced for to determine position⁽⁵⁾ and station, especially before an instrumental delivery when the presence of caput succedaneum jeopardizes the clinical judgment⁽⁶⁾. Angle of progression (AoP) is one of the most reliable parameters to predict the mode of delivery⁽⁷⁻⁹⁾. Intrapartum ultrasound shows high diagnostic accuracy in determining engaged fetal head at angle of progression of $\geq 101^\circ$ ⁽¹⁰⁾ and also indicates the trends in the duration of labor⁽¹¹⁾. Intrapartum abdominal and transperineal ultrasound parameters using head station, cervical dilatation, and AoP have found clinical applicability to predict labor⁽¹²⁾. Transperineal ultrasound has been found useful even after full cervical dilatation to predict vaginal delivery and is a useful reproducible adjunct to determine position and station, especially before an instrumental delivery⁽¹³⁾. The images obtained by ultrasound can be stored in medical records. Identifying women are at risk for cesarean delivery helps in improving pregnancy outcomes by avoiding unplanned emergency cesarean section and improves childbirth experience. Hence, we set out to study the role of intrapartum translabial ultrasound (ITU) with the mode of delivery. The primary objective was to study the role of AoP, cervical length, and position of the fetal head in predicting the mode of delivery in early labor. The secondary objective was to establish a cut-off value for AoP to predict the mode of delivery.

Materials and Methods

This was a prospective observational study conducted from April 2019 to November 2019 in the Department of Obstetrics and Gynaecology, Dr.

TMA Pai Hospital, Udupi. The study population consisted of women in labor admitted in Dr TMA Pai Hospital, Udupi, and fulfilling the inclusion criteria. Women in established labor (cervical dilatation of 4cm) with live, singleton pregnancy at term in cephalic presentation were included. Those with multiple gestation, malpresentation, previous cesarean delivery, uterine surgeries and anomalous uterus were excluded. Anticipating 95% confidence interval, 5% error margin, a sample size of 185 was calculated based on a study by Perez, et al⁽⁸⁾, wherein area under the curve for AoP was 0.85 (95% confidence interval 0.77-0.92). Institutional Ethical Committee clearance was obtained (KH IEC number: 105/2019) and CTRI (Clinical Trial Registry India) registration (CTRI/2019/04/018508) was done. Informed consent was obtained from the subject after explaining the study and F form was documented as per regulatory requirements by the government of India.

Ultrasonography was performed when cervical dilatation was 4 cm. Translabial ultrasound was carried out using either PHILIPS CLEARVUE 350 or SONOSITE M-TURBO ultrasound machine with 5MHz curvilinear transducer c5-2. Subjects were put in dorsal position with an empty urinary bladder. The ultrasound probe was enclosed in a latex disposable glove covered with ultrasound gel.

For the AoP, the probe was placed vertically between labia below the pubic symphysis in the midsagittal plane. An image where the long axis of the pubic symphysis and the leading portion of the fetal head could be made out was obtained. A line was drawn between callipers placed at two ends of the long axis of pubic symphysis (a). The second line was drawn from distal point of the pubic symphysis tangentially to the fetal skull contour (b). AoP was measured manually^(2,14) (Fig. 1).

Measurement of cervical length was done in sagittal plane. It was measured from internal os to the external os⁽¹⁵⁾ (Fig. 2). Three measurements were taken, and the average of the 3 measurements was noted.

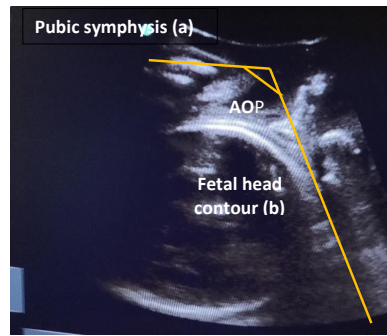


Fig. 1. Sagittal view for measuring angle of progression.

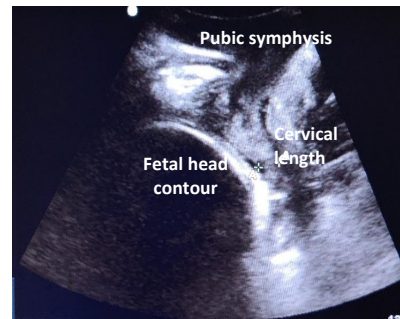


Fig. 2. Sagittal view showing cervical length.

Ultrasound assessment of the fetal head position was done by swinging the transducer across the axial and sagittal planes. The position was assessed utilizing the midline intracranial structures (cavum septum pellucidum, falx cerebri, thalamus, and cerebellar hemispheres) and anterior or posterior cranial structures (orbits, nasal bridge and cervical spine). Position was

described by depicting a circle, like a clock. Depiction of fetal occiput based on hour hand on a clock: positions 2:00 and 4:00 hours were recorded as left occiput transverse (LOT); positions 8:00 and 10:00 hours as right occiput transverse (ROT); positions from 4:00 and 8:00 hours as occiput posterior; and positions 10:00 and 2:00 hours as occiput anterior (Fig. 3).

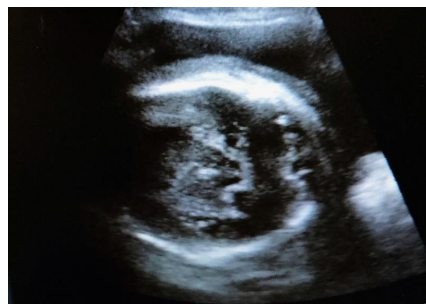

Fig. 3. Ultrasound image of left occipito-transverse position.

The primary outcome measure was to predict the mode of delivery using AoP, cervical length, and position of the fetal head by translabial ultrasound. The secondary outcome was to determine the cut off value of the AoP to predicting vaginal delivery.

Data were entered in Microsoft Excel datasheet and analyzed using Scientific Package for Social Sciences (SPSS) 20 software. Analysis of demographic data was done using percentages for categorical data, mean and standard deviation for continuous data. Analysis of the AoP was done by receiver operating characteristics (ROC) curve. Sensitivity, specificity, positive predictive value and negative predictive value were measured. Cut-off value of AoP, likelihood ratios and clinical utility index were calculated. The area under

the curve (AUC) for cervical length was measured. Odds ratio for position of fetal head was calculated. Logistic regression analysis for all the variables was calculated. P value < 0.05 was considered to be statistically significant.

Results

185 laboring women were enrolled in the study. There were 121 vaginal (65.4%) and 64 cesarean (34.6%) deliveries. Among 121 vaginal deliveries, 112 were normal, and nine were assisted vaginal deliveries. Table 1 presents the demographic and clinical characteristics of the study population. Nulliparous women constituted almost three fourth (74.1%) of the study population.

Table 1. Demographic profile of the study population.

Characteristics	n = 185
Maternal age* (years)	27 ± 3
Parity	
Nulliparous** (%)	74.1
Multiparous** (%)	25.9
Gestational age* (weeks)	38 ± 0.9
Body mass index (kg/m ²)***	22 (20-26)
Birth weight* (kg)	2.9 ± 0.3

Data are presented as mean ± standard deviation* or n (%)** or median (interquartile range)***

Angle of progression (AoP)

Table 2 depicts the mean AoP, cervical length and position of fetal head in early labor (4cm of cervical dilatation) and mode of delivery. It was observed that

as the AoP increased, the chance of vaginal delivery increased. More women with higher AoP delivered vaginally (Fig. 4), whereas only one-fourth women delivered vaginally when AoP < 80°.

Table 2. Angle of progression, cervical length and position of fetal head in early labour (4cm. of cervical dilatation) and mode of delivery.

Predictors	Vaginal delivery n = 121	Caesarean n = 64
Angle of progression* (°)	106 ± 21.9	85.2 ± 14.9
Cervical length* (millimetre)	13.6 ± 5.5	14.7 ± 6.1
Occipito-anterior position** (%)	83.6	16.4
Other positions** (%)	56.5	43.5

* Angle of progression and cervical length are mentioned as mean ± standard deviation.

**Position of the fetal head is mentioned as n (%)

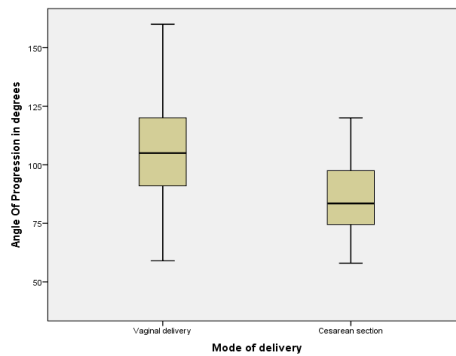


Fig. 4. Angle of progression measured by intrapartum translabial ultrasound. Median angle of progression was 83.5° (IQR 74.5-97.5) in women who had cesarean delivery which was narrower compared to angle of progression in women who had vaginal delivery (105° (IQR 91-120)).

Fig. 5 represents the ROC curve with an AUC of 0.789 (95% CI 0.723-0.855) for AoP in vaginal delivery (both spontaneous vaginal and assisted vaginal delivery). An AoP $\geq 89^\circ$ was associated with vaginal delivery in 81.4% (96 out of 118), and an AoP $< 89^\circ$ was associated with 62.9% (42 out of 67) risk for caesarean delivery. The value of AoP that optimized the curve was 89° ($p \leq 0.0001$). An AOP of 89° measured in the early active phase of labor had a sensitivity, specificity, positive predictive value, and negative predictive value

of 79.3%, 65.6%, 81.3% and 62.7%, respectively. The positive likelihood ratio and the negative likelihood ratio were 2.3 and 0.315, respectively. In primigravid women, with a cut-off value of 89° , the AUC was 0.794. The sensitivity was 80.8%, specificity was 63% ($p < 0.0001$). In multigravida women, AUC was 0.816 for 94.5° cut-off AoP, with sensitivity 72%, specificity 80% ($p = 0.022$). The Clinical Utility Index was 0.644, indicating that AoP has good utility ($CUI \geq 0.64$) in predicting the mode of delivery.

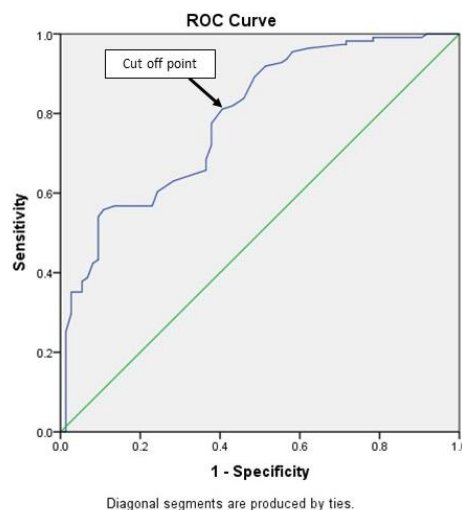


Fig. 5. Receiver operating characteristics curve for angle of progression measured in early active phase of labour in predicting vaginal delivery (AUC=0.789, $p \leq 0.0001$) at cut off of 89° .

Cervical length

Though the chance of vaginal delivery increased as cervical length decreased, cervical

length measured by ITU was not a good predictor of the mode of delivery, as shown in Fig. 6.

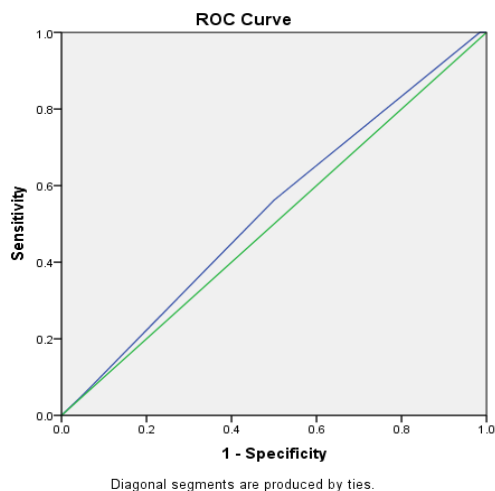


Fig. 6. Receiver operating characteristics curve for cervical length measured in early labour in predicting vaginal delivery (AUC = 0.534, $p = 0.452$).

Position of fetal head

Odds ratio for occipito-anterior position in predicting vaginal delivery was 3.9. Sensitivity for occipito-anterior position in predicting vaginal delivery was 42.42% and specificity was 84.3%. But the diagnostic accuracy of fetal head position in early labor

in predicting the mode of delivery was only 0.56.

Table 3 represents the results of binomial logistic regression analysis. After taking all variables into account in the analysis, AoP, occipito-anterior position of fetal head, and parity were the significant predictors of mode of delivery.

Table 3. Summary of binominal logistic regression analysis of all the variables in predicting the mode of delivery.

Variable	Adjusted odds ratio (95%CI)	p value
Angle of progression (°)	0.938 (0.915 -0.962)	< 0.0001
Cervical length (millimetre)	2.702 (0.481-15.166)	0.259
Occipito-anterior position	2.696 (1.034-7.035)	0.043
Age (years)	0.937 (0.845-1.039)	0.218
Parity	7.244 (2.230-23.528)	0.001
Period of gestation (weeks)	0.770 (0.501-1.183)	0.233
Body Mass Index (kg/m ²)	1.056 (0.959-1.163)	0.269
Birth weight (kg)	1.000 (0.999-1.001)	0.708

CI: confidence interval

Discussion

Intrapartum ultrasound allows objective and reproducible measurement of labor parameters and is comparable to digital vaginal examination, is non-invasive and does not cause discomfort^(16,17). With increasing resolution and easier accessibility, ultrasound is used for fetal head status (engagement, station, and position), cervical status (shortening and dilatation) and placental separation to make more reliable clinical decisions⁽¹⁸⁾. Fetal head position can be identified by transabdominal, transperineal, and translabial ultrasound to diagnose malposition in labor dystocia, especially in the second stage of labour before instrumental delivery. In recent times, intrapartum ultrasound has been used to predict the mode of delivery using one or more parameters involving cervix, station, and position of the fetal head. In this study, we showed that ITU in early labor could provide reliable measurements for predicting labor outcome.

Ultrasound determined AoP in predicting the mode of delivery

185 laboring women were included in the study population. We observed that as the AoP increased, the number of vaginal deliveries increased. With AoP $\leq 80^\circ$, 75% had cesarean delivery, and when AoP $>120^\circ$, all deliveries were vaginal. Results of our study were comparable with studies by Kalache, et al⁽¹⁹⁾ and Barbera, et al⁽⁴⁾ in 2009 which concluded that when AoP was $>120^\circ$, there was higher probability of vaginal delivery⁽¹⁹⁾. An angle of 99° - 120° correlated with zero station^(20,21). By using transperineal ultrasound, the AoP of 95° corresponded to -2 station and 116° to 0 station⁽²²⁾.

A prospective observational study was done by Levy et al in 2012 on 100 primiparous women who were not in labor, where AoP was measured by transperineal ultrasound. The AUC for the AoP was 0.878 ($p < 0.001$) with the cut-off angle of 95° . This cut-off angle had a sensitivity of 85%, a specificity of 89%, a positive predictive value of 98.7% and a negative predictive value of 86.3%. The positive likelihood ratio was 7.7 in predicting vaginal delivery⁽²³⁾. AoP $> 92^\circ$ in non-

laboring nulliparous women at term was associated with 94.8% vaginal delivery⁽²⁴⁾. In a study by Minajagi et al in 120 nulliparous women, the AoP $> 96^\circ$ was associated with vaginal delivery in 95% (76/80) of women⁽²⁵⁾. In a study by Kohl's et al, the mean AoP was 100.9° at cervical dilation < 5 cm and 125.3° at cervical dilatation > 5 cm in spontaneous vaginal deliveries. In assisted vaginal deliveries, it was 93° at < 5 cm cervical dilatation and 113.9° when > 5 cm⁽¹¹⁾.

Study by Perez et al established an AUC of 0.85 with a cut-off angle of 125° with a sensitivity of 67.1% and maximum (100%) specificity. The cut-off angle established by this study was much higher than the current study⁽⁸⁾.

Studies by Eggebo, et al⁽²⁶⁾ and Torkildsen, et al⁽²⁷⁾ were comparable to the current study with respect to the AUC of 0.75 and 0.76, respectively. The cut-off angle was 110° in both the studies. Unlike the current study, both these studies showed low sensitivity and specificity. Positive predictive value and likelihood ratios of both the studies were comparable to the present study. The odds ratio of the current study was 7.7, and it was comparable to studies by Eggebo et al (OR = 5.5) and Torkildsen et al (OR = 1.09).

Ultrasound determined cervical length in predicting the mode of delivery

In our study, translabial ultrasound was performed in all 185 study population in early labor and the cervical length was measured. Majority of the study population had a cervical length between 11 to 20 mm (55.13%) irrespective of parity. As the cervical length decreased, the chance of vaginal delivery increased with 77.8% vaginal delivery when the cervical length was < 11 mm. Tan et al compared cervical length measured by transvaginal ultrasound with Bishop score in predicting cesarean delivery. They showed that cervical length > 20 mm prior to induction was an independent predictor of cesarean delivery⁽²⁸⁾.

ROC curve for cervical length in labor showed an AUC of 0.534 ($p = 0.452$). Thus, it cannot be used as a predictor for the mode of delivery. Results of our study were comparable to study by Hamide et al in

2018, where cervical length measured by transvaginal ultrasound failed to predict the mode of delivery ($p = 0.79$)⁽²⁹⁾. In a study by Alanwar et al, the cervical length measurement by transvaginal ultrasonogram had poor predictive value for cesarean delivery ($AUC = 0.694$)⁽³⁰⁾.

In a systematic review and meta-analysis by Verhoeven et al, summary estimates of sensitivity/specificity for 20, 30 and 40 mm cervical length by ultrasound were 0.82/0.34, 0.64/0.74 and 0.13/0.95 prior to induction of labor suggesting ROC with poor predictive value for caesarean delivery⁽³¹⁾. Study by Khazardoost et al in 2016 showed an AUC of 0.628 ($p = 0.034$)⁽³²⁾.

In contrast to the results of the present study, Aggarwal et al (2019) measured cervical length by transvaginal ultrasound in 300 women, which showed a significant ($p < 0.001$) AUC of 0.72. They established a cut-off value of ≤ 3.4 cm for predicting successful induction of labor with sensitivity and specificity of 82% and 87%, respectively⁽³³⁾. The difference is likely because our study was done in early labor and this study was done prior to induction of labour.

Ultrasound determined position of fetal head in predicting the mode of delivery

The odds ratio for the occipito-anterior position in early labor was 3.9. The diagnostic accuracy of fetal head position in early labor in predicting the mode of delivery was 0.56. Determining the position of the fetal head is of utmost importance in labor dystocia. Occipito-posterior position was associated with the prolonged first and second stage of labor, higher risk of assisted vaginal delivery and increased maternal and perinatal morbidity. Determining fetal head position is a prerequisite for instrumental delivery. An error in the evaluation may result in the inappropriate placement of vacuum or forceps, increasing the risk of injury to fetus and its failure. Wiafe et al concluded that ultrasound was better than digital vaginal examination to identify malposition in first stage of labor⁽³⁴⁾.

In all 185 subjects, fetal head position was assessed by translabial ultrasound in early labor. Fetal head position was anterior in 61 cases (32.97%) and among them, vaginal delivery was in 83.6% (51 out of

61), compared to vaginal delivery of 53.2% (66 out of 124) with other fetal head positions. When the position of the fetal head in early labor was occipito-anterior, the odds ratio of having vaginal delivery was 3.9 times more than that of cesarean delivery ($p = 0.042$).

The results of our study were comparable to the study conducted by Eggebo et al in 2015 on 150 women in the first stage of labor. They showed a significant odds ratio of 2.9 for predicting cesarean delivery with occipito-posterior position ($p = 0.02$)⁽³⁵⁾. Choi et al (2013) conducted a study on 101 primiparous women using ultrasound in both first and second stage of labor. They concluded that the rate of cesarean delivery in the occipito-posterior position was significantly higher than those in occipito-anterior ($p = 0.0024$) and transverse position ($p = 0.0374$). In another study, Choi in 2016 showed that occipito-posterior position was associated with a longer duration of labor than non- occipito-posterior group (77.9 ± 33.4 min versus 52.2 ± 26.6 min, $p = 0.0104$)⁽³⁶⁾. A study by Akmal et al in 2004 on 601 patients by transabdominal ultrasound in active labor showed that fetal head position can predict mode of delivery (odds ratio 2.2, $p \leq 0.001$)⁽³⁷⁾. However, a meta-analysis of 11 studies between 1999 and 2012 by Verhoeven et al concluded that position determined by ultrasound could not be used as a predictor of the mode of delivery as summary point estimates of sensitivity and specificity were 0.39 and 0.71⁽³⁸⁾.

The current study showed a significant correlation between the AoP and position of the fetal head and poor correlation between cervical length and mode of delivery. A risk score based on maternal age, body mass index, and gestational age with intrapartum ultrasound parameters can better predict vaginal delivery ($AUC 0.853$) in nulliparous women in the first stage of labor⁽³⁹⁾. ITU can also be used for teaching students about the dynamic assessment of these key components in labor.

This is the first study in this region using composite ultrasound parameters (AoP, cervical length and position of fetal head) in labor to predict the mode of delivery. However, the small sample size of the study, manual measurement of AoP were the limitations. Serial measurements of AoP and position of the fetal

head would aid in easy decision making in cases of non-progress of labour.

Conclusion

Intrapartum translabial ultrasound can be used as a suitable alternative method to the traditional digital vaginal examination in assessing cervical length, descent of head and position of the presenting part in labor. AoP, the most reproducible ultrasound parameter, which quantifies descent of fetal head, and position of the fetal head assessed by translabial ultrasound in early labor can be used to predict the mode of delivery. The probability of vaginal delivery increases as the AoP increases, with most women delivering vaginally if the AoP is $> 120^\circ$. Cervical length by ITU is not a good predictor of the mode of delivery. ITU can be used as a primary modality in initial labor assessment or as an additive tool to digital vaginal examination. Large, prospective, multicentric, observational studies are required to justify the routine use of intrapartum ultrasound in the Indian context.

Acknowledgements

The authors wish to thank the patients for their cooperation and the hospital authorities' permission to conduct the study.

Potential conflicts of interest

The authors declare no conflict of interest.

References

1. Siergiej M, Sudol-Szopińska I, Zwoliński J, Śladowska-Zwolińska AM. Role of intrapartum ultrasound in modern obstetrics – current perspectives and literature review. *J Ultrason* 2019;19:295-301.
2. Ghi T, Eggebø T, Lees C, Kalache K, Rozenberg P, Youssef A, et al. ISUOG Practice Guidelines: intrapartum ultrasound. *Ultrasound Obstet Gynecol* 2018;52:128-39.
3. Dietz HP, Lanzarone V. Measuring engagement of the fetal head: validity and reproducibility of a new ultrasound technique. *Ultrasound Obstet Gynecol* 2005;25:165-8.
4. Barbera AF, Pombar X, Perugino G, Lezotte DC, Hobbins JC. A new method to assess fetal head descent in labor with transperineal ultrasound. *Ultrasound Obstet Gynecol* 2009;33:313-9.
5. Adam G, Sirbu O, Voicu C, Dominic D, Tudorache S, Cernea N. Intrapartum ultrasound assessment of fetal head position, tip the scale: natural or instrumental delivery? *Curr Health Sci J* 2014;40:18-22.
6. Malvasi A, Tinelli A, Barbera A, Eggebø TM, Mynbaev OA, Bochicchio M, et al. Occiput posterior position diagnosis: vaginal examination or intrapartum sonography? A clinical review. *J Matern Neonatal Med* 2014;27:520-6.
7. Dückelmann AM, Bamberg C, Michaelis SAM, Lange J, Nonnenmacher A, Dudenhausen JW, et al. Measurement of fetal head descent using the 'angle of progression' on transperineal ultrasound imaging is reliable regardless of fetal head station or ultrasound expertise. *Ultrasound Obstet Gynecol* 2010;35:216-22.
8. Pina Pérez S, Jurado Seguer J, Pujadas AR, Serra Azuara L, Lleberia Juanos J, Aguiló Sagristà O. Role of intrapartum transperineal ultrasound: Angle of progression cut-off and correlation with delivery mode. *Clin Obstet Gynecol Reprod Med* 2017;3:1-4.
9. Tutschek B, Braun T, Chantraine F, Henrich W. A study of progress of labour using intrapartum translabial ultrasound, assessing head station, direction, and angle of descent. *BJOG* 2011;118:62-9.
10. Wiafe YA, Whitehead B, Venables H, Odoi AT. Sonographic parameters for diagnosing fetal head engagement during labour. *Ultrasound* 2018;26:16-21.
11. Kohls F, Brodowski L, Kuehnle E, Kniebusch N, Kalache KD, Weichert A. [Intrapartum Translabial Ultrasound: A Systematic Analysis of The Fetal Head Station in The First Stage of Labor]. *Z Geburtshilfe Neonatol* 2018;222:19-24.
12. Ionescu CA, Coroleucă C, Pleș L, Dimitriu M, Banacu M, Viezuină R, Bohiltea R. Ultrasound during labour. *Gineco.eu* 2016;12:211-3.
13. Henrich W, Dudenhausen J, Fuchs I, Kämena A, Tutschek B. Intrapartum translabial ultrasound (ITU): sonographic landmarks and correlation with successful vacuum extraction. *Ultrasound Obstet Gynecol* 2006;28:753-60.
14. Dückelmann AM, Bamberg C, Michaelis SAM, Lange J, Nonnenmacher A, Dudenhausen JW, et al. Measurement of fetal head descent using the 'angle of progression' on transperineal ultrasound imaging is reliable regardless of fetal head station or ultrasound expertise. *Ultrasound Obstet Gynecol* 2010;35:216-22.
15. Zilianti M, Azuaga A, Calderon F, Pagés G, Mendoza G. Monitoring the effacement of the uterine cervix by transperineal sonography: a new perspective. *J Ultrasound Med* 1995;14:719-24.
16. Sherer DM. Intrapartum ultrasound. *Ultrasound Obstet Gynecol* 2007;30:123-39.
17. Molina FS, Nicolaidis KH. Ultrasound in labor and

delivery. *Fetal Diagn Ther* 2010;27:61-7.

18. Ahn KH, Oh M-J. Intrapartum ultrasound: A useful method for evaluating labor progress and predicting operative vaginal delivery. *Obstet Gynecol Sci* 2014;57:427.
19. Kalache KD, Dückelmann AM, Michaelis SAM, Lange J, Cichon G, Dudenhausen JW. Transperineal ultrasound imaging in prolonged second stage of labor with occipitoanterior presenting fetuses: how well does the "angle of progression" predict the mode of delivery? *Ultrasound Obstet Gynecol* 2009;33:326-30.
20. Barbera AF, Imani F, Becker T, Lezotte DC, Hobbins JC. Anatomic relationship between the pubic symphysis and ischial spines and its clinical significance in the assessment of fetal head engagement and station during labor. *Ultrasound Obstet Gynecol* 2009;33:320-5.
21. Bamberg C, Scheuermann S, Slowinski T, Dückelmann AM, Vogt M, Nguyen-Dobinsky TN, et al. Relationship between fetal head station established using an open magnetic resonance imaging scanner and the angle of progression determined by transperineal ultrasound. *Ultrasound Obstet Gynecol* 2011;37:712-6.
22. Usman S, Lees C. Benefits and pitfalls of the use of intrapartum ultrasound. *Australas J Ultrasound Med* 2015;18:53-9.
23. Levy R, Zaks S, Ben-Arie A, Perlman S, Hagay Z, Vaisbuch E. Can angle of progression in pregnant women before onset of labor predict mode of delivery? *Ultrasound Obstet Gynecol* 2012;40:332-7.
24. Gillor M, Vaisbuch E, Zaks S, Barak O, Hagay Z, Levy R. Transperineal sonographic assessment of angle of progression as a predictor of successful vaginal delivery following induction of labor. *Ultrasound Obstet Gynecol* 2017;49:240-5.
25. Minajagi PS, Srinivas SB, Hebbar S. Predicting the Mode of Delivery by Angle of Progression (AOP) before the Onset of Labor by Transperineal Ultrasound in Nulliparous Women. *Curr Women's Health Rev* 2020;16:39-45.
26. Eggebø TM, Hassan WA, Salvesen KÅ, Lindtjørn E, Lees CC. Sonographic prediction of vaginal delivery in prolonged labor: a two-center study. *Ultrasound Obstet Gynecol* 2014;43:195-201.
27. Torkildsen EA, Salvesen KÅ, Eggebø TM. Prediction of delivery mode with transperineal ultrasound in women with prolonged first stage of labor. *Ultrasound Obstet Gynecol* 2011;37:702-8.
28. Tan PC, Vallikkannu N, Suguna S, Quek KF, Hassan J. Transvaginal sonographic measurement of cervical length vs. Bishop score in labor induction at term: tolerability and prediction of Cesarean delivery. *Ultrasound Obstet Gynecol* 2007;29:568-73.
29. Giyahi H, Marsosi V, Faghihzadeh S, Kalbasi M, Lamyian M. Sonographic measurement of cervical length and its relation to the onset of spontaneous labour and the mode of delivery. *Natl Med J India* 2018;31:70.
30. Alanwar A, Hussein SH, Allam HA, Hussein AM, Abdelazim IA, Abbas AM, et al. Transvaginal sonographic measurement of cervical length versus Bishop score in labor induction at term for prediction of caesarean delivery. *J Matern Neonatal Med* 2019;1-8.
31. Verhoeven CJM, Opmeer BC, Oei SG, Latour V, van der Post JAM, Mol BWJ. Transvaginal sonographic assessment of cervical length and wedging for predicting outcome of labor induction at term: a systematic review and meta-analysis. *Ultrasound Obstet Gynecol* 2013;42:500-8.
32. Khazardoost S, Ghotbizadeh Vahdani F, Latifi S, Borna S, Tahani M, Rezaei MA, et al. Pre-induction translabial ultrasound measurements in predicting mode of delivery compared to bishop score: a cross-sectional study. *BMC Pregnancy Childbirth* 2016;16:330.
33. Aggarwal K, Yadav A. Role of transvaginal ultrasonographic cervical assessment in predicting the outcome of induction of labor. *Int J Reprod Contraception Obstet Gynecol* 2019;8:628.
34. Wiafe YA, Whitehead B, Venables H, Dassah ET. Comparing intrapartum ultrasound and clinical examination in the assessment of fetal head position in African women. *J Ultrason* 2019;19:249-54.
35. Eggebø TM, Hassan WA, Salvesen KÅ, Torkildsen EA, Østborg TB, Lees CC. Prediction of delivery mode by ultrasound-assessed fetal position in nulliparous women with prolonged first stage of labor. *Ultrasound Obstet Gynecol* 2015;46:606-10.
36. Choi SK, Park YG, Lee DH, Ko HS, Park IY, Shin JC. Sonographic assessment of fetal occiput position during labor for the prediction of labor dystocia and perinatal outcomes. *J Matern Neonatal Med* 2016;29:3988-92.
37. Akmal S, Kametas N, Tsoi E, Howard R, Nicolaides KH. Ultrasonographic occiput position in early labour in the prediction of caesarean section. *BJOG* 2004;111:532-6.
38. Verhoeven CJM, Rückert MEPF, Opmeer BC, Pajkrt E, Mol BWJ. Ultrasonographic fetal head position to predict mode of delivery: A systematic review and bivariate meta-analysis. *Ultrasound Obstet Gynecol* 2012;40:9-13.
39. Eggebø TM, Wilhelm-Benartzi C, Hassan WA, Usman S, Salvesen KA, Lees CC. A model to predict vaginal delivery in nulliparous women based on maternal characteristics and intrapartum ultrasound. *Am J Obstet Gynecol* 2015;213:362.e1-362.e6.