

Mid-Trimester Termination of 51 Intact Pregnancies by Condom-Balloon Technique

Thawatchai Tansathit MD, MPH,
Theera Tongsong MD,
Somsak Choavisitsaree MD.

*Department of Obstetrics & Gynaecology,
Faculty of Medicine, Chiang Mai University,
Chiang Mai, Thailand*

Abstract : *A total of 51 complicated intact pregnancies at Chiang Mai University Hospital which had indications for termination of pregnancy were accumulatively intervened and monitored. The interim evaluation has lately been carried out. All of them were between 13-28 weeks of gestation and terminated by extra-amniotic stimulation with condom-balloon and subsequent oxytocin augmentation. The mean age of all patients was 26.43 years (ranged 18-39 years) and the mean gestation was 18.63 weeks (ranged 13-28 weeks). The rates of success of termination within 24, 48, and 72 hours were 56.9, 84.3, and 92.2 % respectively. The average induction-abortion time (IA) was 23 hours 49 minutes, which is not significantly different when comparing primiparity and multiparity. Only 3 out of 51 (6.4%) needed surgical curettage due to incomplete expulsion. Only 3 cases developed fever but needed no intensive care. Blood loss was so minimal by close observation that this phenomenon should be substantiated. The result of this paper is quite impressive and strongly suggests that the use of condom-balloon for stimulation and termination of mid-trimester pregnancy is an appropriate procedure because of high efficacy, very minimal complications and it is not expensive. Further investigation and a wider scale of clinical monitoring are suggested. (Thai J Obstet Gynaecol 1993;4:105-110.)*

Key words : mid- trimester termination, extra-amniotic stimulation, condom-balloon

The conventional technique of therapeutic termination for early pregnancy by suction curettage is simple and safe. It is, however, indicated that surgical complications increase with the advancement of the gestational age⁽¹⁾. Surgical evacuation and curettage is, therefore, not recommended when the uterus is over 16 weeks⁽²⁻³⁾. Intra-

amniotic instillation of hypertonic solution such as 20 % sodium chloride has commonly been used in late second trimester pregnancy. Complications, such as hypernatremia, can be a serious problem if hypertonic saline is incorrectly applied. Until lately, prostaglandins and analogues such as sulprostone have been proven to be effective

for second trimester pregnancy termination⁽³⁻⁵⁾. It is, however, indicated that the clinical implication of prostaglandins and derivatives in developing countries such as Thailand is still limited due to the very high expense and evidence of considerable side effects including nausea, vomiting, and diarrhea.

An earlier report of the new method by using condom-balloon technique for extra-amniotic stimulation of endogenous prostaglandin indicated that it is a highly effective method for termination of a dead fetus in utero and has minimal morbidity⁽⁶⁾. It is also much less expensive. At Maharaj Nakorn Chiang Mai Hospital, this technique is currently being used as the primary method of choice for termination of second trimester pregnancy both intact pregnancy and a dead fetus if there is no contraindication. The objective of this paper is interim evaluation of the application of the condom-balloon technique for intact mid-trimester pregnancy termination.

Materials and Methods

A total of 51 cases of 13-28 weeks intact pregnancies which were relevant for termination at Maharaj Nakorn Chiang Mai Hospital from April 1985 to April 1992 were accumulatively monitored and evaluated. All of them were justified for therapeutic termination based upon the individual medical indication. All had no labour pain and had no contraindications including cervicitis, rupture of membranes, cho-

rioamnionitis, undiagnosed fever, and leakage of amniotic fluid. The clinical response and the events of the individual woman were recorded for subsequent evaluation.

Preparation of the condom-balloon apparatus

The condom-balloon apparatus consists of one ordinary rubber urethral catheter of # 14-16, one standard male rubber condom, silk threads of # 3/0, and a metallic catheter guide. All of the above items can be sterilised by soaking in an antiseptic solution (Cidex) for 15 minutes. Under sterile conditions the condom sheath was put over the rubber catheter tip making the condom-balloon portion about 3.5 to 4.0 inches long by doubling ligatures with silk thread. It is very important to make sure that the lumen of the rubber catheter is still patent after ligation. The length of the catheter tip from the ligatures should be about 2 inches long to facilitate the application of the condom-balloon into the uterine cavity. The excessive portion of the condom sheath was then excised. The preparation procedure is illustrated in Fig. 1.

Technique of insertion of the condom-balloon

Under sterile techniques, empty the air within the condom-balloon by deflation with an irrigation syringe otherwise it will be difficult during the application. Holding the anterior lip of

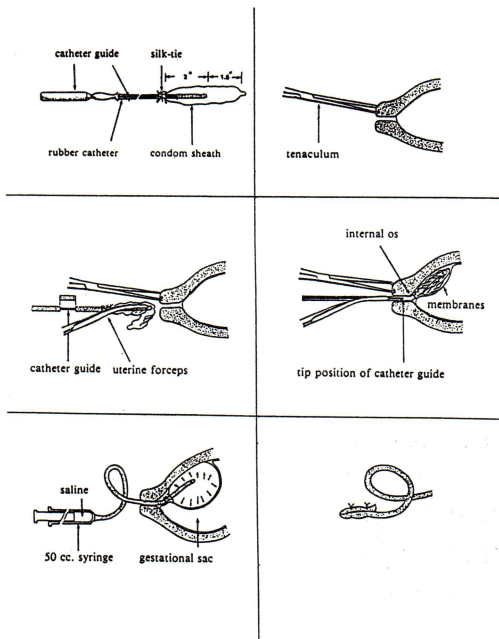


Fig.1 Condom-balloon technique.

the cervix with a tenaculum during gentle advancement of the condom-balloon apparatus into the cervical canal by using curved uterine forceps. The use of catheter guide is frequently recommended for easier application but be sure not to advance the tip of the catheter guide beyond the internal os in order to avoid accidental iatrogenic rupture of the amniotic sac. The balloon is gently advanced in any direction depending on its own freeness until the double knots of ligature are above the internal os and the entire condom-balloon is in the uterine cavity. The balloon is then inflated with normal saline according to the uterine size: 50-100 ml for 12-16 weeks, 100-150 for 16-19, 150-200 for 20-23, and 200-250

for 24-28 weeks respectively. The other end of the catheter was then clamped or tightly ligated with silk and be kept in the vagina for comfortability.

Care after balloon insertion

Bed rest or relaxing activity is acceptable for the patients and waiting for spontaneous labour is advised. After labour has started, the patient is transferred to the labour room for oxytocin augmentation (not more than 10 mIU/ml). Drug or analgesia may be given depending on the individual pain threshold. The patient was observed and wait for the progress, spontaneous expulsion of the condom-balloon, and subsequent expulsion of the conceptus or delivery. All clinical events and steps were recorded for subsequent evaluation.

Results

A total of 51 mid-trimester intact pregnancies were accumulatively terminated and monitored according to the various indications as shown in Table 1.

The average age of the 51 patients was 26.43 ± 5.2 (ranged 18-39 years). Twenty eight out of 51 were primiparity. The mean gestational age was 18.63 ± 3.2 weeks (ranged 13-28 weeks) and the uterine size by examination averaged about 16.82 ± 4.0 weeks (ranged 12-28 weeks).

The accumulative rate of success for expulsion or delivery within 24, 48 and 72 hours was 29 of 51 (56.9%), 43

Table 1 Indications for therapeutic termination of intact pregnancies

Indications	Number
Maternal rubella	11
Hydrops fetalis and Hb Bart	9
Mental retardation	5
Heart disease	5
Severe pre-eclampsia	5
Rape victim	4
Fetal anomaly	4
Schizophrenia	3
Brain tumour	2
Leukemia	1
Lymphoma	1
Breast cancer	1
Total	51

There was no significant difference of the average IL time between primiparity (13 h 16 min) and multiparity (11 h 3 min) ($p > .05$). The average IA time between primiparity (24 h 2 min) and multi-parity (22 h 58 min) was also not statistically different ($p > .05$). Of the 47 successful terminations, 3 patients or 6.4% needed surgical curettage due to incomplete expulsion. It is noteworthy that 11 of 47 had spontaneous expulsion or delivery of the fetus within the intact amniotic sac.

Clinical complications were found in only 3 women, one had febrile morbidity over 38 ° C during retention of the condom-balloon within the

Table 2 Percentage of patients by parity and time needed for induction

Parity	Induction-abortion time (IA) in hours and (%)				
	<24	<48	<72	Failure	Total
0	16(57.1)	24(85.7)	27(96.4)	1(3.6)	28(100)
1	13(56.5)	19(82.6)	20(87.0)	3(13.0)	23(100)
Total	29(56.9)	43(84.3)	47(92.2)	4(7.8)	51(100)

of 51(84.3%), and 47 of 51 (92.2%) respectively as shown in Table 2. Four patients or 7.8% failed to be terminated within 72 h and needed subsequent induction by parenteral sulprostone. Of the successful terminations, the average induction-labour time (IL) was 12 h 20 min and induction-abortion time (IA) was 23 h 49 min.

uterus and the other two had fever on day 1 and day 2 post expulsion but none of them needed intensive care or prolonged hospitalization. In general cases of abortion, blood loss is among the common complications. From this interim evaluation, 4 cases or 8.5% were classified as scanty or minimal blood loss, 34 cases (72.3%) mild or

small amount of blood loss (<150 ml), and 9 cases (19.6%) moderate degree (150-500). There was, however, no severe blood loss or bleeding of more than 500 ml (Table 3).

Table 3 The estimated blood loss of the condom-balloon technique

Degree	N	%
Scanty or minimal	4	8.5
Mild (< 150 ml)	34	72.3
Moderate (150-500 ml)	9	19.6
Severe (>500 ml)	-	-
Total	51	100.0

Discussion

At Maharaj Nakorn Chiang Mai University Hospital, the condom-balloon technique has routinely been used as the primary procedure in the therapeutic termination of mid-trimester pregnancies for more than 10 years. The objective of this interim evaluation is to re-evaluate the clinical implication. Until lately, it has been demonstrated that it is highly effective for mid-trimester pregnancy termination without any serious complications or systemic adverse effects.

The mechanism of induction of labour by using the condom-balloon technique is hard to explain. It has been proven earlier that mechanical stimulation of the fetal membranes

results in prostaglandins production⁽⁷⁾. It is, therefore, possible that the extensive mechanical separation of the membranes and the decidua by the condom-balloon initiates the release of endogenous prostaglandin and results in subsequent uterine contraction. It may also induce biomedical changes in both tissues which contain large amounts of arachidonic acid that is the precursor of prostaglandins⁽⁸⁾. The labour induced by the condom-balloon somewhat mimics natural labour or labour which develops after the use of exogenous prostaglandins. The distinction of this new technique is that there is no problem of overstimulation leading to severe complications such as rupture of the uterus as seen from the use of parenteral prostaglandins.

On one hand, the direction for insertion of the condom-balloon apparatus is somehow automatically advanced in the direction of decidua vera and this phenomenon has been proven by ultrasonographic examination. In the long-term cumulative experience at this hospital, there was neither evidence of bleeding or abruptio placentae. On the other hand, blood loss from this technique is surprisingly minimal. It is probably due to vasoconstrictive effect of the endogenous prostaglandins. However, keep in mind that any bleeding from the uterus noticeable during pregnancy is contraindication for application of the condom-balloon because it can be placenta previa.

The other interesting phenomena

of the condom-balloon technique is evidence that most of the cases experienced spontaneous complete expulsion and the considerable number of patients who had spontaneous deliveries with the fetus within the intact amniotic sac.

Unlike exogenous prostaglandins, the condom-balloon technique has no systemic adverse reaction, therefore, it is more appropriate for a complicated pregnancy, such as heart disease. The disadvantage of this technique is the long induction-interval that is theoretically subject to risk of infection. In the current setting, however, this is not considered a problem if contraindications have earlier been excluded.

In conclusion, this paper has shown that the condom-balloon technique for extra-amniotic stimulation of mid-trimester termination is highly effective and also has minimal morbidity. It is undoubtedly much less expensive and appropriate technology for developing countries.

References

1. Stewart GK, Goldstein P. Medical and surgical complications of therapeutic abortions. *Obstet Gynecol* 1972, 40 :539.
2. Cates W, Schulz KF, Gold J, Tyler CW. Complications of surgical evacuation procedures for abortions after 12 weeks' gestation. In: Zatzuchni GI, Sciarra JJ, Speidel JJ, eds. *Pregnancy Termination : Procedures, safety and New Development*. Maryland : Harper and Row, 1979:206.
3. Osathanondh R. Pregnancy termination (Therapeutic induced abortion). In: Ryan KJ, Berkowitz R, Barbieri RL, eds. *Kistner's Gynecology Principle and Practice*. 5th ed. Chicago : Year Book Medical Publishers, 1990:503-19.
4. Karim SMM, Prostaglandins in Obstetrics and Gynecology. In: International Sulprostone symposium. Vienna, November 1987: 10-3.
5. Karim SMM, Filshie GM. The use of prostaglandin E2 for therapeutic abortion. *J Obstet Gynaecol Br Cwlth* 1972,113:340.
6. Tansathit T, Tongsong T. Termination of dead fetus in utero by condom ballooning technic. In: Proceeding of the fertility research investigator's meeting. Chonburi: Thailand. September 1985:159-72.
7. Yokosawa K, Kanayama N, Terao T. Mechanical stretching increases prostaglandin E2 in cultured human amnion cells. In: Proceeding of the XIIIth Asian and Oceanic Congress of Obstetrics and Gynecology. Bangkok 1991:234.
8. Cunningham FG, MacDonald PC, Gant NF. *Williams obstetrics* 18th ed. Norwalk: Application & Lange, 1989:502-6.