
OBSTETRICS

3-Tourniquets Utero-ovarian Vessels Ligation Technique for Subtotal Cesarean Hysterectomy at Uthaithanee Hospital

Permkiat Tangcharoensilp MD.

Department of Obstetrics and Gynecology, Uthaithanee Hospital, Thailand

ABSTRACT

Objective: To compare the 3-tourniquets utero-ovarian vessels ligation technique in subtotal cesarean hysterectomy with standard method.

Materials and methods: Nine women were performed subtotal cesarean hysterectomy with the 3-tourniquets utero-ovarian vessels ligation technique at Uthaithanee Hospital from March 1, 2011 to January 16, 2012. The control cases were those with standard method before introducing this new technique. Percentage of blood transfusion and mean estimated blood loss were compared between groups.

Results: Subtotal cesarean hysterectomy with the 3-tourniquets utero-ovarian vessels ligation technique has better results in reduction of blood loss during operation. This new technique required blood transfusion in 22.2% with mean estimated blood loss of 844 cc. For standard technique, the blood transfusion rate was 76.9% and mean estimated blood loss was 1,565 cc.

Conclusion: The 3-tourniquets utero-ovarian vessels ligation technique for subtotal cesarean hysterectomy can temporarily stop bleeding from gravid uterus during operation. It significantly reduced blood loss as well as blood transfusion comparing with standard method.

Keywords: Subtotal cesarean hysterectomy, the 3-tourniquets utero-ovarian vessels ligation technique, postpartum hemorrhage

Introduction

The major complications of cesarean hysterectomy are excess blood loss and urinary tract damage during operation. Many studies from 1998 to 2007 reported blood transfusion rate at 83% in emergency and 24 % in elective cases⁽¹⁾. Two studies in 2010 demonstrated 44% of blood transfusion in the first emergency postpartum hysterectomy and 4.79

(1-14) units of blood were used per case in the other study⁽³⁾. This condition need to be managed quickly which can result in excessive blood loss and serious complications. Blood transfusion and blood components replacement may also be necessary. This 3-tourniquets utero-ovarian vessels ligation technique during subtotal cesarean hysterectomy is performed by temporary occlude both ovarian and uterine vessels with

tourniquets at three positions before starting the operation. The advantage of this new technique is the reduction of blood loss which make the operation easier⁽⁴⁾. This technique is also helpful to control bleeding in patient with placenta previa. In addition when subtotal cesarean hysterectomy was already done and further total cesarean hysterectomy was needed, Oshner or Kocher clamp could be caught on cervical stump to traction and remove cervix in the later. This is a method that advice for total cesarean hysterectomy as standard technique by doing subtotal and remove uterus without cervix first and then remove cervix latter⁽¹⁾. At Uthaitanee Hospital, the 3-tourniquets utero-ovarian vessels ligation technique in subtotal cesarean hysterectomy was performed to reduce blood loss, compare with standard technique which is described in Williams Obstetrics⁽¹⁾.

Materials and methods

After the Ethic Committee of Uthaitanee Hospital's approval, we began to use the 3-tourniquets utero-ovarian vessels ligation technique, in 9 women performed subtotal cesarean hysterectomy in Uthaitanee Hospital from March 1, 2011 to January 16, 2012. The primary outcome are blood transfusion and mean estimated blood loss. The results, clinical characteristics, operative time and indications for cesarean hysterectomy were compared with those of subtotal cesarean hysterectomy without this technique in the past 5 years. In the control group, all of 26 cases were done by obstetricians of Uthaitanee Hospital by standard method⁽¹⁾. Data of patients in 2 subtotal

cesarean hysterectomy groups were analyzed. The mean and standard deviation were calculated for continuous variables. Independent-sample Student's t- test was used for analysis. Two side p-values were considered statistically significant at $p < 0.05$ ⁽⁵⁾.

Technique of the 3 tourniquets utero-ovarian vessels ligation

1. Open the fold of peritoneum in broad ligament of both parametrium in avascular area just lateral to the line of uterine vessels.

2. Insert 2 upper tourniquets, each through the window that already done on both left and right broad ligaments then apply ligation including Fallopian tubes, round and utero-ovarian ligaments in position just median to ovary in both sides. Because of quicker application of 2 upper tourniquets than in the lower one (Figure 1.1), so uterine bleeding is partial reduced at the first in a short time.

3. After that, before apply lower tourniquet, we should close the incised uterine wound from cesarean section by suture quickly only to approximate the incision (Fig. 1.1) or use sponge clamp to pull up lower lip of incised wound for tourniquet can apply below easily (Fig. 1.2). The tourniquet should be applied to reach at the level of insertion of utero-sacral ligaments or lower (Fig. 1.3)⁽⁶⁾.

4. When 3 tourniquets were already applied (Fig. 1.4), uterine bleeding would be almost completely controlled. So obstetrician can begin to perform hysterectomy in nearly elective situation, waiting for help and/or adequate resuscitation to improve the patient's

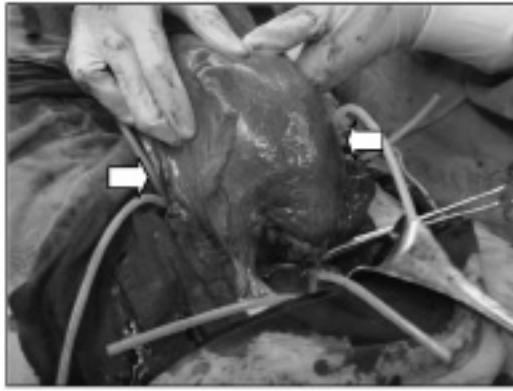


Fig. 1.1 The 2 upper position that should be applied tourniquets in the first (white arrow).



Fig. 1.2 Lower lip of uterine wound should be pulled up or suture quickly before apply lower tourniquet (white arrow).

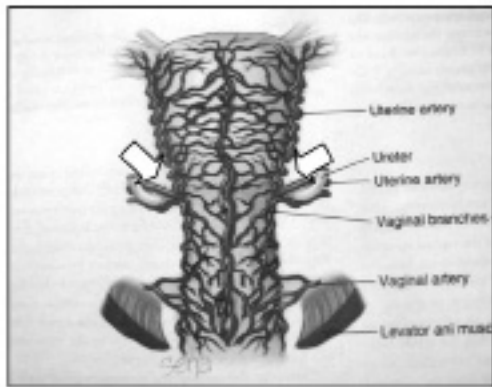


Fig. 1.3 Uterine insertion of utero-sacral ligament is the position that uterine arteries enter to uterus (2 white arrows).

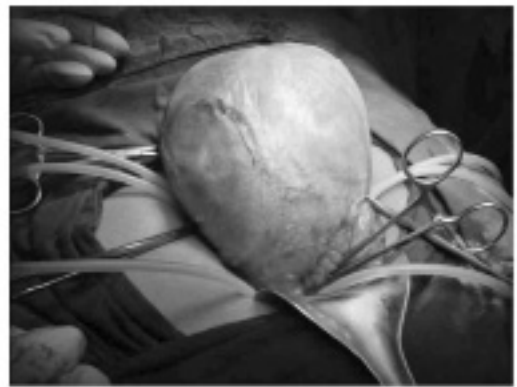

Fig. 1.4 After already applied 3 tourniquets, uterine bleeding was stopped almost completely.

Fig. 1. Method to apply 3 tourniquets utero-ovarian vessels ligation

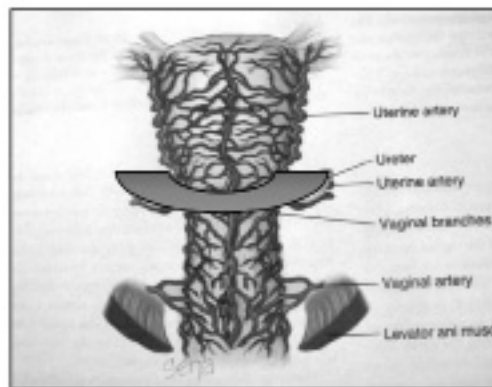


Fig. 2. Ligation of bilateral uterine vessels with the 3 tourniquets technique

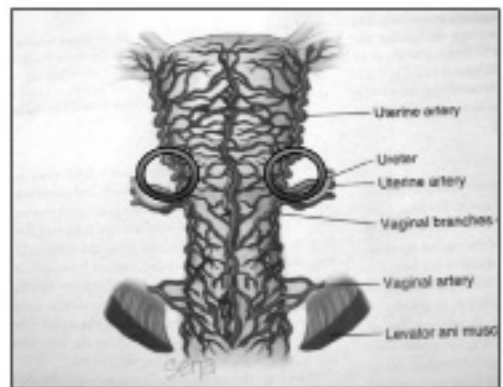


Fig. 3. Bilateral uterine vessels ligation in standard method

Pregnant uterus composes of numerous highly vascular area. Ligation of lower uterine segment of uterus with lower tourniquet can reduce blood loss comparing with bilateral uterine vessels ligation in standard method (Fig. 2 and 3).

Severe laceration of lower uterine segment due to delivery of the baby during cesarean section may cause

failure of this new technique because vessels in severe uterine laceration of uterine lower segment opening in many points will cause difficulty to apply lower tourniquet. If the patient has complete family and has high chance for cesarean hysterectomy, to avoid severe laceration of uterine lower segment, classical cesarean section is more preferable.

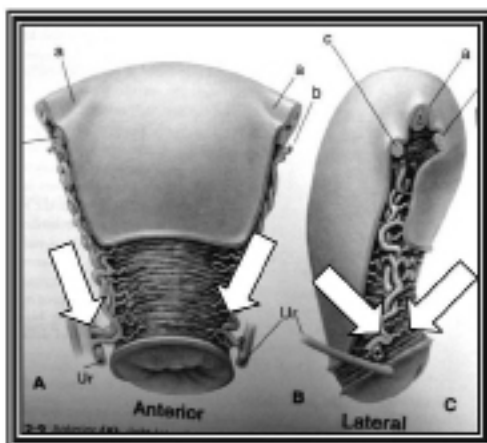


Fig. 4. Position of the lower portion of uterus that both uterine arteries enter to (white arrow), so the lower tourniquet should apply to reach to this level (insertion of utero-sacral ligament) or lower than.

Adequate bladder dissection to separate it from anterior uterine lower segment before lower tourniquet application is very important, because this procedure

can prevent injury to both ureters by pushing them down together with bladder, and make ease to apply lower tourniquet to reach effective level (Fig. 4.)⁽⁶⁾.

Results

Table 1. Comparison of the characteristics of subtotal cesarean hysterectomy in 2 groups

Characteristics	Group 1 (3 tourniquets utero-ovarian vessels ligation technique) (n=9)		Group 2 (standard method) (n=26)		p
	Emergency (n=7)	Elective (n=2)	Emergency (n=25)	Elective (n=1)	
	Age (years)	35.56±3.62		31.77±5.97	
Gravidity	2.56±0.50		2.58±0.69		0.925
Gestational age (weeks)	38.33±1.89		38.88±1.50		0.466
Indications					0.217

Characteristics	Group 1 (3 tourniquets utero-ovarian vessels ligation technique) (n=9)		Group 2 (standard method) (n=26)		p
	Emergency (n=7)	Elective (n=2)	Emergency (n=25)	Elective (n=1)	
	Uterine atony	2		8	
Abnormal placenta adherence	4		13		
Placenta previa	2		5		
Large myoma uteri	1		0		
Operative complications					0.500
Urinary tract injury	0		2		
Other complications	0		0		
Mean estimated blood loss (cc)	844.44±142.29		1,565.38±969.10		0.001*
Operation time (minutes)	107.78±35.13		120.19±32.51		0.392

Data presented as mean +/- standard deviation or n.

For 7 of 9 cases of subtotal cesarean hysterectomy performed with this new technique, were emergent cases and the other two were elective. Indications for cesarean hysterectomy were uterine atony 2 cases, abnormal placenta adherences 4 cases, placenta previa 2 cases and pregnant with large myoma 1 case. All of 9 patients had no urinary tract or bowel injury and were discharged from hospital in 3-5 days. In the control group, 25 were emergency and the other one was elective. There were 2 cases that had urinary tract damage during operation in this later group. Both of them were emergency cases. The clinical characteristics, indications for cesarean hysterectomy, estimated blood loss and comparison of both groups are shown in Table 1.

Two of 9 subtotal cesarean hysterectomies with the 3 tourniquets utero-ovarian vessels ligation technique needed blood transfusion (22.2%). Both of them are emergency cases. In the control group, 20 of 26 patients (76.09%) needed blood transfusion. And all of them are emergency cases.

Indications for blood transfusion in 2 emergency cases from tourniquets ligation group were placenta previa with failed to secure bleeding. So blood loss was already heavy before the decision to do hysterectomy.

In the other case, severe hypotension was developed from high spinal block but at that moment the diagnosis was uncertain. So blood transfusion was transfused 1 unit in that critical time although no heavy blood loss. Although the obstetricians knew the diagnosis, they continued subtotal cesarean hysterectomy with this new technique due to severe uterine atony without blood transfusion.

Discussion

In this study, the 3-tourniquets utero-ovarian vessels ligation technique in subtotal cesarean hysterectomy can dramatic reduce blood loss from gravid uterus during operation. This new assistant technique is superior to subtotal cesarean hysterectomy by standard method because obstetricians can perform operation in situation that no active and heavy blood loss as in standard method that not use this assistant technique. So, they can carefully operative and have adequate time to plan for effective operation. In addition, tourniquet is simple equipment, cheap, commonly retained in most hospitals, no trauma to the applied organ and removable although completely applied compare with standard technique for stop bleeding by selective artery ligation with suture such as uterine

vessels ligation procedure. The technique for application is easy, safe, and suitable for gravid uterus. Almost every obstetrician can use this new assistant technique. After application of 3 tourniquets, uterine bleeding was temporally stopped. Subtotal cesarean hysterectomy will change from emergent to nearly elective procedure. Otherwise, this new technique itself can effectively control severe hemorrhage from placental site at lower uterine segment in case of uncontrolled hemorrhage placenta previa, after placental removal in cesarean section especially in case of associated abnormally adhered placentation⁽⁷⁾ although the obstetrician decided to perform hysterectomy. Reduction of blood loss at placental site by direct suture or/and selective artery ligation are now used as standard method⁽⁸⁾. It is the first procedure to start before beginning of subtotal cesarean hysterectomy in order to reduce blood loss. In experience of 2 cases in this study, the 3-tourniquets utero-ovarian vessels ligation technique was demonstrated more effective and predictable than the standard method. In addition, in case of amniotic fluid embolism that up to now, there is no definite effective treatment except good supportive care. This new technique may be part of supportive care in the aspect of temporal bleeding control from gravid uterus to prevent end organ damage from hypoxia especially in brain, of survivors cases that caused by severe hypovolemic shock from heavy blood loss in DIC situation of this syndrome⁽⁹⁾.

This new technique can also be used for temporary stop bleeding from gravid uterus in almost causes. So anesthesiologist will have time for fluid and/or blood replacement to improve condition of the unstable patients and to make correct decision especially in critical time.

Nevertheless, this technique is not recommended for case of placenta previa with anterior placenta percreta invading through uterine wall and bladder because of the changing in anatomy of vessels and uterine lower segment. Lower tourniquet cannot be effectively applied. If it was diagnosed before operation, preoperative balloon-tipped catheters placement into both internal iliac arteries is recommended instead⁽⁸⁾. Although this easy technique may increase rate of

cesarean hysterectomy, due to easier decision to hysterectomy because this technique made subtotal cesarean hysterectomy to be safer and simpler. Furthermore, subtotal cesarean hysterectomy is the most effective method to stop uterine bleeding from almost causes of postpartum hemorrhage. But in the present time that obstetric practices being in high risk for law suit. This new technique may be the correct answer, especially to prevent serious law suit in case of maternal death due to postpartum hemorrhage.

Conclusion

The 3-tourniquets utero-ovarian vessels ligation technique is innovation that changes subtotal cesarean hysterectomy from emergent, high risk operation to nearly elective and safe procedure by effective control blood loss before and during operation. So, when compare to subtotal cesarean hysterectomy by standard method, the operative results are much better especially in reduction of blood loss during operation.

References

1. Cunningham FG, Gant NF, Levono KJ, Gilstrap LCIII, Hauth JC, Wenstrom KD, editors. Williams obstetrics 23 rd ed. New York: Mc Graw-Hill; 2010:544-63.
2. Rossi AC, Lee RH, Chmait RH. Emergency postpartum hysterectomy for uncontrolled postpartum bleeding. A systematic review. *Obstet Gynecol* 2010; 115:637-44.
3. Yalinkaya A, Guzel AI, Kangol K. Emergency postpartum hysterectomy: 16-years experiences of a medical hospital. *J Chin Med Assoc.*2010; 73:360-3.
4. Tamizian O, Arulkumaran S. The surgical management of post-partum hemorrhage. *Best Prac res. Clin Obstet Gynecol* 2002;16:81-98.
5. Jaiyodsin S. Statistics for medical research. Health. Co. *Th Journal* 2009;1:30-4
6. Cunningham FG, Gant NF, Levono KJ, Gilstrap LCIII, Hauth JC, Wenstrom KD, editors. Williams obstetrics 23 rd ed. New York: Mc Graw-Hill; 2010:14-35.
7. Knight M, UKOSS. Peripartum hysterectomy in the UK: Management and outcome of associated hemorrhage. *BJOG* 2007, 114:1380-7.
8. Cunningham FG, Gant NF, Levono KJ, Gilstrap LCIII, Hauth JC, Wenstrom KD, editors. Williams obstetrics 23 rd ed. New York: Mc Graw-Hill; 2010:757-803.
9. Clark SL, Hankins GDV, Dudley DA, Dildy GA, Porter TF. Amniotic fluid embolism: Analysis of national registry. *Am J Obstet Gynecol* 1995; 172:1158-67.

การตัดมดลูกแบบเหนือปากมดลูกขณะผ่าตัดคลอด โดยใช้เทคนิคช่วยห้ามเลือดโดยใช้เส้นยาง 3 เส้น ผูกรัดเส้นเลือดเลี้ยงมดลูกและรังไข่ ที่โรงพยาบาลอุทัยธานี

เพิ่มเกียรติ ตั้งเจริญศิริ

วัตถุประสงค์ : เพื่อเปรียบเทียบการใช้เทคนิคช่วยผ่าตัดแบบใหม่ด้วยการใช้เส้นยาง 3 เส้นผูกมัดมดลูก ช่วยในการทำผ่าตัดตัดมดลูกแบบเหนือปากมดลูกขณะผ่าตัดคลอดเพื่อลดการเสียเลือดในระหว่างการผ่าตัด โดยเปรียบเทียบกับวิธีผ่าตัดแบบมาตรฐานปกติ

วัสดุและวิธีการ : ผู้ป่วย 9 รายในโรงพยาบาลอุทัยธานีที่ได้รับการ ตัดมดลูกแบบเหนือปากมดลูกขณะผ่าตัดคลอดโดยใช้เทคนิคช่วยผ่าตัดแบบใหม่ การใช้เส้นยาง 3 เส้นผูกมัดมดลูก เพื่อลดการเสียเลือดขณะผ่าตัด ตั้งแต่วันที่ 1 มีนาคม พ.ศ.2554 ถึง 16 มกราคม พ.ศ.2555 โดยเปรียบเทียบกับผู้ป่วยในโรงพยาบาลอุทัยธานีที่ได้รับการผ่าตัดแบบเดียวกันด้วยวิธีมาตรฐานปกติโดยไม่ได้ใช้เส้นยาง ผูกมัดมดลูก จำนวน 26 รายในระยะเวลา 5 ปีก่อนนำเทคนิคใหม่นี้มาใช้ โดยเปรียบเทียบประสิทธิภาพของการลดการเสียเลือด จากจำนวนผู้ป่วยที่ต้องให้เลือดและปริมาณการเสียเลือดขณะผ่าตัดโดยเฉลี่ยต่อรายในผู้ป่วยทั้งสองกลุ่ม

ผลการศึกษา : การตัดมดลูกแบบเหนือปากมดลูกขณะผ่าตัดคลอดโดยใช้เทคนิคช่วยผ่าตัดแบบใหม่ การใช้เส้นยาง 3 เส้น ผูกมัดมดลูก สามารถลดการเสียเลือดในขณะผ่าตัดได้ดีกว่าอย่างชัดเจน โดยผู้ป่วยกลุ่มที่ใช้เทคนิคเส้นยาง 3 เส้นผูกมัดมดลูกมีจำนวนผู้ป่วยที่ต้องให้เลือดในการผ่าตัดเพียง 2 ใน 9 ราย (22.2%) และปริมาณการเสียเลือดโดยเฉลี่ยต่อรายเท่ากับ 844 มิลลิลิตร เทียบกับ ผู้ป่วยที่ได้รับการผ่าตัดแบบมาตรฐานปกติจำนวน 26 รายในระยะเวลา 5 ปีก่อนนำเทคนิคใหม่นี้มาใช้มีจำนวนผู้ป่วยที่ต้องให้เลือดในการผ่าตัด 20 ใน 26 ราย (76.9%) และปริมาณการเสียเลือดโดยเฉลี่ยต่อ รายเท่ากับ 1,565 มิลลิลิตร

สรุป : ด้วยผลของการสามารถช่วยห้ามเลือดจากมดลูกด้วยเทคนิคช่วยห้ามเลือดโดยใช้เส้นยาง 3 เส้นผูกมัดเส้นเลือดเลี้ยงมดลูกและรังไข่ โหม่นี้ทำให้การผ่าตัดตัดมดลูกขณะ ผ่าตัดคลอดที่เดิมมีความเสี่ยงสูงจากการที่มดลูกในระยะนี้จะมีการเสียเลือดที่รวดเร็ว, ปริมาณมากและมักจะเป็นการผ่าตัดฉุกเฉิน กลายมาเป็นการผ่าตัดที่ปลอดภัย นอกจากนี้ ด้วยคุณสมบัติในการสามารถชะลอการเสียเลือดไว้ก่อนในเวลาอันรวดเร็ว เมื่อเทียบกับวิธีมาตรฐานปกติ