

CASE REPORT

Ruptured Tubal Pregnancy with a Negative Urine Pregnancy Test and Serum Beta Human Chorionic Gonadotropin

Panwara Paritakul, M.D.*.

** Department of Obstetrics and Gynaecology, Faculty of Medicine, Srinakharinwirot University, Bangkok 10110, Thailand*

ABSTRACT

A rare case of ruptured tubal pregnancy with a negative urine pregnancy test (UPT) and serum beta hCG was reported. The patient presented with massive intraperitoneal bleeding and hypovolumic shock. Despite the negative UPT, a rupture tubal pregnancy was ruled out and a consultation with the gynaecologist was not done. Exploratory laparotomy revealed massive hemoperitoneum with a 5-cm purplish mass at the right fallopian tube and the right salpingectomy was performed. The serum beta hCG was sent intraoperatively, and the result was 4.2 mIU/mL. The pathological report confirmed a tubal pregnancy containing a 0.5-cm embryo and chorionic villi.

Keywords: ectopic pregnancy, pregnancy test

Correspondence to: Panwara Paritakul, M.D., Department of Obstetrics and Gynaecology, Faculty of Medicine, Srinakharinwirot University, Bangkok 10110, Thailand, E-mail Panwara_k@hotmail.com, Phone 083-0736145

รายงานผู้ป่วยซึ่งมีการแตกของการตั้งครรภ์ในท่อนำไข่ โดยที่ผลตรวจการตั้งครรภ์จากปัสสาวะและผลการตรวจค่า beta Human Chorionic Gonadotropin ในน้ำเหลืองเป็นลบ

พรรณวรา ปรีตกุล

บทคัดย่อ

บทความนี้ได้นำเสนอรายงานผู้ป่วยที่มีการแตกของการตั้งครรภ์ในท่อนำไข่ โดยที่ผลตรวจการตั้งครรภ์จากปัสสาวะและน้ำเหลืองเป็นลบ ผู้ป่วยมาโรงพยาบาลด้วยอาการแสดงของช็อกร่วมกับภาวะตกเลือดในช่องท้อง เนื่องจากผลตรวจการตั้งครรภ์จากปัสสาวะเป็นลบ แพทย์ผู้ดูแลจึงมิได้นึกถึงภาวะเลือดออกในช่องท้องที่มีสาเหตุมาจากการตั้งครรภ์นอกมดลูกและมิได้มีการปรึกษาสูติ-นรีแพทย์ ผลการผ่าตัดเปิดช่องท้องพบว่ามีเลือดออกในช่องท้องปริมาณมากร่วมกับพบก้อนสีแดงคล้ำขนาด 5 ซม. ที่ท่อนำไข่ด้านขวา จึงได้ผ่าตัดท่อนำไข่ด้านขวาออก โดยได้ส่งตรวจระดับ beta hCG ในน้ำเหลืองขณะทำผ่าตัดซึ่งผลออกมาได้เท่ากับ 4.2 mIU/mL ผลการตรวจทางพยาธิวิทยายืนยันการตั้งครรภ์ที่ท่อนำไข่ โดยตรวจพบเนื้อเยื่อรก (chorionic villi) และตัวอ่อน (embryo) ขนาด 0.5 ซม.

คำสำคัญ: การตั้งครรภ์นอกมดลูก, ผลตรวจการตั้งครรภ์

Introduction

Nontraumatic intraperitoneal hemorrhage has various possible causes⁽¹⁾. A ruptured ectopic pregnancy is among the differential diagnosis and should be highly suspected in a reproductive age female patient. Urine pregnancy test plays a significant role in the diagnostic algorithm of acute hemoperitoneum. The negative UPT often leads the surgeon to exclude a ruptured ectopic pregnancy as a possible cause of the bleeding, as it was long believed that the beta hCG elevates in all cases of ectopic pregnancy⁽²⁾. We present a case of ruptured ectopic pregnancy resulting in massive hemoperitoneum and hypovolumic shock despite the undetectable level of beta hCG.

Case presentation

A 41 year old woman (Gravida 3, Para 1 with one spontaneous abortion 20 years ago) presented at the emergency room complaining of acute abdominal pain and lightheadedness 2 hours prior to arrival. She was lifting a heavy plant pot when she had a sudden onset of severe lower abdominal pain followed by an episode of dizziness and syncope. Her relatives brought her to the hospital. The patient was previously healthy and never had any major illness or operation. At arrival, the patient looked drowsy but alert when called. Vital signs at the emergency room were blood pressure 80/40 mmHg, pulse rate of 110 beats/min, respiratory rate 28 breaths/min and body temperature 36.2°C. The oxygen saturation was 98%. On physical examination, the patient was markedly pale and sweating. The heart and lungs were normal. There were abdominal distension and generalized rebound tenderness, as well as diminished bowel sounds. The point of maximum tenderness was not clearly identified. A bulging cul-de-sac was noted at the rectal examination, but a pelvic examination was not performed. Investigation results were as follow Hb 7.7 g/dL, Hct 23.3%. Platelets and coagulogram were normal. The patient reported that her last menstrual period was 3 weeks ago, which she recalled as scanty and last for only 2 days. The menstrual cycle before that was

regular as she was currently taking oral contraceptive pills. However, 3 pills were missed during the last month. Urine pregnancy test was done despite the given information, and the result came back as negative. A bedside transabdominal ultrasonogram was performed, and a large amount of free fluid was noted at the hepatorenal pouch and the cul-de-sac. The appearance of the uterus and both adnexa was not noted.

An emergency consultation with the surgery department was made, and the provisional diagnosis was an acute intraperitoneal hemorrhage. Because of a negative result of urine pregnancy test, an ectopic pregnancy was not considered a possible cause and consultation with Obstetrics and Gynecology department was omitted. Despite the hemodynamic instability, the patient was given 4 liters of normal saline solution along with 2 units of PRCs over the period of 40 minutes. Emergency laparotomy was performed approximately 1 hour after hospital arrival. Hemoperitoneum total of 3,000 mL was noted at entering of the abdomen. After the blood was removed, the surgeon carefully explored the entire abdominal cavity. The liver, spleen and other abdominal organs were noted as normal. The only pathologic finding was a 5-cm purplish mass at the right fallopian tube with a 2-cm rupture site at ampulla region (Fig. 1). The gross appearance of the mass was likely an ectopic gestation. Intraoperative consultation with gynecology team was made, and right salpingectomy was performed. The resected mass was inspected at the operating theater and reveals a 0.5-cm embryo like structure encased in blood clots (Fig. 2). A quantitative serum beta hCG was sent intraoperatively just before the start of the salpingectomy procedure, and the result was 4.2 mIU/mL, a level that was interpreted that there was no pregnancy according to our laboratory reference value. An additional 1 unit of PRCs was transfused to the patient. The remaining postoperative course was uneventful, and the patient was discharged on her 6th day in good condition. The pathological examination of the resected tissue confirmed a tubal pregnancy containing a 0.5-cm embryo and chorionic villi.

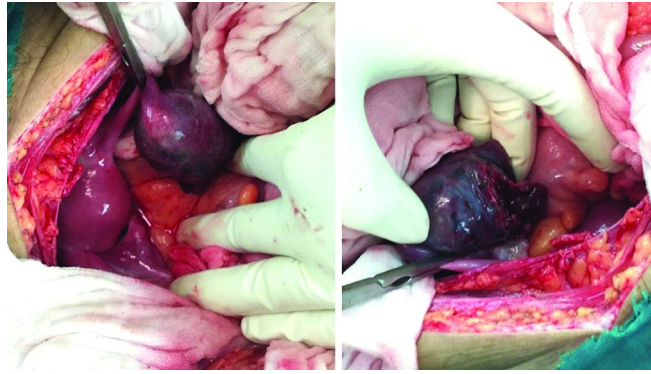


Fig. 1. A purplish mass at the right fallopian tube (left) and a 2 cm rupture site (right)

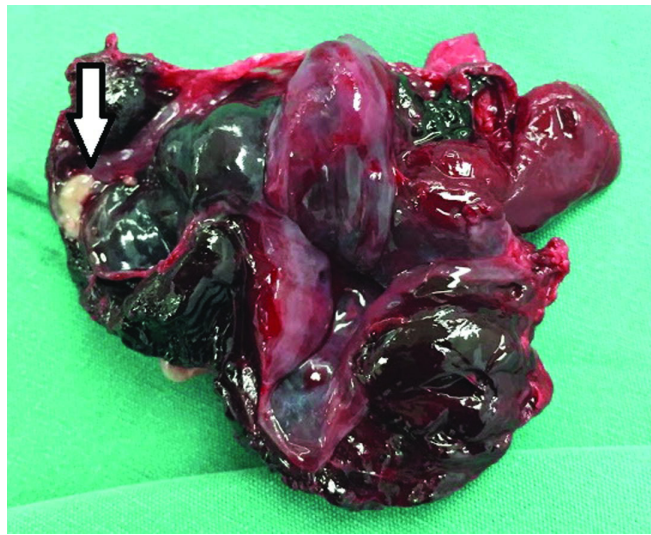


Fig. 2. Embryo like structure (arrow) encased in blood clots

Discussion

A urine pregnancy test is a quick and reliable diagnostic test to detect pregnancy. It has a sensitivity of 99% to detect the level of beta hCG greater than 25 mIU. A negative result often led the care provider to rule out pregnancy as a possible cause of the presenting illness. In the presenting case, the patient had acute intraperitoneal hemorrhage and a negative urine pregnancy test misled the physician to rule out a ruptured ectopic pregnancy as a possible underlying cause.

There is a study that showed a correlation between the tubal pregnancy size and the beta hCG

level⁽³⁾. However, the correlation between serum beta hCG level and a risk of rupture of tubal pregnancy is still in controversy. Some suggest that patient with high level of beta hCG is more likely to experience a tubal rupture^(4, 5), while some conclude that there is no correlation between the serum beta hCG levels and tubal rupture^(6, 7).

In our case, the patient presented with a large tubal mass despite the undetectable serum beta hCG. A possible explanation for this unique presentation was that the content of the large tubal mass was mostly composed of blood clots which distended the tubal lumen instead of an active gestational tissue. We

assume that the trophoblastic tissue was inactive long before the episode of rupture. Therefore, the serum beta hCG subsided over time. This assumption was also mentioned in some of the previous case reports^(8, 9). Other proposed mechanisms explaining the undetectable beta hCG in an ectopic pregnancy includes the defective biosynthesis of the beta hCG in the ectopic trophoblast and the enhance clearance of the hormones from the circulation⁽¹⁰⁾.

In a retrospective study of 305 cases, a negative urine pregnancy test can be found in 1.6% of all ectopic pregnancies⁽⁶⁾. However, rupture of tubal pregnancy with negative urine pregnancy test is very rare⁽¹¹⁾. To date, there were 8 cases reported in the published literature. The factor that precipitates tubal rupture in patients with low serum beta hCG has never been clarified. However, it is interesting to note that the patient in this report developed abrupt abdominal pain during strenuous physical activity (lifting a large plant pot). Even though most tubal pregnancy rupture spontaneously and it is not known what factor precipitates rupture of a tubal pregnancy⁽¹²⁾, our case suggests that an abrupt increased abdominal pressure possibly precipitates rupture. Therefore, patients receiving conservative management of ectopic pregnancy should be advised to refrain from activities that may increase the intraabdominal pressure.

A flaw in the diagnostic streamline of this case was that the exclusion of ectopic pregnancy as the underlying cause of the intraperitoneal bleeding was solely relied on the negative UPT result. The bimanual pelvic examination along with transvaginal ultrasonogram could have been very useful in aiding the preoperative diagnosis of gynecologic conditions in this case. Among the case reports of ruptured ectopic pregnancy with undetectable beta hCG which a pelvic examination or a transvaginal sonogram was noted in the literature, most of the cases either show significant adnexal tenderness on pelvic examination^(11, 13-15), or an abnormal adnexal mass on the transvaginal sonogram^(8, 11, 13, 15) (4 out of 5 cases). We recommend that in a woman presenting with intraperitoneal bleeding of unknown origin. A bimanual pelvic examination should be done in every case to assess for cervical and adnexal pain.

A transvaginal sonogram, when available and does not interfere with prompt management, should also be investigated to rule out any possible gynecologic condition causing the bleeding, including an ectopic gestation. The surgeon should keep in mind that when the clinical features strongly suggest an ectopic pregnancy, a negative beta hCG level does not exclude the possibility of the disease.

Potential conflicts of interest

The authors declare no conflict of interest.

References

1. Lubner M, Menias C, Rucker C, Bhalla S, Peterson CM, Wang L, et al. Blood in the belly: CT findings of hemoperitoneum. *Radiographics* 2007;27:109-25.
2. Schwartz RO, Di Pietro DL. beta hCG as a Diagnostic Aid for Suspected Ectopic Pregnancy. *Obstet Gynecol* 1980;56:197-203.
3. Guvendag Guven E, Dilbaz S, Dilbaz B, Guven S, Sahin Ozdemir D, Haberal A. Serum biochemistry correlates with the size of tubal ectopic pregnancy on sonography. *Ultrasound Obstet Gynecol* 2006;28:826-30.
4. Latchaw G, Takacs P, Gaitan L, Geren S, Burzawa J. Risk factors associated with the rupture of tubal ectopic pregnancy. *Gynecol Obstet Invest* 2005;60:177-80.
5. Darkhaneh RF, Asgharnia M, Porkar NF, Alipoor AA. Predictive value of maternal serum β -hCG concentration in the ruptured tubal ectopic pregnancy. *Iran J Reprod Med* 2015;13:101-4.
6. Saxon D, Falcone T, Mascha EJ, Marino T, Yao M, Tulandi T. A study of ruptured tubal ectopic pregnancy. *Obstet Gynecol* 1997;90:46-9.
7. Galstyan K, Kurzel RB. Serum beta-hCG titers do not predict ruptured ectopic pregnancy. *Int J Fertil Womens Med* 2005;51:14-6.
8. Kalinski MA, Guss DA. Hemorrhagic shock from a ruptured ectopic pregnancy in a patient with a negative urine pregnancy test result. *Ann Emerg Med* 2002;40:102-5.
9. Hochner-Celnikier D, Ron M, Goshen R, Zacut D, Amir G, Yagel S. Rupture of ectopic pregnancy following disappearance of serum beta subunit of hCG. *Obstet Gynecol* 1992;79:826-7.
10. Taylor RN, Padula C, Goldsmith PC. Pitfall in the diagnosis of ectopic pregnancy: Immunocytochemical evaluation in a patient with false negative serum beta hCG level. *Obstet Gynecol* 1988;71:1035-8.
11. Daniilidis A, Pantelis A, Makris V, Balaouras D, Vrachnis N. A unique case of ruptured ectopic pregnancy in a patient with negative pregnancy test-a case report and brief review of the literature. *Hippokratia* 2014;18:282-4.

12. Falcone T, Mascha EJ, Goldberg JM, Falconi LL, Mohla G, Attaran M. A study of risk factors for ruptured tubal ectopic pregnancy. *J Womens Health* 1998;7:459-63.
13. Brennan DF, Kwatra S, Kelly M, Dunn M. Chronic ectopic pregnancy—two cases of acute rupture despite negative β hCG. *J Emerg Med* 2000;19:249-54.
14. Tse KY, Leung W, Lau N, Lau C. Haemoperitoneum due to tubal abortion in a patient with negative urine pregnancy test: case report and literature review. *Hong Kong J Gynaecol Obstet Midwifery* 2006;6:45-8.
15. Lee JK, Lamaro VP. Ruptured tubal ectopic pregnancy with negative serum beta hCG--a case for ongoing vigilance? *N Z Med J* 2009;122:94-9.