
GYNAECOLOGY

Intraoperative Lymphatic Mapping and Sentinel Node Identification in Patients with Early Stage Cervical Cancer Undergoing Radical Hysterectomy and Pelvic Lymphadenectomy : A Pilot Study

Jitti Hanprasertpong MD,*
Puchong Padungsutt MD,**
Chairat Leelaphatanadit MD,**
Chaiyod Thirapakawong MD.**

* Division of Gynecologic Oncology, Department of Obstetrics & Gynecology, Faculty of Medicine, Prince of Songkla University, Hatyai, Songkla 90112, Thailand

** Division of Gynecologic Oncology, Department of Obstetrics & Gynecology, Faculty of Medicine, Siriraj Hospital, Mahidol University, Bangkok 10700, Thailand

ABSTRACT

Objective The purpose of this study was to determine the feasibility of sentinel lymph node (SLN) identification in cervical cancer patients undergoing radical hysterectomy and pelvic lymphadenectomy by using intraoperative lymphatic mapping with blue dye.

Design Descriptive study.

Setting Department of Obstetrics & Gynecology, Faculty of Medicine, Siriraj Hospital.

Methods Cervical cancer patients who underwent radical hysterectomy and pelvic lymphadenectomy were enrolled. During intraoperative period, patients without grossly suspected pelvic lymph node metastasis will be injected with blue dye, 1% isosulfan blue dye (5 ml) intracervically before any dissection. Ten minutes after dye injection, blue lymph vessels and lymph nodes were identified and recorded. Blue lymph nodes (sentinel nodes) were dissected first and followed by pelvic lymphadenectomy and radical hysterectomy. Blue lymph nodes (sentinel nodes), other pelvic lymph nodes and uterus were sent separately for histologic examination by routine hematoxylin & eosin staining (H&E).

Results Between June 2001 and January 2002, sixteen patients were enrolled, including 2 patients with stage IA2 and 14 patients with stage IB1. Median age was 45.9 years (33-62 years). Sentinel lymph nodes were identified in 12 of 16 patients (75%). A total of 34 lymph nodes were identified clinically as sentinel nodes. The locations of sentinel nodes were 27 external iliac, 4 internal iliac and 3 obturator node basin. Routine histologic examination showed no lymph nodes metastasis in all nodes (sentinel and non-sentinel). No serious complication was noted but transient decrease in oxygen saturation as measured by pulse oximetry was detected in most patients but returned to normal within 3 hours after dye injection without any cardiopulmonary compromise.

Conclusions Sentinel lymph node identification using intraoperative lymphatic mapping with blue dye is feasible and safe. More patients are needed to determine the accuracy of this technique.

Key words: sentinel node, cervical cancer, blue dye

Cervical cancer is the most common gynecologic cancer in Thailand accounting for 23.4: 100,000 women-year. Most of the patients were diagnosed in advanced stage. Patients with early stage cervical cancer could be treated with either radical surgery or radiation therapy. The presence of lymph node metastasis is a major adverse prognostic factor in women with early stage cervical cancer after radical surgery.⁽¹⁾ Thus, removal of pelvic lymph nodes is essential for assessing the extent of disease.

However, lymphadenectomy has been associated with complications such as vascular injury, nerve injury, lymphedema, lymphocyst and adhesion formation.^(2,3) However, the incidence of pelvic node metastasis in patient who underwent radical surgery was 4.8% and 15.9% in FIGO stage IA2 and IB1 respectively.⁽⁴⁾ Thus, about 85-95% of early stage cervical cancer patients did not have any benefit from lymphadenectomy. However, preoperative investigation by lymphangiography, computed tomography and magnetic resonance imaging are not highly enough to detect nodal metastasis.⁽⁵⁾ A new technique which involved the selective evaluation of regional lymphatics based on sentinel node identification may be appropriate in this subgroup of patients.

Sentinel nodes are regional lymph nodes which are first involved in cancer metastasis via lymphatic route.^(6,7) It is the most appropriate lymph node to be selected for screening examination.⁽⁷⁾ According to the sentinel node concept, all lymph nodes will be negative if the sentinel lymph node is negative.

The intraoperative blue dye injection using 1% isosulfan blue (Lymphazurin 1%, triphenylmethane dye) was reported as the one of sentinel node identification technique.⁽⁷⁻¹⁸⁾ It is selectively picked up by regional lymphatics because approximately 50% of blue dye are weakly bound to serum protein. Lymphatic vessels and

nodes are distinguishable from surrounding tissue by the resultant bright blue color. Other techniques used to identify sentinel node such as preoperative lymphoscintigraphy or intraoperative gamma probe with technitium-99m-labeled radiocolloid injection and combined technique were also reported.^(8,9,18)

Nowadays, sentinel node identification procedures have been applied in clinical practice of various cancers, e.g. early stage breast, melanoma, and vulvar cancer.^(7,13,19) This procedure might also prevent unnecessary harmful radical lymphadenectomy and decrease postoperative complication in early stage cancer patients who have a low incidence of regional nodal metastasis. Accordingly, we investigated the feasibility of intraoperative lymphatic mapping and sentinel lymph node (SLN) identification in early cervical cancer patients.

Materials and Methods

Patient Selection

Early stage cervical cancer patients (FIGO stage IA2, IB1) undergoing radical hysterectomy and pelvic lymphadenectomy were eligible for study. Rationale of this research was discussed and accepted from the group of gynecologic oncologist of Siriraj Hospital. Informed consent was obtained from all participants. Patients were considered ineligible if they had undergone prior chemotherapy, pelvic radiotherapy, grossly node metastasis during surgery. In addition, patients with prior retroperitoneal surgery were not candidates for SLN identification because of possible alterations of lymphatic flow. All histologic types were eligible to enter the study. Preoperative testing consisted of complete blood test, renal function test, chest X-ray, and EKG as institute routine preparation.

Technique: intraoperative lymphatic mapping and sentinel node identification

On the day of surgery, after induction of general anesthesia, all patients were placed in low lithotomy position to allow intraoperative vaginal approach for intracervical dye injection. Routine abdominal preparation and draping were performed. Exploratory laparotomy was performed using vertical midline incision to ensure adequate exposure of pelvic and lower para-aortic tissues. In patients with normal appearing lymph nodes, the lymphatic mapping procedure was performed. At this point, a speculum was placed in the vagina and 5 ml of 1% isosulfan blue dye (1% Lymphazurin, Department of Pharmacy, Siriraj Hospital, Bangkok, Thailand) was injected into the cervical stroma, using a needle, avoiding injection into tumor mass.(Figure 1) A needle extender or spinal needle No.25 was used with gentle pressure to minimize spillage of blue dye. Injection was generally performed at four locations, 3, 6, 9, and 12 o'clock of the cervix. After the injection of blue dye, pelvic peritoneum was incised bilaterally to expose the retroperitoneum and then avascular paravesical and pararectal spaces were gently developed.

After dye injection up to 10 minutes was allowed for nodal dye uptake. Once dye uptake was observed in retroperitoneal lymphatics.(Figure 2) The pelvic nodal regions were carefully inspected for dye uptake in lymphatic channels and specific lymph nodes.(Figure 3) Any node that was blue was considered a sentinel node. Surgical findings were recorded on an anatomical diagram. Lymph node(s)

with obvious dye stained (green-blue color) was separately excised and designated as "sentinel node". Then, complete pelvic lymphadenectomy followed by radical hysterectomy were performed. Common iliac or lower paraaortic nodes were further dissected if identified as a sentinel node(s). Intraoperative pulse oximetry was monitored throughout the operation and green-blue discolorization of urine was observed until recovery.(Figure 4)

Histopathologic examination

All lymph nodes were inspected by the pathologist. If grossly metastatic lymph node was identified, routine sections were submitted. Normal appearing lymph nodes were cut perpendicularly to the long axis into 3 mm-sections and submitted for routine hematoxylin & eosin staining (H&E). The rest of surgical specimens were prepared as routine examination of radical hysterectomy. Surgical findings were correlated with final pathologic reports. Frozen section was performed only if requested by gynecologic oncologist during operation.

According to Siriraj Hospital's standard practice, if grossly enlarged pelvic lymph nodes and metastasis were confirmed by frozen section, operation would be discontinued. Thereafter, some patients would be advised to receive adjuvant therapy if they had poor prognostic factors such as parametrial micrometastasis, nodal micrometastasis and also grossly pelvic nodal metastasis.

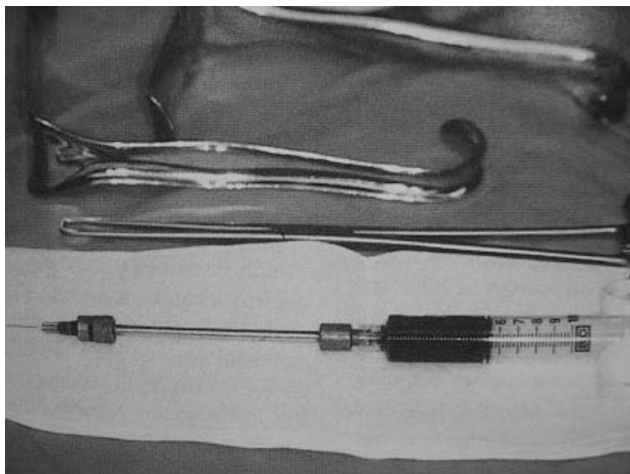


Fig. 1. Isosulfan blue dye and instruments.

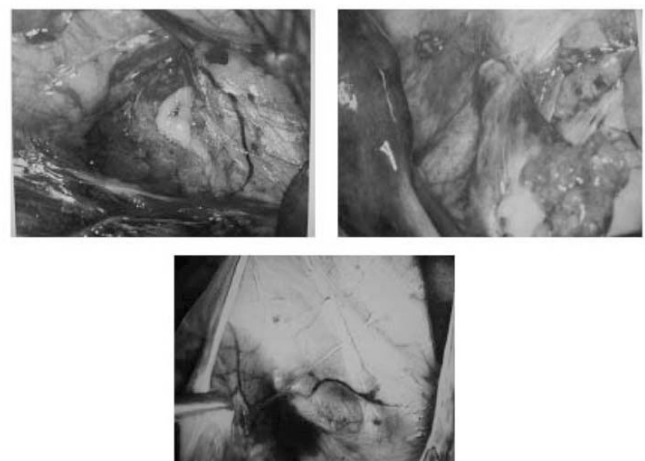


Fig. 2. Dye uptake in retroperitoneal lymphatics.

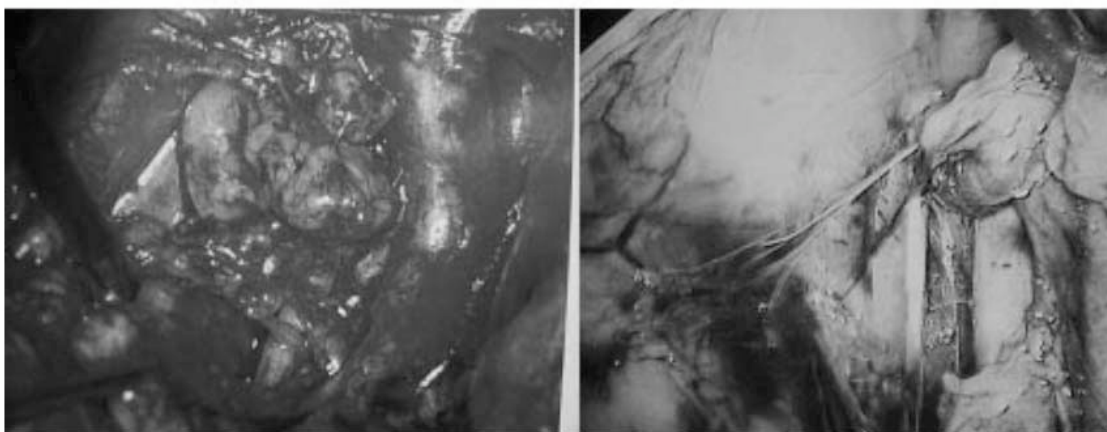


Fig. 3. Dye uptake in retroperitoneal lymph nodes.



Fig. 4. Green-blue discolorization of urine.

Statistic analysis

Data were entered into a computerized database and analyzed by using the SPSS software (version 10.0 for windows, SPSS Inc, Chicago, IL). Unpaired t-tests and Fisher Exact test were used.

Results

Patient characteristics

Between June 2001 and January 2002, 16 patients [cervical cancer FIGO stage IA2 (n = 2), stage IB1 (n = 14)] were enrolled into the study. Median age was 45.9 years (range 33-62 years). All of these patients underwent radical hysterectomy and pelvic lymphadenectomy. Tumor characteristics are presented in Table 1.

Table 1. Tumor characteristics

| Characteristic | Number | Percent |
|-------------------------|--------|---------|
| Tumor size | | |
| Less than 2 cm | 12 | 75.0 |
| 2-4 cm | 4 | 25.0 |
| Prior conization | | |
| Y | 6 | 37.5 |
| N | 10 | 62.5 |
| Histology | | |
| Squamous | 11 | 68.8 |
| Adenocarcinoma | 4 | 25.0 |
| Adenosquamous | 1 | 6.2 |

Intraoperative lymphatic mapping

At least 1 blue-green lymph node was identified in each of the 12 patients. Thus, the detection rate was 75%(95%CI 51-90%). Six patients underwent cervical conization before lymphatic mapping and surgical procedure. This procedure did not affect the likelihood of sentinel node identification. ($p=1$, Fisher-Exact test) (Table 2)

Sentinel node characteristics

In these 12 patients, a total of 34 sentinel lymph nodes were identified. The most common location of sentinel lymph nodes was the external iliac area.(Table 3) The sentinel lymph nodes were not found in the common iliac and paraaortic regions. The locations of blue nodes are shown in Fig. 5.

Table 2. Sentinel node and cervical conization

| Prior conization | Blue-green lymph node | |
|------------------|-----------------------|--------------|
| | Positive (%) | Negative (%) |
| Y | 5(83.3)* | 1(16.7) |
| N | 7(70.0)* | 3(10.0) |

(* $P= 1.0$, Fisher-Exact test)

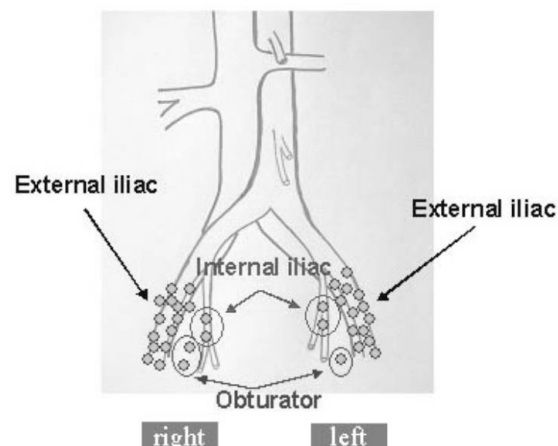
**Fig. 5.** Diagram of sentinel lymph node location.

Table 3. Location of sentinel nodes

| Location | Side | Number of sentinel node | % |
|----------------|-------|-------------------------|------|
| External iliac | both | 27 | 79.4 |
| | right | 14 | |
| | left | 13 | |
| Internal iliac | both | 4 | 11.8 |
| | right | 2 | |
| | left | 2 | |
| Obturator | both | 3 | 8.8 |
| | right | 2 | |
| | left | 1 | |
| Total | | 34 | |

No metastasis was found in all patients by routine hematoxylin & eosin staining (H&E) of 3 mm-section. Overall tolerance for lymphatic mapping procedure was excellent. No anaphylaxis or injuries during injection of 1% isosulfan blue dye was observed. Transient decrease in oxygen saturation, as measured by pulse oximetry, was noted in many patients but retaining to normal within 3 hours after dye injection. Arterial blood gas was investigated in some patients depend on anesthesiologist opinion. All blood gas results were high PaO₂ and normal PaCO₂. All patients had a blue-green discolorization of urine for a few days. The injection technique added about 20 minutes to the operative time when compared with usual time for routine radical hysterectomy and pelvic lymphadenectomy.

Discussion

The technique of the sentinel lymph node identification has gained increasing attention since its introduction in melanoma by Morton et al.⁽⁶⁾ For gynecologic malignancies, Levenback et al reported sentinel lymph node detection in vulvar carcinoma using 1% isosulfan blue dye and appeared to be an effective technique.⁽¹³⁾ Several lymphatic mapping studies have been performed in patients with cervical carcinoma.⁽⁸⁻¹²⁾ In previous large study, Malur et al reported a series of 50 patients, including 18 with stage II and advanced disease, who underwent lymphatic

mapping with various techniques. They identified sentinel lymph nodes in 90 % of patients using a combined technique, compared with 55% using blue dye technique alone and 76 % using radiocolloid alone.⁽⁹⁾ In our study, the overall detection rate was 75% which was higher than those of O' Boyle et al and Levenback et al.^(10,18) The study of O' Boyle et al, reported that sentinel lymph node detection rate in 20 cervical cancer patients using 1% isosulfan blue dye was 60%.⁽¹⁰⁾ Inflammation and healing processes after conization may alter the lymphatic route and affect the sentinel node detection. This study showed that prior conization did not affect the rate of detection which was similar to the finding of Dargent et al reported.⁽¹¹⁾

The most common location for sentinel lymph node was the region of the external iliac vessels accounting for 79.4 %. Verheijen et al reported that the majority of the sentinel lymph nodes were located along the external iliac vessels (33.3%) and the obturator fossa (27.7%).⁽⁸⁾ Conversely, Noguchi H et al, reported that pelvic lymph node metastasis were most commonly seen in the parametrium (25 %) and along the internal iliac vessels (6.9%).⁽²⁰⁾ In our small pilot study, there was no metastasis in sentinel nodes and non-sentinel nodes. Overall, the complication rates from 1% isosulfan blue dye injection varied from 0% to 1.5% and predominantly related to allergic reaction.^(11,16) In our experience, no anaphylaxis or

injuries during injection of 1% isosulfan blue dye was observed. Nevertheless, transient decrease in oxygen saturation as measured by pulse oximetry was observed in 12 patients. It occurred as a result of interaction between 1% isosulfan blue dye absorptive spectroscopy and wave lengths used to measure oxygen saturation by pulse oximetry device.⁽¹⁶⁾

We used this pilot study to explore the possible use of intraoperative mapping with 1% isosulfan blue dye. This technique seems to be easy and feasible to perform. More patients were needed to evaluate the clinical applicability of this procedure. At present, intraoperative blue dye injection was applied in part of breast cancer operation at Siriraj hospital for 5 years, especially in early stage disease. It produced a little problem and no serious effects. If the sentinel lymph node detection is effective and safe, it may be combined with the other techniques to enhance the accuracy of sentinel lymph node detection. Our data are not sufficient to recommend abandoning, pelvic lymphadenectomy in surgical treatment of early stage cervical cancer. This technique is still investigational protocol until there are enough beneficial data about survival end point from large multi-institutional trial.

Further study, e.g. molecular biological methods should be performed to detect to validate the very early detection of tumor metastasis. Step sectioning and immuno-histochemical method for detection of micrometastasis in the sentinel lymph node in patients with vulvar carcinoma showed micrometastasis in only 4 % of the lymph nodes judged as tumor-free following H&E staining.⁽²⁰⁾

References

1. Vatanasapt V, Martin N, Sriplung H, et al. Cancer in Thailand. IARC technical report No.16.1993:59.
2. Hacker NF. Cervical cancer. In: Berek JS, Hacker NF. Practical gynecologic oncology. 3rd ed. Baltimore: William & Wilkins, 2000:345-455.
3. Disaia PJ, Creasman WT. Clinical gynecologic oncology. 5thed. St.Louis: Mosby Year Book, 1997: 51-106.
4. Hatch KD. Cervical cancer. In: Berek JS, Hacker NF. Practical gynecologic oncology. 2nded. Baltimore: William & Wilkins, 1994: 243-83.
5. Beyersdorff D, Bahnsen J, Frischbier HJ. Nodal involvement in cancer of uterine cervix : value of lymphography and MRI. Eur J Gynaecol Oncol 1995; 16:274-7.
6. Pfeifer JD. Sentinel lymph node biopsy. Am J Clin Pathol 1999 ;112: 599-602 .
7. Morton DL, Wen DR, Wong JH, Economou JS, Cagle LA, Storm FK, et al. Technical details of intraoperative lymphatic mapping for early stage melanoma. Arch Surg 1992;127:392-9.
8. Verheijen RM, Pijpers R, Van Diest PJ, Burger CW, Buist MR, Kenemans P. Sentinel node detection in cervical cancer. Obstet Gynecol 2000; 96:135-8 .
9. Malur S, Krause N, Kohler C ,Schneider A. Sentinel lymph node detection in patients with cervical cancer. Gynecol Oncol 2001;80:254-7.
10. O'Boyle JD, Coleman RL, Bernstein SG, Lifshitz S, Muller CY, Miller DS. Intraoperative lymphatic mapping in cervical cancer patients undergoing radical hysterectomy: a pilot study. Gynecol Oncol 2000;79: 238-43.
11. Dargent D, Martin X, Mathevet P. Laparoscopic assessment of the sentinel lymph node in early stage cervical cancer. Gynecol Oncol 2000;79:411-5.
12. Echt ML, Finan MA, Hoffman MS, Kline RC, Roberts WS, Florica JV. Detection of sentinel lymph node with lymphazurin in cervical, uterine, vulvar malignancies. South Med J 1999;92: 204-8.
13. Levenback C, Burke TW, Gershenson DM, Morris M, Malpica A, Ross MI. Intraoperative lymphatic mapping for vulvar cancer. Obstet Gynecol 1994;84:163-7.
14. Levenback C, Burke TW, Morris M, Malpica A, Lucas KR, Gershenson DM. Potential applications of intraoperative lymphatic mapping in vulvar cancer. Gynecol Oncol 1995;59:216-20.
15. Ansink AC, Sie-Go D, van der Velden J, Sijmons EA, Lopes ADB, Monaghan JM, et al. Identification of sentinel lymph nodes in vulvar carcinoma patients with the aid of patent blue v injection: a multicenter study. Cancer 1999;86:652-6.
16. Burke TW, Levenback C, Tornos C, Morris M, Wharton JT, Gershenson DM. Intraabdominal lymphatic mapping to direct selective pelvic and paraaortic lymphadenectomy in women with high-risk endometrial cancer: results of a pilot study. Gynecol Oncol 1996; 62:169-73.
17. Coleman RL, Whitten CW, O'Boyle J, Sidhu B. Unexplained decrease in measured oxygen saturation by pulse oximetry following injection of lymphazurin 1 % (isosulfan blue) during a lymphatic mapping procedure. J Surg Oncol. 1999 ;70:126-9.
18. Levenback C, Coleman RL, Burke TW, Lin WM, Erdman W, Deavers M, et al. Lymphatic mapping and sentinel node identification in patients with cervix cancer undergoing radical hysterectomy and pelvic lymphadenectomy. J Clin Oncol 2002; 20:688-93.
19. Giuliano AE, Kirgan DM, Guenther JM, Morton DL. Lymphatic mapping and sentinel lymphadenectomy for breast cancer. Ann Surg 1994;220:391-401.

-
20. Noguchi H, Shiozawa I, Sakai Y, Yamazaki T, Fukuta T. Pelvic lymph node metastasis of uterine cervical cancer. *Gynecol Oncol* 1987;27:150-8 .
 21. De Hullu JA, Hollema H, Piers DA, Verheijen RHM, Van

Diest PJ, Mourits MJE, et al. Sentinel lymph node procedure is highly accurate in squamous cell carcinoma of the vulva. *J Clin Oncol* 2000;18:2811-6.