
OBSTETRICS

Correlation of Cervical Length Obtained from Transperineal Ultrasonography, Transvaginal Ultrasonography and Digital Examination

Nuanpun Tanmoun MD,
Kasem Raungrongmorakot MD,
Pornpimol Ruangvutilert MD. Ph.D,
Dittakarn Boriboonhirunsarn MD. MPH., Ph.D,
Pornpen Tontisirin BN,
Watcharaporn Butsansee P.N.

Department of Obstetrics and Gynecology, Faculty of Medicine Siriraj Hospital, Mahidol University, Bangkok 10700, Thailand

ABSTRACT

Objectives To evaluate the correlation of cervical length measurements obtained from digital examination, transperineal, and transvaginal ultrasonography techniques and to determine discomfort arising from each technique.

Design Cross-sectional study.

Setting Division of Maternal-Fetal Medicine, Department of Obstetrics and Gynecology, Faculty of Medicine Siriraj Hospital, Mahidol University.

Subjects Fifty pregnant women at 37 weeks' gestation or more who agreed to participate were enrolled.

Methods Cervical length was measured in each woman by both transperineal and transvaginal ultrasonography by experienced staff using standard technique and criteria. Digital examination was performed to evaluate cervical length without knowledge of sonographic results. Discomfort arising from each technique was assessed using visual analog scale.

Main outcome measures Correlation between cervical length measurements from each technique.

Results Cervical length measurement from digital examination was the lowest among the 3 techniques and measurements from transperineal and transvaginal ultrasonography were comparable. There were significant correlations of cervical length measured in each technique. Results from transperineal and transvaginal ultrasonography demonstrated the strongest correlation ($r\ 0.73$, $p < 0.001$). Significant higher discomfort score was demonstrated in digital examination while there was no significant difference between transperineal and transvaginal techniques.

Conclusion There were significant correlations between cervical length measurements from digital examination, transperineal and transvaginal sonographic assessments. Transperineal ultrasonography showed low discomfort. Such technique can be considered an alternative method when potential complications from digital examination or transvaginal ultrasonography of the cervix are anticipated and where resources are limited.

Key words: Cervical length, Transvaginal ultrasonography, Transperineal ultrasonography, Digital examination

The cervix is the cylindrical portion of the uterus which enters the vagina and lies at a right angle to it. Its length is between 2 - 4 centimeters. During pregnancy, the cervix is an important structure that separates the fetus from the outside environment. The closed and uneffaced cervix physically maintains the fetus in utero. Its secretion, forming the mucous plug, is partly responsible for prevention of ascending infection. Cervical length may vary in different subpopulations and has been shown to be different according to parity, gestational age, maternal age, race, nutritional status and certain obstetric complications.⁽¹⁻³⁾ The determination of cervical status, especially cervical length, is an important part of the identification and management of patients at risk for preterm birth and those with cervical incompetence.^(4,5) Digital examination remains the most comprehensive method available for evaluation of the cervix. All parameters, i.e., position, consistency, dilatation, effacement and station can be evaluated by this method.⁽⁶⁾ However, the nature of digital cervical examination is subjective. Cervical ultrasonography has an additional advantage, as compared with digital examination in visualization of the supravaginal portion of cervix, enabling the assessment of the internal cervical os where early changes from incompetence cervix and premature labor occur.⁽⁷⁻⁸⁾ Ultrasonography also has the theoretical advantage of decreasing the risk of infection and irritation of cervix compared to digital examination.⁽⁹⁾

Transabdominal ultrasonography has been used to assess the uterine cervix. However, this technique fails to image the cervix adequately in a number of cases in the third trimester of pregnancy.⁽¹⁰⁾ A distended bladder is a prerequisite for transabdominal scanning. Nevertheless, this sometimes distorts the lower uterine segment, causing false elongation of cervix. In addition, obscuration of the cervix can be caused by overlying fetal parts and poor image quality secondary to large maternal body habitus.^(7,10-11) To avoid the

problems inherent with transabdominal scanning, the sonographic image of the cervix can be alternatively performed with either a transperineal or transvaginal approach.

Transvaginal ultrasound of the cervix has been more accurate in assessment during pregnancy.^(10,12) Nevertheless, this technique may be relatively or absolutely contraindicated in some situations, including preterm labor, rupture of the membranes or placenta previa since it may increase risk of infection or induce vaginal bleeding.^(6,7,10,12)

Transperineal ultrasonography was first introduced in 1976 by Lewin et al.⁽¹³⁾ It is considered to be a suitable alternative to transvaginal or transabdominal ultrasonography because the ultrasound transducer does not enter the vagina or touch the cervix.

Similar technique is used for both transperineal and transvaginal ultrasonography, with hip abduction and elevated on a bolster in supine position. In both techniques, the pregnant women should empty their bladder. Transperineal scanning is performed with a 3.5 - 5.0 MHz convex transducer (the same as transabdominal transducer) while transvaginal approach needs a specifically designed 5.0 - 10.0 MHz convex transducer with an appropriate covering for hygienic purposes.^(7,12)

Transperineal ultrasonography is considered to be a reasonable alternative to transvaginal ultrasonography in evaluation of cervical length in situation that transvaginal ultrasonography is theoretically contraindicated, such as ruptured of membranes or with vaginal bleeding of uncertain etiology.⁽⁶⁾ Transperineal ultrasonography may also be more suitable for primary care unit where a transvaginal transducer is not available.

The purpose of this study was to evaluate the correlation of cervical length measurements obtained from digital examination, transperineal, and transvaginal ultrasonography techniques.

Materials and methods

After approval by the Ethical Committee on Research Involving Human Subject, Faculty of Medicine Siriraj Hospital, Mahidol University, the study was conducted in Maternal-Fetal Medicine Unit, Department of Obstetrics and Gynecology, Siriraj Hospital. A total of 50 pregnant women of 37 weeks' gestation or more who agreed to participate were enrolled. Exclusion criteria included women with ruptured of the membranes, previous cervical surgery, undiagnosed vaginal bleeding and true labor pain. All participants underwent transperineal ultrasonography, transvaginal ultrasonography and digital examination for cervical length evaluation.

Pregnant women were asked to empty their bladder and were placed in supine position with hip abducted and elevated on a bolster.^(6,14) An appropriately-covered 3.5-MHz curvilinear transducer was used for transperineal ultrasonography (Aloka 1700; Aloka Co., Ltd, Tokyo, Japan). The transducer was placed sagittally on the anterior to perineum and moved until a proper sagittal plane of cervix was obtained. Sonolucent endocervical mucus was used as a guide to identify the true external and internal os. The cervical length was measured in a straight line between the external and internal os. If the external and internal os were not clearly demonstrated, the case would be judged as unmeasurable. After the transperineal ultrasonography had been performed, transvaginal ultrasonography using a 7.5-MHz curvilinear endovaginal transducer with appropriate covering (Aloka 1700; Aloka Co., Ltd, Tokyo, Japan) was carried out. The transducer was placed in the anterior fornix of the vagina and care was taken to avoid exerting undue pressure on the cervix, which may cause artificial lengthening of the structure. The cervical length was measured using the same technique. Each ultrasonographic measurement was performed by experienced staff at Maternal Fetal Medicine unit. Finally, each pregnant woman underwent digital examination by another examiner who was blinded to transperineal and transvaginal ultrasonography results. The cervical length was

estimated in centimeter calibrating with the approximate length of the part of the examination finger inside the cervical canal if the external os was opened. If the external os was closed, the cervical length was estimated externally from the external os to the level of posterior fornix. Discomfort arising from the three techniques was also evaluated by visual analog scale with scaling from 0 - 10; which 0 means the least discomfort and 10 means the highest discomfort.

To avoid any bias, the results were not analyzed until the study has been completed. Correlation coefficients (*r*) were estimated to determine correlation of cervical length measurements between techniques. Comparison of cervical length measurements between techniques were made using paired t-test. Discomfort scores were compared using Wilcoxon signed-rank test. Statistical significance was considered when *p* value < 0.05.

Results

A total of 50 pregnant women were recruited in this study. Baseline characteristics showed that the mean age was 26.0 ± 6.2 years with mean BMI of 26.6 ± 3.7 Kg/m². They were average 38.7 ± 1.3 weeks' gestation. Their occupation was laboring in the majority of the women (70%), and most of them graduated secondary school or lower (86%).

Cervical length was evaluated by transperineal, transvaginal ultrasonography, and digital examination in each woman. Cervical length was unmeasurable by transperineal ultrasonography in 1 woman. Mean cervical length from each technique was shown in Table 1.

Table 1. Mean cervical length measured by digital examination, transperineal and transvaginal ultrasonography

Method	N	Mean \pm SD (cm)	P value*
Digital Examination	50	2.0 \pm 0.7	< 0.001
Transperineal Ultrasonography	49	3.2 \pm 0.6	0.174
Transvaginal Ultrasonography	50	3.3 \pm 0.7	-

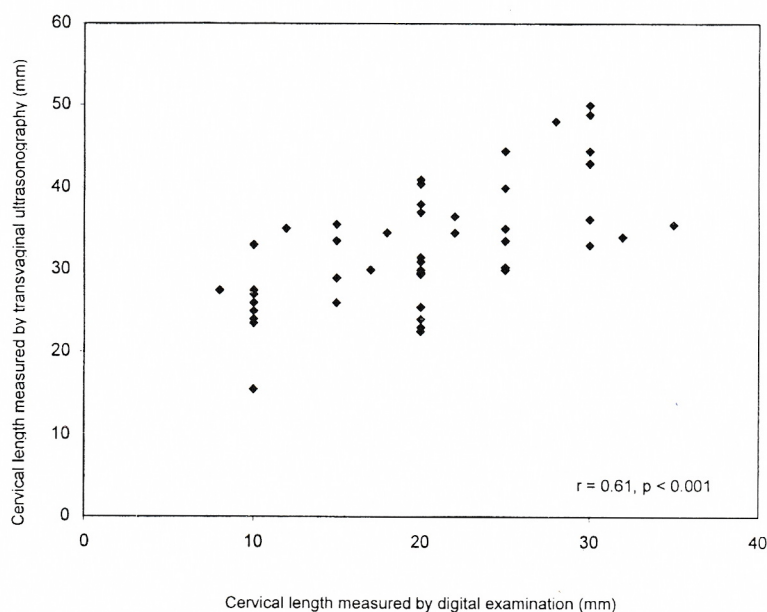
* Paired t-test, compared with transvaginal results

The mean cervical length measured by digital examination was the lowest among the 3 techniques. It was approximately 1.3 cm lower than those measured by transvaginal technique with statistical significance ($p < 0.001$). On the other hand, cervical length measured by transperineal technique was comparable to those measured by transvaginal technique.

Correlation between cervical lengths measurements by the 3 techniques were shown in Table 2. Results from every technique were significantly correlated with one another. The strongest correlation was observed between transperineal and transvaginal techniques (correlation coefficient 0.73, $p < 0.001$). Scatter plot diagrams were shown in Fig. 1 - 3.

Table 2. Correlation coefficient between cervical length measurements by different techniques

	Digital Examination	Transperineal Ultrasonography	Transvaginal Ultrasonography
Digital Examination	1.0	0.51 ($p < 0.001$)	0.61 ($p < 0.001$)
Transperineal Ultrasonography	0.51 ($p < 0.001$)	1.0	0.73 ($p < 0.001$)
Transvaginal Ultrasonography	0.61 ($p < 0.001$)	0.73 ($p < 0.001$)	1.0

**Fig. 1.** Scatter plot diagram between cervical length measured by digital examination and transvaginal ultrasonography.

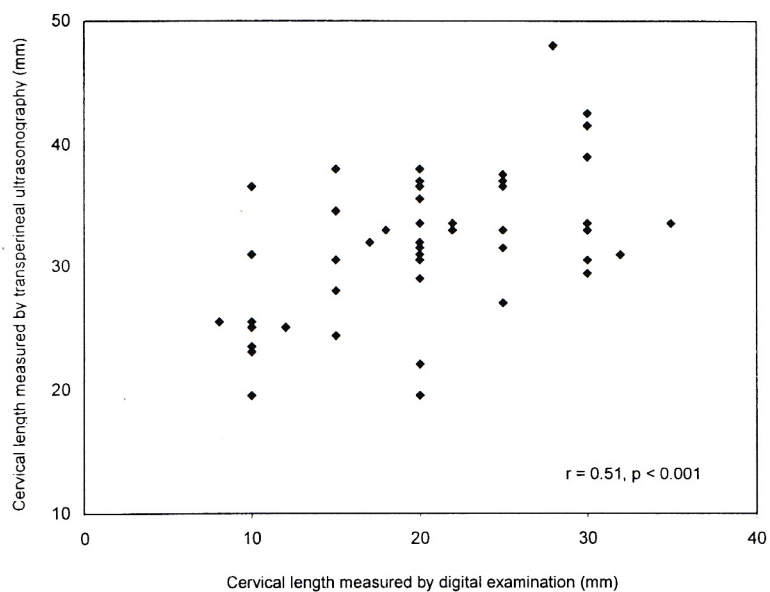


Fig. 2. Scatter plot diagram between cervical length measured by digital examination and transvaginal ultrasonography.

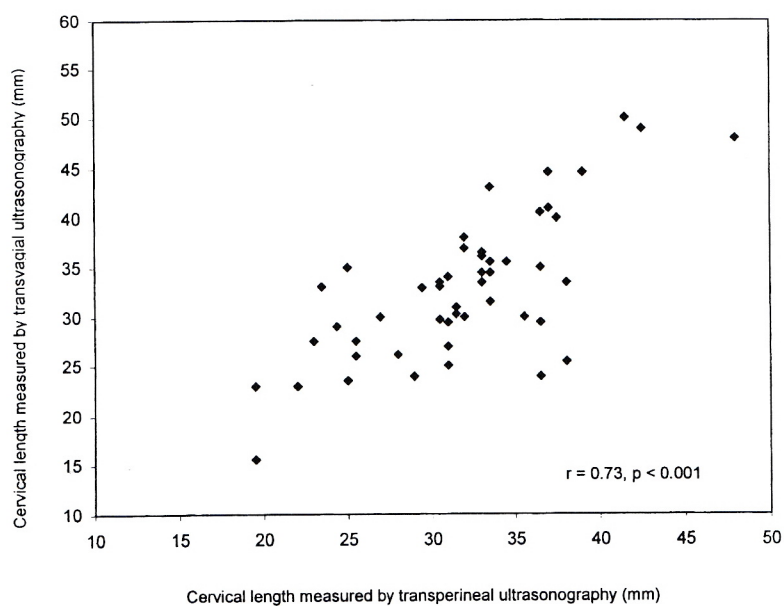


Fig. 3. Scatter plot diagram between cervical length measured by transperineal and transvaginal ultrasonography.

Discomfort scores arising from three techniques were demonstrated in the Table 3. Significant higher discomfort score was showed in digital examination,

but no significant different between transperineal and transvaginal ultrasonography were observed.

Table 3. Discomfort scores arising from digital examination, transperineal and transvaginal ultrasonography

Method	N	Median (IQR)	P value*
Digital Examination	50	5.2 (1.5 - 8.9)	< 0.001
Transperineal Ultrasonography	49	0.5 (0.3 - 1.7)	0.09
Transvaginal Ultrasonography	50	0.8 (0.4 - 2.2)	-

* Wilcoxon signed-rank test, compared with transvaginal results

Discussion

Evaluation of the gravid cervix plays an important role in management of a number of obstetric conditions including assessment of risk for preterm delivery, preinduction cervical assessment, and diagnosis of cervical incompetence, placenta previa and vasa previa.^(7,12) Although digital examination of the cervix is a part of routine care for obstetric patients, it has some drawbacks. Frequent digital examinations of the cervix have been associated with premature rupture of the membranes, possibly through mechanism involving increased bacterial inoculation of endocervical canal or prostaglandin release. In addition, digital examination can cause bleeding in cases with placenta previa.^(15,16) Use of ultrasound to assess cervical status reduces the potential for such complications. More over, ultrasound imaging can assess full cervical length and the status of the internal os without invading the endocervical canal. Thus, the use of ultrasound to assess the cervix and lower uterine segment in pregnancy is gaining popularity.

The results showed a significant correlation between digital examination and transvaginal ultrasonography in the assessment of cervical length. Several studies have also shown a good correlation between transvaginal ultrasound and digital examination of cervical length in pregnancy.^(9,10) However, only fair to poor correlations between the two measurements have been reported by others.^(8,17-21) Similar to other studies, we found that

cervical length assessed from digital examination is shorter than that from transvaginal technique. Ultrasonography is superior to manual palpation for assessing true cervical length due to the supravaginal portion of the cervix is out of reach of the examining finger.⁽²²⁾

The correlation between transperineal ultrasonography and digital examination of cervical length was also observed. This finding was inconsistent with those from studies of Mahony et al and Richey et al.^(23,24) Additional significant correlation was demonstrated between transperineal and transvaginal ultrasonography in our study, similar to previous study of Kurtzman et al.⁽²⁵⁾ Therefore, all the three measurement techniques are correlated.

In our study, transvaginal ultrasonography enabled excellent visualization and cervical length measurement in 100% of cases. These results were similar to those of Heath et al⁽³⁾ who were able to accomplish cervical length measurement in 100% of women using transvaginal approach with only none or mild discomfort. In the present study, Transperineal ultrasonography could visualize the cervix in 98% of cases in agreement with several previous studies, where transperineal ultrasonography gave adequate visualization of the cervix in 78 - 97 %.^(23,25-28) The results also demonstrated that discomfort scores were significantly higher among digital examination technique, but those of transperineal and transvaginal ultrasonography were comparable.

To reduce the variability and improve reproducibility of cervical length measurement using transvaginal ultrasonography, the following conditions are suggested: (1) the internal os is visualized as a flat dimple or an isosceles triangle, (2) the whole length of the cervix is visualized, (3) the external os appears symmetric, (4) the distance from the surface of posterior lip to the cervical canal is equal to the distance from the surface of the anterior lip to the cervical canal. These conditions, when met, ensure visualization of entire cervix and placement of only minimal pressure on the cervix by the transducer.⁽³⁾ Common pitfalls in transperineal ultrasonography include obscuring of the external cervical os by gas in rectum and mistaking the bladder for lower uterine segment. Placement of the patient in the left lateral decubitus position with an empty bladder often enables a clearer view of the cervix.

In this study, efforts have been implemented to avoid and minimize biases in cervical length measurements. All sonographic examinations were performed by experienced staff and all measurements were done the same standard practice and criteria described earlier. In addition, digital examination was performed without knowledge of the results from sonographic measurements.

In conclusion, transperineal ultrasonography is a possible method of choice when potential complications from digital examination or transvaginal ultrasonography of the cervix are anticipated. It is associated with high yield and low discomfort. It is easy to learn and to perform and can be repeated as many times as required. It is neither invasive nor time-consuming. Moreover, it requires no additional equipment since the transabdominal transducer can be used. An extra probe is not necessary while transvaginal approach needs a special one.⁽²⁸⁾ This makes it more suitable than and a better alternative to transvaginal technique, especially where resources are limited.

References

1. Anderson HF. Transvaginal and transabdominal

- ultrasonography of uterine cervix during pregnancy. *J Clin Ultrasound* 1991; 19: 77-83.
2. Iams SD, Goldenberg RL, Meis PJ, Mercer BM, Moawad A, Das A. The length of the cervix and risk of spontaneous premature delivery. *N Engl J Med* 1996; 334: 567-72.
3. Heath VC, Southall TR, Souka AP, Novgkov A, Nicolaides KH. Cervical length at 23 weeks gestation: Relation to demographic characteristics and previous obstetric history. *Ultrasound Obstet Gynecol* 1998; 12: 304-11.
4. Creasy RK. Preterm labor and delivery. In: Creasy RK, Resnik R, editors. *Maternal fetal medicine: Principle and practice*. Philadelphia: WB Saunders; 1989. 477-504.
5. Cousins L. Cervical incompetence, 1980: A time for reappraisal. *Clin Obstet Gynecol* 1980; 23: 467-79.
6. Sonek J, Shellhaas C. Cervical sonography: a review. *Ultrasound Obstet Gynecol* 1998; 11: 71-8.
7. Wong G, Levine D. Sonographic assessment of the cervix in pregnancy. *Seminars in Ultrasonography, CT and MRI* 1998; 19: 370-380.
8. Gomez R, Galasso M, Romero R, Mazor M, Sorokin Y, Concalves L, et al. Ultrasonographic examination of the uterine cervix is better than digital examination as a predictor of the likelihood of premature delivery in patients with preterm labor and intact membranes. *Am J Obstet Gynecol* 1994; 171: 956-64.
9. Goldberg J, Newman RB, Rust PF. Interobserver reliability of digital and endovaginal ultrasonographic cervical length measurement. *Am J Obstet Gynecol* 1997; 177: 853-8.
10. Brown JE, Thieme GA, Shah DM, Fleischer A, Boehm F. Transabdominal transvaginal endosonography: Evaluation of the cervix and lower uterine segment in pregnancy. *Am J Obstet Gynecol* 1986; 155: 721-6.
11. Confino E, Mayden K, Giglia RV, Vermesh M, Gleicher N. Pitfalls in sonographic imaging of the incompetent uterine cervix. *Acta Obstet Gynecol Scand* 1986; 65: 593-7.
12. Mahony BS. Ultrasound of the cervix during pregnancy. *Abdom Imaging* 1997; 22: 569-78.
13. Lewin D, Sodoul G, Sylvain-Leroy BS. Perineal echotomography: A new method of objective measurement of cervix. *J Gynecol Obstet Biol Reprod* 1976; 5: 651-5.
14. Hertzberg BS, Kliever MA, Baumeister LA, McNally PB, Fazekas CK. Optimizing transperineal sonography imaging of the cervix : the hip elevation technique. *J Ultrasound Med* 1994; 13: 933-6.
15. Lenihan JP. Relationship of antepartum pelvic examination to premature rupture of membranes. *Obstet Gynecol* 1984; 63: 33-7.
16. Cretsas G, Palatos M, Lolis D, Aravantinos D, Kaskarelis D. Bacterial contamination of the cervix and premature rupture of membranes. *Am J Obstet Gynecol* 1981; 139: 522-5.
17. Lim BH, Mahmood TA, Smith NC, Beat I. A prospective comparative study of transvaginal ultrasonography and digital examination for cervical assessment in the third trimester of pregnancy. *J Clin Ultrasound* 1992; 20: 599-603.

18. Sonek JD, Iams JD, Blumemfeld M, Johnson F, London M, Gabbe S. Measurement of cervical length in pregnancy: comparison between vaginal ultrasonography and digital examination. *Obstet Gynecol* 1990; 76: 172-5.
19. Paterson-Brown S, Fish NM, Edmonds DK, Rodeck CH. Preinduction cervical assessment by Bishop's score and transvaginal ultrasound. *Eur J Obstet Gynecol Reprod Biol* 1991; 40: 17-23.
20. Iams JD, Paraskos J, London MB, Teteris JN, Johnson FF. Cervical sonography in preterm labor. *Obstet Gynecol* 1994; 84: 40-6.
21. Jackson GM, Ludmir Jack, Bader TJ. The accuracy of digital examination and ultrasound in the evaluation of cervical length. *Obstet Gynecol* 1992; 79: 214-8.
22. Singer A, Jordan JA. The anatomy of the cervix. In: Jordan JA, Singer A, editors. *The cervix*. London: WB Saunders; 1976. 13-36.
23. Mohony BS, Nyberg DA, Luthy DA, Hirsch JH, Hickok DE, Petty CN. Translabial ultrasound of the third trimester uterine cervix: correlation with digital examination. *J Ultrasound Med* 1990; 9: 717-23.
24. Richey SD, Ramin KD, Roberts SW, Ramin SM, Cox SM, Twickler DM. The correlation between transperineal sonography and digital examination in the evaluation of the third trimester cervix. *Obstet Gynecol* 1995; 85: 745-8.
25. Kurtzman JT, Goldsmith LJ, Gall SA, Spinnato JA. Transvaginal versus transperineal ultrasonography: a blinded comparison in the assessment of cervical length at midgestation. *Am J Obstet Gynecol* 1998; 179: 852-7.
26. Carr DB, Smith K, Parson L, Chansky K, Shields LE. Ultrasonography for cervical length measurement: agreement between transvaginal and translabial techniques. *Obstet Gynecol* 2000; 96: 554-8.
27. Cicero S, Skentou C, Souka A, To MS, Nicolaides KH. Cervical length at 22-24 weeks of gestation: comparison of transvaginal and transperineal-translabial ultrasonography. *Ultrasound Obstet Gynecol* 2001; 17: 335-40.
28. Zilianti M, Azuaga A, Calderon F, Redondo C. Transperineal sonography in second trimester to term pregnancy and early labor. *J Ultrasound Med* 1991; 10: 481-5.