

Femoral neck fracture in the elderly

Nattapol Tammachote

Femoral neck fracture is one of the most serious health problems in the elderly patients. The incidence is increasing due to the growing of aging society. The worldwide incidence of hip fractures is expected to reach 6 millions per year by the year 2050.¹ These patients often have preexisting underlying medical conditions which are not only prolong the recovery after surgery but also increase the risk of postoperative complications and mortality. The reported 30-day mortality rate after femoral neck fracture in the elderly was approximately 10% and increased to 33% at one year after hip fracture.²

The common cause of femoral neck fracture in the elderly is fall on the same level while the fracture in the young people is often from high energy trauma such as vehicle collision or fall from a great height. These patients come to the hospital with pain around the groin and hip that get worse when they bear weight or try to move the hip. They are unable to walk and may appear shortening of the affected leg. A simple diagnostic tool of femoral neck fracture is plain radiographs (Figure 1). In some situations the fracture line may not be seen from the X-rays images but the patient have persisted symptom, magnetic resonance imaging (MRI) may be used as an advance imaging modality to diagnose the presumed hip fracture which is not apparent on initial radiographs.³

The goals of treatment of femoral neck fracture are to surgically fix it as soon as possible to get the patient back to the pre-injury functional level and prevent complications. The choice of treatment

depends on fracture configuration, patient profiles, and surgeon preference. The patient factors such as patient's health status measured by American Society of Anesthesiologists score, preinjury ambulatory status, age, cognitive function, and comorbidities. In non-displaced femoral neck fracture internal fixation with multiple screws is preferred. In contrast, the displaced femoral neck fractures are at high risk of non-union and osteonecrosis of femoral head⁴, the hip replacement is the gold standard of treatment.

The hip replacement options for femoral neck fracture in the advanced age include hemiarthroplasty and total hip arthroplasty (THA) (Figure 2). Hemiarthroplasty replaced only the femoral head side with prosthesis while THA replaced on both acetabulum and femoral head sides. Hemiarthroplasty is less sophisticated and has been associated with low dislocation rate, less blood loss, shorter surgical times and lower costs.⁵ However, some patients treated with hemiarthroplasty required conversion to THA due to groin pain from acetabular erosion. THA has been proved to provide better functional outcomes and patient satisfaction.^{6,7} The recent study recommended THA is the optimal treatment for patients with expected life expectancy more than 4 years or in those patients under 80 years old.⁸

The major concern issue about THA in patients with femoral neck fracture is higher rate of hip dislocation compare to total hip replacement in other hip disease. The hip dislocation rate is approximately

2 times higher compared with hemiarthroplasty.⁹ The surgical techniques to concur this problem include using front side surgical approach, proper prostheses placement, adequate soft tissue tension and proper implant selection. Author chooses direct anterior approach (Figure 2) for hip replacement in femoral neck fracture patient. This approach has minimal risk of postoperative instability by maintaining posterior soft tissue structures.

Femoral neck fracture in the elderly is associated with osteoporosis. Prevention of the risk of other refracture is necessary. Patients should be investigated the bone mineral density by using DEXA scan. In the US, only 21% of hip fracture patients received affective drug therapy for other osteoporotic

fracture prevention.¹⁰ We should not only fix the fracture but also had to prescribe the drug for osteoporosis and secondary fracture prevention. Patients receiving osteoporotic medications had lower mortality rates than untreated patients approximately 5 times.¹¹

In conclusion, femoral neck fracture is an important issue in healthcare system. The appropriate management is not only the proper fracture management but also the intergraded care with multidisciplinary teams to get the patients back to the pre-fracture status.

The osteoporotic re-fracture prevention is also another factor to reduce the patients' mortality rate.

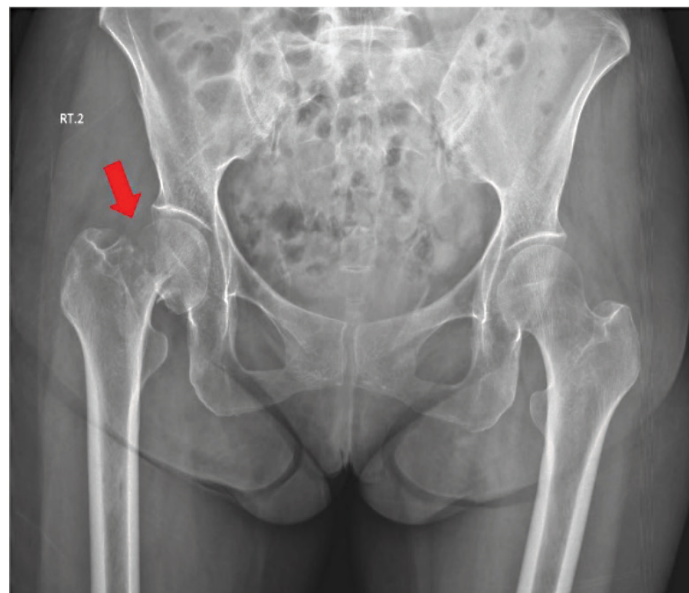


Figure 1 Plain radiograph shows displaced right femoral neck fracture.

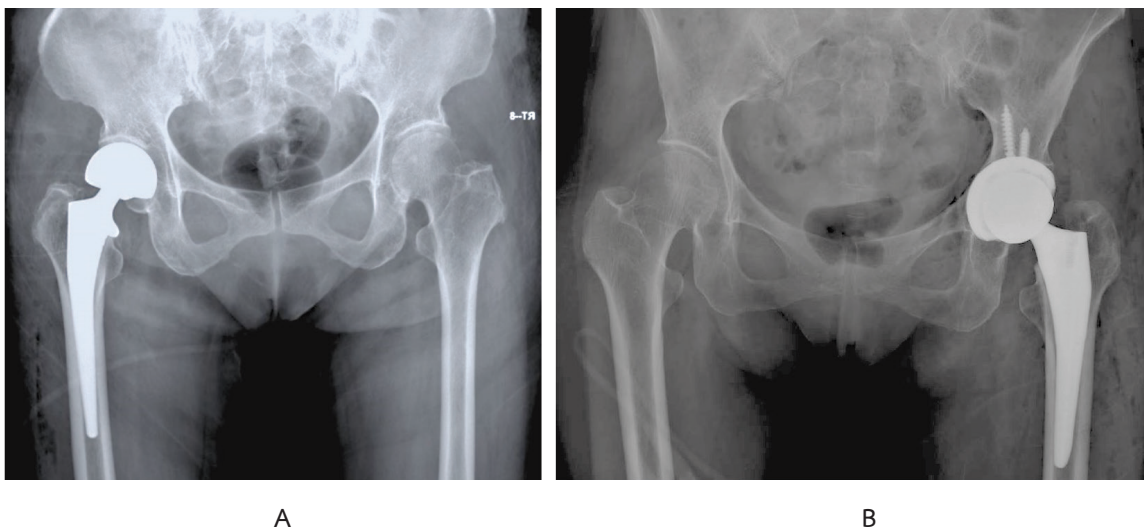


Figure 2 Plain radiographs show A. Bipolar hemiarthroplasty. B Total hip arthroplasty.

References

1. Kannus P, Parkkari J, Sievänen H, Heinonen A, Vuori I, Järvinen M. Epidemiology of hip fractures. *Bone*. 1996;18(1 Suppl):57s-63s.
2. Roche JJ, Wenn RT, Sahota O, Moran CG. Effect of comorbidities and postoperative complications on mortality after hip fracture in elderly people: prospective observational cohort study. *Bmj*. 2005;331(7529):1374.
3. Roberts KC, Brox WT, Jevsevar DS, Sevarino K. Management of hip fractures in the elderly. *J Am Acad Orthop Surg*. 2015;23(2):131-137.
4. Miyamoto RG, Kaplan KM, Levine BR, Egol KA, Zuckerman JD. Surgical management of hip fractures: an evidence-based review of the literature. I: femoral neck fractures. *J Am Acad Orthop Surg*. 2008;16(10):596-607.
5. Keating JF, Grant A, Masson M, Scott NW, Forbes JF. Displaced intracapsular hip fractures in fit, older people: a randomised comparison of reduction and fixation, bipolar hemiarthroplasty and total hip arthroplasty. *Health Technol Assess*. 2005;9(41):iii-iv, ix-x, 1-65.
6. Schmidt AH, Leighton R, Parvizi J, Sems A, Berry DJ. Optimal arthroplasty for femoral neck fractures: is total hip arthroplasty the answer?. *J Orthop Trauma*. 2009;23(6):428-433.
7. Bishop J, Yang A, Githens M, Sox AH. Evaluation of Contemporary Trends in Femoral Neck Fracture Management Reveals Discrepancies in Treatment. *Geriatr Orthop Surg Rehabil*. 2016;7(3):135-141.
8. Lewis DP, Wæver D, Thorninger R, Donnelly WJ. Hemiarthroplasty vs Total Hip Arthroplasty for the Management of Displaced Neck of Femur Fractures: A Systematic Review and Meta-Analysis. *J Arthroplasty*. 2019;34(8):1837-1843. e2.
9. Bhandari M, Einhorn TA, Guyatt G, Schemitsch EH, Zura RD, Sprague S, et al. Total Hip Arthroplasty or Hemiarthroplasty for Hip Fracture. *N Engl J Med*. 2019;381(23):2199-208.
10. Solomon DH, Johnston SS, Boytsov NN, McMorrow D, Lane JM, Krohn KD. Osteoporosis medication use after hip fracture in U.S. patients between 2002 and 2011. *J Bone Miner Res*. 2014;29(9):1929-1937.
11. Rotman-Pikielny P, Frankel M, Lebanon OT, Yaacobi E, Tamar M, Netzer D, et al. Orthopedic-Metabolic Collaborative Management for Osteoporotic Hip Fracture. *Endocr Pract*. 2018;24(8):718-725.