



Vet Integr Sci
Veterinary Integrative Sciences

ISSN: 2629-9968 (online)

Website: www.vet.cmu.ac.th/cmvj

**Case report**

The surgical repair of a congenital peritoneopericardial diaphragmatic hernia in Maine Coon cat

Chattida Panprom¹, Palin Jiwaganont¹, Ratikorn Bootcha¹ and Soontaree Petchdee^{2,*}

¹ Kasetsart University Veterinary Teaching Hospital, Faculty of Veterinary Medicine,
Kasetsart University, Kamphaeng Saen, Nakorn Pathom 73140, Thailand

² Department of Large Animal and Wildlife Clinical Science, Faculty of Veterinary Medicine,
Kasetsart University, Kamphaeng Saen Nakorn Pathom 73140, Thailand

Abstract

A 1-year-old female Maine Coon cat presented with a history of labored breathing and intermittent cough. Thoracic radiography revealed a diaphragmatic hernia; echocardiography showed adhesions of a hepatic lobe and gall bladder to the left myocardium. After a final diagnosis of peritoneopericardial diaphragmatic hernia (PPDH), a surgical treatment was successfully done to repair the congenital PPDH. Blood transfusion was performed during surgical correction to ameliorate the excessive blood loss during liver lobectomy. This surgical technique can close the diaphragmatic defect and be used as a treatment option to prevent further herniation and reduce compliance with heart failure complications. Surgical treatment provides an excellent outcome for cats with a congenital pericardial-diaphragmatic anomaly. However, severe hemorrhage may occur with the abdominal organ's adhesion to the pericardium, such as the liver. This study described the diagnosis and surgical treatment. The surgical procedure may provide the information for further successful treatment in the feline congenital pericardial defect.

Keywords: : Feline, Pericardial diaphragm hernia, Surgical treatment

Corresponding author: Soontaree Petchdee, Department of Large Animal and Wildlife Clinical Sciences, Faculty of Veterinary Medicine, Kasetsart University, Kamphaeng Saen Campus, Nakorn Pathom 73140, Thailand. E-mail: fvetstr@ku.ac.th.

Article history; received manuscript: 11 June 2021,
revised manuscript: 1 July 2021,
accepted manuscript: 13 July 2021,
published online: 16 July 2021

Academic editor; Korakot Nganvongpanit



Open Access Copyright: ©2021 Author (s). This is an open access article distributed under the term of the Creative Commons Attribution 4.0 International License, which permits use, sharing, adaptation, distribution, and reproduction in any medium or format, as long as you give appropriate credit to the original author (s) and the source.

INTRODUCTION

Peritoneopericardial diaphragmatic hernia (PPDH) is a common congenital pericardial defect encountered in cats (Khan et al., 2019; Hodgkiss-Geere et al., 2015; Banz and Gottfried., 2010; Margolis et al., 2018). PPDH is an abnormal development of the dorsolateral septum transversum or the lateral pleuro-peritoneal folds that cause the communication between the peritoneal and pericardial sac through the diaphragm (Berry et al., 1990). This diaphragmatic defect resulted in the herniation of the abdominal organs into the pericardial cavity. Previous studies have reported that the overall incidence of congenital PPDH in cats was 0.59%, with the age range from 2-138 months (Banz and Gottfried, 2010). This congenital defect is usually presented in long-haired breeds cats. Maine coon breed predisposition to PPDH has been found, PPDH is usually an incidental finding with no specific clinical signs and rarely results in a large amount of pericardial effusion and cardiac tamponade (Linton et al., 2016; Kovacich et al., 2001). However, adhesions of the abdominal viscera to the pericardial sac may be observed, and the liver is the most found organ into the pericardial sac in feline patients (Reimer et al., 2004).

Surgery is the definitive treatment, and it is necessary for emergencies. In addition, severe clinical signs, including dyspnea or vomiting, necessitate surgical repair. A previous study indicated that animals with clinical signs of PPDH were more likely to undergo surgery than animals without such signs. (Burns et al., 2015; Statz et al., 2007). The prognosis of PPDH in dogs and cats is good, and the postoperative mortality in animals undergoing the surgical correction was 14% (Banz and Gottfried., 2010).

CASE PRESENTATION

The cat (one year old, female, Maine Coon) presented with a history of labored breathing, intermittent cough, while no traumatic incident was reported. The cat was asymptomatic during the physical examination, with no pain on the abdominal palpation, normal heart, and lung sound. Thoracic radiography and echocardiogram were performed to aid in the diagnosis. Thoracic radiography showed enlargement of the cardiac silhouette and discontinuity of the diaphragm. Echocardiography demonstrated that the left hepatic lobe with gallbladder adhered to the left ventricular myocardium. Cat underwent surgical treatment to repair the diaphragmatic remnants with absorbable suture, and a thoracostomy tube was placed to drain the effusion fluid. Liver lobectomy was performed to remove the adhesions of the herniated liver lobe to the myocardium. Hyperthermia and oxygen dependency was observed after the surgical correction. Blood transfusion was performed during the surgical treatment, and the cat was treated with cefixime (5 mg/kg IV q12h) and intravenous lactated Ringer's solution (5 mg/kg/hr). The cat showed improvement in clinical symptoms after surgical treatment, and thoracic radiography revealed the extent of the diaphragm and found the separation of the abdominal and thoracic organs.

CLINICAL DIAGNOSIS and FINDINGS

Blood samples were collected and submitted for routine hematological and biochemical investigations, as shown in [Table 1](#).

Table 1 Signalment, hematological and serum biochemical parameters before, 3 days and 14 days after surgical repair

Parameter	Before	After		Reference value *
		3 days	14 days	
WBC (x10 ³ /uL)	12.56	14.82	13.03	5.5-19
RBC (x10 ⁶ /uL)	7.83	5.46	6.89	5-10
HGB (gm%)	11.6	8.2	9.7	10-15
PCV (%)	35.2	23.4	30.1	30-45
Band neutrophil (x10 ³ /uL)	-	0.67	-	0-0.3
Segmented neutrophil (x10 ³ /uL)	6.78	9.18	5.8	2.5-12.5
Lymphocyte (x10 ³ /uL)	5.40	4.44	6.6	1.5-7.0
Monocyte (x10 ³ /uL)	0.25	0.44	0.39	0-8.5
Eosinophil (x10 ³ /uL)	0.12	0.29	0.13	0-7.5
BUN (mg%)	30.9	20.8	26.9	15-34
Creatinine (mg%)	2.04	1.39	2.41	<2.0
Total Protein (gm%)	8.0	6.2	8.4	5.8-7.8
ALT (U/L)	59	399	43	28-76
AST (U/L)	23	129	20	12-40

* Reference ranges used at the Laboratory of Veterinary Diagnostic Unit, Faculty of Veterinary Medicine, Kasetsart University, Thailand

Thoracic radiography

Thoracic radiography was used to aid the diagnosis of PPDH, such as enlarge caudal cardiac silhouette, coexisting with diaphragmatic discontinuity, and irregular soft tissue over the caudal heart was observed. Thoracic radiographs of the cat are shown in [Figure 1](#).

Echocardiography

The patient underwent a transthoracic echocardiographic examination using a General Electric Vivid 5s ultrasound system to examine the heart function. Echocardiographic examination (Echo) was recorded at baseline and after the surgical correction ([Table 2](#)). The measurement was performed in a parasternal long and short axis view in a lateral recumbent position with no sedation. The imaging was assessed before and after surgical repair and was captured and stored for offline analysis. Left ventricular wall structure and function were calculated by measuring the images from two-dimensional and M-mode planes. Ventricular wall thickness and dimensions were recorded during diastole and systole to obtain the cardiac parameters.

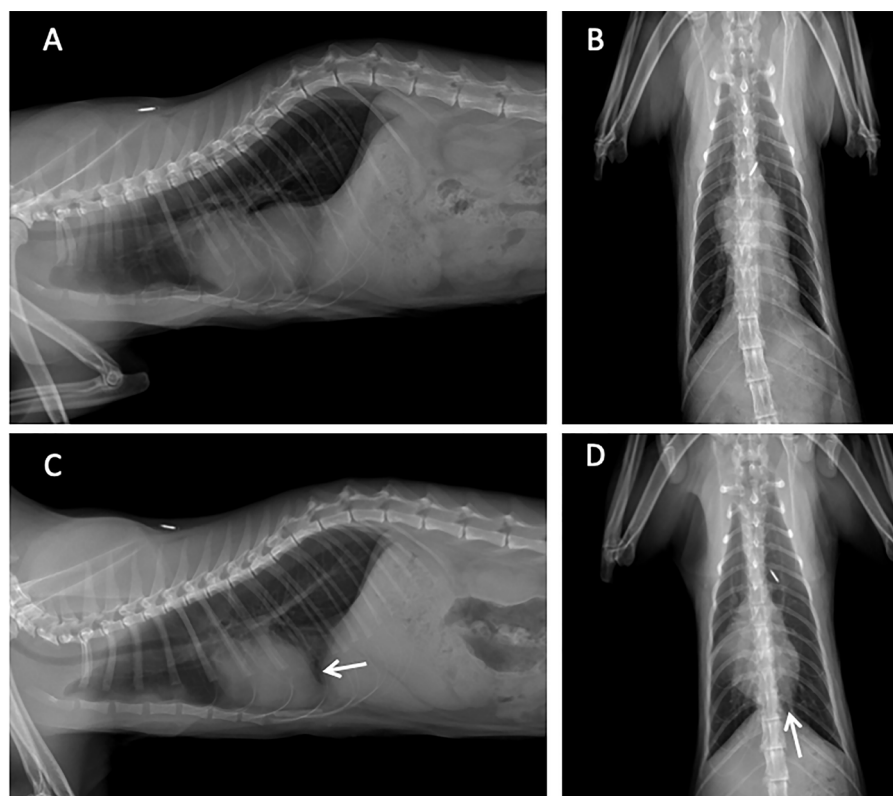


Figure 1 Lateral and ventrodorsal radiographs showed enlarged cardiac silhouette with suspicion of liver lobe displacement before surgical repair (A and B), and after repair showed the border of diaphragm (white arrow) and liver lobe over the caudal heart was disappeared (C and D).

Table 2 Echocardiography parameters before and after surgical repair of PPDH in cat

Parameters	Before	14 days after repair
Echocardiography		
IVSs (cm)	0.4	0.6
IVSd (cm)	0.4	0.6
LVIDs (cm)	1.6	1.3
LVIDd (cm)	2.1	1.6
LA:Ao	1.63	1.52
FS (%)	22	25
FAC (%)	42	50
TAPSE	0.6	0.8
Heart rate (bpm)	200	140
VHS	8.5	8

SURGICAL TREATMENT

Cat was pre-medicated with intravenous fentanyl (50 mcg/kg) followed by alfaxalone (1 mg/kg) for induction. The anesthesia was maintained by isoflurane with 2-5% concentration during spontaneous ventilation. A limb lead electrocardiogram was used to determine the cardiac rhythm. Surgical repair was done, and a 7 cm ventral midline incision was made from the xiphoid extending caudally (Figure 2). The defected diaphragm was closed with 3-0 monofilament absorbable sutures, and parts of the left liver lobe were removed from the myocardium. Air was evacuated from the thorax until negative pressure. After the diaphragmatic defect correction, the abdomen was closed with 3-0 monofilament absorbable sutures, and the skin was sutured with 3-0 surgical nylon.

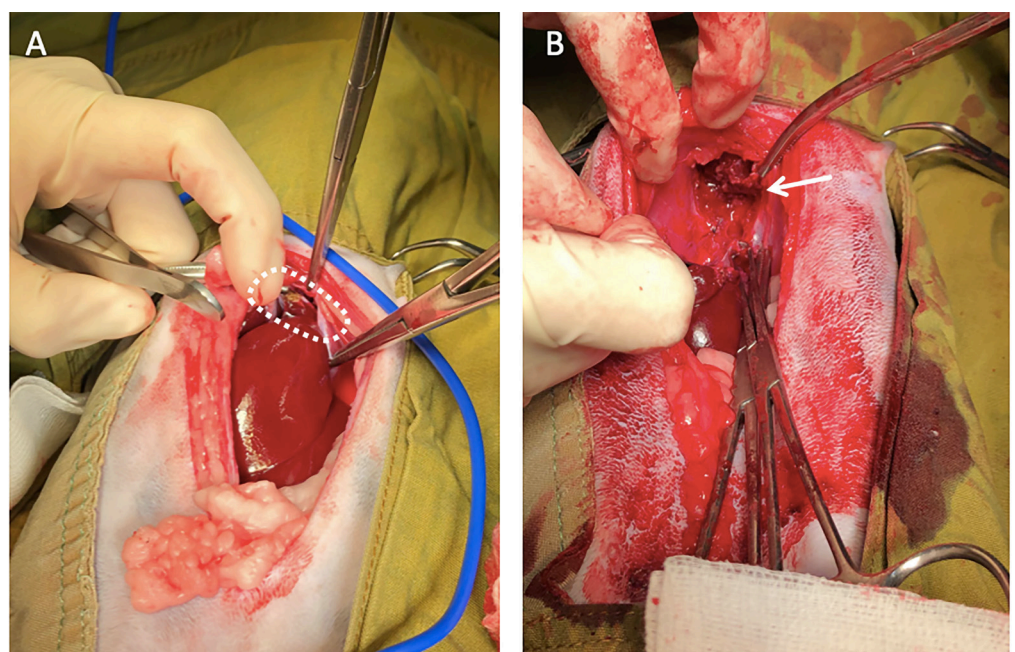


Figure 2 Image of the diaphragm that has a 2.5 cm defect continuous with pericardial sac (white circle) and the left liver lobe is displaced through the defect and form the adhesion with the left ventricle (A). After the surgical repair, the herniated liver lobe was removed from the myocardium (B; white arrow).

EVALUATION

Postoperatively, the patient had shown intermittent cough and dyspnea without murmur and arrhythmias after surgical repair. Fentanyl was used for pain management after surgery by CRI at 5 mcg/kg/hr. The daily follow-up was done under close supervision in the critical care unit. Eventually, the animal was discharged 14 days after the surgical treatment. The hematological examination in the cat revealed anemia with decreased packed cell volume (PCV), decreased platelet count, an increased number of white blood cells. The biochemical blood profiles showed elevated hepatic enzymes such as alanine aminotransferase (ALT), aspartate aminotransferase (AST) showed in Table 1.

Postoperative thoracic radiographs revealed peritoneopericardial hernia repair and stabilization of normal anatomy in both thoracic and abdominal cavities. Echocardiography showed the liver lobe adhered with the left ventricle, and after the surgical treatment, no liver lobe is visible (Figure 3). Blood transfusion was performed in an open system of the blood collection from the donor cat. The vital parameters such as respiratory rate, mucous membrane color, and capillary refill time are made continuously at baseline and every 30 minutes until the transfusion is completed.

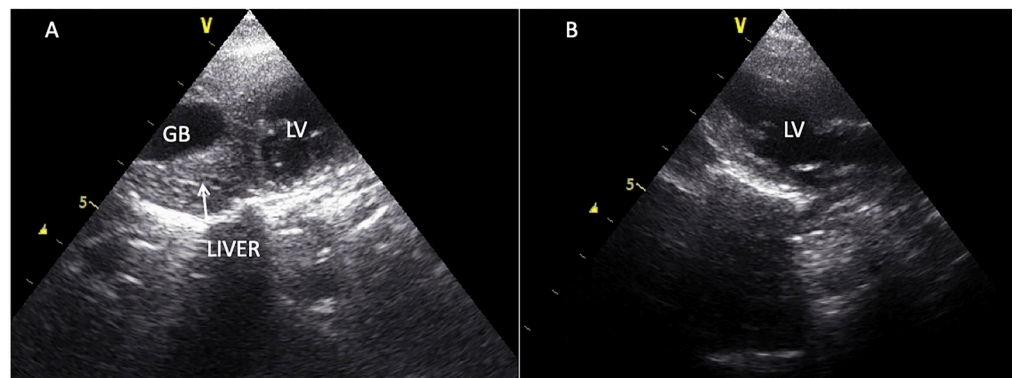


Figure 3 Echocardiographic image showing the adhesion of myocardium with liver lobe (white arrow) in the left ventricle (A) and after surgical correction, no liver lobe is visible after the procedure (B).

DISCUSSION

Radiographic and ultrasonographic findings can diagnose congenital PPDH similar to this study (Rosenstein et al., 2001; Hock et al., 2018). In addition, thoracic radiography and echocardiography may aid in diagnosis and rule out any other anomalies such as hypertrophic cardiomyopathy, dilated cardiomyopathy, and pericardial effusion (Barrett and Kittrell, 1966). In this present study, the echocardiographic image provided the final diagnosis. The images showed no pericardial boundaries, which is different from the usual conditions. Due to the small amount of pericardial lubricant in the pericardial sac, ultrasonography images can clearly distinguish the pericardial region from the liver lobe.

Previous reports suggested that the detection of the PPDH often happened by chance from the routine examination (Margolis et al., 2018). However, the animals showed clinical signs in this present case report, such as labored breathing and intermittent cough, and surgical treatment is the best effective treatment. This report may provide helpful information in clinical practice to help diagnose and treat the disease effectively in the future.

After diagnosis, a surgical treatment protocol was designed to repair the defect and to prevent further herniation. Therefore, surgical treatment of PPDH was the treatment of choice in our study. In general, therapy for PPDH requires a surgical correction which should be performed as early as possible in young animals (Fossum, 2007). In this study, surgical treatment was performed when the cat was 1-year old, and as a result, marked adhesions were noticed. In this

case, resection of the liver was required to remove the adhesion part. It is better not to interfere with heart function and prevent heart failure than the lobectomy of the liver.

Although many previous reports for surgical correction and the method used in surgical treatment have been described in the textbook, it has been reported that the success rate of surgical treatment is relatively low (Banz and Gottfried, 2010). Therefore, this study provides helpful information to guide the preparation and may help a further higher success rate of surgical correction in similar case studies.

This surgical procedure was performed on a cat with severe adhesion and carried the risk for excessive hemorrhage from the liver when performed the liver lobectomy. The appropriate blood transfusion was a good resolution when there was marked adhesion. Post-surgical treatment with blood transfusion, liver support, and positive inotrope drug showed improvement in symptoms such as cough and dyspnea. In addition, the prophylaxis treatment with a ferric supplement such as haemomaxx® will provide the alleviation of thrombocytopenia after surgical correction in this study. There are some limitations of this treatment method. The surgical technique can correct the herniation through the diaphragm. However, the severe adhesion of the herniated liver lobe with the myocardium can cause compliance heart failure. Previous studies have indicated that the success rate of surgical treatment is relatively low. It also has a poor prognosis in cases of abnormal heart function (Banz and Gottfried, 2010).

In the present case report, the contraction function of the heart is poor due to the attachment of the abdominal organs to the pericardium and left ventricle. In addition, the surgical treatment in this present study has been successful. Therefore, this case study is helpful to give the information for the decision making for a similar case with a large attachment of the abdominal organ and the heart.

Further administration of a drug such as Pimobendan is necessary to help the heart contraction. Another limitation is that for significant defects in which tension of the closure is a problem, autologous flaps or prosthetic patches can be used. Autologous flaps or prosthetic patches can give the barrier and eliminate additional pericardial adhesion (Wallace et al., 1992; Legallet et al., 2017). Moreover, the significant defect, adhesion, can cause complications after treatment, i.e., recurrent PPDH. The mesh/graft might be needed to decrease the complication after surgical correction. In addition, the adhesion can cause a large amount of blood loss, so blood transfusion needs to be decided before surgery.

In conclusion, this procedure was safe and provided a good prognosis, and could prevent recurrent herniation. This study suggested that surgical repair could be used to treat congenital PPDH in dogs and cats.

ACKNOWLEDGEMENTS

The authors are grateful to Kasetsart Veterinary Teaching Hospital, KamphaengSaen, Thailand for providing the necessary facilities.

CONFLICT OF INTEREST

The authors declare that there is no conflict of interest.

FUNDING

The authors received no financial support for this study.

ETHICAL APPROVAL

This work involved the use of non-experimental animals only (including owned or unowned animals and data from prospective or retrospective studies). Established internationally recognized high standards ('best practice') of individual veterinary clinical patient care were followed. Ethical approval from a committee was therefore not necessarily required..

INFORMED CONSENT

Informed consent (either verbal or written) was obtained from the owner or legal custodian of all animal(s) described in this work (either experimental or non-experimental animals) for the procedure(s) undertaken (either prospective or retrospective studies).

REFERENCES

- Banz, A.C., Gottfried, S.D., 2010. Peritoneopericardial diaphragmatic hernia: a retrospective study of 31 cats and eight dogs. *J. Am. Anim. Hosp. Assoc.* 46, 398-404.
- Barrett, R.B., and Kittrell, J.E. 1966. Congenital peritoneopericardial diaphragmatic hernia in a cat. *Vet. Radiol.* 7(1),21-26.
- Berry, C.R., Koblik, P.D., Ticer, J.W., 1990. Dorsal peritoneopericardial mesothelial remnant as an aid to the diagnosis of feline congenital peritoneopericardial diaphragmatic-hernia. *Vet. Radiol.* 31, 239-245.
- Burns, C.G., Bergh, M.S., McLoughlin, M.A., 2013. Surgical and nonsurgical treatment of peritoneopericardial diaphragmatic hernia in dogs and cats: 58 cases (1999-2008). *J. Am. Vet. Med. Assoc.* 242, 643-650.
- Fossum, T.W., 2007. Surgery of the lower respiratory system: pleural cavity and diaphragm. In: Fossum TW, ed. *Small Animal Surgery*. 3rd ed. St. Louis: Mosby, Inc., pp. 896-929.
- Hoek, I., Payne, J.R., Feugier, A., Connolly, D.J., 2018. Inter-observer variability for cardiac ultrasound measurements in cats repeated at different time points in early adult life. *Vet. Anim. Sci.* 5, 44-46.
- Hodgkiss-Geere, H.M., Palermo, V., Liuti, T., Philbey, A.W., Marques, A., 2015. Pericardial cyst in a 2-year-old Maine Coon cat following peritoneopericardial diaphragmatic hernia repair. *J. Feline Med. Surg.* 17(4), 381-386.
- Khan, S., Sajik, D., Calvo, I., Phillips, A., 2019. Novel peritoneopericardial diaphragmatic hernia in a dog. *Vet. Rec. Case. Rep.* 7, e000896.
- Kovacich, J.C., Boyle, E.M. Jr., Needle, D., Maier, R.V., 2001. Iatrogenic intrapericardial diaphragmatic hernia associated with cardiac tamponade. *J. Trauma.* 50(1), 136-139.
- Legallet, C., Thieman, K., Mankin, L., Selmic, E., 2017. Prognostic indicators for perioperative survival after diaphragmatic herniorrhaphy in cats and dogs: 96 cases (2001-2013). *BMC Vet. Res.* 13(1), 16.

- Linton, M., Tong, L., Simon, A., Buffa, E., McGregor, R., Labruyère, J., Foster, D., 2016. Hepatic fibrosarcoma incarcerated in a peritoneopericardial diaphragmatic hernia in a cat. *JFMS Open Rep.* 17; 2(1), 2055116916638681.
- Margolis, C., Zakošek Pipan, M., Demchur, J., Or, M., Henthorn, P., Casal, M.L., 2018. Congenital peritoneopericardial diaphragmatic hernia in a family of Persian cats. *JFMS Open Rep.* 4(2), 2055116918804305.
- Reimer, S.B., Kyles, A.E., Filipowicz, D.E., Gregory, C.R., 2004. Long-term outcome of cats treated conservatively or surgically for peritoneopericardial diaphragmatic hernia: 66 cases (1987-2002). *J. Am. Vet. Med. Assoc.* 224(5), 728-732.
- Rosenstein, D.S., Reif, U., Stickle, R.L., Watson, G., Schall, W., Amsellem, P., 2001. Radiographic diagnosis: pericardioperitoneal diaphragmatic hernia and cholelithiasis in a dog. *Vet. Radiol. Ultrasound.* 42(4), 308-310.
- Statz, G.D., Moore, K.E., Murtaugh, R.J., 2007. Surgical repair of a peritoneopericardial diaphragmatic hernia in a pregnant dog. *J. Vet. Emerg. Crit. Care.* 17, 77-85.
- Wallace, J., Mullen, H.S., Lesser, M.B., 1992. A technique for surgical correction of peritoneal pericardial diaphragmatic hernia in dogs and cats. *J. Am. Vet. Med. Assoc.* 28, 503-510.

How to cite this article;

Chattida Panprom, Palin Jiwaganont, Ratikorn Bootcha and Soontaree Petchdee. The surgical repair of a congenital peritoneopericardial diaphragmatic hernia in Maine Coon cat. *Veterinary Integrative Sciences.* 2021; 19(3): 439- 447.
